

CASE REPORT

Microsurgical reconstruction of congenital upper extremity deformities of malformations

Koji Takamoto¹  | Tsu-Min Tsai²¹NTT Medical Center Tokyo, Shinagawa, Japan²Christine M. Kleinert Institute for Hand and Microsurgery, Louisville, KY, USA**Correspondence**Tsu-Min Tsai, Christine M. Kleinert Institute for Hand and Microsurgery, 225 Abraham Flexner Way, Louisville, KY 40202, USA.
Email: ttsai@kleinertkutz.com**Abstract**

We present two rare microsurgical reconstructions. A case with phocomelia was treated with lengthening of soft tissues following vascularized fibula grafting with epiphysis, and a case with cleft hand was reconstructed with spare-part toe transfer.

KEYWORDS

cleft hand, limb lengthening, phocomelia, toe transfer using spare parts, vascularized fibular bone graft with epiphyseal transfer

1 | INTRODUCTION

For congenital malformation of upper extremity, the techniques and results of reconstruction have been published. We present two rare microsurgical reconstructions performed by the senior author (TMT).

The first case had partial phocomelia. Phocomelia is an exceedingly rare anomaly with intercalary segmental deficiency,¹ which is idiopathic or caused by thalidomide. It can be classified into three types proposed by Frantz and O'Rahilly.² In type I, complete phocomelia, hand is attached directly to trunk. In type II, proximal phocomelia, the forearm and hand are attached to trunk. In type III, distal phocomelia, hand is attached to arm.² We applied limb lengthening following vascularized fibular bone grafting, which was preliminarily reported earlier.³

The second case had a cleft hand. Cleft hand has two main types, typical and atypical.^{4,5} Typical cleft hand involves bilateral hands and inherits, while atypical occurs unilaterally and sporadically.⁶ Atypical type has minimal tendon and dysplastic bone formation. Ogino proposed 5 types of cleft hand from type 0 (no digit defect) to type 4 (four digits defect).⁷ Type 4 typically lacks radial four digits. We performed toe-to-hand transfer using aberrant portion.

2 | CASE PRESENTATION

2.1 | Case 1

A 2-year-old boy was born with isolated idiopathic Franz type 2 phocomelia on right upper extremity (Figure 1A). He was healthy without any other abnormalities. There was no history of mother having taken any medications during pregnancy. He had a sensate hand at shoulder level, which was consisted of a thumb and three fingers. He was unable to place the hand neither toward nor away from the trunk. The right shoulder was flail. The radiograph showed a single bone in the arm, which was consistent with ulna by its proximal configuration. An arteriogram indicated arterial patency to all digits, primarily through the ulnar artery. The donor leg had patent femoral, peroneal, tibial arteries, and inferior genicular artery which supplies proximal fibular epiphysis.

We planned two separate stages of reconstruction consisted of elongation of soft tissues in the upper arm following fibular bone grafting. The first surgery was application of an external fixator for distraction between scapula and the ulna. Postoperatively, elongation with external fixator was started by 1 mm per day. Ten weeks later, the elongated space was enough to fill with fibula (Figure 1B) and the second surgery

FIGURE 1 Case 1. A, Preoperative clinical photograph demonstrating 2-y-old boy born with isolated proximal-type phocomelia on right upper extremity. B, Radiographic images showing elongated soft tissue between scapula and ulna under the external fixator. C, Intraoperative photograph showing raised osteocutaneous graft with fibular epiphysis

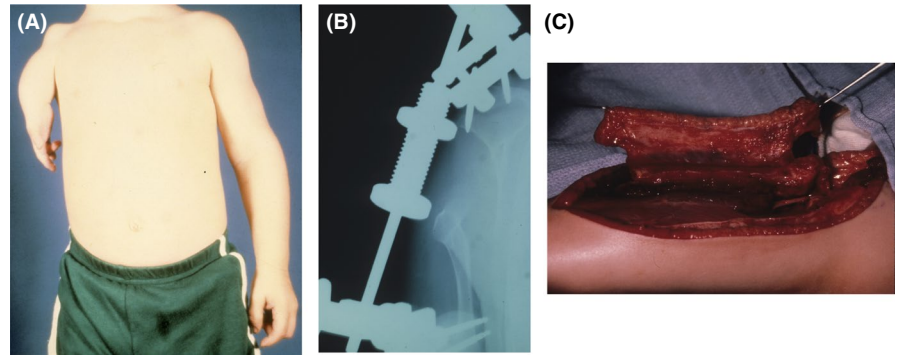
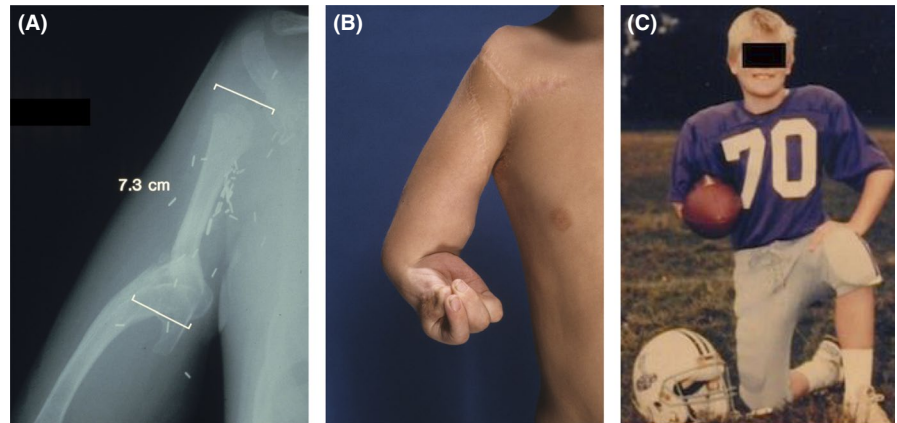


FIGURE 2 Case 1. Postoperative images. A, Radiologic image at 2-y follow-up showing growing humerus up to 7.3 cm. B, Clinical photograph demonstrating gripping with tenodesis effect at 7 y postoperatively. C, Patient was able to play football using the reconstructed arm and hand



was performed. After removal of the device, terminal part of the brachial plexus was identified along with the brachial vessels. Then fibula was dissected proximally until it met the head. Inferior genicular artery and peroneal artery were identified, which supplies metaphysis and endosteum.³ The proximal fibular bone was cut attached with an island monitoring flap. (Figure 1C) The vessels were then divided with pedicle. Then, the lateral collateral ligament was reconstructed to preserve the knee joint stability. Both peroneal and inferior genicular arteries were anastomosed with 9-0 nylon sutures to a 5-cm Y-shaped vein graft. Then, the vein graft was connected end-to-side to the brachial artery. Two venous pedicles coursing along the fibula were anastomosed to brachial veins. Good perfusion was observed in the endosteal tissue, surrounding muscle, and monitoring skin. Then, capsule of the glenohumeral joint was opened in order to fill with the fibular head. After stabilizing fibula and scapula with a K-wire, the capsule of the shoulder joint was anchored to the periosteum of the fibula with nonabsorbable sutures. The deltoid and pectoralis major muscles were then secured to the periosteum and muscle on the proximal end of the fibula graft. Following dissection of the ulnar nerve, the graft was transfixed with a K-wire to the ulna.

Hydrocodone-acetaminophen was taken as needed for acute postoperative pain. There was no major postprocedure complication. Two years after the reconstructive surgery, the epiphysis remained open and the bone was growing at a rate

of 1.3 cm per year up to 7.3 cm. (Figure 2A) At 7-year follow-up, the total longitudinal growth was 4.0 cm. The patient could grip the hand in coordination with wrist flexion. (Figure 2B) Sensation was maintained over all surfaces of the upper extremity. Active range of motion of the reconstructed shoulder joint was 70 degrees in flexion, 50 degrees in extension, and 40 degrees in abduction with smooth articulation. The shoulder stability, arm length, and hand utilization away from the trunk improved total efficiency and appearance of the upper extremity. (Figure 2C).

2.2 | Case 2

A 3-year-old girl had deformities and ectrodactyly in four limbs at birth. No related etiological factor could be identified. Her growth and development were normal. Her left hand lacked four ulnar digits except the thumb, which could be classified as atypical, Ogino type 4 but an uncommon form with defective ulnar four digits. (Figure 3A) Her left lower limb consisted of small pendent Y-shaped foot with two deformed rudimentary toes. (Figure 3B) Below-knee amputation on the right lower extremity had been performed at a local hospital to allow fitting of prostheses. Prior to left lower extremity disarticulation, she was referred for the possibility of toe-to-hand transfer using the foot portion. Radiography demonstrated a single triphalangeal thumb ray and rudimentary foot

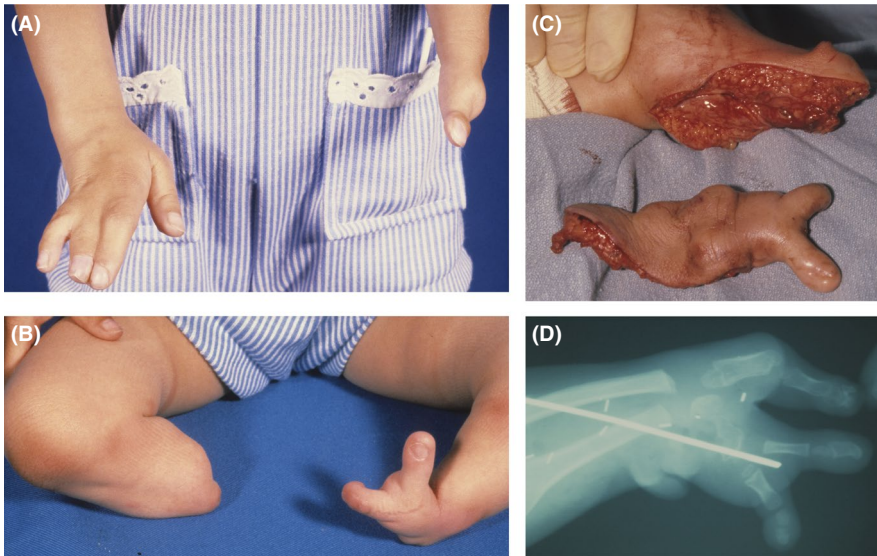


FIGURE 3 Case 2. A, One-ray thumb in left hand. B, Left lower limb consisting of Y-shaped foot with two rudimentary toes. Right leg had already below-knee amputation done. C, The dissected hand along with resected foot remnant. D, The composite graft affixed on the hand with K-wire

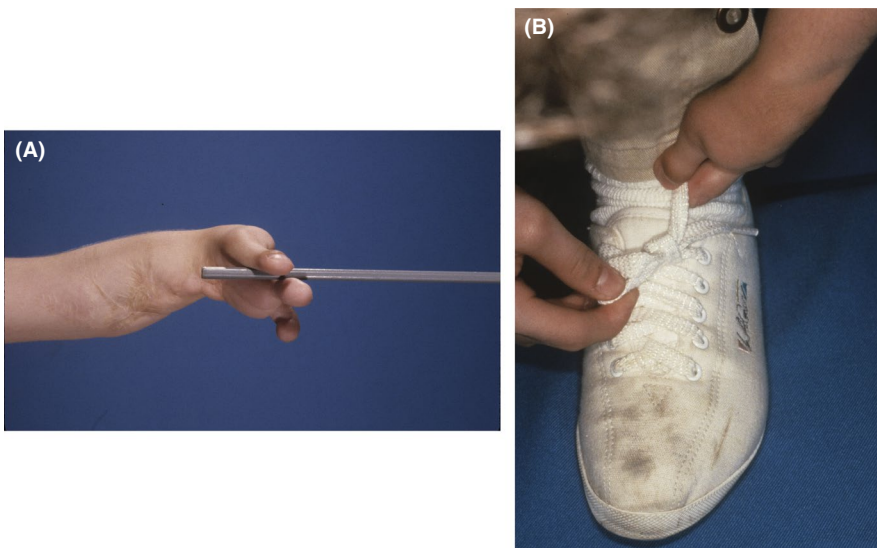


FIGURE 4 Case 2. 7 y after the reconstructive surgery. A, The digits have tactile sensation, and pinch strength is enough to hold objects. B, The patient can tie shoelaces independently

with coalition of tarsal bones. Arteriograms ascertained posterior tibial artery feeding the toes. All major arteries were patent including the radial, ulnar, iliac, and femoral arteries.

She underwent simultaneous toe-to-hand transfer. The procedure began with exploring volar side of the hand. The ulnar and median nerves, flexor pollicis longus and abductor pollicis longus tendons, a common flexor muscle, and three dorsal extensor muscles were identified. Subsequently, the foot remnant was dissected and resected. (Figure 3C) It did not have any tendons suitable for transfer. To acquire the motion of foot transplant, fascial strip grafts from the fascia lata were sutured to the periosteum of distal phalangeal bones of the toes. The composite graft was affixed on the hand with a K-wire between the metatarsal bone and distal radius. (Figure 3D) The artery was anastomosed to radial artery with 10-0 nylon using interpositional vein graft. Concurrently, two concomitant veins were anastomosed to subcutaneous veins

in the hand. Nerve connection between the ulnar nerve and posterior tibial nerve was performed with 8-0 nylon, sparing rigid median nerve.

Postoperative course was uneventful for both extremities. She had been on occupational therapy at the local hospital. At 15 months postoperative visit, the transferred digits served as a stable and sensible post and demonstrated scissoring with the thumb. Approximately 2 years after the reconstruction, a revision surgery was performed including fusion of the intermetacarpal joint and web space release with z-plasty. Seven years after the surgery, two-point discrimination test displayed 6 mm in the thumb and 8 mm in the reconstructed digits. No growth discrepancy between them was noted. The web span was adequate for grasping medium-sized objects such as pen, cup with handle. (Figure 4A) The patient was able to perform most of self-care activities independently such as tying shoelaces. (Figure 4B).

TABLE 1 Previously reported spare-part toe-to-hand transfer for congenital malformations

Author	Year	Age	Sex	Transferred part	Laterality	Complications	Treatment for complications
O'Brien ²⁶	1978	5	Female	Anomalous great toe of cleft foot	Unilateral	None	
May ¹⁴	1981	9	Male	Anomalous great toe of cleft feet	Bilateral	Delayed healing of the feet	Closed spontaneously
Meals ²⁷	1983	10	Male	Anomalous great toe	Unilateral	Minor skin slough	No description
Haranishi ²⁸	1994	4	Female	Excess great toe	Unilateral	None	
Chang ²⁹	2002	4	Male	Anomalous great toe of cleft foot	Unilateral	Arterial thrombosis	Reverse saphenous vein graft
		9	Male	Great toes of malformed feet	Bilateral	None	

3 | DISCUSSION

In the management of upper extremity shortening in children, forearm lengthening by distraction osteogenesis has been reported.⁸⁻¹¹ One article about humeral lengthening in phocomelia has been published by Seitz et al.¹² They lengthened humerus remnant for a 3-year-old four-limb phocomelia patient with the technique of callotasis. The lengthening with frame device resulted in poor bone regeneration, and 13-cm bone graft was required. It was also complicated with pin tract infection.

Instead of distraction osteogenesis, we applied soft tissue lengthening following vascularized fibular bone graft with epiphysis. The reason was that it provides a vascularized bone with growth potential and does not require a long period to wait for osteogenesis under external fixation. This is especially important for pediatric patients. Potential drawbacks are demand for relatively complex technique for vascularized bone grafting, sacrificing normal fibula and possible growth arrest of transferred epiphysis. Nevertheless, the limb growth in Case 1 maintained in the recipient site and acquired appropriate length.

Toe-to-hand transfer has been an accepted technique for congenital malformations.¹³⁻²⁵ However, most cases were grafted normal toe. Some children have combined upper and lower extremity deformities. The patients enjoyed improved overall function and appearance by transferred composite tissue which was otherwise being discarded.^{14,26-29} No major complication was reported in the spare-part transfer. (Table 1) However, anatomic variations would make these operations challenging. To make a precise decision based on the anomalies, sufficient preoperative tests are required. The surgery may require flexibility and creativity, and the surgeon should be prepared with backup options.

Children with upper extremity differences would be referred to pediatric orthopedic surgeons in large centers. Communication between the orthopedic surgeon and hand surgeon is the first key factor for success. For the complex

cases, staged reconstructions and multiple revisions may be necessary and the family should be notified. Excellent clinical results with minimal postoperative complications could be achieved by appropriate education of the patient and family, careful supervision of therapy, and close monitoring by the surgeon.

CONFLICT OF INTEREST

None declared.

AUTHOR CONTRIBUTIONS

KT: prepared manuscript. TMT: guided the author in writing the manuscript and proofread the final manuscript.

ORCID

Koji Takamoto  <https://orcid.org/0000-0002-3031-3361>

REFERENCES

- Goldfarb CA, Manske PR, Busa R, Mills J, Carter P, Ezaki M. Upper-extremity phocomelia reexamined: a longitudinal dysplasia. *J Bone Joint Surg Am.* 2005;87(12):2639-2648.
- Frantz CH, O'Rahilly R. Congenital skeletal limb deficiencies. *J Bone Joint Surg Am.* 1961;43(8):1202-1224.
- Tsai TM, Ludwig L, Tonkin M. Vascularized fibular epiphyseal transfer: a clinical study. *Clin Orthop.* 1986;210:228-234.
- Barsky AJ. Cleft hand: classification, incidence, and treatment. Review of the literature and report of nineteen cases. *J Bone Joint Surg Am.* 1964;46:1707-1720.
- Kozin SH. Upper-extremity congenital anomalies. *J Bone Joint Surg Am.* 2003;85(8):1564-1576.
- Miura T, Suzuki M. Clinical differences between typical and atypical cleft hand. *J Hand Surg Br.* 1984;9:311-315.
- Ogino T. Cleft hand. *Hand Clin.* 1990;6(4):661-671.
- De Bastini G, Aldegheri R, Renzi Brivio L, Trivella G. Limb lengthening by callus distraction (Callotasis). *J Ped Ortho.* 1987;7(2):129-134.
- Cheng JC. Distraction lengthening of the forearm. *J Hand Surg Br.* 1991;16:441-445.
- Abe M, Shirai H, Okamoto M, Onomura T. Lengthening of the forearm by callus distraction. *J Hand Surg.* 1996;21B:151-163.

11. Hill RA, Ibrahim T, Mann HA, Siapkara A. Forearm lengthening by distraction osteogenesis in children: a report of 22 cases. *J Bone Joint Surg Br.* 2011;93:1550-1555.
12. Seitz WH, Froimson AI. Callotaxis lengthening in the upper extremity: indications, techniques, and pitfalls. *J Hand Surg.* 1991;16A:932-939.
13. Yoshimura M. Toe-to-hand transfer. *Plast Reconstr Surg.* 1980;66(1):74-84.
14. May JW, Smith RJ, Peimer CA. Toe-to-hand free tissue transfer for thumb construction with multiple digit aplasia. *Plast Reconstr Surg.* 1981;67:205-213.
15. Gilbert A. Toe transfers for congenital hand defects. *J Hand Surg Am.* 1982;7(2):118-124.
16. Gilbert A. Reconstruction of congenital hand defects with microvascular toe transfers. *Hand Clin.* 1985;1:351-360.
17. Lister GD. Microsurgical transfer of the second toe for congenital deficiency of the thumb. *Plast Reconstr Surg.* 1988;82:658-665.
18. Buck-Gramcko D. Progress in the treatment of congenital malformations of the hand. *World J Surg.* 1990;14:715-724.
19. Eaton CJ, Lister GD. Toe transfer for congenital hand defects. *Microsurg.* 1991;12(3):186-195.
20. Radocha RF, Netscher D, Kleinert HE. Toe phalangeal grafts in congenital hand anomalies. *J Hand Surg Am.* 1993;18(5):833-841.
21. Shvedovchenko IV. Toe-to-hand transfers in children. *Ann Plast Surg.* 1993;31(3):251-254.
22. Vilkki SK. Advances in microsurgical reconstruction of the congenitally adactylos hand. *Clin Orthop Relat Res.* 1995;314:45-58.
23. Kay S, McGuiness C. Microsurgical reconstruction in abnormalities of children's hands. *Hand Clin.* 1999;1999(15):563-583.
24. Van Holder C, Giele H, Gilbert A. Double second toe transfer in congenital hand anomalies. *J Hand Surg Br.* 1999;24(4):471-475.
25. Foucher G, Medina J, Navarro R, Nagel D. Toe transfer in congenital hand malformations. *J Reconstr Microsurg.* 2001;17(1):1-7.
26. O'Brien BM, Black MJM, Morrison WA, MacLeod AM. Microvascular great toe transfer for congenital absence of the thumb. *Hand.* 1978;10:113-124.
27. Meals RA, Lesavoy MA. Hallux-to-hand transfer during ankle disarticulation for multiple limb anomalies. *JAMA.* 1983;249:72-73.
28. Harashina T, Inoue T, Fujino T, Uchinishi K, Itoh Y. Reconstruction of a floating thumb with an excess big toe. *J Reconstr Microsurg.* 1994;10(1):11-15.
29. Chang J, Jones NF. Simultaneous toe-to-hand transfer and lower extremity amputations for severe upper and lower limb defects: the use of spare parts. *J Hand Surg Br.* 2002;27(3):219-223.

How to cite this article: Takamoto K, Tsai T-M. Microsurgical reconstruction of congenital upper extremity deformities of malformations. *Clin Case Rep.* 2020;8:612–616. <https://doi.org/10.1002/ccr3.2635>