

Generalized megaesophagus associated with Schmidt-like syndrome in a dog

Reza Azargoun^{1*}, Seyed Mohammad Hashemi-Asl², Siamak Asri-Rezaei¹

¹ Department of Internal Medicine and Clinical Pathology, Faculty of Veterinary Medicine, Urmia University, Urmia, Iran; ² Department of Surgery and Diagnostic Imaging, Faculty of Veterinary Medicine, Urmia University, Urmia, Iran.

Article Info	Abstract
Article history: Received: 20 September 2023 Accepted: 08 January 2024 Available online: 15 April 2024	A 2-year-old intact male Asian Shepherd dog was referred with a history of chronic regurgitation along with normal appetite and diagnosis of megaesophagus on plain radiography. Clinical examination revealed normothermia, normocardia, normopnea, low body condition score and poor hair coat. The most important laboratory findings include anemia, azotemia, hyperlipidemia, increased thyroid stimulating hormone, decreased thyroxine and hypocortisolemia, as well as a marked increase in acetylcholine receptor antibody concentration. Based on the results, in addition to primary hypothyroidism and primary hypoadrenocorticism, myasthenia gravis was also diagnosed as an underlying cause of megaesophagus. Following nursing care and preferred treatment of each disease, the megaesophagus was resolved in the next visit. This clinical report describes for the first time, to the authors' knowledge, a dog with a rare type of autoimmune polyglandular syndrome (APS) known in human medicine as a Schmidt's syndrome. We want to emphasize the importance of clinicians' awareness regarding the possibility of APS to identify different diseases caused by it in order to achieve successful treatment.
Keywords: Autoimmune polyglandular syndrome Hypoadrenocorticism Hypothyroidism Myasthenia gravis	

© 2024 Urmia University. All rights reserved.

Introduction

Polyglandular endocrinopathy is a rare immune-mediated syndrome and comprises 2.30% of dogs with endocrine diseases.^{1,2} Contrary to the name of this syndrome, it may include endocrine related or unrelated disorders.³ In medicine, there are four types according to the combination of diseases in each patient.⁴ Autoimmune polyglandular syndrome (APS) type 2, also called Schmidt's syndrome, is defined as a presence of primary hypoadrenocorticism in combination with primary hypothyroidism, being recently reported in a few cases of canine patients.⁵ In humans, other possible concomitant disorders can be type 1 diabetes mellitus, immune-mediated hemolytic anemia, primary hypogonadism, megaesophagus, myasthenia gravis, immune-mediated thrombocytopenia and celiac disease.⁶

Although APS is apparently well-known in human medicine, there is an insufficient knowledge regarding this syndrome in small animal medicine.³ To the authors' knowledge, this is the first report of the concomitant presence of primary hypoadrenocorticism and primary hypothyroidism, as well as myasthenia

gravis, similar to Schmidt's syndrome, in a dog with generalized megaesophagus.

Case Description

An intact 2-year-old male Asian Shepherd dog was referred to the Urmia University Veterinary Teaching Hospital, Urmia, Iran, with the owner's complaint of persistent regurgitations started four months ago. In a patient's history, there was a good appetite and regurgitations were associated with eating. Regular vaccination and anti-parasitic treatment courses were carried out, and the dog was fed a home-made diet. Clinical examination revealed a low body condition score (2; scale: 1-5), poor coat, mild peripheral lymphadenopathy and relatively normal rectal temperature (37.90 °C). Thoracic auscultation, abdominal palpation and neurological examinations were unremarkable. Conscious cervical and thoracic plain radiographic examinations (Mobile Drive AR 30; SMAM, Muggio, Italy) showed an extensive dilated, gas-filled esophagus suggestive of generalized megaesophagus (Fig. 1). There was no indication of simultaneous aspiration pneumonia.

*Correspondence:

Reza Azargoun. DVM, DVSc

Department of Internal Medicine and Clinical Pathology, Faculty of Veterinary Medicine, Urmia University, Urmia, Iran

E-mail: r.azargoun@urmia.ac.ir



This work is licensed under a Creative Commons Attribution-NonCommercial-ShareAlike 4.0 International (CC BY-NC-SA 4.0) which allows users to read, copy, distribute and make derivative works for non-commercial purposes from the material, as long as the author of the original work is cited properly.

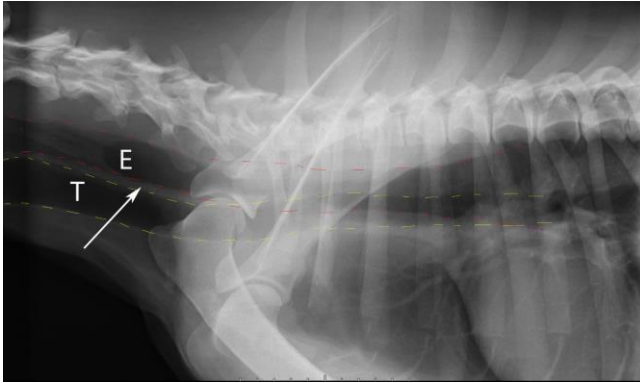


Fig. 1. Right lateral radiograph of the neck and chest of the dog with megaesophagus. The arrow represents a strip sign. E: Esophagus; T: Trachea.

Laboratory tests using automatic hematological analyzer (Celltac Alpha Vet MEK-6550K; Nihon Kohden, Tokyo, Japan) and automatic biochemistry auto-analyzer (BT-1500; Biotecnica Instruments, Roma, Italy) were

performed to determine the cause of megaesophagus (Table 1). The results represented non-regenerative anemia, mild azotemia and hyperlipidemia, as well as typical hormonal changes associated with hypothyroidism. Due to the low level of basal cortisol concentration, the adrenocorticotropic hormone (ACTH) stimulation test, a gold standard for the diagnosis of hypoadrenocorticism, was carried out. Hence, serum cortisol concentration was measured before and 60 min after intravenous administration of tetracosactide (Alborz Darou, Tehran, Iran).⁷ Cortisol concentrations before and after ACTH administration confirmed hypoadrenocorticism (23.00 nmol L⁻¹ and 77.00 nmol L⁻¹, respectively). Surprisingly, an increase in acetylcholine receptor antibody concentration approved the concomitant myasthenia gravis (Table 1). The level of autoantibodies against muscle acetylcholine receptors was determined using immunoprecipitation radioimmunoassay as a gold standard for the diagnosis of myasthenia gravis in humans and dogs.⁸

Table 1. Laboratory parameters before and after medical interventions.

Parameters	Reference range	Pre-treatment values	Post-treatment values
Hematology			
White blood cells ($\times 10^9$ L ⁻¹)	6.00 - 15.00	7.10	10.27
Red blood cells ($\times 10^{12}$ L ⁻¹)	5.00 - 8.50	4.43*	5.31
Hemoglobin (g dL ⁻¹)	12.00 - 18.00	9.20*	13.70
Hematocrit (%)	37.00 - 55.00	27.50*	41.60
Mean corpuscular volume (fL)	60.00 - 80.00	52.80*	58.30*
Mean corpuscular hemoglobin (pg)	19.00 - 26.00	17.70*	20.07
Mean corpuscular hemoglobin concentration (g dL ⁻¹)	31.50 - 37.00	33.40	35.00
Platelets ($\times 10^9$ L ⁻¹)	160 - 500	391.00	395
Lymphocytes ($\times 10^9$ L ⁻¹)	1.00 - 4.80	1.99	3.11
Monocytes ($\times 10^9$ L ⁻¹)	0.00 - 1.30	0.13	0.00
Eosinophils ($\times 10^9$ L ⁻¹)	0.00 - 1.25	0.30	0.00
Neutrophils ($\times 10^9$ L ⁻¹)	3.00 - 11.50	4.68	7.16
Biochemistry			
Total protein (g L ⁻¹)	54.00 - 77.00	75.00	70.00
Sodium (mmol L ⁻¹)	139 - 154	122*	137*
Potassium (mmol L ⁻¹)	3.50 - 6.00	6.50*	4.70
Phosphate (mmol L ⁻¹)	0.80 - 1.60	1.08	1.10
Total calcium (mmol L ⁻¹)	2.00 - 3.00	2.10	2.10
Creatinine (μ mol L ⁻¹)	40.00 - 106	165*	86.00
Urea (mmol L ⁻¹)	2.00 - 9.00	10.30*	8.15
Alkaline phosphatase (U L ⁻¹)	20.00 - 155	79.00	161*
Aspartate aminotransferase (U L ⁻¹)	23.00 - 65.00	44.00	29.00
Alanine aminotransferase (U L ⁻¹)	16.00 - 91.00	24.00	31.00
Bile acids (μ mol L ⁻¹)	< 10.00	2.00	5.50
Triglycerides (mmol L ⁻¹)	0.45 - 1.90	3.50*	2.40*
Cholesterol (mmol L ⁻¹)	3.80 - 7.00	8.80*	7.40*
Glucose (mmol L ⁻¹)	3.00 - 7.00	3.70	4.70
Hormonology			
Thyroxine (μ g dL ⁻¹)	1.52 - 3.60	< 0.10*	1.89
Thyroid stimulating hormone (mIU L ⁻¹)	0.00 - 37.00	51.00*	34.00
Cortisol (nmol L ⁻¹)	28.00 - 250	Basal: 23.00*	Basal: 193
	200 - 400	Post ACTH: 77.00*	-
Immunology			
Acetylcholine receptor antibodies (nmol L ⁻¹)	< 0.60	9.90*	4.30*

* Outside of the reference range. ACTH: Adrenocorticotropic hormone.

According to the paraclinical findings, primary hypoadrenocorticism and primary hypothyroidism along with myasthenia gravis can be the underlying causes of generalized megaesophagus in the presented dog. The owner was instructed to place the dog on a Bailey-like chair, feed the dog in an upright position with a small amount of liquid diet and then, keep the dog in that position for 15 min.^{9,10} Initially, oral prednisolone (0.20 mg kg⁻¹ per day; Aburaihan, Tehran, Iran) and fludrocortisone acetate (0.01 mg kg⁻¹ per day; Aburaihan) were prescribed to treat hypoadrenocorticism.¹¹ Also, oral pyridostigmine bromide (1.00 mg kg⁻¹, q12hr; Alborz Daru) was recommended to improve esophageal function.⁹ The oral administration of levothyroxine (0.02 mg kg⁻¹, q12hr; Iran Hormone, Tehran, Iran) was commenced 10 days subsequent to the initiation of prednisolone administration to preclude the possibility of the Addison crisis induction.¹²

Two months after the initial visit, the owner of the dog stated in a phone call that the animal's general condition had improved significantly and the regurgitation had stopped. However, the dog was again referred to the hospital to adjust the dosage of the drugs used. There was no radiological sign of megaesophagus. Also, laboratory results were markedly changed (Table 1).

Discussion

Dysmotility and concomitant dilation of the esophagus is known as megaesophagus, a prevalent cause of canine regurgitation. It is classified into two categories including congenital megaesophagus and acquired megaesophagus. Congenital form is associated with vagal dysfunction and acquired one can be idiopathic or in association with some diseases such as myasthenia gravis, hypothyroidism, hypoadrenocorticism, neoplasia, dysautonomia and polyradiculoneuritis. Seventy-six percent of megaesophagus cases in dogs are considered idiopathic, and in the remaining cases, myasthenia gravis is the most common cause of the acquired form.¹⁰

It has been proposed that megaesophagus can be caused by immune-mediated endocrinopathy (e.g., hypothyroidism and hypoadrenocorticism) in dogs.³ Possible causes of megaesophagus linked to hypothyroidism can be related to metabolic disorder, myopathy or neuropathy occurring due to the thyroid dysfunction.¹³ In hypoadrenocorticism, cortisol deficiency and electrolyte abnormalities leading to neuromuscular dysfunction can be the possible causes of megaesophagus.^{7,11} However, in both endocrinopathies, megaesophagus is reversible with early detection and supplementation.

It is estimated that hypothyroidism and hypoadrenocorticism are the second most common polyglandular endocrinopathy (20.00% of patients with comorbid

endocrinopathies) following hyperadrenocorticism and diabetes mellitus in the dog population.¹ In this patient, both hypothyroidism and hypoadrenocorticism were diagnosed almost concomitantly, but it was unfeasible to determine which one manifested first. It should be remembered that an autoimmune disease may predispose to other autoimmune processes.¹⁴

Myasthenia gravis is an autoimmune neuromuscular disease being caused by depletion or dysfunction of the post-synaptic nicotinic acetylcholine receptors, as seen in congenital form, or an immune-mediated attack against acetylcholine receptors of skeletal muscle, leading to acquired form. The latter is classified into focal, generalized and acute fulminating types. Megaesophagus is a frequently encountered condition in dogs with acquired myasthenia gravis, owing to the large proportion of skeletal muscle found in the canine esophagus.⁹ The patient, presented here, probably had focal myasthenia gravis, as there were no historical or clinical indications of muscle weakness in the limbs and muscle weakness was diagnosed in only one group of muscles (esophagus).⁸

Acquired myasthenia gravis can be associated with some concomitant diseases such as hypothyroidism and hypoadrenocorticism.⁹ It is strongly hypothesized that the dog reported here was affected by an immune-mediated cause similar to APS, specifically Schmidt's syndrome in humans. However, it was not possible to assess autoantibody levels in our patient to facilitate the identification of an immune-mediated origin. It's worth noting that APS confirmation is not always feasible. For example, Kooistra *et al.* demonstrated no circulating autoantibodies in their Boxer dog; while, Bowen *et al.* documented both thyroid and adrenocortical ones.^{5,15} Nevertheless, polyglandular deficiency syndrome can be diagnosed in our patient due to the presence of two endocrinopathies.^{2,4}

In conclusion, this case report provided the clinical features and therapeutic response of a dog diagnosed with Schmidt-like syndrome. Schmidt's syndrome is a rare condition with an insidious onset that can be a diagnostic challenge for clinicians. We would like to emphasize the significance of careful clinical and paraclinical examinations because the diagnosis of APS is a prerequisite for a successful treatment.

Acknowledgments

We are grateful for the technical assistance of the personnel of Urmia University Veterinary Teaching Hospital, Urmia, Iran.

Conflict of interest

The authors declare no conflict of interest.

References

1. Cartwright JA, Stone J, Rick M, et al. Polyglandular endocrinopathy type II (Schmidt's syndrome) in a Doberman pinscher. *J Small Anim Pract* 2016; 57(9): 491-494.
2. Hwang S-Y, An J-H, Lee J-H, et al. Autoimmune polyendocrine syndrome with hypoadrenocorticism and diabetes mellitus in a dog: a rare case. *J Vet Med Sci* 2021; 7(6): 2120-2123.
3. Blois SL, Dickie E, Kruth SA, et al. Multiple endocrine diseases in dogs: 35 cases (1996-2009). *J Am Vet Med Assoc* 2011; 238(12): 1616-1621.
4. Furukawa S, Meguri N, Koura K, et al. A case of canine polyglandular deficiency syndrome with diabetes mellitus and hypoadrenocorticism. *Vet Sci* 2021; 8(3): 43. doi: 10.3390/vetsci8030043.
5. Pikula J, Pikulova J, Bandouchova H, et al. Schmidt's syndrome in a dog: a case report. *Vet Med (Praha)* 2007; 52(9): 419-422.
6. Greco D. Canine autoimmune polyglandular syndromes. In: Bruyette D (Ed). *Clinical small animal internal medicine*. 1st ed. Hoboken, USA: John Wiley & Sons 2020; 113-116.
7. Kelly D. Reversible megaesophagus in a dog with isolated glucocorticoid-deficient hypoadrenocorticism. *Vet Rec Case Rep* 2020; 8(1): e001055. doi: 10.1136/vetreccr-2019-001055.
8. Khorzad R, Whelan M, Sisson A, et al. Myasthenia gravis in dogs with an emphasis on treatment and critical care management. *J Vet Emerg Crit Care (San Antonio)* 2011; 21(3): 193-208.
9. Hahn T-Y, Kang M-H, Eom K-D, et al. Focal form of acquired myasthenia gravis with megaesophagus in a Yorkshire terrier dog. *Korean J Vet Res* 2014; 54(1): 59-62.
10. Ko GB, Kim J, Choi HI, et al. Improvement of megaesophagus after treatment of concurrent hypothyroidism. *J Vet Clin* 2018; 35(1): 19-21.
11. Van Lanen K, Sande A. Canine hypoadrenocorticism: pathogenesis, diagnosis, and treatment. *Top Companion Anim Med* 2014; 29(4): 88-95.
12. Vanmal B, Martlé V, Binst D, et al. Combined atypical primary hypoadrenocorticism and primary hypothyroidism in a dog. *Vlaams Diergeneesk Tijdschr* 2016; 85(6): 355-364.
13. Kumar KS, Srikala D. Hypothyroid associated megaesophagus in dogs: four years (2009-2013) study in Hyderabad, India. *J Adv Vet Anim Res* 2015; 2(2): 221-224.
14. Abuzneid YS, Yaghi Y, Madia A, et al. First case recognized as autoimmune polyglandular syndrome type 2 with myasthenia gravis in Palestine: a case report and literature review. *Ann Med Surg* 2021; 68: 102575. doi: 10.1016/j.amsu.2021.102575.
15. Kooistra HS, Rijnberk A, van den Ingh TS. Polyglandular deficiency syndrome in a boxer dog: thyroid hormone and glucocorticoid deficiency. *Vet Q* 1995; 17(2): 59-63.