



Surgical staging and resection of malignant pleural mesothelioma

Lawrence B. Brown¹, Frank Corl², Shanda H. Blackmon³

¹Johns Hopkins Medicine, Department of Surgery, Baltimore, MD, USA; ²Mayo Clinic, Department of Media Services, Medical Illustration, Rochester, MN, USA; ³Mayo Clinic, Division of General Thoracic Surgery, Department of Surgery, Rochester, MN, USA

Correspondence to: Shanda H. Blackmon, MD, MPH. Professor of Surgery, Mayo Clinic, 200 1st Street, MA-12W, Rochester, MN 55905, USA. Email: blackmon.shanda@mayo.edu.

Submitted Jul 03, 2020. Accepted for publication Oct 28, 2020.

doi: 10.21037/jtd-19-2267

View this article at: <http://dx.doi.org/10.21037/jtd-19-2267>

Introduction

Mesothelioma is a malignancy of mesothelial cells, which line the pleura, peritoneum, pericardium, and tunica vaginalis. Malignancy of the pleural lining is most commonly associated with occupational exposure to asbestos (1). Mesothelioma is four times more likely to present in men than in women due to workplace exposures, and the median age of diagnosis is 74. Typically, there is a 20- to 50-year delay between asbestos exposure and the development of mesothelioma (2).

Mesothelioma represents less than 1% of all cancers, but it has a particularly poor prognosis (1). Approximately 3,200 people are diagnosed with mesothelioma every year in the United States (US) (3). Patients often present with wheezing or hoarseness, shortness of breath, a persistent cough, and pain in the chest or back. Many of these patients are diagnosed with advanced disease, and the five-year relative survival rate is 10% (2).

Staging and subtyping are the first and most important steps in determining which treatment is best for an individual patient. An expert pathologist from an experienced medical center should review all relevant tissue biopsies. Evaluation from a needle thoracentesis may not prove to be adequate for staging purposes, as effusion fluid cytology does not allow assessment of invasion (4).

When a patient has a history of significant exposure to asbestos, shipyards, or construction, along with a pleural effusion, the suspicion for mesothelioma should arise. This suspicion will cause the thoracic interventionalist to approach the drainage and evaluation differently than if this were a known other metastatic tumor or benign pleural effusion.

Staging and operative techniques

Proper staging involves a combination of imaging and surgical evaluation. Computed tomography (CT) (*Figure 1A,B*) and positron emission tomography (PET) (*Figure 2A,B*) scans can delineate mediastinal involvement with short axis diameter greater than 1cm or increased FDG activity. Endobronchial ultrasound (EBUS) (*Figure 3A*) or endoscopic ultrasound (EUS) (*Figure 3B*) can often confirm pathology without requiring the patient to undergo a surgical staging mediastinoscopy (5). When metastatic disease is suspected, a needle core biopsy can confirm the presence of mesothelial malignant cells in tissue (6). There are three basic surgical staging procedures that are required to assess a patient's candidacy for surgical intervention and complete staging when no clear imaging indicates they have metastatic disease; mediastinoscopy, laparoscopy, and thoracoscopy.

The three minimally invasive procedures are delineated in this technique illustration. The first technique includes a thoracoscopic biopsy and evaluation of the pleura (*Figure 4*). Once the tissue type is confirmed, the surgeon may desire to proceed with laparoscopic abdominal evaluation (*Figure 5A*) and mediastinoscopy (*Figure 5B*) (5). Performing these procedures in the correct order will allow the patient to avoid unnecessary surgery. Once staging has been performed, the findings should be reviewed with the patient for an open discussion about expectations, findings, and which treatment may be best for them based on their goals of care (*Table 1*). Patients should be educated about disease stage prior to performing irreversible procedures such as talc, resection, or therapy.

The T stage describes the stage characteristics of the

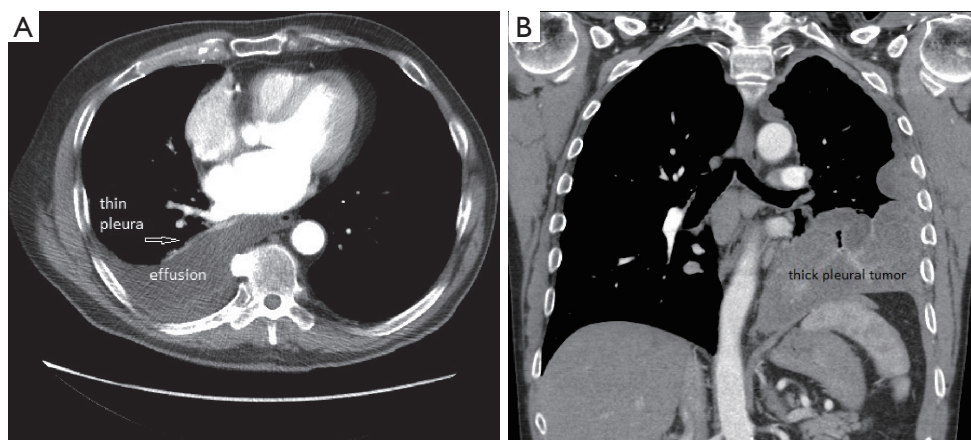


Figure 1 CT imaging of different stages of mesothelioma. (A) CT scan of mesothelioma with minimal pleural involvement and an effusion; (B) CT scan of mesothelioma with extensive pleural and fissural involvement including bulky lymphadenopathy.

tumor. T1 Mesothelioma (*Figure 6*) is limited to the ipsilateral parietal pleura, with or without involvement of the visceral pleura. The tumor may also include the diaphragmatic and mediastinal pleura. T2 Mesothelioma (*Figure 7*) involves the ipsilateral pleura surfaces (parietal, diaphragmatic, mediastinal, and visceral pleura) with at least one of the following: extension into the lung parenchyma, invasion of the diaphragmatic muscle, and/or a confluent visceral pleura tumor (including the fissure). T3 Mesothelioma (*Figure 8*) involves any ipsilateral pleural surfaces, with at least one of the following: extension into mediastinal fat, invasion of the endo-thoracic fascia, non-transmural involvement of the pericardium, and/or a solitary focus of tumor invading the soft tissues of the chest wall. T4 Mesothelioma (*Figure 9*) is characterized by diffuse extension or multifocal masses of tumor in the chest wall, with potential rib destruction. Additionally, the tumor may extend into the contralateral pleura, spine, mediastinal organs, through the internal surface of the pericardium (with or without a pericardial effusion; or tumor involving the myocardium), and/or trans-diaphragmatic into the peritoneum (*Table 2*) (7,8).

The N stage describes the nodal stage. N1 nodal disease is characterized by metastasis in the ipsilateral bronchopulmonary, mediastinal, or hilar lymph nodes. N2 nodal disease spreads to the contralateral mediastinal, subcarinal or ipsilateral paratracheal lymph nodes, or ipsilateral or contralateral supraclavicular nodes (*Figure 10*) (7,8).

The M stage is related to metastasis. M0 demonstrates no distant metastasis and M1 demonstrates that metastasis

is present (*Table 2*) (7,8).

Staging (IA–IV) for malignant pleural mesothelioma (MPM) is related to the patient's TNM characteristics (*Table 3*).

Insertion of a PleurX catheter is safe and effective to provide palliation for recurrent malignant pleural effusions caused by Mesothelioma (*Figure 11*) (9). This tunneled indwelling pleural catheter is inserted percutaneously and allows for intermittent drainage of effusions outside of the hospital setting (10). Alternatively, talc pleurodesis or other pleurodesis technology may be employed to relieve a patient from dyspnea due to recurrent effusions. It is important talc not be instilled until the patient has been evaluated by an expert mesothelioma care team, staged, offered enrollment into clinical research, discussed surgical options with a surgeon expert in the field, and has been given an opportunity to decide what pathway they choose, as placing talc inside the chest of a mesothelioma patient can burn bridges for therapy.

Pleurectomy and decortication (P/D) (*Figure 12*) is one of the two surgical procedures recommended for MPM. It involves thoracotomy, extrapleural dissection of the parietal and visceral pleura, and mediastinal lymph node dissection. Resection of the diaphragm and/or pericardium may be necessary if these structures are invaded (11). P/D (*Figure 13*) may include reconstruction of the diaphragm and pericardium with expanded polytetrafluoroethylene (ePTFE) mesh. ePTFE is an inert polymer of monofilament threads that will integrate completely with the patient in seven months (12). Extrapleural pneumonectomy (EPP) (*Figure 14*) goes a step further than P/D, and involves

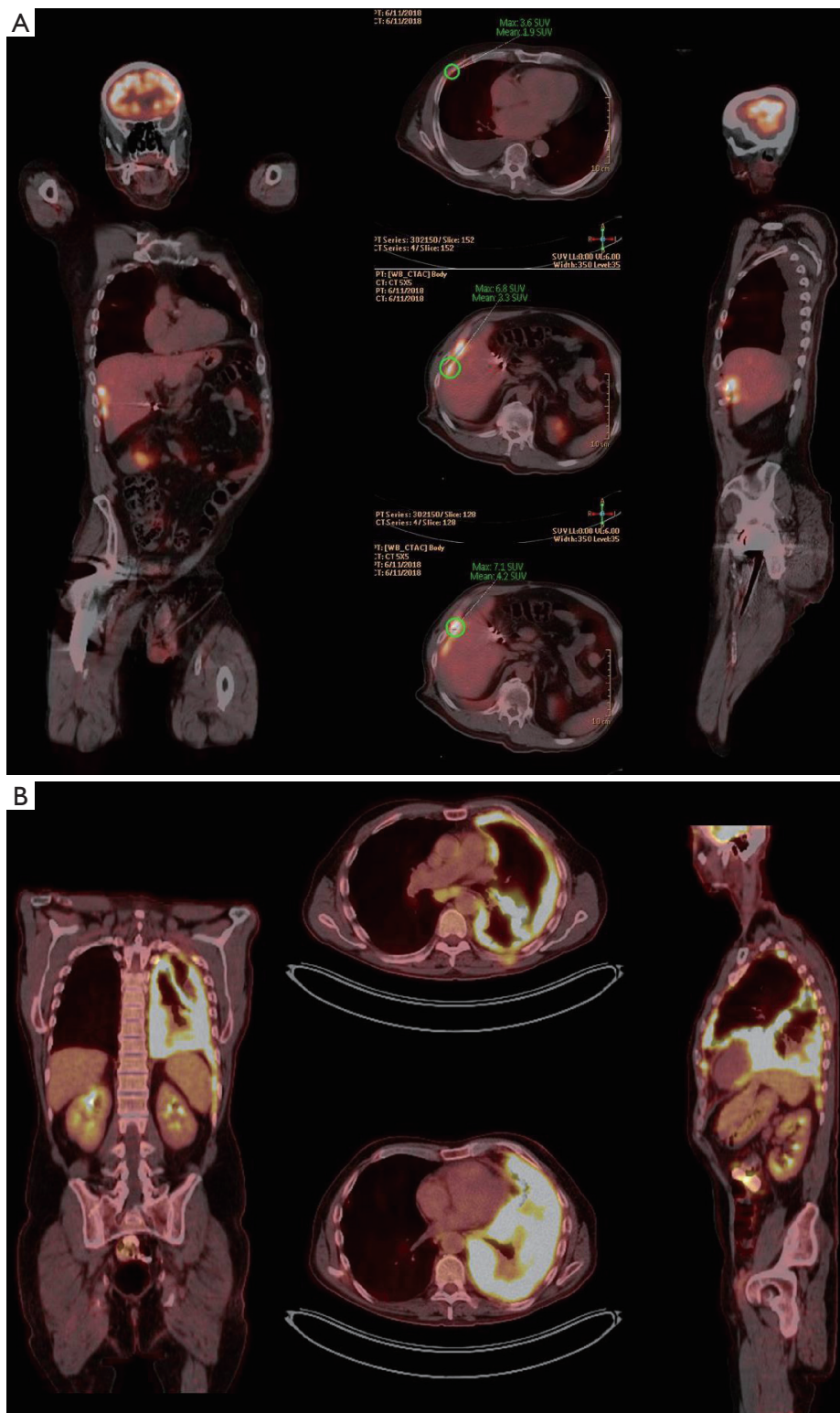


Figure 2 PET imaging of different stages of mesothelioma. (A) PET scan with limited stage mesothelioma; (B) PET scan with mediastinal nodal involvement (two lymph nodes can be seen in the subcarinal region on the top axial CT central image) and extensive pleural disease (FDG avidity represented by bright yellow color).

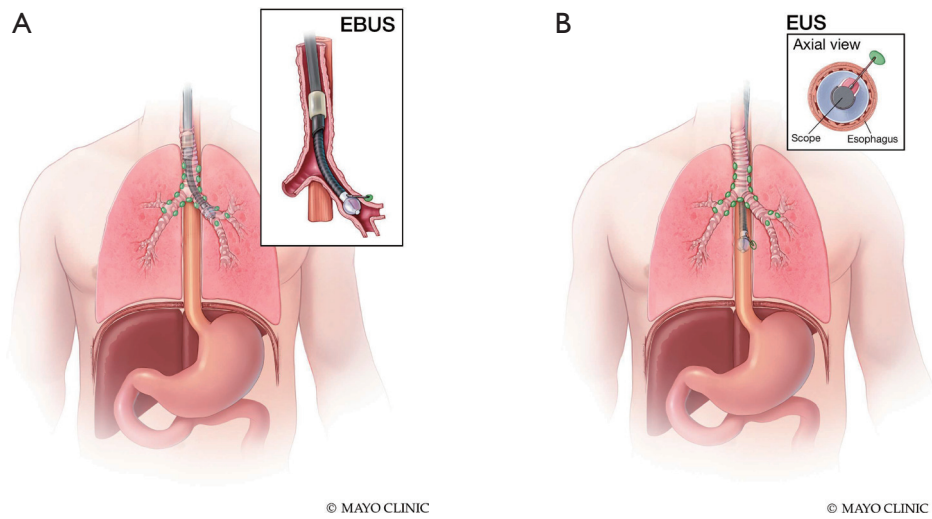


Figure 3 Staging techniques with EBUS and EUS for mesothelioma. (A) EBUS technique to stage the lymph nodes for mesothelioma; (B) EUS technique to stage the lymph nodes for mesothelioma. EBUS, endobronchial ultrasound; EUS, endoscopic ultrasound.

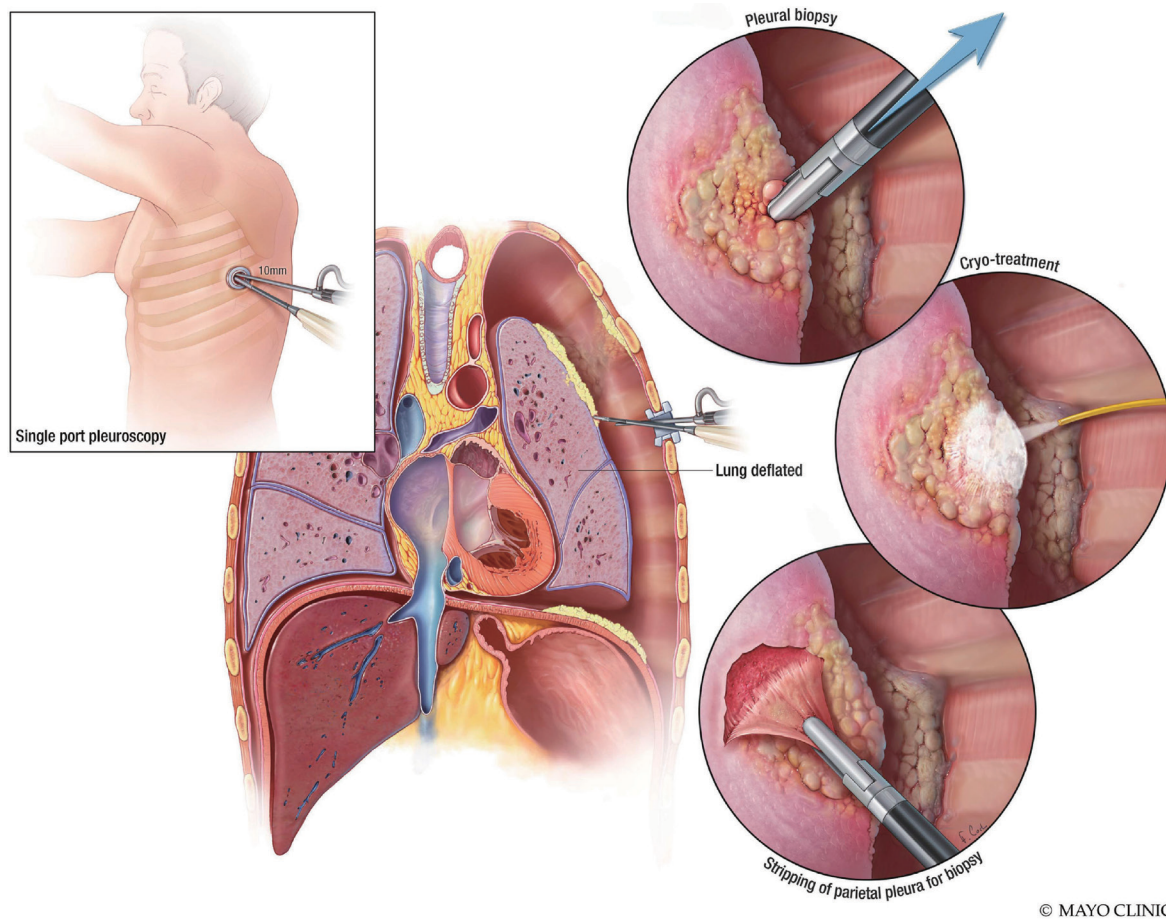
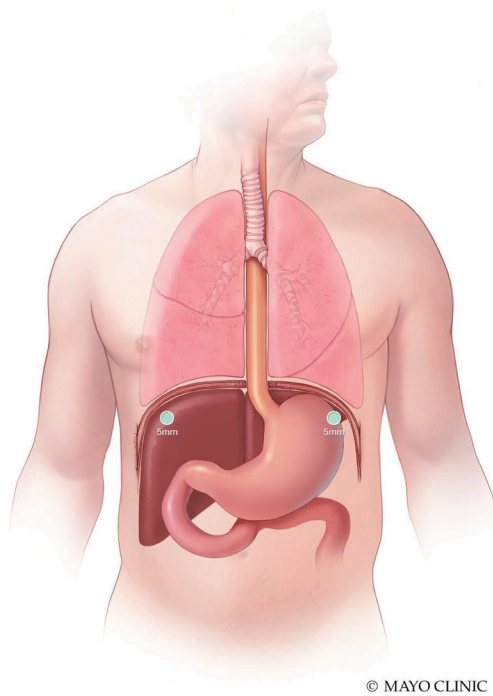
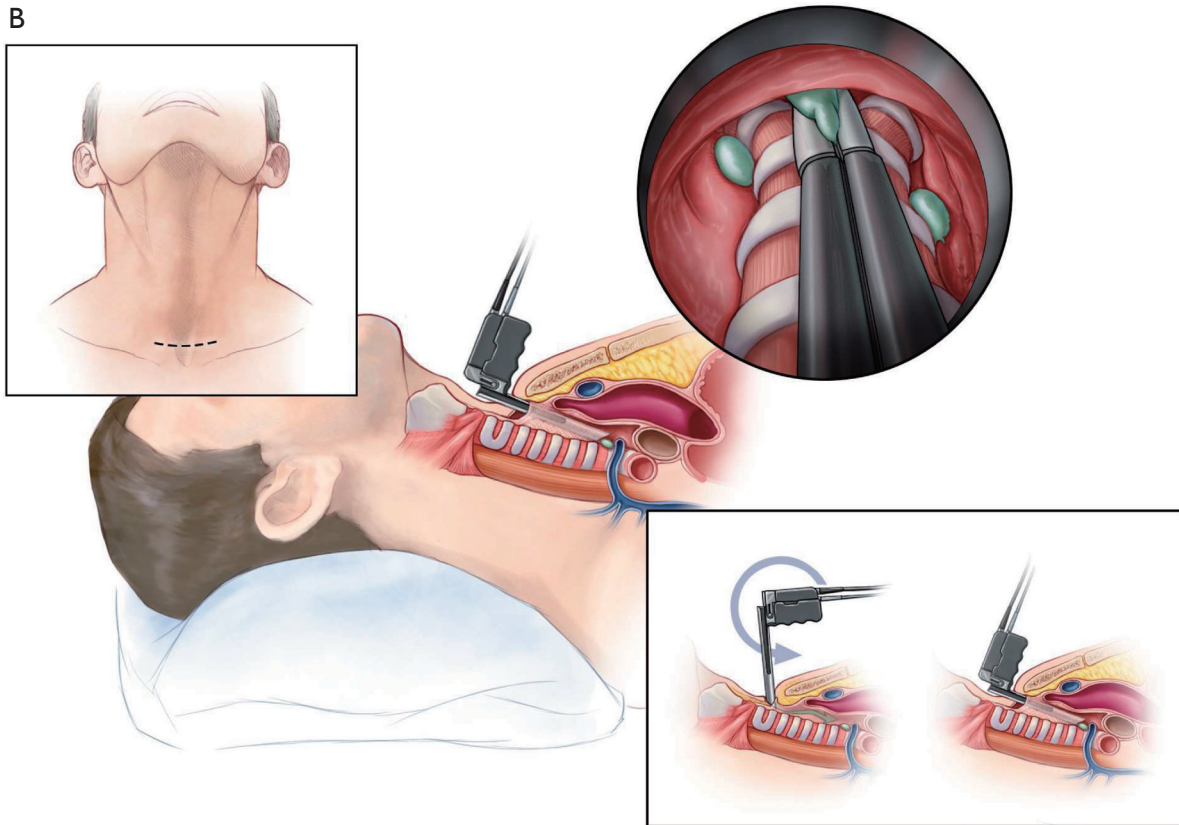


Figure 4 Staging thoracoscopy for mesothelioma; single port pleuroscopy, biopsy, cryotherapy, or pleural sampling. However, parietal pleural biopsy is preferred over visceral pleural biopsy to minimize air leak.

A



B



© MAYO CLINIC

Figure 5 Minimally invasive staging techniques for mesothelioma. (A) Staging laparoscopy; (B) staging mediastinoscopy.

Table 1 How to share staging with the patient as you discuss treatment options

Cancer stage	Organs involved
Stage Ia	This is “localized” cancer; it is limited to one part of the chest wall lining. At this stage, the tumor is isolated to the pleura lining the chest wall. It may also affect the pleura of the diaphragm, the mediastinum or the lungs
Stage Ib	This is “localized” cancer; it is limited to one part of the chest wall lining. At this stage, the tumor is scattered on the pleura lining the chest wall. It may also affect the pleura of the diaphragm, the mediastinum or the lungs
Stage II	At this stage, the tumor may have spread beyond the lining of the chest to the diaphragm or to a lung. It is likely scattered on the pleura lining the chest wall. In addition, the tumor has invaded the following area(s): <ul style="list-style-type: none"> On the surface of the lung In the space between the lobes of the lung (called the fissure) In the lung On the diaphragm
Stage III	At this stage, the tumor may have spread to other structures within the chest and may involve nearby lymph nodes. The tumor is scattered on the pleura lining the chest wall. It may also affect the pleura of the diaphragm, the mediastinum or the lungs. In addition, the tumor has invaded the following area(s): <ul style="list-style-type: none"> In one area of the chest wall In the fat of the center of the chest In the lining around the heart
Stage IV	Stage IV mesothelioma is an advanced cancer that has spread more extensively within the chest. It may have spread to distant areas, such as the brain, liver and lymph nodes elsewhere in the chest <p>At this stage, the tumor is scattered on the pleura lining the chest wall. It may also affect the pleura of the diaphragm, the mediastinum or the lungs. In addition, the tumor has invaded the following area(s):</p> <ul style="list-style-type: none"> Through the chest wall in many locations Into the pleural of the opposite side of the chest Into the organs in the center of the chest Into the abdomen Into the spine

en bloc resection of the lung, pleura, pericardium, and diaphragm (11). For either pleurectomy and decortication or extra-pleural pneumonectomy, the surgeon often has to make a 7th intercostal space incision for thoracotomy, but then enter through the 4–6th intercostal space and 7–9th intercostal space to provide enough access to complete the incision. This is a single incision, double intercostal space thoracotomy. Often, epidural coverage may be difficult. This surgery is often painful and has associated morbidity.

Surgical eligibility and outcomes

The choice of surgical extirpation for MPM should be determined by a multi-disciplinary team, including a surgeon. The role of surgery is for diagnosis, staging, and

macroscopic resection of disease; surgery should be reserved for patients with good performance status and with stage I–III disease. Patients with a sarcomatoid histology (the most aggressive mesothelioma cell type) or stage IV MPM should not undergo a surgical procedure, unless for a palliative reason (13).

P/D should be considered the first choice of treatment for patients with early stage disease (stage I, N0-1). On the other hand, while EPP often has an increased morbidity and mortality when compared to P/D, this technique may permit a more complete resection in those patients identified to have bulky deep fissure involvement (13,14).

Morbidity and mortality are different for EPP, as compared to P/D. Patients who undergo resection of the lung, hemidiaphragm, and ipsilateral pericardium (during

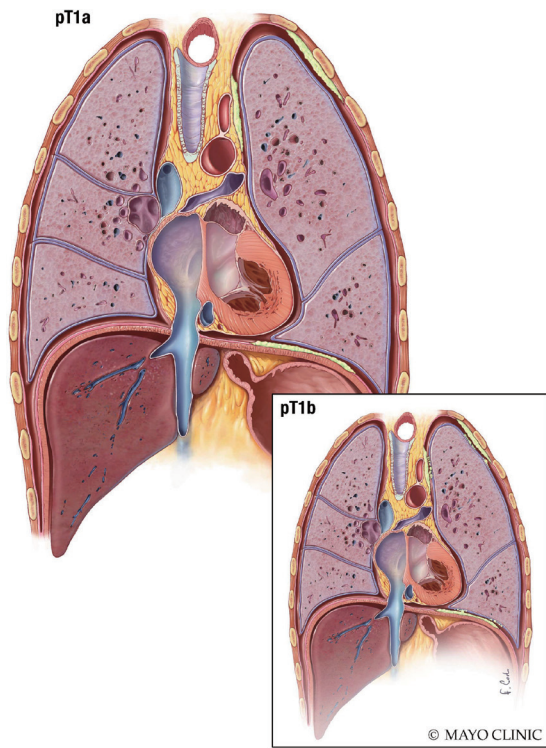


Figure 6 T1 mesothelioma.

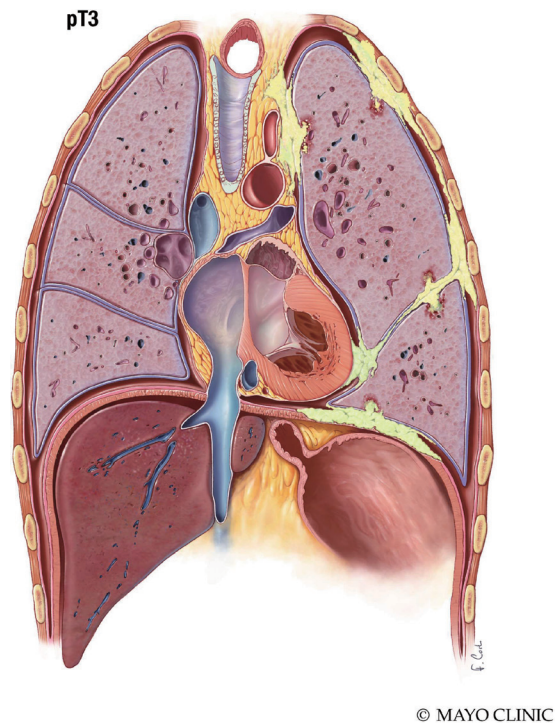


Figure 8 T3 mesothelioma.

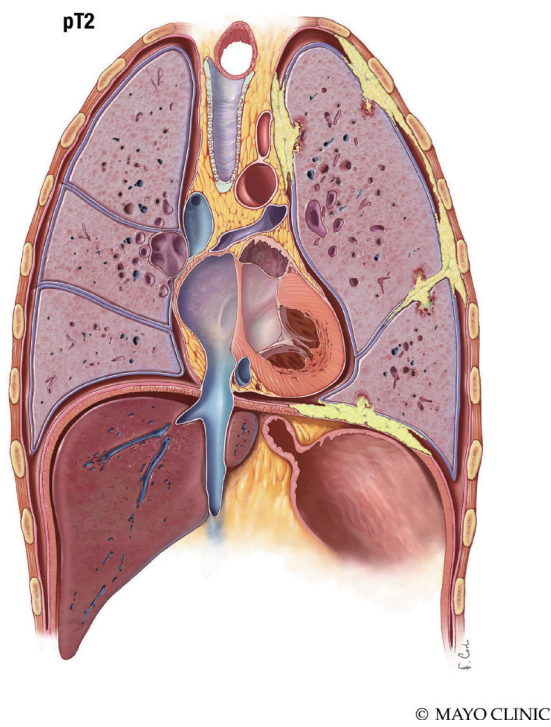


Figure 7 T2 mesothelioma.

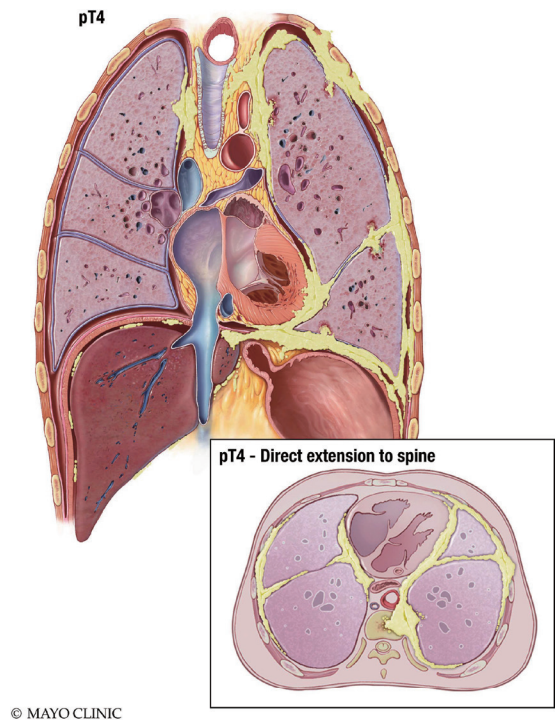


Figure 9 T4 mesothelioma.

Table 2 Malignant pleural mesothelioma staging guidelines

TNM stage	Definition
T	Primary tumor
TX	Primary tumor cannot be assessed
T0	No evidence of primary tumor
T1	Tumor limited to the ipsilateral parietal pleura with or without involvement of: <ol style="list-style-type: none"> 1. Visceral pleura 2. Mediastinal pleura 3. Diaphragmatic pleura
T2	Tumor involving each of the ipsilateral pleural surfaces (parietal, mediastinal, diaphragmatic, and visceral pleura) with at least one of the following features: <ol style="list-style-type: none"> 1. Involvement of the diaphragmatic muscle 2. Extension of tumor from visceral pleura into the underlying pulmonary parenchyma
T3	Locally advanced but potentially resectable tumor. Tumor involving all ipsilateral pleural surfaces (parietal, mediastinal, diaphragmatic, and visceral pleura), with at least one of the following features: <ol style="list-style-type: none"> 1. Involvement of the endo-thoracic fascia, 2. Extension into the mediastinal fat 3. Solitary, completely resectable focus of tumor extending into the soft tissues of the chest wall 4. Non-transmural involvement of the pericardium
T4	Locally advanced technically unresectable tumor. Tumor involving all ipsilateral pleural surfaces (parietal, mediastinal, diaphragmatic, and visceral pleura) with at least one of the following features: <ol style="list-style-type: none"> 1. Diffuse extension or multifocal masses of tumor in the chest wall, with or without associated rib destruction 2. Direct trans-diaphragmatic extension of the tumor to the peritoneum 3. Direct extension of tumor to the contralateral pleura 4. Direct extension of tumor to mediastinal organs 5. Direct extension of tumor into the spine 6. Tumor extending through to the internal surface of the pericardium with or without a pericardial effusion; or tumor involving the myocardium
N	Regional lymph nodes
NX	Regional lymph nodes cannot be assessed
N0	No regional lymph node metastases
N1	Metastases in the ipsilateral bronchopulmonary, hilar, or mediastinal (including the internal mammary, peri-diaphragmatic, pericardial fat pad, or intercostal) lymph nodes
N2	Metastases in the contralateral mediastinal, ipsilateral, or contralateral supraclavicular lymph nodes
M	Distant metastasis
M0	No distant metastasis
M1	Distant metastasis present

Definitions for T, N, M staging as outlined by the 8th edition of the TNM staging system by the International Association for the Study of Lung Cancer/American Joint Committee on Cancer (AJCC). Used with permission of the American College of Surgeons, Chicago, Illinois. The original source for this information is the AJCC Cancer Staging Manual, Eighth Edition (2017) published by Springer International Publishing.

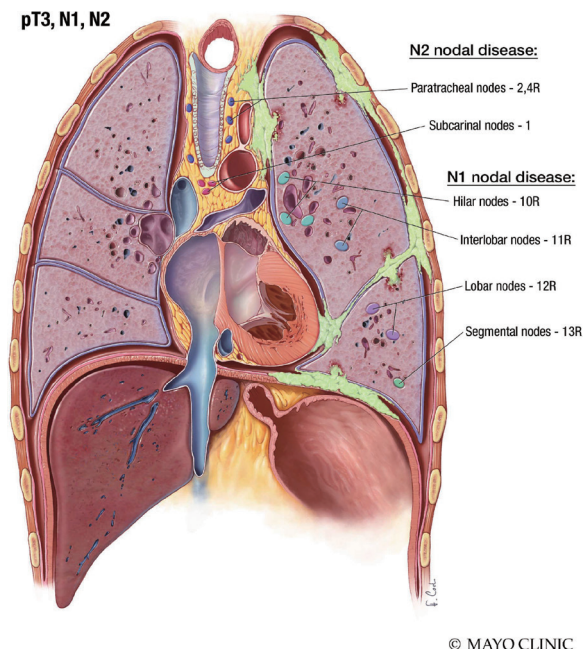


Figure 10 Ipsilateral N1 and N2 nodal disease.

Table 3 Malignant pleural mesothelioma stage grouping related to TNM descriptors

Stage	T	N	M
IA	T1	N0	M0
IB	T2, 3	N0	M0
II	T1, 2	N1	M0
IIIA	T3	N1	M0
IIIB	T1–3	N2	M0
IV	T4	N0–2	M0
	Any T	Any N	M1

Stage groupings related to TNM descriptors as outlined by the 8th edition of the TNM staging system by the International Association for the Study of Lung Cancer/American Joint Committee on Cancer (AJCC). Used with permission of the American College of Surgeons, Chicago, Illinois. The original source for this information is the AJCC Cancer Staging Manual, Eighth Edition (2017) published by Springer International Publishing.

an EPP) may experience additional hemodynamic and cardiorespiratory complications postoperatively. The most common complication following a P/D is a prolonged air leak, associated with trauma to the lung tissue during removal of the pleura (13,14).

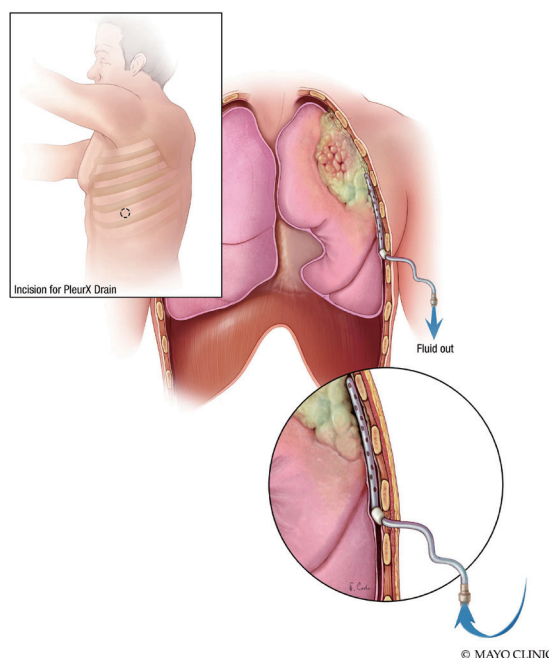


Figure 11 Thorascopic PleurX catheter insertion through the same staging single port site. If surgery is planned, the tunneled pleural catheter should be placed through the same single port site instead of tunneled under the skin. This should be done with the intent to later resect the tract. If, however, a tunneled pleural catheter is being placed for long-term management in the palliative setting, the cuff should be placed just underneath the skin and the device should have a long-tunneled tract to the pleura.

Mortality in EPP usually results from bronchopleural fistula (leading to sepsis and multiorgan failure) and pulmonary embolism. However, in P/D mortality was usually the result of atelectasis, pneumonia, air leak, localized infection, pulmonary embolism, and empyema. While P/D may have a lower perioperative morbidity and mortality, long-term cure among those surviving may be slightly lower when compared to survivors of EPP (13,14).

Patients who undergo EPP should be able to tolerate a pneumonectomy and should have a pre-operative testing to determine their predicted postoperative forced expired volume in the first second of expiration (FEV₁) and diffusing capacity of the lung for carbon monoxide (DLCO). Patients with predicted post-operative values greater than 40% are considered candidates for pneumonectomy. However, pre-operative values between 30–60% of predicted required further work-up prior to surgery, and less than 30% post-operative values are considered to be high-risk

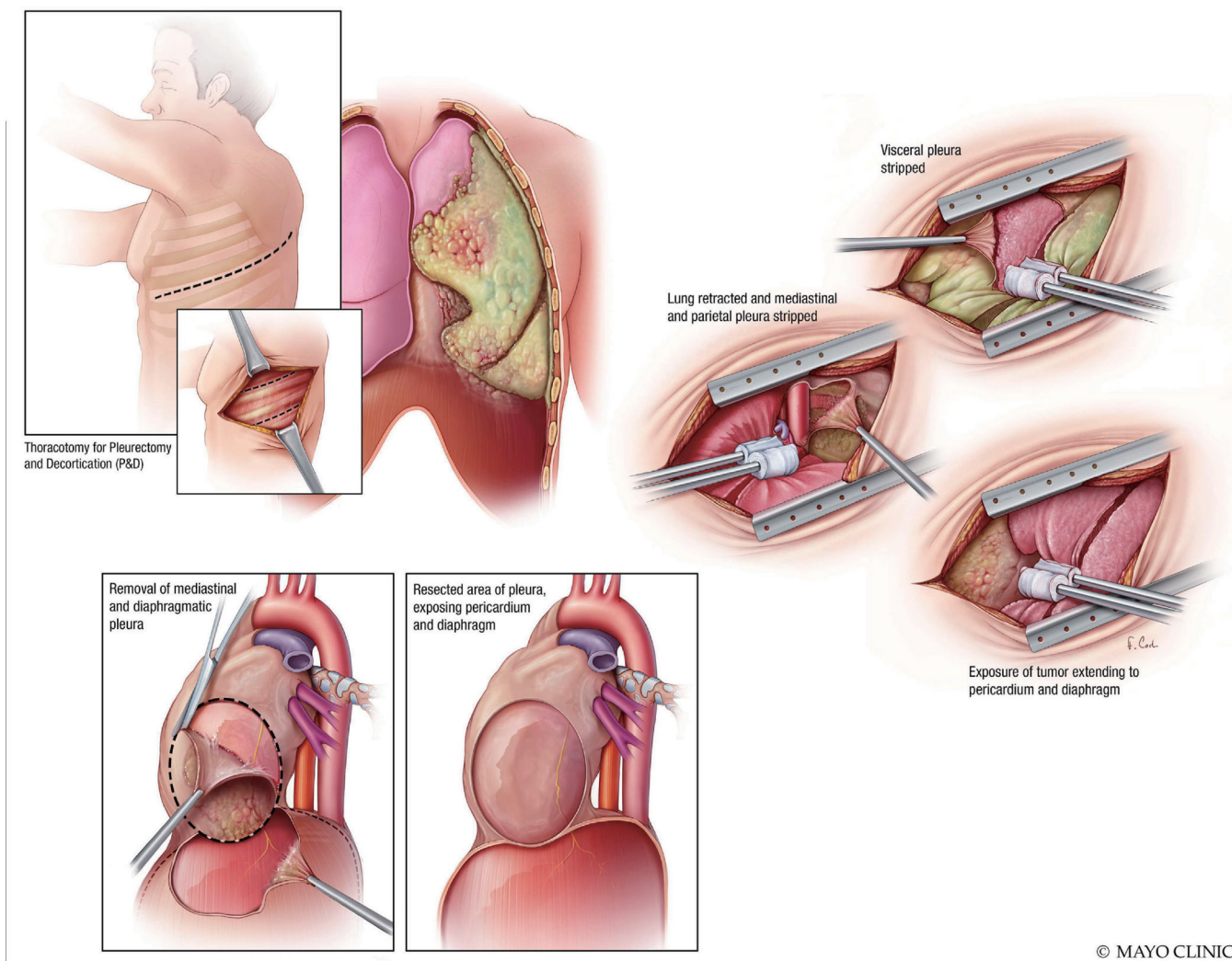


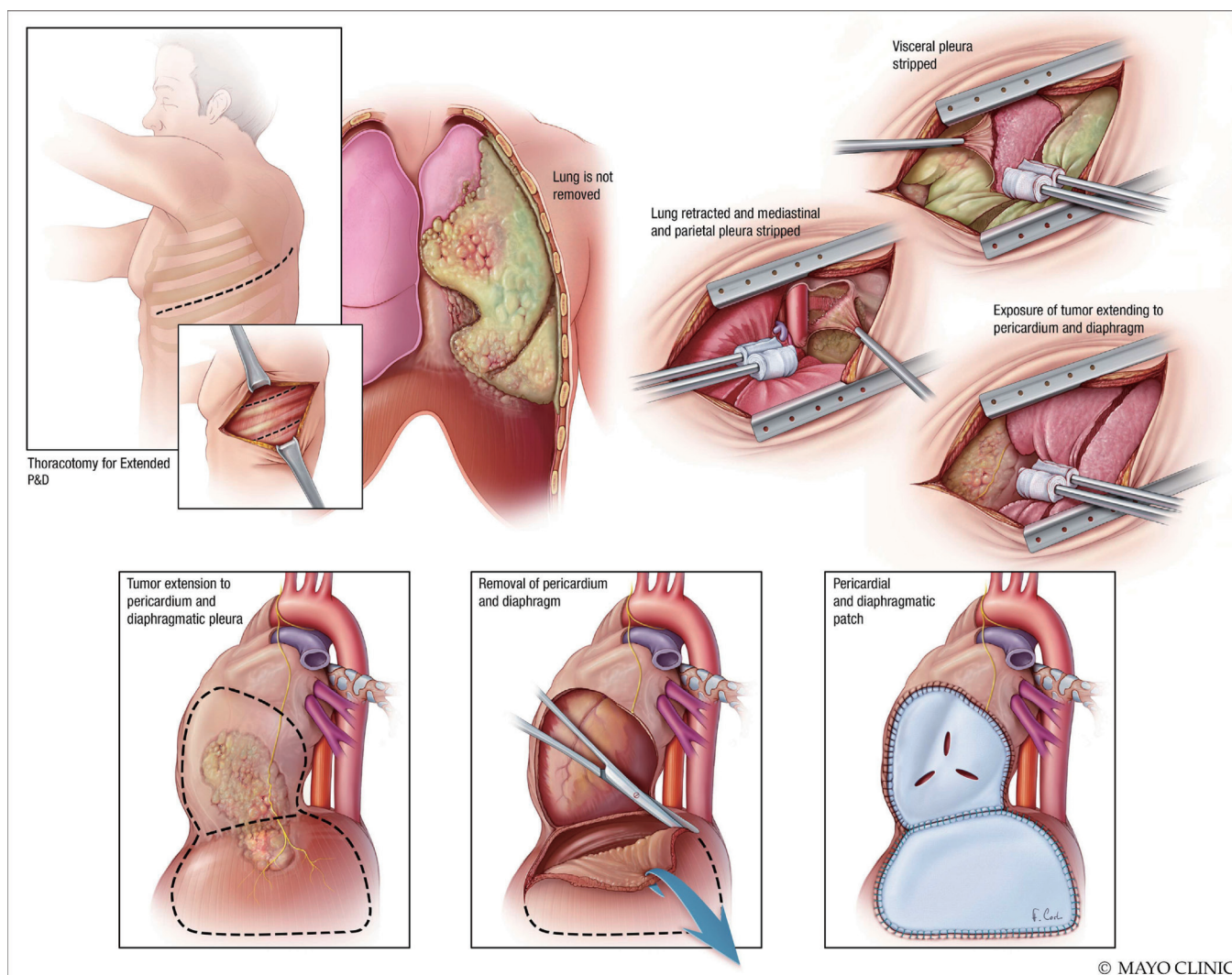
Figure 12 Pleurectomy and decortication. The diseased lung is not resected, but the entire surface of the lung visceral surface as well as the parietal pleural surface of the chest wall, pericardium, and diaphragm is resected. This resection cannot be performed where full thickness involvement or invasion of structures is noted. Although the pleural surfaces of the pericardium and diaphragm are resected, the muscle of the diaphragm is preserved and not reconstructed. In the image at the top left, a single incision thoracotomy is made, but the intercostal incisions may require two interspaces to be opened for adequate exposure.

candidates (15).

Most patients are not cured of their disease after resection, although there are some patients who may experience long-term survival or cure. However, the combination of therapies (both surgical and nonsurgical) are typically administered with curative intent (13,14). We recommend that eligible patients are enrolled into clinical trials in an effort to prospectively answer questions and improve care in such a rare disease.

Adjunctive surgical therapy

Other therapies like cryotherapy, heated intrapleural chemotherapy, photodynamic therapy, or intraoperative radiation can be employed in conjunction with surgical resection (16,17). However, the addition of neoadjuvant or adjuvant chemotherapy and radiation in sequence with surgery is typically made in a multi-disciplinary tumor board after complete staging is performed.



© MAYO CLINIC

Figure 13 Extended pleurectomy and decortication with ePTFE reconstruction. Just as in the case above, the lung parenchyma is preserved, but the lining is removed. The phrenic nerve, diaphragm, pericardium, as well as the visceral and parietal pleural surfaces, are completely removed. Thus, the pericardium and diaphragm have to be reconstructed. In selected cases, the pericardium may not have to be reconstructed, but in all cases of full-thickness diaphragm resection, it must be reconstructed—typically with Gore-Tex™ ePTFE mesh (W.L. Gore & Associates, Flagstaff, AZ). In cases of pericardial reconstruction, small drainage holes should be placed in the mesh to prevent cardiac tamponade if a pericardial effusion persists. This will allow drainage and decompression into the pleural space. ePTFE, expanded polytetrafluoroethylene.

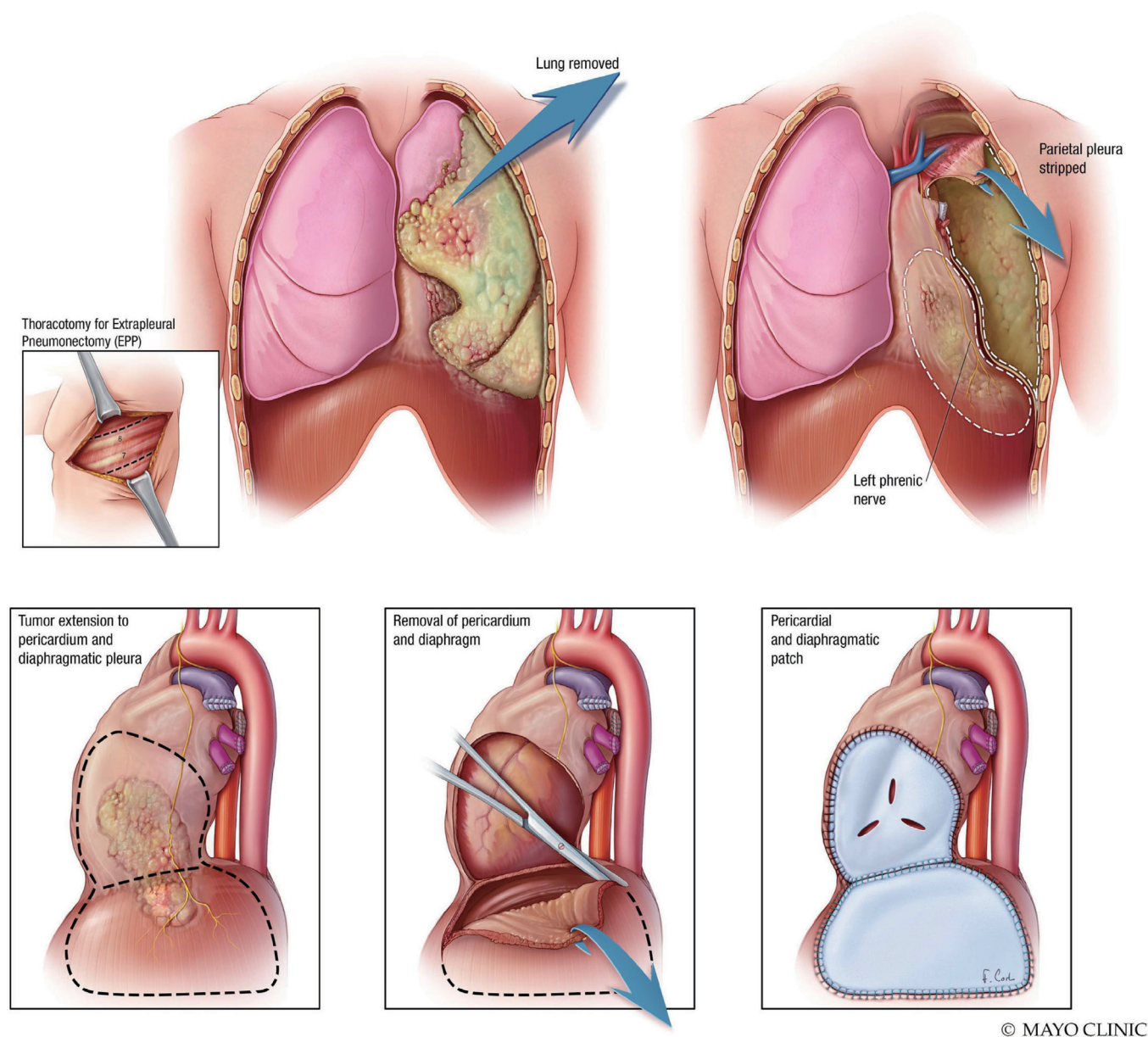
Pitfalls/comparisons

Due to a poor prognosis, the management of pleural mesothelioma remains controversial. Many of the early staging systems reflected institutional-level experiences and were not externally validated. Presently, the classification outlined by the International Mesothelioma Interest Group (IMIG), the International Association for the Study of Lung

Cancer (IASLC), and the American Joint Committee on Cancer (AJCC), have been adopted for clinical use. These recommendations consider surgical and pathologic variables as well as cross-sectional imaging (5,7).

Pearls

Single port video-assisted thoracoscopy (VATS) is a reliable



© MAYO CLINIC

Figure 14 Extrapleural pneumonectomy. Following the same principles applied in *Figure 13*, additional procedures include removal of the lung by hilar stapling and division. The entire affected lung is removed with the diseased parietal pleura, diaphragm, and pericardium. In this case, pericardial reconstruction is mandatory to prevent cardiac herniation into the pleural space.

method to diagnose intrathoracic conditions. A single incision from 0.5 to 2.5 cm in length is made, followed by blunt dissection to the pleural plane and introduction of articulating operative instruments parallel to a 5-mm 0° or 30° video-thoracoscope allows access both for diagnosis and evaluation for staging without creating too many ports that need to be later excised or are seeding for extrapleural

spread of tumor (18). Placement of the incision is determined by the location of the intrathoracic pathology as well as where a thoracotomy may be later placed to include this incision for removal, and, thus careful review of the chest computed tomography is crucial. Unlike, traditional VATS, the pleural evaluation may also be performed safely under locoregional anesthesia (through an epidural

catheter) and without intubation (medical pleuroscopy). When performing the surgical removal of mesothelioma, the surgeon may choose to make one external thoracotomy incision but then two separate intercostal incisions so that the entire chest may be reached. Additionally, placing a laparoscopic camera into the open thoracotomy wound during resection may provide additional access into the chest with enhanced visualization for learners who might be in the room as well as improved resection from an enhanced view of the intrathoracic cavity.

Acknowledgments

We would like to thank and acknowledge the media services of Mayo Clinic for their assistance in creating the included illustrations. All images are used with permission of Mayo Foundation for Medical Education and Research, all rights reserved.

Funding: None.

Footnote

Conflicts of Interest: All authors have completed the ICMJE uniform disclosure form (available at <http://dx.doi.org/10.21037/jtd-19-2267>). SHB reports grants from Steris and Medtronic, outside the submitted work. These funds are only used to fund research. The other authors have no conflicts of interest to declare.

Ethical Statement: The authors are accountable for all aspects of the work in ensuring that questions related to the accuracy or integrity of any part of the work are appropriately investigated and resolved. All of the included figures were created by a medical illustrator working with our team, and no human subjects were used in the creation of this project. However, our team understands that all procedures performed in studies involving human participants should be in accordance with the ethical standards of the institutional and/or national research committee(s) and with the Helsinki Declaration (as revised in 2013).

Open Access Statement: This is an Open Access article distributed in accordance with the Creative Commons Attribution-NonCommercial-NoDerivs 4.0 International License (CC BY-NC-ND 4.0), which permits the non-commercial replication and distribution of the article with the strict proviso that no changes or edits are made and the

original work is properly cited (including links to both the formal publication through the relevant DOI and the license). See: <https://creativecommons.org/licenses/by-nc-nd/4.0/>.

References

1. Moore AJ, Parker RJ, Wiggins J. Malignant mesothelioma. *Orphanet J Rare Dis* 2008;3:34.
2. American Cancer Society. Cancer Facts & Figures 2017 [Internet]. American Cancer Society. 2017. Available online: <https://www.cancer.org/content/dam/cancer-org/research/cancer-facts-and-statistics/annual-cancer-facts-and-figures/2017/cancer-facts-and-figures-2017.pdf>
3. Henley SJ, Larson TC, Wu M, et al. Mesothelioma incidence in 50 states and the District of Columbia, United States, 2003-2008. *Int J Occup Environ Health* 2013;19:1-10.
4. van Zandwijk N, Clarke C, Henderson D, et al. Guidelines for the diagnosis and treatment of malignant pleural mesothelioma. *J Thorac Dis* 2013;5:E254-E307.
5. Bonomi M, De Filippis C, Lopci E, et al. Clinical staging of malignant pleural mesothelioma: current perspectives. *Lung Cancer (Auckl)* 2017;8:127-39.
6. Metintaş M, Ozdemir N, İşiksoy S, et al. CT-guided pleural needle biopsy in the diagnosis of malignant mesothelioma. *J Comput Assist Tomogr* 1995;19:370-4.
7. Amin MB, Edge S, Greene F, et al. *AJCC Cancer Staging Manual* Eighth edition. Springer Int Publ, 2017.
8. Rusch VW. A proposed new international TNM staging system for malignant pleural mesothelioma. From the International Mesothelioma Interest Group. *Chest* 1995;108:1122-8.
9. Meier M, Mortensen MR, Larsen LU. Implantation of permanent pleural catheter for palliation of malignant pleural effusion. *Cancer Manag Res* 2016;8:129-33.
10. Van Meter ME, McKee KY, Kohlwes RJ. Efficacy and safety of tunneled pleural catheters in adults with malignant pleural effusions: a systematic review. *J Gen Intern Med* 2011;26:70-6.
11. Hasegawa S. Extrapleural pneumonectomy or pleurectomy/decortication for malignant pleural mesothelioma. *Gen Thorac Cardiovasc Surg* 2014;62:516-21.
12. Solli P, Brandolini J, Pardolesi A, et al. Diaphragmatic and pericardial reconstruction after surgery for malignant pleural mesothelioma. *J Thorac Dis* 2018;10:S298-303.
13. Ricciardi S, Cardillo G, Zirafa CC, et al. Surgery for malignant pleural mesothelioma: an international guidelines review. *J Thorac Dis* 2018;10:S285-92.

14. Batirel HF. Extrapleural pneumonectomy (EPP) vs. pleurectomy decortication (P/D). *Ann Transl Med* 2017;5:232.
15. Roy PM. Preoperative pulmonary evaluation for lung resection. *J Anaesthesiol Clin Pharmacol* 2018;34:296-300.
16. Cramer G, Simone CB 2nd, Busch TM, et al. Adjuvant, neoadjuvant, and definitive radiation therapy for malignant pleural mesothelioma. *J Thorac Dis* 2018;10:S2565-S2573.
17. Rosenzweig KE. Malignant pleural mesothelioma: adjuvant therapy with radiation therapy. *Ann Transl Med* 2017;5:242.
18. Rocco G. One-port (uniportal) video-assisted thoracic surgical resections--a clear advance. *J Thorac Cardiovasc Surg* 2012;144:S27-31.

Cite this article as: Brown LB, Corl F, Blackmon SH. Surgical staging and resection of malignant pleural mesothelioma. *J Thorac Dis* 2020;12(12):7467-7480. doi: 10.21037/jtd-19-2267