

Echocardiographic Evaluation of Postoperative Coaptation Geometry of Left AV Valve in Complete Atrioventricular Septal Defect

Hiroo Kinami¹, Kiyozo Morita, Gen Shinohara and Yoshimasa Uno

Department of Cardiac Surgery, Jikei University School of Medicine, Minato-ku, Tokyo, Japan.

Clinical Medicine Insights: Pediatrics
Volume 16: 1–7
© The Author(s) 2022
Article reuse guidelines:
sagepub.com/journals-permissions
DOI: 10.1177/11795565221139118



ABSTRACT

BACKGROUND: We sought to determine the difference in geometric parameters in the left atrioventricular valve (LAVV) postoperative complete atrioventricular septal defect (CAVSD) compared to the normal heart, and the correlation between geometric and functional parameters for detecting the mechanism of LAVV regurgitation (LAVVR) in CAVSD.

METHODS: LAVV geometric parameters based on complete and acceptable quality echocardiograms of 18 patients with repaired CAVSD compared with 17 normal controls. LAVVR severity was also quantified by indexed vena contracta (I-VC) (mm) and % jet area/left atrium area (% Jet/LA), and the correlation with LAVV parameters in the CAVSD group was investigated.

RESULTS: In the CAVSD group, the posterior closing angle (Pc) was nearly the same as the anterior closing angle (Ac), yet in the normal heart, the Pc angle was double the Ac angle. The anterior opening angle (Ao) and posterior-to-anterior leaflet diameter ratio (a/p) in the CAVSD group was also significantly smaller. The CAVSD group also had a shorter indexed coaptation length (I-CL) and indexed tenting height (I-TH). Displacement length (ΔD) differed completely between the CAVSD and Normal groups, and also showed a strong positive correlation to the functional parameters of LAVVR (% Jet/LA: $r = .70$, $P = .02$; I-VC: $r = .60$, $P = .02$).

CONCLUSIONS: The parameters in this study were applicable to CAVSD AV valve coaptation characteristics. We introduced 2 novel measures that may provide important insights into the differences in geometry and performance of the LAVV in repaired CAVSD as compared to normal hearts.

KEYWORDS: Complete atrioventricular septal defect, echocardiography, coaptation geometry, congenital heart surgery, AV valve regurgitation

RECEIVED: April 16, 2021. **ACCEPTED:** October 28, 2022.

TYPE: Original Research

FUNDING: The author(s) received no financial support for the research, authorship, and/or publication of this article.

COMPETING INTERESTS: The author(s) declared no potential conflicts of interest with respect to the research, authorship, and/or publication of this article.

CORRESPONDING AUTHOR: Hiroo Kinami, Department of Cardiac Surgery, Jikei University School of Medicine, 3-25-8 Nishinbashi, Minato-ku, Tokyo 105-8461, Japan. Email: kinami_md11@jikei.ac.jp

Introduction

Atrioventricular septal defect (AVSD) represents approximately 3% of patients born with congenital heart disease. Surgical repair includes partitioning the common AV valve into right- and left-sided components, closure of the valvular cleft or zone of apposition, and closure of any ventricular and atrial septal defects. Since the first successful repair of a complete atrioventricular septal defect (CAVSD) by Lillehei et al in 1955,¹ surgical repair and postoperative management of AVSDs have improved.²⁻⁶ The Pediatric Heart Network reported that AVSD outcome data from 7 North American centers demonstrated an overall 6-month mortality rate of 4%.⁷ It was also reported that 22% of patients had moderate or greater left-side AV valve regurgitation (LAVVR) 6 months after repair.⁷ In fact, hemodynamically significant LAVVR is the main cause of early and late deaths and the need for reoperation.^{8,9} Severe regurgitation across the left AV valve (LAVV) is rarely tolerated, causing significant mortality in children. Although numerous factors seem to be related to postoperative LAVVR, there have been few reports regarding the structure and geometric changes that may produce regurgitation.¹⁰⁻¹³ In

adults, the relationship between mitral valve plasty and postoperative geometric parameters has been discussed in detail using 3D visualization techniques such as echocardiography and magnetic resonance imaging. These studies have revealed the pre- and postoperative geometric changes in the mitral valve and the relationships between geometric parameters and mitral regurgitation severity, in addition to an evaluation of mitral ring annuloplasty.¹⁴⁻¹⁶ Establishing geometric parameters in AVSDs would help us to evaluate the factors of LAVVR and teach us how to improve our surgical techniques. In this study, we sought to determine the difference in geometric parameters in the LAVV between CAVSD and normal heart cases, which may describe the coaptation characteristics in each group. In the CAVSD group, an intra-group comparison of geometric parameters and functional parameters might help us detect the geometric determinants related to LAVVR.

Methods

Study design

This is a retrospective chart review, in which we reviewed complete and acceptable quality echocardiograms of 18 patients



with repaired CAVSD compared with 17 normal controls. The clinical data related to these patients at our institution had been also collected.

Inclusion and exclusion criteria

We included CAVSD patients who had undergone intracardiac repair (ICR) with two-patch method at our institution and who had been followed by echocardiogram at our outpatient department between January 2013 and December 2015. The patients with normal ventricular function (as Normal group), who had echo for the purpose of screening at the department of pediatric cardiology to exclude physiologic murmur in 2014 which did not require further studies or outpatient visits, were also included. The age range of the normal group at echocardiogram was between 0.45 and 17.5 years old. We excluded the patients who we lost to follow-up or who had poor echo images which meant we could not measure all of our echo cardiogram parameters precisely.

Ethical approval/consent

This study qualifies for a waiver or alteration of consent as the following criteria were met in this study. All charts and echo data were reviewed retrospectively after discharge. The risk is minimal and includes breach of confidentiality from hacking into hospital computers. The retrospective chart review does not include any contact with a patient or family. The study protocol has been reviewed and approved by the Jikei University School of Medicine Ethics Committee; 28-213(8456).

Surgical procedures

We only performed two-patch method for CAVSD group. In all cases, cardiopulmonary bypass was established using bicaval cannulation under moderate hypothermia. A left atrial vent was inserted through a left atrial appendage. Cold blood cardioplegia and terminal warm blood cardioplegia were chosen. A 0.4-mm expanded polytetrafluoroethylene (ePTFE) VSD patch (GoreTex; W.L. Gore & Associates, Flagstaff, AZ) was placed on the right side of the ventricular septal crest using a running Prolene suture with the respect which preserved preoperative geometry by adjusting VSD patch size to VSD depth as same as possible. We had tried to close the left atrioventricular valve cleft completely, except for cases that involved hypoplastic left mural leaflet or insufficient leaflet area of the LAVV component, which were closed with interrupted Prolene sutures. The autologous glutaraldehyde-treated atrial septal defect (ASD) patch was sutured, and, at the same time, the superior and the inferior bridging leaflets were separated with 2 patches using interrupted horizontal mattress sutures. The ASD patch was sutured to the rim of the ostium primum using a continuous Prolene suture, and, in the process, shifting the coronary sinus drain to the LA.

Echocardiogram evaluation

The long-axis view parasternal view (LAX) and apical four-chamber view (4ch) were used for all measurements. The measurements were performed at both end-systole and end-diastole. End-systole was taken as the frame preceding the LAVV opening, and end-diastole was taken as the frame at which the LAVV begins to close.

Geometric parameters

In the CAVSD group, the bridging leaflet is referred to as the anterior leaflet, and the left mural leaflet as the posterior leaflet in this study. LAVV measurements obtained from the 2D echocardiography studies are shown in Figure 1. LAVV indexed annulus size (I-AN), leaflet indexed tenting height (I-TH), Indexed coaptation length (I-CL), anterior leaflet closing angle (Ac), posterior leaflet closing angle (Pc), and posterior-to-anterior leaflet diameter ratio (a/p) were measured at end-systole by 2D echocardiography at LAX and 4ch view in each group. Anterior leaflet opening angle (Ao) and posterior opening angle (Po) were also measured at the end-diastole. Ac and Ao are the angles between the annulus line and the anterior leaflet at the end-diastolic phase and the mid-systolic phase. Similarly, Pc are the angles between and Po are the angles between the annular line and the posterior leaflet in the same phases. The parameter a/p is the ratio that the length of the anterior leaflet is divided by the length of the posterior leaflet to assess the characteristics of the LAVV coaptation.

The parameters of length were normalized relative to an appropriate power of the body surface area (BSA), which was calculated at the time of echocardiographic measurement. Normalized dimensions are presented in “centimeters/meters,” normalized areas are presented in “centimeters squared/meters squared,” and normalized volumes are presented in “milliliters/meters cubed.” From the 4ch view, we established Displacement length (ΔD), which is the diameter from the line of the common AV valve annulus to the septal side of the LAVV annulus. We defined a shift to the apex side as a plus and the point on the line of common AV valve annulus as 0, and the length was divided by the LAVV annulus diameter and multiplied by 100 (%) for normalization. The main reason why we start measuring ΔD is this length is variate postoperatively which should be related to the depth of the VSD patch and might change the geometry and function of the anterior leaflet.

Functional parameters

LAVVR was quantified by indexed vena contracta (I-VC) (mm) and % jet area/left atrium area (% Jet/LA). The vena contracta width was measured at the narrowest region of the regurgitant flow at convergence at mid-systole and was indexed to BSA. % Jet/LA was the ratio of the color Doppler jet to the

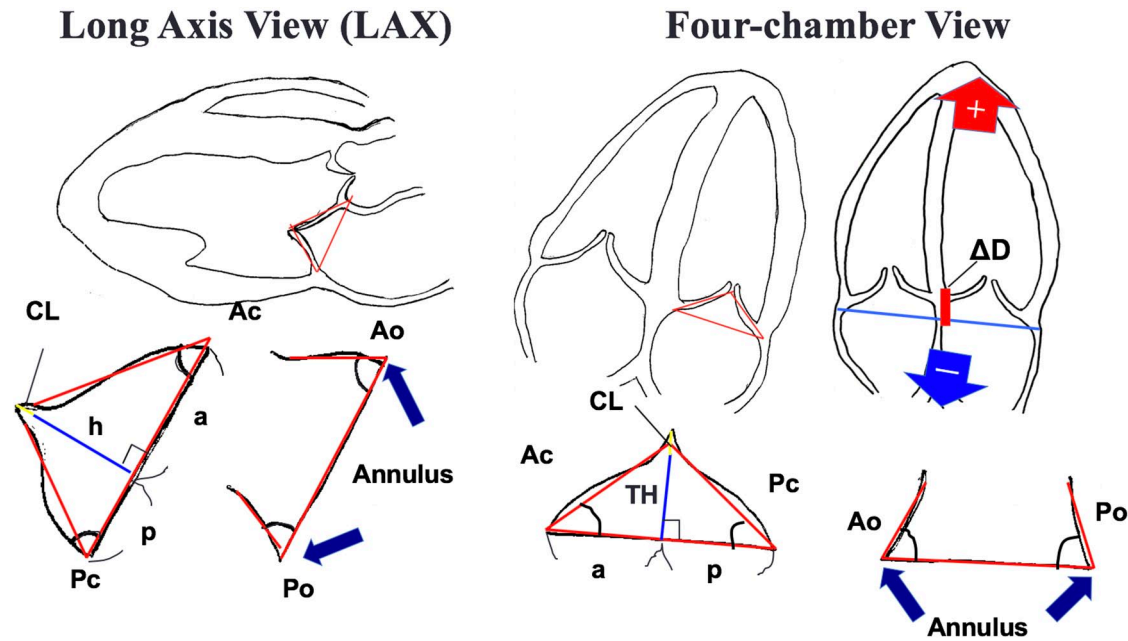


Figure 1. A, Left AV valve annulus size (AN), leaflet tenting height (TH), coaptation length (CL), anterior leaflet closing angle (Ac), posterior leaflet closing angle (Pc), and posterior-to-anterior leaflet diameter ratio (a/p) were measured at end-systole by 2D echocardiography at LAX and 4ch views in each group. Anterior leaflet opening angle (Ao) and posterior opening angle (Po) were also measured at end-diastole. From the 4ch view, we established displacement length (ΔD), which is the diameter from the line of the common AV valve annulus to the septal side of the left AV valve annulus. We defined a shift to the apex side as a plus, and the point on the line of common AV valve annulus as 0, and the length was divided by the left AV valve annulus diameter and multiplied by 100 (%) for normalization.

area of the LA traced by the echocardiographic measurement system.

Statistical analysis

Patient's baseline characteristics and outcomes were summarized using descriptive statistics. Categorical variables are distributed as frequencies and percentages. Continuous variables are described as mean \pm standard deviation if the data were normally distributed or median with range if not normally distributed. A Wilcoxon rank sum test for positively skewed variables and Student's *t*-test was used to compare changes in outcomes. *P* value <0.05 was considered statistically significant. To identify the geometric parameters associated with the functional parameters in the CAVSD group, univariate analysis was evaluated and multivariate models were subsequently applied.

Results

Study characteristics

The group for this analysis included 35 patients (CAVSD group, 18; Normal group, 17), all of whom were Japanese (100%). In the CAVSD group, 78% had trisomy 21, and 56% were male. The median age at latest echocardiogram was 9.3 years, the median age at ICR was 11.2 months. The years from the surgeries were very variate 8.7 ± 7.6 (years), the median of 8.6 years. Our facility used to perform ICR at around 6 to 10 months of age, but recently the procedure has been performed at around 4 to 6 months of age. In this cohort, 61% of

cases were classified as Rastelli A, 17% as Rastelli B, and 22% as Rastelli C. We revealed that LAVVR at the latest echocardiogram was trivial in 11% of the cases, mild in 66%, mild to moderate in 6%, and moderate in 17%. No case required reoperation for LAVVR during the median 8.4 years follow-up. When comparing the Normal and CAVSD groups, none of the baseline characteristics showed any significant differences. The Normal group possessed similar characteristics to the CAVSD group such as the median age at echocardiogram, sex ratio, body weight (BW), and BSA. The base general left ventricular functions estimated by echocardiogram were similar, such as left ventricular diastolic diameter (LVDd) and LV ejection fraction (LVEF) (Table 1).

Geometric parameters

The geometric parameters at 4ch in the CAVSD group were compared to the parameters at LAX in the Normal group for anatomical reasons. The indexed annulus diameter (I-AN) values were nearly the same. In the CAVSD group, the Pc angle was nearly the same as the Ac angle, yet in the normal group, the Pc angle was double that of the Ac angle ($P < .001$). The a/p in the CAVSD group was half that of the Normal group ($P < .001$). On the other hand, the Po angle showed no significant difference between the groups ($P = .08$), but there was a significant difference in the Ao angle ($P < .001$). The CAVSD group had a relatively shorter indexed coaptation length (I-CL) ($P = .09$) and indexed tenting height (I-TH) ($P = .08$) than the

Table 1. Patient characteristics: postoperative complete atrioventricular defect and normal heart.

CHARACTERISTICS	CAVSD (N=18)	NORMAL (N=17)	P VALUE
Age at echocardiogram (years)	9.3 ± 7.7	6.3 ± 5.9	.23
Age at operation (months)	11.2 ± 4.2	N/A	N/A
Sex (%male)	10 (55.6%)	13 (76.5%)	N/A
Trisomy 21 (%)	14 (77.8%)	N/A	N/A
Rastelli types			
A	11 (61.1%)	N/A	N/A
B	3 (16.7%)	N/A	N/A
C	4 (22.2%)	N/A	N/A
Body weight (kg)	23.5 ± 16.9	20.8 ± 14.7	.61
Body surface area (m ²)	0.81 ± 0.39	0.77 ± 0.39	.71
Ejection fraction (%)	70.7 ± 2.5	69.5 ± 4.5	.64
LVDd (mm)	31.4 ± 7.6	33.1 ± 6.5	.47

Table 2. Echocardiographic evaluation of geometric parameters between CAVSD and normal.

PARAMETERS	CAVSD (N=18)	NORMAL (N=17)	P VALUE
Ac angle (°)	23 ± 7	23 ± 4	.38
Pc angle (°)	26 ± 9	44 ± 7	<.001
a/p	1.1 ± 0.5	2.2 ± 0.6	<.001
Ao angle (°)	55 ± 13	73 ± 9	<.001
Po angle (°)	74 ± 14	82 ± 15	.09
Displacement Length	9.9 ± 5.7	-9.9 ± 4.0	<.001
I-Tenting height (mm/m ²)	5.8 ± 3.2	8.1 3.0	.08
I-Coaptation length (mm/m ²)	4.6 ± 2.3	6.0 ± 2.0	.09

Normal group but there were no significant differences respectively. ΔD showed a complete difference between the groups ($P < .001$) as it described the features of AVSD (Table 2). As an interesting reference, the actual diameters from the common AV valve annulus were 1.97 ± 1.34 (mm) in CAVSD and -2.16 ± 0.83 (mm) in Normal. These numbers were divided by each annulus diameter and normalized into ΔD as we explained in the Methods section.

Univariate analysis of the association of the geometric parameters with the functional parameters of LAVVR

Univariate analysis showed that ΔD had a significantly strong positive correlation to % Jet/LA in terms of the correlation coefficient ($r = .70$, $P = .02$). There was a significant negative association between I-VC and Pc angle ($r = -.65$, $P = .04$). ΔD

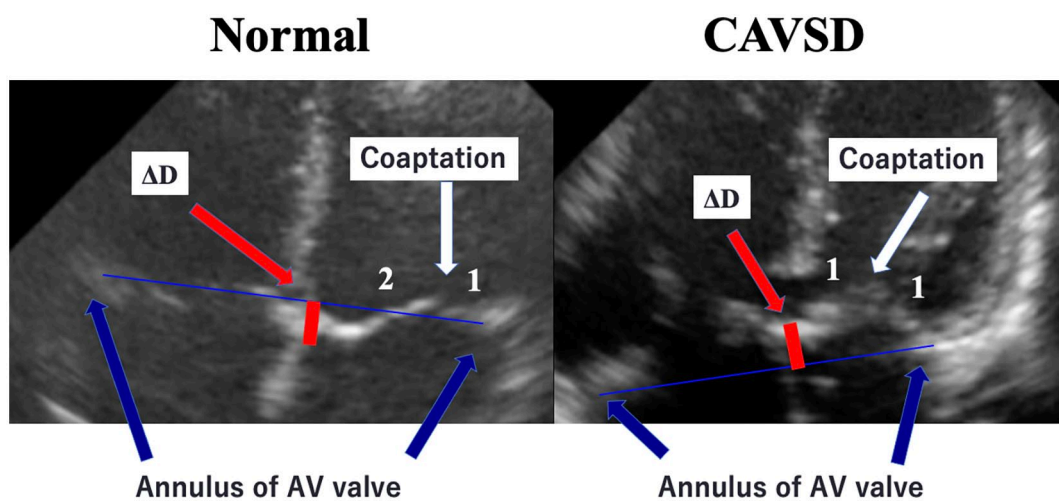
was also likely to have a positive correlation to I-VC ($r = .63$, $P = .06$) (Table 3).

Discussion

Atrioventricular septal defect represents a set of complex characteristics generated from a defect in the development of the endocardial cushions. After CAVSD patients undergo ICR, the geometry of the LAVV will change dramatically as a result of the partitioning of the common AV valve into right- and left-sided components, closure of the valvular cleft or zone of apposition, and closure of VSD. These geometric changes affect LAVVR and LAVV functions. Unfortunately, we do not have effective tools for evaluating postoperative geometric changes, but, in adults, the relationship between mitral valve plasty and post-operative geometric parameters has been discussed in detail using echocardiography.¹⁶⁻¹⁸ These reports in adults have defined numerous geometric parameters that were useful for

Table 3. Possible determinant of LAVVR severity: comparing the geometric parameters versus MR/LA area and I-Vena contracta.

PARAMETERS	MR/LA AREA		I-VENA CONTRACTA	
	R	P VALUE	R	P VALUE
I-Annulus	.29	.12	.39	.89
Ac angle	.40	.68	.11	.45
Pc angle	-0.52	.32	-0.25	.18
a/p	-0.55	.46	-0.19	.15
I-Tenting height	.35	.28	.28	.55
I-Coaptation length	.35	.52	.16	.55
Displacement length	.70	.02	.60	.02

**Figure 2.** The comparison of coaptation geometry between CAVSD and normal hearts at 4ch view in echocardiogram. In the CAVSD group, the a/p was 1.1 and ΔD was $+9.9 \pm 7.2$. In the Normal group, the a/p was 2.2 and ΔD was -9.4 ± 3.6 .

evaluating valvular flexibility and coaptation patterns, such as valvular angles, tenting height, and coaptation length. We did not only adopt these common mitral geometric parameters to the left atrioventricular valve but also established 2 new parameters that include a/p and ΔD . Both of these parameters are suitable for describing the features of the postoperative CAVSD coaptation pattern and have not been reported previously. In the CAVSD group, the Pc angle was nearly the same as the Ac angle, and the a/p was 1.1. In the Normal group, the Pc angle was double the Ac angle, and the a/p was 2.2. These data implied that posterior leaflet movement would stop at the “deep” point, and the anterior leaflet would move to the deep point with about twice the momentum in the normal group. Some reports have indicated that performing mitral valve annuloplasty with saddle-shaped and flat annuloplasty rings is responsible for the restrictive motion of the posterior leaflet that was described as monocusp behavior of the anterior leaflet.¹⁴ From the view of coaptation geometry, the contribution of the anterior leaflet to regurgitant regulation in the normal heart is much more considerable than the role of the posterior leaflet. On the other hand, in the CAVSD group, the coaptation point is located at the center between the bridging leaflet and the left

mural leaflet. These results described the features of CAVSD in which the left mural leaflet contributes more to the coaptation mechanism and regulation of AV valve insufficiency than the mitral posterior leaflet of a normal heart does. We described the difference in coaptation characteristics between CAVSD and Normal in Figure 2. While there was no significant difference in the Po angle between the groups, there was a significant difference in the Ao angle. These differences occurred during post-operative changes in which the motion of the bridging leaflets had been limited by compression between VSD and ASD patches. That is one of the reasons why the bridging leaflet of AVSD plays a minor role in the coaptation mechanism.

In terms of Displacement length (ΔD), the AVSD group shows a significant difference: $+9.9 \pm 7.2$ versus the Normal group -9.4 ± 3.6 . In our strategy, we define VSD patch height to be the same as the natural pre-operative VSD height with intra-operative measurement. Even under these conditions, the place where the bridging leaflet attaches is displaced, in a wide range, toward the apex side. It should be noted that ΔD had a significantly positive correlation to % Jet/LA and I-VC. These results imply that bridging leaflet displacement toward the apex side could be one of the determinants for regulating

LAVVR. Based on this result, the modified one-patch method would likely produce massive LAVVR, but several reports have shown that there is no difference in LAVVR between the two-p and modified one-patch methods¹⁸⁻²⁰. It is believed that a significant postoperative increase of ΔD worsens LAVVR, and a minimum change of ΔD makes no difference even after the modified one-patch method.

We also tried to detect a relationship between ΔD and other geometric parameters to find the mechanism causing LAVVR related to ΔD , but no correlations were found.

In our study, no cases required re-operation due to significant LAVVR that are satisfactory LAVV functions and results. The annular diameters are also well-preserved based on this study, and additionally, the CAVSD group had no significant differences in I-CL and I-TH values compared to the normal group, which reflects the preservation of proper coaptation. We have a very low threshold to place the 3 mm GoreTex strip across the bridging leaflets which are designed 80% of the length of Z score O tricuspoid valve diameter based on the BSA. The posterior or/and anterior annuloplasty was applied for the LAVV plasty in case we saw the annular dilation or more than moderate grade LAVVR preoperatively. These techniques seemed to be helpful to maintain the proper annular diameter on both the bridging leaflets and the bridging leaflets/the left mural leaflet directions. Ultimately these techniques might help to preserve a decent length of I-TH and I-CL. We aimed to detect the relationship between the geometric parameters, and the geometry and the functional parameters to reveal the mechanism of regulating LAVVR. No obvious relationships were detected in this study but further evaluation including preoperative measurement and more samples will reveal precise mechanisms with these geometric parameters and identify the best way to regulate LAVVR.

Study Limitations

Because our data were collected retrospectively, there were some missing cases that we could not follow and could not evaluate due to the poor quality of the images. That is one of the reasons why we were not able to collect enough data that detect a clearly defined relationship between geometric parameters and functional parameters. Especially for detecting the relationship between ΔD and LAVVR and other geometric parameters, we should correct pre-operative data, and compare pre- and post- ΔD prospectively in a further study. Because we were not able to detect the statistical significant relationship between each geometric parameter or a geometric parameter and a functional parameter, it was difficult to feedback on our surgical technique.

Conclusions

We evaluated the coaptation features of postoperative CAVSD patients using an echocardiogram which was compared to coaptation geometries in normal hearts. In this evaluation, we

did not only adopt common mitral geometric parameters to the left atrioventricular valve but also introduced 2 novel measures that may provide important insights into the differences in geometry and performance of the LAVV in repaired CAVSD as compared to normal hearts. Subsequent investigations with larger cohorts will be needed to confirm our findings.

Declarations

Ethics approval and consent to participate

The study protocol has been reviewed and approved by the Jikei university school of medicine ethics committee; 28-213(8456).

Consent for publication

This study qualifies for a waiver or alteration of consent as the following criteria were met in this study. All charts and echo data were reviewed retrospectively after discharge. The risk is minimal and includes breach of confidentiality from hacking into hospital computers.

The retrospective chart review does not include any contact with a patient or family.

Acknowledgements

The author(s) received no financial support for the research, authorship, and/or publication of this article.

Author contribution(s)

Hiroo Kinami: Data curation; Formal analysis; Investigation; Methodology; Project administration; Writing – original draft; Writing – review & editing. Kiyozo Morita: Project administration; Supervision; Validation. Gen Shinohara: Formal analysis; Supervision. Yoshimasa Uno: Supervision.

Availability of data and materials

Not applicable.

ORCID iD

Hiroo Kinami  <https://orcid.org/0000-0002-1983-2400>

IRS approval

The study was conducted in accordance with Institutional Human Subjects Committee Guidelines and was approved by the Institutional Review Board at Jikei University School of Medicine. The study was a retrospective review of the pediatric cardiology and cardiac surgery database at Jikei University School of Medicine identifying all patients who underwent surgical repair for CAVSD, as CAVSD group, and Normal (ie, control) group.

REFERENCES

1. Lillehei CW, Cohen M, Warden HE, Varco RL. The direct-vision intracardiac correction of congenital anomalies by controlled cross circulation; results in thirty-two patients with ventricular septal defects, tetralogy of Fallot, and atrioventricularis communis defects. *Surgery*. 1955;38:11-29.

2. Jacobs JP, Jacobs ML, Mavroudis C, et al. Atrioventricular septal defects: lessons learned about patterns of practice and outcomes from the congenital heart surgery database of the Society of Thoracic Surgeons. *World J Pediatr Congenit Heart Surg.* 2010;1:68-77.
3. Hoohenkerk GJF, Bruggemans EF, Rijlaarsdam M, Schoof PH, Koolbergen DR, Hazekamp MG. More than 30 years' experience with surgical correction of atrioventricular septal defects. *Ann Thorac Surg.* 2010;90:1554-1561.
4. Ono M, Goerler H, Boethig D, et al. Improved results after repair of complete atrioventricular septal defect. *J Card Surg.* 2009;24:732-737.
5. Bando K, Turrentine MW, Sun K, et al. Surgical management of complete atrioventricular septal defects. A twenty-year experience. *J Thorac Cardiovasc Surg.* 1995;110:1543-1552.
6. Suzuki T, Bove EL, Devaney EJ, et al. Results of definitive repair of complete atrioventricular septal defect in neonates and infants. *Ann Thorac Surg.* 2008;86:596-602.
7. Atz AM, Hawkins JA, Lu M, et al.; Pediatric Heart Network Investigators. Surgical management of complete atrioventricular septal defect: associations with surgical technique, age, and trisomy 21. *J Thorac Cardiovasc Surg.* 2011;141:1371-1379.
8. Meisner H, Guenther T. Atrioventricular septal defect. *Pediatr Cardiol.* 1998;19:276-281.
9. Thies WR, Breyman T, Matthies W, Crespo-Martinez E, Meyer H, Körfer R. Primary repair of complete atrioventricular septal defect. In infancy. *Eur J Cardiothorac Surg.* 1991;5:571-574.
10. Ugaki S, Khoo NS, Ross DB, Rebeyka IM, Adatia I. Modified single-patch compared with two-patch repair of complete atrioventricular septal defect. *Ann Thorac Surg.* 2014;97:666-671.
11. Kaza E, Marx GR, Kaza AK, et al. Changes in left atrioventricular valve geometry after surgical repair of complete atrioventricular canal. *J Thorac Cardiovasc Surg.* 2012;143:1117-1124.
12. Bharucha T, Sivaprakasam MC, Haw MP, Anderson RH, Vettukattil JJ. The angle of the components of the common atrioventricular valve predicts the outcome of surgical correction in patients with atrioventricular septal defect and common atrioventricular junction. *J Am Soc Echocardiogr.* 2008;21:1099-1104.
13. Al Senaidi KS, Ross DB, Rebeyka IM, et al. Comparison of two surgical techniques for complete atrioventricular septal defect repair using two- and three-dimensional echocardiography. *Pediatr Cardiol.* 2014;35:393-398.
14. Jensen MO, Jensen H, Levine RA, et al. Saddle-shaped mitral valve annuloplasty rings improve leaflet coaptation geometry. *J Thorac Cardiovasc Surg.* 2011;142:697-703.
15. Bothe W, Rausch MK, Kvitting JP, et al. How do annuloplasty rings affect mitral annular strains in the normal beating ovine heart? *Circulation.* 2012;126:S231-S238.
16. He S, Weston MW, Lemmon J, Jensen M, Levine RA, Yoganathan AP. Geometric distribution of chordae tendineae: an important anatomic feature in mitral valve function. *J Heart Valve Dis.* 2000;9:495-501.
17. Allen HD. *Moss & Adams' Heart Disease in Infants, Children, and Adolescents, Including the Fetus and Young Adult.* 8th ed. Wolters Kluwer Health/Lippincott Williams & Wilkins; 2013.
18. Backer CL, Stewart RD, Bailliard F, Kelle AM, Webb CL, Mavroudis C. Complete atrioventricular canal: comparison of modified single-patch technique with two-patch technique. *Ann Thorac Surg.* 2007;84:2038-2046.
19. Jeong IS, Lee CH, Lee C, et al. Surgical outcomes of the modified single-patch technique in complete atrioventricular septal defect. *Interact Cardiovasc Thorac Surg.* 2009;8:435-437.
20. Pan G, Song L, Zhou X, Zhao J. Complete atrioventricular septal defect: comparison of modified single-patch technique with two-patch technique in infants. *J Card Surg.* 2014;29:251-255.