



Contents lists available at ScienceDirect

International Journal of Surgery Case Reports

journal homepage: www.casereports.com

Right hepatectomy after spontaneous hepatic rupture in a patient with preeclampsia: A case report



Carlos A. Millan^{a,*}, Juan C. Forero^b

^a Fundacion Universitaria Ciencias de la Salud, Colombia

^b Department of Surgery, Hepatobiliary and Transplant Surgery, Hospital de San Jose, Bogota, Colombia, Fundacion Universitaria Ciencias de la Salud

ARTICLE INFO

Article history:

Received 5 May 2017

Received in revised form 29 July 2017

Accepted 30 July 2017

Available online 18 August 2017

Keywords:

Spontaneous hepatic rupture

HELLP syndrome

Hepatectomy

Angioembolization

ABSTRACT

INTRODUCTION: Spontaneous hepatic rupture associated with preeclampsia or HELLP syndrome is a rare and life threatening event, only 200 cases have been reported in the literature.

PRESENTATION OF CASE: We present a case of a 31 year old female with 28 weeks of gestation that presented with acute abdominal pain, elevated blood pressure and altered liver enzymes an abdominal ultrasound that showed a subcapsular hematoma occupying the whole right lobe and free abdominal fluid, she required emergent laparotomy, C-section, hepatic packing, followed by angioembolization and finally right hepatectomy.

DISCUSSION AND CONCLUSION: Spontaneous hepatic rupture due to preeclampsia or HELLP syndrome is a medical emergency, it requires a prompt and decisive treatment. Multiple treatment modalities are available, from simple hepatic packing to endovascular embolization, but in extreme situations a formal hepatectomy might be required.

© 2017 The Authors. Published by Elsevier Ltd on behalf of IJS Publishing Group Ltd. This is an open access article under the CC BY-NC-ND license (<http://creativecommons.org/licenses/by-nc-nd/4.0/>).

1. Introduction

Spontaneous hepatic rupture associated with preeclampsia or HELLP syndrome is a rare event, the incidence is 1 in 40,000–1 in 250,000 pregnancies [1]. It carries a high mortality reaching up to 28% [2]. Treatment depends on the clinical presentation from a conservative management to emergent laparotomy perihepatic packing and second look operation. Other treatment modalities like endovascular embolization and even liver transplantation can be used successfully [3,4]. Formal hepatectomy is an option to be considered when less invasive measures fail to stop the bleeding or when there is extensive liver necrosis due to the risk of infection. Only a few cases of cases of hepatectomy after spontaneous hepatic rupture have been described in the literature [5]. This case report follows the SCARE criteria [6].

Presentation of case

A 31 year old hispanic female G1P1A0 with 28 weeks gestation and irregular prenatal control, a body mass index of 30, arrived to the emergency room at our private university hospital in Bogota, Colombia with one day history of right upper quadrant pain, emesis and diarrhea. Past medical history was uneventful. Her previous pregnancy was an uncomplicated vaginal delivery. Physical exam-

ination revealed a blood pressure of 145/90 mm/Hg, a heart rate of 97 beats per minute, tenderness in the right upper quadrant, a uterine height of 28 cm, and a normal fetocardia. Laboratory tests revealed a WBC of 14500 m/L, Hgb of 12 mg/dl, Platelet count of 220,000 m/L, liver enzymes with an ALT of 97 mg/dl, AST of 87 mg/dl, INR of 1.4, LDH 1100 UI/L, normal bilirubin and renal function tests, proteinuria of 500 mg/dl in a random urine sample.

Abdominal US showed a subcapsular hematoma comprising segments V,VI,VII,VIII and free abdominal fluid. A diagnosis of ruptured subcapsular hematoma associated with preeclampsia was made and emergent laparotomy was indicated. Informed consent was obtained from the patient and family, prophylactic antibiotic was initiated and hemoderivative reserve was requested. In less than 4 h of admission she was in the operating room accompanied by acute care surgery, obstetrics and neonatology. The operation revealed the following findings: 3000cc of hemoperitoneum a ruptured subcapsular hematoma involving the whole right lobe with acute bleeding. She underwent C-section and perihepatic packing. The newborn was transferred to the neonatal intensive care unit had an adequate adaptation and after a week was discharged. During surgery she required 4 units of packed red blood cells (PRBC) and 4 units of plasma. She was transferred to the ICU (Intensive Care Unit) after surgery to continue resuscitation with intravenous fluids, vasoactive support: noradrenaline titrated up to 1 mcg/kg/min and vasopressin up to 6 u/h, all under hemodynamic monitoring with FLOTRAC™, during the course of the second postoperative day there was evidence of persistent hypovolemia, requiring additional 2 units of PRBC, so it was decided to take her to selective

* Corresponding author.

E-mail address: mimac13@yahoo.com (C.A. Millan).

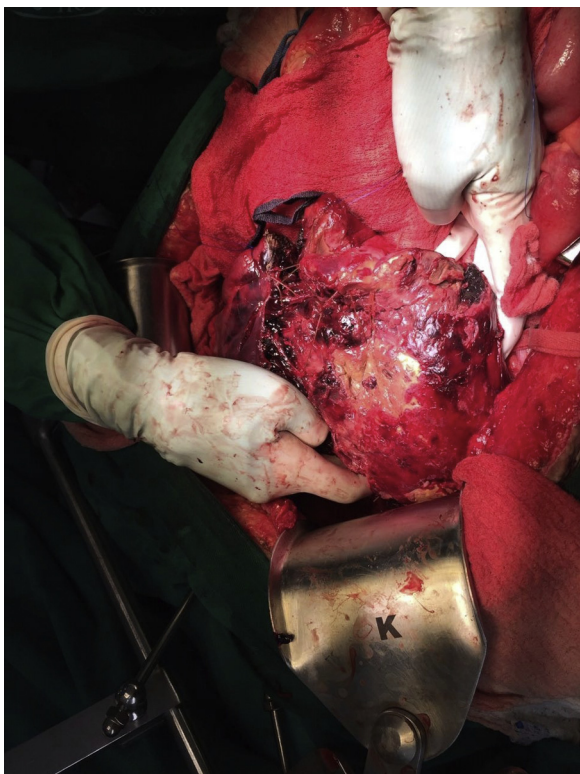


Fig. 1. Intraoperative photo showing the necrotic right lobe.

angioembolization of the right hepatic artery by vascular surgery. She was scheduled for a second look operation 24 h later by hepatobiliary surgery, finding a devitalized and a necrotic right lobe so cultures were taken and a formal right hepatectomy was done (Fig. 1). Total operating time was 4 h, blood loss was 100cc. After the procedure she slowly recovered but developed a fluid collection in the liver bed that required percutaneous drainage and 21 days of antibiotic treatment, cultures grew *Klebsiella Pneumoniae* and *Citrobacter Freundi*. The total hospital stay was 33 days.

2. Discussion

Spontaneous hepatic rupture associated with preeclampsia and HELLP syndrome is a rare event, it still carries a high maternal and neonatal mortality. In this particular case the patient didn't have all the diagnostic criteria for HELLP syndrome but did have elevated liver enzymes, evidence of hemolysis; and fulfilled the diagnostic criteria for preeclampsia [6]. In the initial evaluation the obstetrics and surgery department decided that the best course of action would be to perform an emergent laparotomy to perform the emergency C-section and in the same time evaluate the liver. At this point there could be several courses of action; to perform dedicated hemostasis with hepatorrhaphy, perform perihepatic packing, or finally perform a right hepatectomy. Due to the amount of blood loss, the difficulty in attaining hemostasis, summed to the necessity to perform another urgent procedure (the C-section), adding even more time to the procedure, it was evident that appropriate action would be a damage control surgery with only perihepatic packing. Unfortunately the packing alone didn't stop the bleeding. It could be said that in this scenario the second look operation could be expedited, but we decided that an additional procedure besides a second look operation might be needed so in a complementary approach the embolization was done. It did stop the bleeding but in retrospect it might have contributed to the necrosis of the right lobe. That's why the second look operation is crucial not

only to remove the packing but to evaluate the liver parenchyma. Formal right hepatectomy was not planned for the second look operation it was decided intraoperatively due to the extensive devitalized tissue necrosis of the right lobe. The most important teaching points that can be taken from this case report are that when faced with this kind of patients the diagnosis should be made quickly, and the surgical treatment shouldn't be delayed, if laparotomy is considered, perihepatic packing should be tried first but always keeping in mind that complications or treatment failure can occur, and if they do, a lobectomy or even a liver transplant should be considered. Reviewing the literature most of the subcapsular hematomas can be managed by perihepatic packing or angioembolization [7], it is very unusual to end up in a formal lobectomy but it is important to have the availability of a liver surgeon in case it's needed. Some old series report hepatectomies or lobectomies, but only as one of the various treatment available, reporting a survival after lobectomy of only 25% [8]. But many advances in anesthesia, perioperative management and ICU care make nowadays liver resection a safer procedure with better outcomes. It is interesting to see that in the series reported by Wilson et al. a small proportion of patients required elective lobectomy, for cholangitis associated with hematoma and lobe atrophy so outpatient followup is important in this patients [9]. This case reports adds to the scarce literature about subcapsular hematoma associated with preeclampsia and validates the role of lobectomy in this era of minimally invasive treatments.

3. Conclusion

For the successful management of spontaneous hepatic rupture secondary to preeclampsia a swift and coordinated effort by a multidisciplinary team is vital for a good outcome. When other options fail, a formal lobectomy can be done with low morbidity and no mortality.

Conflict of interest

The author declared that there was no conflict of interest.

Funding

This research did not receive any specific grant from funding agencies in the public, commercial, or not-from-profit sectors.

The authors do not declare some type of external financing for the presentation of the case report.

Ethical approval

This is a case report involving one patient and thus does not require IRB approval.

Consent

Written informed consent was obtained from the patient for publication of this case report and accompanying images. A copy of the written consent is available for review by the Editor-in-Chief of this journal on request.

Author contribution

Carlos Millan: writing paper
 Juan Forero: data collection
 Carlos Millan: study design
 Carlos Millan: data analysis
 Carlos Millan: study concept

Registration of research studies

In concordance with the Helsinki declaration this case report does not require registration in the database, in this case there is no experimentation with humans

Guarantor

Carlos Alberto Millan

References

- [1] T. Pavlis, S. Aloizos, P. Aravosita, C. Mystakelli, D. Petrochilou, N. Dimopoulos, et al., Diagnosis and surgical management of spontaneous hepatic rupture associated with HELLP syndrome, *J. Surg. Educ.* 66 (2009) 163–167.
- [2] P. Vigil-De Gracia, Maternal deaths due to eclampsia and HELLP syndrome, *Int. J. Gynecol. Obstet.* 104 (2009) 90–94.
- [3] J.L. Poo, J. Gongora, Hepatic haematoma and hepatic rupture in pregnancy, *Ann. Hepatol.* 5 (2006) 224–226.
- [4] B.D. Shames, L.A. Fernandez, H.W. Sollinger, L.T. Chin, A.M. D'Alessandro, S.J. Knechtle, et al., Liver transplantation for HELLP syndrome, *Liver Transpl.* 11 (2005) 224–228.
- [5] F.A. Marsh, S.J. Kaufmann, K. Bhabra, Surviving hepatic rupture in pregnancy—a literature review with an illustrative case report, *J. Obstet. Gynecol.* 23 (2003) 109–113.
- [6] Riaz A. Agha, Alexander J. Fowler, Alexandra Saeta, Ishani Barai, Shivanchan Rajmohan, Dennis P. Orgill, The SCARE statement: consensus-based surgical case report guidelines, *Int. J. Surg.* 34 (2016) 180–186.
- [7] B.K. Rinehart, D.A. Terrone, E.F. Magann, R.W. Martin, W.L. May, J.N. Martin, Preeclampsia-associated hepatic hemorrhage and rupture: mode of management related to maternal and perinatal outcome, *Obstet. Gynecol. Surv.* 54 (1999) 196–202.
- [8] J.G. Orea, I. Gaviño, J.L. Cardenas, A. Cuanalo, S. Brachet, Rupture of the liver and subcapsular hematoma caused by toxemia. A case successfully treated by left lobectomy, *Ann. Chir.* 38 (February (1)) (1984) 19–22.
- [9] S.G. Wilson, A.D. White, A.L. Young, M.H. Davies, S.G. Pollard, The management of the surgical complications of HELLP syndrome, *Ann. R. Coll. Surg. Engl.* 96 (October (7)) (2014) 512–516.

Open Access

This article is published Open Access at [sciencedirect.com](https://www.sciencedirect.com). It is distributed under the [IJSCR Supplemental terms and conditions](#), which permits unrestricted non commercial use, distribution, and reproduction in any medium, provided the original authors and source are credited.