



Electrical impedance tomography and trans-pulmonary pressure measurements in a patient with extreme respiratory drive



Atsuko Shono, Peter Somhorst*, Diederik Gommers

Department of Adult Intensive Care Medicine, Erasmus MC – University Medical Center, 's Gravendijkwal 230, 3015 CE Rotterdam, The Netherlands

ARTICLE INFO

Article history:

Received 8 September 2016

Received in revised form

13 January 2017

Accepted 13 January 2017

ABSTRACT

Preserving spontaneous breathing during mechanical ventilation prevents muscle atrophy of the diaphragm, but may lead to ventilator induced lung injury (VILI). We present a case in which monitoring of trans-pulmonary pressure and ventilation distribution using Electrical Impedance Tomography (EIT) provided essential information for preventing VILI.

© 2017 The Authors. Published by Elsevier Ltd. This is an open access article under the CC BY-NC-ND license (<http://creativecommons.org/licenses/by-nc-nd/4.0/>).

1. Introduction

Mechanical ventilation is a critical part of intensive care medicine, but is also known to induce injury to both the lungs and respiratory muscles. In order to minimize injury, protective ventilation strategies are employed based on low tidal volume and relative low levels of PEEP.

During controlled mechanical ventilation, when spontaneous breathing (SB) is absent, atrophy of diaphragm muscle cells has been found already after 12–72 hours after onset of mechanical ventilation [1,2]. Therefore, it has been recommended to maintain diaphragmatic activity and keep respiratory effort intact [3]. In addition, SB has been shown to improve dorsal ventilation, alveolar recruitment and oxygenation by reducing atelectasis, histological damage and cytokine production [4–10].

However, studies have demonstrated that a strong inspiratory effort can cause high trans-pulmonary pressures (P_{TP}), leading to increase in damage to the already injured lung. Yoshida et al. [11] showed in a rabbit model that SB was beneficial during mild lung injury, but harmful during severe lung injury. This was confirmed in patients with severe ARDS in which the early use of neuromuscular blocking agents (NMBA's) reduced the risk of barotrauma and improved survival [12].

Extra-corporeal membrane oxygenation (ECMO) negates the need for mechanical ventilation, allowing for more protective ventilation strategies.

To accomplish a persistent protective ventilation strategy in patients with severe hypoxemia, the monitoring of respiratory

parameters is essential, such as P_{TP} [14–16] or electrical impedance tomography (EIT) [17].

We report the case of a patient with interstitial (post-)infectious lung injury who required, as a protective lung strategy, both NMBA's and ECMO during his stay on the Intensive Care Unit (ICU).

2. Case report

The patient was a 24 years old male with no known medical history. Almost three weeks before admission, the patient went swimming in natural water and consequently developed a cough, pain while coughing and bloody sputum. He was prescribed antibiotics (amoxicillin) by his general practitioner. One week later he was admitted to the ICU department due to progressive respiratory insufficiency and increased work of breathing. He received high flow nasal cannula oxygen therapy (OptiFlow, 35 L/min, FiO_2 0.6), but had to be intubated the next day due to fatigue and was ventilated using pressure support mode. High peak pressures (34 cmH_2O) with a PEEP of 14 cmH_2O and FiO_2 of 0.7 had to be applied, resulting in a PaO_2 of 70 mmHg, SaO_2 of 96%, $PaCO_2$ of 59 mmHg and pH of 7.37. X-ray and CT imaging were assessed as bilateral tree-in-bud sign (Fig. 1). After two days of mechanical ventilation, patient was transferred to our hospital (reference center for ECMO) with the question if patient was a candidate for vv-ECMO. Since no diagnosis could be made, broad-spectrum antibiotics were given (cefotaxime, ciprofloxacin, doxycycline) and steroid therapy (methylprednisolone, 160 mg/day) was started for suspected eosinophilic pneumonia.

The patient was ventilated using pressure support ventilation with a PEEP of 18 cmH_2O and a peak airway pressure of 28 cmH_2O respectively. PaO_2 and $PaCO_2$ were both of 70 mmHg with 50% oxygen at that time. The tidal volume reached values up to 12 mL/

* Corresponding author. Department of Intensive Care, Erasmus MC – University Medical Center, Room H-602, P.O. Box 2040, 3000 CA Rotterdam, The Netherlands.
E-mail address: p.somhorst@erasmusmc.nl (P. Somhorst).

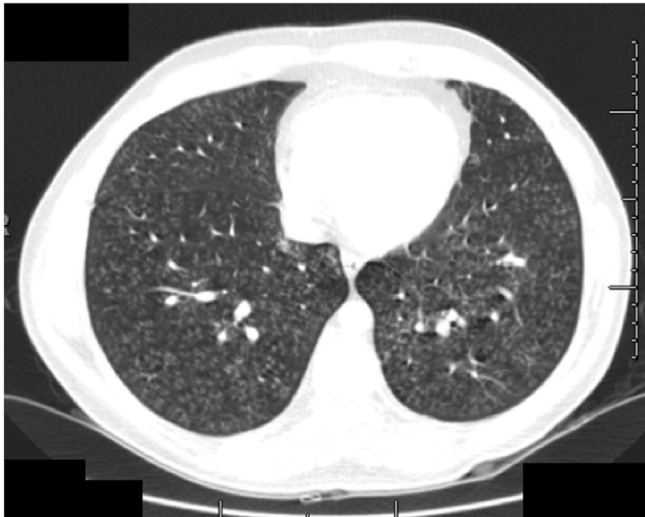

Fig. 1. CT imaging taken at initial admission to the primary hospital. The image showed miliary opacities.

kg ideal body weight due to strong inspiratory effort. Propofol and remifentanyl were increased from 240 to 400 mg/h and from 0.15 to 0.26 $\mu\text{g}/\text{kg}/\text{h}$ respectively in an attempt to reduce tidal volume. Also, the ventilator mode was switched to volume-controlled mode with a tidal volume of 480 mL (6.4 mL/kg ideal body weight). The patient had persisting spontaneous efforts in a 1:2 ratio: one spontaneous effort during every second mandatory breath (Fig. 2A). An esophageal balloon catheter (NutriVent, Sidam S.R.L., Mirandola, Italy) was inserted and P_{TP} was calculated. P_{TP} was 34 cmH₂O during inspiration and -9 cmH₂O at end expiration (Fig. 2A). Simultaneously electrical impedance tomography (EIT) measurements were performed at the 5th intercostal space (Fig. 3).

On day 4 after intubation, a bolus of rocuronium (80 mg) was administered intravenously followed by a continuous infusion (30 mg/h) due to the high P_{TP} . The ventilator mode was switched to pressure-controlled ventilation with a PEEP of 18 cmH₂O and peak airway pressure of 28 cmH₂O. P_{TP} decreased from 34 to 19 cmH₂O during inspiration and P_{TP} increased from -9 to -2 cmH₂O at end of expiration (Fig. 2B and C). TIV decreased by 65% and was more homogeneously distributed (Fig. 4). The predominant distribution

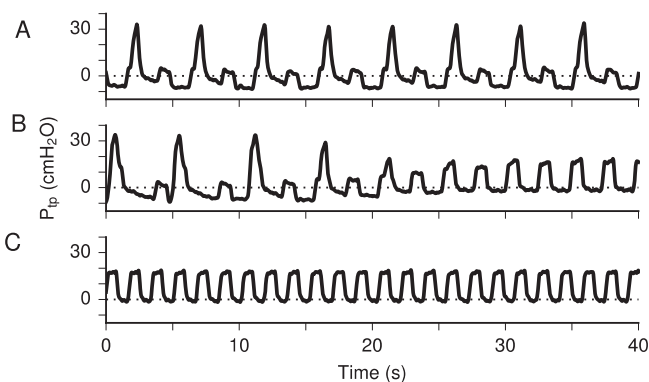


Fig. 2. Trans-pulmonary pressure (P_{TP}) waveforms before (A), during (B) and after (C) onset of rocuronium infusion. Before administration of rocuronium, the alternating spontaneous breaths and mandatory breaths are visible. During the spontaneous breaths, the P_{TP} rises to values beyond 35 cmH₂O. During the onset of rocuronium infusion the P_{TP} during spontaneous breaths quickly reduces in amplitude. After a few breaths, spontaneous effort seems to disappear completely, decreasing the peak P_{TP} to 19 cmH₂O. The P_{TP} at end-expiration increases from -9 cmH₂O to -2 cmH₂O.

of inspired gas to the dependent part during an almost entire inspiratory phase dramatically changed to even distribution to both parts after administration of rocuronium.

Despite the more protective ventilation strategy, gas exchange deteriorated (PaCO_2 of 120 mmHg, PaO_2 of 68 mmHg with an FiO_2 of 0.7). In an effort to improve gas exchange, the patient was put in prone position on day five of mechanical ventilation, without success. Immediately thereafter, the patient was put on veno-venous ECMO via the femoral vein and internal jugular vein. Blood flow was 5 L/min with a sweep gas flow of 2.5 L/min. Blood gases improved quickly (SaO_2 91%–94%, PaO_2 kept stable around 60 mmHg with an FiO_2 of 0.3, pH 7.17 to 7.53, PaCO_2 120 to 42 mmHg). During ECMO, ventilation was continued on pressure-controlled mode, with PEEP decreased from 18 to 14 cmH₂O and peak pressure from 28 to 24 cmH₂O, resulting in tidal volumes of 2.4 mL/kg. During the next five days, PEEP was reduced to 10 cmH₂O and peak pressure to 20 cmH₂O. The sedation was lowered in order to allow spontaneous breathing resulting in tidal volumes of 4.6–9.3 mL/kg. In the meanwhile, blood culture became positive for the presence of leptospirosis, for which the patient was already being treated with cefotaxime and doxycycline.

The patient slowly improved and was weaned from ECMO after 12 days (day 15 after intubation). He was weaned from the ventilator within the next five days. Another ten days later he was discharged to the ward and finally discharged from the hospital 56 days after initial admission. A definitive diagnosis was missing, but an organizing pneumonia was mentioned as the most probable cause.

3. Discussion

In this case report we describe a patient who showed great inspiratory effort during assisted mechanical ventilation. The inspiratory effort resulted in large trans-pulmonary pressure. This was dramatically decreased after the administration of muscle relaxation, also resulting in a more even distribution between the dependent and non-dependent lung as shown by EIT.

On the one hand one likes to encourage persistent diaphragmatic activity in order to prevent VIDD. On the other hand, it is known that an increased respiratory drive — resulting in high P_{TP} — causes mechanical stress in the lung, which may contribute to ventilator-induced lung injury (VILI). In an experimental sheep study, induced spontaneous hyperventilation induced reduced compliance and severe lung edema, finally leading to death, whereas none of the sheep who received muscle relaxant after induced hyperventilation and controlled mechanical ventilation with a fixed low tidal volume developed lung edema and all animals survived [22]. Another experimental study showed that the same level of inflation as during spontaneous breathing (6 mL/kg), during muscle paralysis 2–3 times higher driving pressures (28 vs 10 cmH₂O) and 2–3 times larger tidal volumes (15 vs 6 mL/kg) were required, indicating overstretching of the dependent lung regions due to spontaneous effort [23]. Similarly, in this case the TIV in the dependent lung regions before administration of an NMBA was 3.8 times higher as compared to the TIV after NMBA administration. Additionally, the peak P_{TP} was 10 cmH₂O higher than the physiological limit of 25 cmH₂O [16], but was reduced to below this physiological limit after NMBA administration.

These findings suggest that muscle paralysis plays an important role as part of the ventilation strategy to decrease the risk of VILI in patients with significant spontaneous effort. It is apparent that the protective effect of muscle paralysis is case-specific and requires extensive monitoring [24]. Monitoring of ventilation distribution may be important in all patients with high respiratory effort for clinical decision-making regarding the ventilation strategy, such as

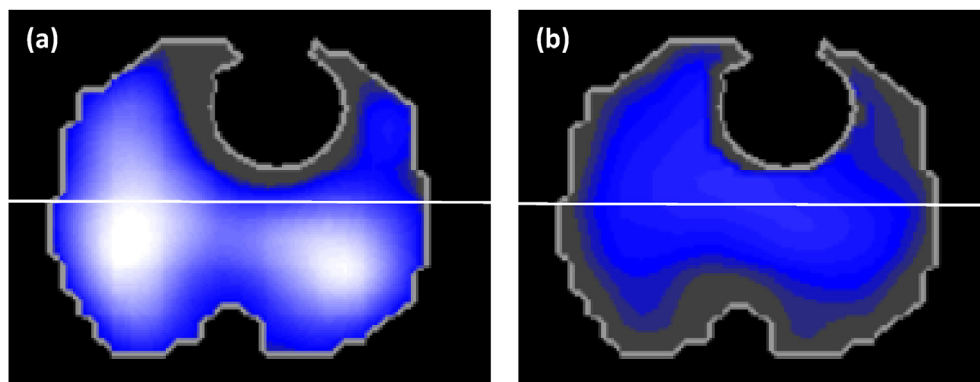


Fig. 3. EIT ventilation distribution map before and after administration of rocuronium. The image represent a transverse plane at the level of the 5th intercostal space. Anatomical positioning is equal to CT imaging. Dark grey areas indicate no ventilation. White areas indicate high TIV, with decreasing TIV towards darker colors. (a) The fraction of regional TIV before administration of rocuronium was 25% and 75% in the non-dependent and the dependent regions, respectively. (b) After administration of rocuronium, global TIV decreased to 35% of that of before administration. The fraction of distribution of global TIV after rocuronium administration was 43% and 57% in the non-dependent and the dependent regions, respectively. (For interpretation of the references to colour in this figure legend, the reader is referred to the web version of this article.)

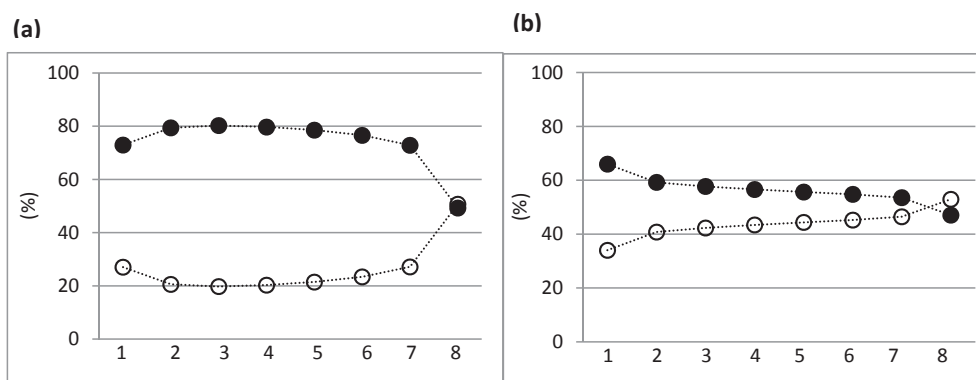


Fig. 4. Intratidal gas distribution (a) before and (b) after administration of rocuronium. The intratidal gas distribution describes the regional gas distribution during an inspiration. The global tidal impedance changes were divided into eight iso-volume sections. The corresponding time points of the eight iso-volume steps are translated to the regional TIV changes and the percentile contribution of the dependent and non-dependent regions was calculated and plotted. (a) The graph shows the predominant distribution of inspired gas to the dependent part during an almost entire inspiratory phase. (b) Inspired gas distributed equivalently to both parts of the lungs after administration of rocuronium. Dashed lines represents the interpolation lines; open circles = non-dependent region; solid circles = dependent region.

prone positioning and application of lung-replacing therapy like ECMO.

Although the spatial resolution is limited, EIT can accurately visualize changes in aeration and regional ventilation [19,25]. Most importantly, it is non-invasive and more readily available compare to the golden standard, computed tomography imaging. In the case we presented, EIT imaging clearly showed inhomogeneous ventilation indicating overstretch in the dorsal parts of the lung. Measurement of the P_{TP} confirmed that the inhomogeneous ventilation distribution was associated with increased pressure surpassing physiological limits.

P_{TP} measurements are regarded as an important value to respiratory monitoring [14,16,24,26–28]. The esophageal pressure — used to calculate P_{TP} — is generally overestimated in supine patients, requiring a correction of approximately 5 cmH₂O [14]. The P_{TP} that is presented in this report are not corrected for that underestimation. However, a difference of approximately 5 cmH₂O does not change the interpretation of the values of the P_{TP} or the chosen course of treatment.

In summary, administration of NMBA's increased the homogeneity of ventilation distribution and reduced peak P_{TP} in a patient with strong spontaneous effort. Inhomogeneous ventilation can be detected at the bedside using EIT imaging. Monitoring of the regional ventilation and trans-pulmonary pressure could provide

useful information in determining personalized ventilation strategies.

References

- [1] S. Jaber, B.J. Petrof, B. Jung, G. Chanques, J.-P. Berthet, C. Rabuel, et al., Rapidly progressive diaphragmatic weakness and injury during mechanical ventilation in humans, *Am. J. Respir. Crit. Care Med.* 183 (2011) 364–371, <http://dx.doi.org/10.1164/rccm.201004-0670OC>.
- [2] S. Levine, T. Nguyen, N. Taylor, M.E. Friscia, M.T. Budak, P. Rothenberg, et al., Rapid disuse atrophy of diaphragm fibers in mechanically ventilated humans, *N. Engl. J. Med.* 358 (2008) 1327–1335, <http://dx.doi.org/10.1056/NEJMoa070447>.
- [3] M.J. Tobin, F. Laghi, A. Jubran, Narrative review: ventilator-induced respiratory muscle weakness, *Ann. Intern. Med.* 153 (2010) 240–245, <http://dx.doi.org/10.7326/0003-4819-153-4-201008170-00006>.
- [4] P. Neumann, H. Wrigge, J. Zinserling, J. Hinz, E. Maripuu, L.G. Andersson, et al., Spontaneous breathing affects the spatial ventilation and perfusion distribution during mechanical ventilatory support, *Crit. Care Med.* 33 (2005) 1090–1095.
- [5] H. Wrigge, J. Zinserling, P. Neumann, J. Defosse, A. Magnusson, C. Putensen, et al., Spontaneous breathing improves lung aeration in oleic acid-induced lung injury, *Anesthesiology* 99 (2003) 376–384.
- [6] H. Wrigge, J. Zinserling, P. Neumann, T. Muders, A. Magnusson, C. Putensen, et al., Spontaneous breathing with airway pressure release ventilation favors ventilation in dependent lung regions and counters cyclic alveolar collapse in oleic-acid-induced lung injury: a randomized controlled computed tomography trial, *Crit. Care* 9 (2005) R780–R789, <http://dx.doi.org/10.1186/cc3908>.
- [7] F. Saddy, G.P. Oliveira, C.S.N.B. Garcia, L.M. Nardelli, A.F. Rzezinski, D.S. Ornellas, et al., Assisted ventilation modes reduce the expression of lung

- inflammatory and fibrogenic mediators in a model of mild acute lung injury, *Intensive Care Med.* 36 (2010) 1417–1426, <http://dx.doi.org/10.1007/s00134-010-1808-6>.
- [8] P.M. Spieth, A.R. Carvalho, A. Güldner, M. Kasper, R. Schubert, N.C. Carvalho, et al., Pressure support improves oxygenation and lung protection compared to pressure-controlled ventilation and is further improved by random variation of pressure support, *Crit. Care Med.* 39 (2011) 746–755, <http://dx.doi.org/10.1097/CCM.0b013e318206bda6>.
- [9] J. Xia, B. Sun, H. He, H. Zhang, C. Wang, Q. Zhan, Effect of spontaneous breathing on ventilator-induced lung injury in mechanically ventilated healthy rabbits: a randomized, controlled, experimental study, *Crit. Care* 15 (2011) R244, <http://dx.doi.org/10.1186/cc10502>.
- [10] C. Putensen, C. Putensen, N.J. Mutz, G. Putensen-Himmer, J. Zinserling, Spontaneous breathing during ventilatory support improves ventilation-perfusion distributions in patients with acute respiratory distress syndrome, *Am. J. Respir. Crit. Care Med.* 159 (1999) 1241–1248, <http://dx.doi.org/10.1164/ajrccm.159.4.9806077>.
- [11] T. Yoshida, A. Uchiyama, N. Matsuura, T. Mashimo, Y. Fujino, The comparison of spontaneous breathing and muscle paralysis in two different severities of experimental lung injury, *Crit. Care Med.* 41 (2013) 536–545, <http://dx.doi.org/10.1097/ccm.0b013e3182711972>.
- [12] L. Papazian, J.-M. Forel, A. Gacouin, C. Penot-Ragon, G. Perrin, A. Loundou, et al., Neuromuscular blockers in early acute respiratory distress syndrome, *N. Engl. J. Med.* 363 (2010) 1107–1116, <http://dx.doi.org/10.1056/NEJMoa1005372>.
- [14] S.P. Keller, H.E. Fessler, Monitoring of oesophageal pressure, *Curr. Opin. Crit. Care* 20 (2014) 340–346, <http://dx.doi.org/10.1097/MCC.0000000000000092>.
- [15] E. Akoumianaki, S.M. Maggiore, F. Valenza, G. Bellani, A. Jubran, S.H. Loring, et al., The application of esophageal pressure measurement in patients with respiratory failure, *Am. J. Respir. Crit. Care Med.* 189 (2014) 520–531, <http://dx.doi.org/10.1164/rccm.201312-2193CI>.
- [16] S. Grasso, P. Terragni, A. Birocco, R. Urbino, L. Del Sorbo, C. Filippini, et al., ECMO criteria for influenza A (H1N1)-associated ARDS: role of transpulmonary pressure, *Intensive Care Med.* 38 (2012) 395–403, <http://dx.doi.org/10.1007/s00134-012-2490-7>.
- [17] P. Blankman, D. Gommers, Lung monitoring at the bedside in mechanically ventilated patients, *Curr. Opin. Crit. Care* 18 (2012) 261–266, <http://dx.doi.org/10.1097/MCC.0b013e3283534a4a>.
- [19] J.A. Victorino, J.B. Borges, V.N. Okamoto, G.F.J. Matos, M.R. Tucci, M.P.R. Caramez, et al., Imbalances in regional lung ventilation: a validation study on electrical impedance tomography, *Am. J. Respir. Crit. Care Med.* 169 (2004) 791–800, <http://dx.doi.org/10.1164/rccm.200301-1330C>.
- [22] D. Mascheroni, T. Kolobow, R. Fumagalli, M.P. Moretti, V. Chen, D. Buckhold, Acute respiratory failure following pharmacologically induced hyperventilation: an experimental animal study, *Intensive Care Med.* 15 (1988) 8–14, <http://dx.doi.org/10.1007/BF00255628>.
- [23] T. Yoshida, V. Torsani, S. Gomes, R.R. De Santis, M.A. Beraldo, E.L.V. Costa, et al., Spontaneous effort causes occult pendelluft during mechanical ventilation, *Am. J. Respir. Crit. Care Med.* 188 (2013) 1420–1427, <http://dx.doi.org/10.1164/rccm.201303-0539OC>.
- [24] S. Hraiech, T. Yoshida, L. Papazian, Balancing neuromuscular blockade versus preserved muscle activity, *Curr. Opin. Crit. Care* 21 (2015) 26–33, <http://dx.doi.org/10.1097/MCC.0000000000000175>.
- [25] H. Wrigge, J. Zinserling, T. Muders, D. Varelmann, U. Günther, C. von der Groeben, et al., Electrical impedance tomography compared with thoracic computed tomography during a slow inflation maneuver in experimental models of lung injury, *Crit. Care Med.* 36 (2008) 903–909, <http://dx.doi.org/10.1097/CCM.0B013E3181652EDD>.
- [26] J.O. Benditt, Esophageal and gastric pressure measurements, *Respir. Care* 50 (2005) 68–75. — discussion 75–77.
- [27] A. Soroksky, A. Esquinas, Goal-directed mechanical ventilation: are we aiming at the right goals? A proposal for an alternative approach aiming at optimal lung compliance, guided by esophageal pressure in acute respiratory failure, *Crit. Care Res. Pract.* 2012 (2012) 597932–597939, <http://dx.doi.org/10.1155/2012/597932>.
- [28] D. Talmor, T. Sarge, C.R. O'Donnell, R. Ritz, A. Malhotra, A. Lisbon, et al., Esophageal and transpulmonary pressures in acute respiratory failure, *Crit. Care Med.* 34 (2006) 1389–1394, <http://dx.doi.org/10.1097/01.CCM.0000215515.49001.A2>.