Clin Kidney J (2013) 6: 547–548
doi: 10.1093/ckj/sft086
Advance Access publication 14 August 2013

CKJ

Images in Nephrology
(Section Editor: G. H. Neild)

Page kidney phenomenon secondary to an atypical presentation of Erdheim-Chester disease

Shaifali Sandal and Martin S. Zand

Division of Nephrology, School of Medicine and Dentistry, University of Rochester Medical Center, Rochester, NY, USA

Correspondence and offprint requests to: Shaifali Sandal; E-mail: shaifali_sandal@URMC.rochester.edu

A 50-year-old man with a 6-month history of arthralgias, recurrent pericardial and pleural effusions presented to the nephrology clinic with uncontrolled hypertension and elevated creatinine. No proteinuria or hematuria was noted. Computed tomography (CT) scan of the abdomen showed a hypodense tissue encasing both kidneys (Figure 1A). Tissue biopsy revealed a fibroproliferative process, dense fibrosis and focal collections of histiocytes (Figure 1B). These histiocytes had a dense amphophilic cytoplasm, but were not foamy. Given our clinical impression, specific immunostains were performed. Histiocytes stained positive for CD68 (Figure 1C) and factor XIIIa, and negative for CD1a, Alk-1 and S-100. Findings were consistent with Erdheim-Chester disease (ECD) and the patient underwent a trial of interferon therapy with minimal improvement and subsequently imitinab therapy with some stabilization of symptoms.

ECD is a systemic, infiltrative disease, characterized classically by foamy histiocytes, with immunohistochemical characteristics different from those of Langerhans cell (LC) histiocytosis [1]. LC expresses proteins CD1a and S100 and demonstrates the presence of Birbeck granules [1, 2]. ECD is composed of histiocytes that express evidence of phagocytic differentiation, hence stain positive for CD68, but lack proteins CD1a and S100 and Birbeck granules [1, 2]. ECD shows a tropism for connective, adipose and perivascular tissues, almost always involves bone with characteristic osteosclerosis of long bones and can present with potentially life-threatening complications, such as heart failure and tamponade [1, 2]. Renal and perirenal involvement was found in 29% of patients [2]. The morphologic and clinical presentation is different from IgG4-related disease that consists of a lymphoplasmacytic infiltrate [3]. The treatment of ECD usually includes steroids and immunomodulating medications, and surgical decompression has been reported to preserve renal function [4].

Page kidney phenomenon is the extrinsic compression of the renal parenchyma leading to hypertension, via activation of the renin–angiotensin–aldosterone system [5]. Often caused by hemorrhage and malignancies, in our patient it was from the infiltration around the kidneys.

Conflict of interest statement. None declared.

(See related article by Samson et al. Perirenal fibrosis: make your diagnosis. *Clin Kidney J* 2013; 6: 543–544)

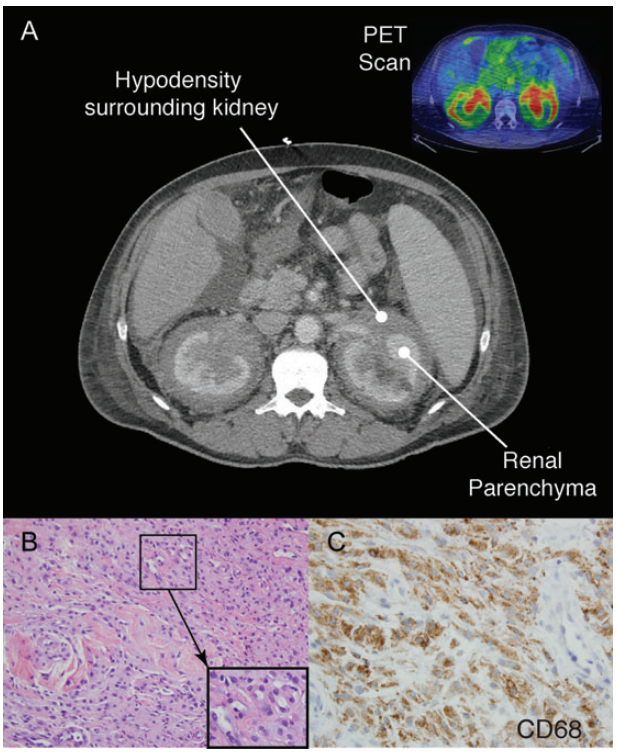

Fig. 1: (**A**) CT image of the abdomen showed a dense collection encasing the kidneys bilaterally, and inset shows the positron emission tomography scan. (**B**) Hematoxylin and eosin stain of the tissue biopsy revealed a fibroproliferative process, and focal collections of histiocytes with dense amphophilic cytoplasm but were not 'foamy'. (**C**) Immunohistochemical stains demonstrated these histiocytes stained positive for CD68.

References

1. Dion E, Graef C, Haroche J *et al*. Imaging of thoracoabdominal involvement in Erdheim-Chester disease. *AJR. Am J Roentgenol* 2004; 183: 1253–1260
2. Veyssier-Belot C, Cacoub P, Caparros-Lefebvre D *et al*. Erdheim-Chester disease. Clinical and radiologic characteristics of 59 cases. *Medicine* 1996; 75: 157–169

3. Stone JH, Zen Y, Deshpande V. IgG4-related disease. *N Engl J Med* 2012; 366: 539–551
4. Wimpissinger TF, Schernthaner G, Feichtinger H *et al*. Compression of kidneys in Erdheim-Chester disease of retroperitoneum: open surgical approach. *Urology* 2005; 65: 798
5. Smyth A, Collins CS, Thorsteinsdottir B *et al*. Page kidney: etiology, renal function outcomes and risk for future hypertension. *J Clin Hypertens* 2012; 14: 216–221

Received for publication: 23.4.13; Accepted in revised form: 3.7.13