

Available online at www.sciencedirect.com

ScienceDirect

journal homepage: www.elsevier.com/locate/ajur

Review

Artificial intelligence for renal cancer: From imaging to histology and beyond



Karl-Friedrich Kowalewski ^{a,1}, Luisa Egen ^{a,1},
 Chanel E. Fischetti ^b, Stefano Puliatti ^{c,d}, Gomez Rivas Juan ^e,
 Mark Taratkin ^f, Rivero Belenchon Ines ^g,
 Marie Angela Sidoti Abate ^a, Julia Mühlbauer ^a,
 Frederik Wessels ^a, Enrico Checcucci ^h, Giovanni Cacciamani ^{i,*}
 on behalf of the Young Academic Urologists (YAU)-
 Urotechnology-Group

^a Department of Urology and Urological Surgery, University Medical Centre Mannheim, Mannheim, Germany

^b Department of Emergency Medicine, Brigham and Women's Hospital, Harvard Medical School, Boston, MA, USA

^c Urology Department, University of Modena & Reggio Emilia, Modena, Italy

^d ORSI Academy, Melle, Belgium

^e Department of Urology, Hospital Clinico San Carlos, Madrid, Spain

^f Institute for Urology and Reproductive Health, Sechenov University, Moscow, Russia

^g Urology and Nephrology Department, Virgen del Rocío University Hospital, Manuel Siurot s/n, Seville, Spain

^h Department of Surgery, Candiolo Cancer Institute, FPO-IRCCS, Candiolo, Turin, Italy

ⁱ USC Institute of Urology, University of Southern California, Los Angeles, CA, USA

Received 30 January 2022; received in revised form 7 April 2022; accepted 7 May 2022

Available online 18 June 2022

KEYWORDS

Kidney cancer;
 Imaging;
 Technology;
 Artificial intelligence;
 Machine learning

Abstract Artificial intelligence (AI) has made considerable progress within the last decade and is the subject of contemporary literature. This trend is driven by improved computational abilities and increasing amounts of complex data that allow for new approaches in analysis and interpretation. Renal cell carcinoma (RCC) has a rising incidence since most tumors are now detected at an earlier stage due to improved imaging. This creates considerable challenges as approximately 10%–17% of kidney tumors are designated as benign in histopathological evaluation; however, certain co-morbid populations (the obese and elderly) have an increased

* Corresponding author.

E-mail address: Giovanni.Cacciamani@med.usc.edu (G. Cacciamani).

Peer review under responsibility of Tongji University.

¹ These authors equally contributed to the article.

<https://doi.org/10.1016/j.ajur.2022.05.003>

2214-3882/© 2022 Editorial Office of Asian Journal of Urology. Production and hosting by Elsevier B.V. This is an open access article under the CC BY-NC-ND license (<http://creativecommons.org/licenses/by-nc-nd/4.0/>).

peri-interventional risk. AI offers an alternative solution by helping to optimize precision and guidance for diagnostic and therapeutic decisions. The narrative review introduced basic principles and provide a comprehensive overview of current AI techniques for RCC. Currently, AI applications can be found in any aspect of RCC management including diagnostics, perioperative care, pathology, and follow-up. Most commonly applied models include neural networks, random forest, support vector machines, and regression. However, for implementation in daily practice, health care providers need to develop a basic understanding and establish interdisciplinary collaborations in order to standardize datasets, define meaningful endpoints, and unify interpretation.

© 2022 Editorial Office of Asian Journal of Urology. Production and hosting by Elsevier B.V. This is an open access article under the CC BY-NC-ND license (<http://creativecommons.org/licenses/by-nc-nd/4.0/>).

1. Introduction

1.1. Renal cell carcinoma (RCC)

RCCs make up 3.0% of all known cancer cases with a worldwide increasing incidence of 2.0% per year [1]. Currently, the highest occurrence is noted in North America and Western Europe, while an emerging disease burden can be seen for Latin America, Asia, and Africa as adaption to the Western lifestyle proceeds [2]. As of 2018, RCCs account for 1.8% of global cancer deaths with approximately 114 000 and 61 000 deaths in men and women, respectively. After a peak in mortality rates of 4.3/100 000 in the early 1990s, a continuous decline was noted most likely due to advancing diagnostic modalities and treatment options [3].

Histopathology of RCC comprises numerous entities with clear cell, papillary, and chromophobe RCC being the most common subtypes [4]. Important benign lesions constitute angiomyolipomas and oncocytomas that occur in 0.4% and 3.0%–7.0% of solid renal tumors [5]. In the context of emerging and novel therapeutic agents, pre-therapeutic classification of RCC subtypes becomes increasingly relevant [6].

Approximately 60% of RCC are diagnosed incidentally due to the frequent use of imaging modalities [7]. Thus, detection of renal tumors shows a decreasing trend in tumor size and stage, while the incidence of small renal masses (SRMs) rises [8]. Symptoms such as flank pain, hematuria, and palpable tumors have become rare and may indicate advanced disease [4]. SRMs can be defined as contrast-enhancing lesions with a maximum diameter of 4 mm [9] that are typically characterized by a slow growth rate, low malignant potential, and an increasing risk for metastatic disease above 3 mm [10].

Concerning SRM, the concept of active surveillance becomes increasingly relevant especially for the elderly and comorbid patients, who have higher associated peri-interventional risk factors [11]. Jewett et al. [12] reported low local progression rates and rare occurrence of metastases in 2-year follow-up in a study of 178 patients under active surveillance.

The choice for the treatment of localized RCC is surgical resection, while nephron-sparing approach is preferred whenever possible to preserve renal function. However,

10%–17% of kidney tumor specimens are designated benign by histopathological evaluation [13]. Thus high precision in diagnostic evaluation is needed in order to enable adequate oncological management and prevent overtreatment.

Prior to active surveillance, a renal mass biopsy (RMB) can be performed in order to identify the risk of progression depending on histopathological subtype and stage [14]. Additionally, before initiation of ablative or systemic treatment, histological confirmation is required using RMB [15]. The role of RMB in advance of surgical treatment is controversial. In a large retrospective, multicenter study including 516 patients after surgery of SRM, Richard et al. [16] described a lower rate of postoperatively identified benign tumors when routine RMB was performed preoperatively. However, RMB as invasive diagnostic tool can incur risks, such as tumor seeding, development of perinephric hematomas, or bleeding. Marconi et al. [17] conveyed a systematic review and meta-analysis including data of 57 studies showing a low rate of hematomas (4.3%) and rare occurrence of clinically significant bleeding (0–1.4%). Diagnostic accuracy of RMB in terms of sensitivity and specificity to detect malignancy was high with 99.1% and 99.7%, respectively. On the other hand, in a study by Moch et al. [5], only 64.6% of oncocytomas diagnosed by RMB were found to be benign lesions by histopathological evaluation after surgical resection. Therefore, diagnostic methods of RCC need to be refined in order to obtain pre-therapeutic diagnostic accuracy for adequate disease management, while simultaneously reducing invasiveness.

1.2. Basics of artificial intelligence (AI) and machine learning (ML)

AI is broadly defined as the ability of machines to perform tasks and solve problems for which they have not been explicitly programmed. Recently, AI and its subdomain ML have seen a tremendous rise in medical utility within the last decade [18,19]. However, these methods are often criticized to be a black box which is poorly understood, especially by medical staff [20]. Still, the majority of algorithms follow basic principles that are easy to understand, even without a strong background in mathematics or statistics (Fig. 1). Nevertheless, a major problem is that the actual decision-making of the applied AI method itself is

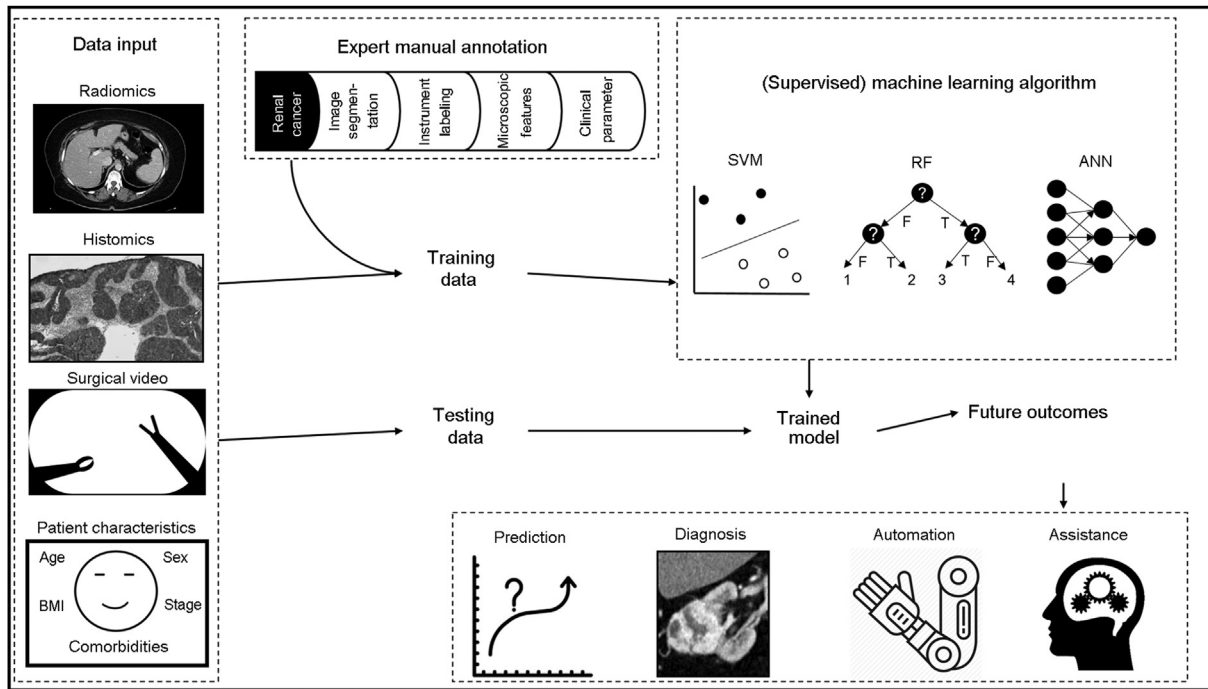


Figure 1 Basic principles of supervised ML models for renal cancer. Available data from different aspects of clinical care can be used as input. Following manual annotation, ML algorithms are trained to create the models. Unused test data are used for validation and to determine the final model which can assist during care of future patients (adopted from Garrow et al. [21]). 1253 mm×714 mm (38×38 DPI). SVM, support vector machine; RF, random forest; ANN, artificial neural networks; ML, machine learning; BMI, body mass index.

often very difficult to comprehend (especially in deep learning [DL] methods) which represents a relevant hurdle for clinical implementation, especially with regard to medical product laws.

To start, all algorithms first need data. This includes not only traditional data such as baseline patient characteristics (*i.e.*, age or comorbidities), but any information that can be documented during the course of (surgical) treatment, which can include surgical video, staff participation, intra-peritoneal pressure, or table position [21]. The application of AI to the amount and variety of data affords new opportunities and insights into the interpretation and complexity of data often overlooked by the human eye. It should be noted, however, that the importance of high data quality cannot be emphasized enough. An AI model is only as good as the data it is trained on. Before (supervised) AI models can be trained, available data usually undergo some kind of pre-processing, such as segmentation or annotation by human experts. During this step, raw data need to be labeled with meta-data that contain identifiers, time stamps, segmentations, and/or frames [22]. The process of annotation is time-consuming and represents a major drawback for the implementation of AI as meaningful assistance in real-world settings [23–25]. However, once the data are in their final form, they are usually divided into training and test sets. This step is crucial to avoid overfitting of the models. Overfitting is observed when models achieve high performance on the training data, while showing poor performance when applied to (unseen) test data [26]. Based on the results of the test set, the final model can be chosen

and applied to future data for either classification of binary data (“Will complications occur postoperatively?”) or regression in instances of continuous data (“How long will the hospital stay be?”) [27,28]. In contrast to supervised models, unsupervised models are used to recognize pattern within data (clustering) and follow different principles that are beyond the scope of this review. Last but not least, it should be mentioned that statistical models and ML should not be used synonymously, despite some similarities and depending on different definitions in the literature. Broadly, statistical models aim at characterizing the relationship between observations, which is termed inference; in contrast, ML models are concerned with prediction. In addition, statistical models make assumptions about normality, linearity, or residuals that are not needed when applying ML approaches [29,30].

1.3. Aim

Aim of the current non-systematic narrative review was to provide a comprehensive overview of current AI and ML techniques for RCC. In the following, applications of AI during the process from diagnosis, treatment, histology, and follow-up were discussed (Fig. 2).

2. Imaging

Different imaging modalities are necessary for RCC diagnosis. Ultrasound is a valid screening method that can

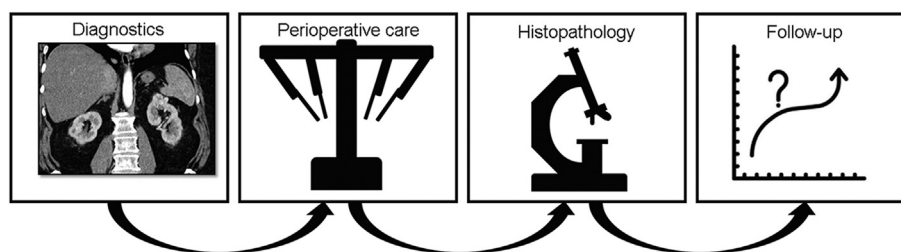


Figure 2 Applications of artificial intelligence during the course of treatment. 401 mm×112 mm (38×38 DPI).

reliably distinguish between solid and cystic renal lesions. However, for definitive diagnosis, cross-sectional imaging, such as computed tomography (CT) or magnetic resonance imaging (MRI) is required [31].

Multiphase contrast-enhanced CT imaging is recommended as gold standard for RCC, which offers specific enhancement characteristics captured in serial imaging of pre-contrast, corticomedullary, nephrographic, and (facultative) excretory phases [32]. Sensitivity for the detection of renal masses is at about 90% and even higher for lesions greater than 2 cm [33]. However, the challenge of an RCC diagnosis is not only in its detection, but more importantly, in the subtype division. Homogeneity, vascularization, and enhancement patterns are common features and histological subtypes of renal biopsies, but as of now, accurate distinction of renal lesions is not reliable, especially SRM [31]. MRI is utilized only in cases where the patient has an allergy to contrast medium, impaired renal function, or suspected renal vein infiltration or thrombus [34]. Unlike CT, MRI has added value because of its ability to differentiate between solid and cystic masses. According to the study by Kaur et al. [32], the diagnostic accuracy of MRI in relation to RCC subtype discrimination offers sensitivities as high as 86%–90% and specificities of 76.2%–93.8%.

Recently, the use of multi-parametric MRI (mpMRI) has been introduced as an auxiliary tool to overcome present limitations of conventional CT and MRI. mpMRI uses features, such as T2-weighted signals and apparent diffusion coefficient signals to differentiate subtle characteristics (e.g., thin septa or contrast enhancement) with higher accuracy [31]. Kay et al. [35] demonstrated an 81% diagnostic accuracy for detecting clear cell and a 91% diagnostic accuracy for detecting papillary RCC using mpMRI. Similarly, Cornelis and Grenier [36] reported a 100% detection rate for fat-poor angiomyolipomas with 89% specificity. Additionally, the use of contrast-enhanced ultrasound, optical coherence tomography, and positron-emission tomography are presented in literature with limited use in clinical practice.

Contrast-enhanced ultrasound offers the advantage of a non-invasive method with excellent temporal and spatial resolution and high predictive value of renal lesions [37]. However, the differentiation of benign versus malignant lesions was poor [38]. The administration of optical coherence tomography, a method creating two- or three-dimensional images by capturing low-coherent, emitted light from biological tissue, has been analyzed in studies and showed promising results concerning the characterization of benign renal tumors, though literature remains limited [32].

In general, radiologic reports are highly dependent on the radiologist's subjective interpretation and experience [39]. As a solution, radiomics comprises various parameters, such as voxel, texture, and histogram analysis, in order to extract more information from conventional CT or MRI imaging than perceptible with the human eye [40]. Radiomics follows the predefined steps of image acquisition, identifying volume of interest, segmentation (computer-aided edge detection followed by manual correction), quantitative data extraction, and building databases [41]. It is an innovative concept in oncology for cancer detection, diagnostic as well as prognostic assessment, and monitoring treatment response.

As aforementioned, one of the biggest challenges in diagnosing RCC has been in differentiating between benign and malignant lesions to prevent overtreatment. A systematic review and meta-analysis conducted by Mühlbauer et al. [42] reported promising results for the discrimination of angiomyolipoma from RCC and oncocytoma from RCC with the log of the odds ratios of 2.89 and 3.08, respectively. In a pooled analysis of 30 studies discriminating between benign and malignant lesions, the log of the odds ratio was 3.17 ($p < 0.001$) [42]. Ma et al. [43] analyzed data of 84 histopathologically examining renal masses and showed that radiomics-based evaluation was superior to conventional CT analysis in differentiating fat-poor angiomyolipoma from clear cell RCC. In another study investigating imaging follow-up under systemic therapy, Goh et al. [44] identified CT texture analysis as an independent predictor of tumor progression and response to targeted therapy.

Despite the evaluation of large data sets, radiomics is still limited by the necessity to manually predefine quantitative metrics. The utilization of ML algorithms and DL promotes further automatization, as images are examined on the basis of AI pattern recognition [13]. With regards to prostate cancer, AI has been used to detect malignancy on mpMRI with high accuracy [45] or predict cancer grading with comparable precision to expert radiologists [46]. The preparation of raw data for ML based analysis includes a specific workflow (see [supplementary fig. 1](#)). After data acquisition, the first step was the segmentation of medical images followed by image annotation of regions of interests [23]. Afterward specific features are to be extracted based on enhancement or voxel characteristics such as histogram distribution, skewness, and kurtosis [47]. Hereby a model is created relating annotations with feature details. This procedure can be facilitated by DL algorithms that extract information from annotated data and can identify further features of predictive value [13]. The model then needs to

be validated as these algorithms can improve and revise themselves through experience. For this purpose, one database is divided into a training and a validation set. The final model is then applied to the test data set. Finally, in order to implement in clinical practice, the model needs to be externally validated [23].

Li et al. [48] analyzed the benefit of radiomics for differential diagnosis of chromophobe RCC and renal oncocytoma using multiphase CT scans of 61 patients and applied five ML algorithms (K-nearest neighbors, support vector machine, random forest, logistic regression, and multi-layer perception). All ML models proved high diagnostic accuracy, especially when combining data from corticomedullary and nephrographic phases [48]. Nassiri et al. [49] presented a radiomic-based ML algorithm tested on 684 patients as feasible tool to discriminate dignity of renal masses with an area under the curve (AUC) of 0.84. Numerous studies have investigated ML and DL algorithms as future tools for assessing RCC subtype classification [50,51], Fuhrman grade [52], and prognosis [53], and showed promising results. In a study of 217 patients with pathologically confirmed renal tumors, Xu et al. [13] compared diagnostic accuracy of distinguishing benign from malignant masses by radiomics-based models including random forest and DL to radiologists' evaluation. Best results were obtained for the combination of the two imaging sets using DL and radiomics with an AUC of 0.925 and 0.826, respectively, outperforming assessment of the two radiologists (AUC 0.724 and 0.667) [13]. A systematic review conducted by Kocak et al. [54] analyzed the methodologic quality of 30 studies on the application of AI for renal mass characterization and highlighted the importance of the implementation of AI for clinical integration.

3. Perioperative applications

During the perioperative phase, AI algorithms can be useful in workflow recognition, detection, and the visualization of at-risk structures, and can also be used to differentiate tissue during surgery. During the postoperative care, intraoperatively recorded parameters and events may help to predict the risk for complications. According to the study by Doyle and Kavoussi [55], the optimal AI system would incorporate all of the aforementioned features in order to provide real-time assistance. Such a system would need to be able to recognize a patients' individual anatomy, track surgical tools, and adapt continuously to the changing intraoperative environment. However, today's technology is not yet progressed enough to make this vision a reality. However, promising research has addressed the next steps in actualizing this potential; an excerpt of these studies is summarized below.

3.1. Surgical workflow recognition

In order to provide surgeons with real-time feedback, automated workflow recognition is crucial. Garrow et al. [21] provided a comprehensive overview of currently applied ML algorithms and useable data streams to enable surgical phase recognition. They found that the most

commonly used input data were surgical videos and manual annotation of instruments when applied to artificial neural networks and hidden Markov models. Other studies evaluated armbands attached to the surgeon's forearm or infrared sensors for workflow detection [56,57]. Specific to surgical technique, Nakawala et al. [58] applied "Deep-Onto" to surgical videos to obtain a comprehensive surgical workflow with context recognition in order to not only detect surgical phases, but also the steps, anatomy, instruments, and actions involved in completing specific tasks. The "Deep-Onto" platform was described as framework for DL models and knowledge management tools. The authors used more than 700 000 frames derived from nine full robotic-assisted partial nephrectomy (RAPN) videos that were annotated. Subsequently, ten different surgical phases were defined and the data were divided into training, validation, and test sets. The trained models achieved average success rates when predicting the RAPN steps of 74.0% for precision (positive predictive value) and 74.3% for accuracy. In another study, Zhao et al. [59] built ML models in order to predict the operating time for a broad range of procedures including radical nephrectomy and RAPN. Preoperatively available patient- and procedure-specific parameters (e.g., tumor localization and comorbidities) were used as training data for the ML models (e.g., random forest, regression, and neural networks). All ML models showed a better prediction compared to the baseline model (which included scheduled case duration, previous average case durations, and surgeon adjustments). Consequently, the authors estimated that the rate of accurately planned cases can be increased from 35% to over 50%. Focusing on surgical outcomes, Bhandari et al. [60] conducted a multi-institutional study to predict intraoperative and postoperative events for patients undergoing RAPN. ML models comprising logistic regression, random forest, and neural networks were trained with patient demographics and preoperative data to predict intraoperative events, while all of the three were then used to predict postoperative events. Overall, data from 1690 patients with 59 variables were available. The best models to predict intraoperative events achieved performance metrics of 0.858 (AUC) and 0.590 (precision-recall curve), while models for postoperative events achieved values as high as 0.875 (AUC) and 0.706 (precision-recall curve), respectively.

Notably, one of the greatest setbacks to AI or ML integration is the availability of ready-to-use input data for the training of the AI models. Ross et al. [61] suggested one solution to overcome this bottleneck of manual annotation and labeling of data. The authors demonstrated that by the use of self-supervised learning and a conditional generative adversarial network on unlabeled data (porcine nephrectomies from the EndoVis 2017 Robotic Instrument Segmentation Challenge), the required amount of labeled data (image data in this case) can be reduced by approximately 75% [61]. Additionally, reliable data may also be captured by recording motion of surgical instruments during the procedure itself. Hung and his group [62,63] pioneered in this field and implemented AI methods for an interpretation of automated performance metrics derived from robotic

instruments to predict postoperative outcomes after radical prostatectomy. In another study, they were able to show that these metrics may also be used to differentiate between experience during RAPN [64].

3.2. AI to enable augmented reality assistance

The idea of superimposing virtual models during RAPN has been described before [65–67]. Nosrati et al. [68] described a technique to augment the surgeon's endoscopic view by visualizing anatomical structures such as vessels, the kidney, or the tumor. In order to do so, a ML model (random forest in this case) was trained to recognize color and textural patterns and thus to differentiate tissue. The proposed technique was then tested on 15 RAPNs retrospectively and yielded a 45% improvement in detection accuracy compared to prior work [69]. In order to potentially discriminate benign from malignant tissue, Haifler et al. [70] tested Ramen spectroscopy on *ex vivo* specimens of normal kidney tissue and renal carcinoma. The obtained spectra from the spectroscopy were fed into a Bayesian and a logistic regression model used for tissue classification. Results were promising with sensitivity and specificity of 95.8% and 88.8%, respectively.

4. AI to detect and interpret histopathological features

AI applications specific to pathology have garnered increasing interest, with preliminary studies showing that AI models have the potential to outperform pathologists [71], and for example, histopathology-based AI analysis can predict metastases after radical prostatectomy [72]. In a recent overview, Lee et al. [51] highlighted the potential of AI frameworks to reduce interobserver variability and sampling bias introduced by human pathologists.

Holdbrook et al. [73] developed a pipeline to differentiate between high- and low-risk clear cell RCC based on histopathologic tissue obtained from 59 patients who underwent surgery. The final classification was done by a support vector machine and achieved F-scores ranging from 0.73 to 0.83 (values ranging from 0 to 1 with 1 indicating better performance). Tabibu et al. [74] trained convolutional neural networks (CNNs) with hematoxylin and eosin (H&E) whole-slide images from The Cancer Genome Atlas (TCGA) to detect clear cell and chromophobe RCC. On the test set, an AUC of 0.98 was achieved to detect clear cell RCC while an AUC 0.95 was achieved to detect chromophobe RCC. In addition, the authors developed a risk index based on tumor shape and nuclei features that was notably associated with an increased patient survival rate. TCGA was also used by Tian et al. [75] who predicted a 2-tiered Fuhrman's grade for clear cell RCC. Seven ML algorithms (included regression with different regularization techniques, neural networks, support vector machines, and random forest) were trained with nuclei histomics features. The performance of the final models, as evaluated by the AUC, reached values from 0.781 to 0.839.

Similar approaches were reported by other research groups. Fenstermaker et al. [76] achieved 100% sensitivity and 97.1% specificity with a CNN trained on H&E stained

images from TCGA to differentiate between normal tissue and RCC. Yeh et al. [77] used H&E stained digitalized slides that were fed in a support vector machine to detect nuclei that were used to grade clear cell RCC with an AUC of 0.97. Likewise, Khoshdeli et al. [78] demonstrated that a deep model CNN outperforms a shallow model CNN when differentiating low-grade granular tumors from high-grade clear cell RCC. This was again based on H&E stained images from the TCGA.

In contrast to the prior study, He et al. [79] did not use morphological features of tumor cells but numeric data of marker proteins that were derived from immunohistochemical images of RCC. The K-nearest neighbor algorithm was implemented and could link certain proteins to subtypes of RCC, such as autophagy protein 5 to chromophobe RCC. Singh et al. [80] have taken a different approach using gene expression profiles that were downloaded from the Genomics Data Commons portal (<https://gdc.cancer.gov/>) in order to identify biomarkers to differentiate between early and late stages of papillary RCC. Different ML algorithms (such as random forests, naïve Bayes, support vector machines, K-nearest neighbor, and shrunken centroid classifier) were used for feature extraction and classification. Shrunken centroid classifiers and random forests showed the best performances of 0.812 and 0.815, respectively, as measured by the precision-recall AUC. In a similar study by the same authors, the relationships of methylation patterns of papillary RCC and gene expression from the TCGA were investigated using mostly the same ML algorithms as before [81]. Additionally, Brennan et al. [82] aimed at developing a method to distinguish oncocytoma from chromophobe RCC based on methylation through ML algorithms, which could be applied to preoperative biopsy specimens.

5. Predicting long-term follow-up

Predicting overall survival, risk of recurrence, or other outcomes for cancer patients may be helpful to tailor individual treatment plans and allow for better patient counselling. While there is only a moderate amount of studies using AI models to predict the post-treatment course for RC, there are a considerable number of AI applications for prostate and bladder cancer. For example, Hung et al. [83] used automated performance metrics to predict urinary continence for patients undergoing robotic-assisted radical prostatectomy. Here, instrument motion tracking, clinicopathology features, and event metrics were used as input data along [84]. The authors applied random forests and a Cox proportional hazards deep neural network (named as DeepSurv [85]) to available data from 100 patients. DeepSurv achieved the best results with a concordance index of 0.6 and a mean absolute error of 85.9. Interestingly, automated performance metrics were more important than clinicopathological features to predict continence. In another study by Wong et al. [86], different ML models (such as random forests, K-nearest neighbor, and logistic regression) were compared to a traditional Cox regression analysis to predict biochemical recurrence 1 year after radical prostatectomy. All ML models outperformed the Cox regression evaluated by the

AUC (Cox: 0.865 vs. K-nearest neighbor: 0.903 vs. random forest: 0.924 vs. logistic regression: 0.940).

However, with regard to RCC, data were sparse. Kattan [87] published a study to compare a Cox model with tree-based ML approaches and neural networks on three large datasets. One of these researches provided data for diseases-recurrence of 601 patients who underwent surgical treatment of RCC [88]. In contrast to the previously described study, the Cox model achieved the best performance assessed by the concordance index. A comprehensive comparison of eight different ML models (included support vector machines, logistic regression, decision trees, K-nearest neighbor, naïve Bayes, random forest, AdaBoost, and gradient boost) based on data from 2814 patients was provided by Kim et al. [89] in order to predict recurrence after surgical treatment of RCC. Naïve Bayes outperformed the other models with an AUC of 0.836 at 5 years after surgery and 0.784 after 10 years. In addition, Guo et al. [90] presented an abstract comparing a neural network and a boosted decision tree model to predict recurrence after curative treatment after RCC. Data from 697 patients were available. Final predictors of the optimized model included age, sex, tumor laterality, radical or partial nephrectomy, T&N status, margin status, and Fuhrman grade which resulted in an AUC of 0.877.

As discussed in detail earlier, radiomics are helpful as a means of differentiating between benign and malignant renal lesions upon first diagnosis. Nazari et al. [53] expanded upon this and used radiomics to predict death in RCC patients. In total, available CT scans from 70 patients were used to train four different classification algorithms including support vector machines, K-nearest neighbor, generalized linear model, and XGBoost. The best model was XGBoost that achieved performances as high as an AUC of 0.95–0.98, accuracy of 0.93–0.98, sensitivity of 0.93–0.96, and specificity of approximately 1.0, respectively (given in 95% confidence intervals). Furthermore, Brodie et al. [91] provided a current overview about the capabilities of AI in renal cancer imaging in combination with radiomics. Based on the presented approaches, the authors concluded that this would enable informed shared decision-making in regards to treatment strategies including active surveillance.

In the setting of metastatic disease, Buchner et al. [92] used clinical and histopathological data available at the beginning of medical treatment to predict survival at 36 months. Data from 175 metastatic RCC patients were prospectively gathered and fed into logistic regression models and artificial neural networks. In the validation set, the artificial neural network correctly predicted death in 91% of patients (overall accuracy 95%), while the logistic regression only achieved an overall accuracy of 78%.

6. Conclusion

In summary, AI and ML models are evolving quickly in all aspects of RCC management and perform already as well as human counterparts. However, to realize implementation in daily practice, health care providers need to develop a basic understanding in order to standardize data sets, define meaningful endpoints, and unify interpretation. This

requires interdisciplinary collaboration and the implementation of AI curricula into medical education. In the future, large and accessible databases with high-quality data incorporating all aspects of RCC care from diagnosis to treatment are necessary which will allow external validation and continuous training of AI models.

Author contributions

Study concept and design: Karl-Friedrich Kowalewski, Giovanni Cacciamani, Enrico Checcucci, Gomez Rivas Juan.

Data acquisition: Mark Taratkin, Rivero Belenchon Ines, Stefano Puliatti, Gomez Rivas Juan.

Screening of references: Mark Taratkin, Rivero Belenchon Ines, Stefano Puliatti, Gomez Rivas Juan.

Creation of images: Luisa Egen, Chanel E. Fischetti, Marie Angela Sidoti Abate.

Drafting of manuscript: Karl-Friedrich Kowalewski, Chanel E. Fischetti, Luisa Egen, Marie Angela Sidoti Abate, Julia Mühlbauer.

Critical revision of the manuscript: Frederik Wessels, Julia Mühlbauer, Karl-Friedrich Kowalewski, Giovanni Cacciamani, Enrico Checcucci.

Conflicts of interest

The authors declare no conflict of interest.

Appendix A. Supplementary data

Supplementary data to this article can be found online at <https://doi.org/10.1016/j.ajur.2022.05.003>.

References

- [1] Ferlay J, Colombet M, Soerjomataram I, Dyba T, Randi G, Bettio M, et al. Cancer incidence and mortality patterns in Europe: estimates for 40 countries and 25 major cancers in 2018. *Eur J Cancer* 2018;103:356–87.
- [2] Padala SA, Barsouk A, Thandra KC, Saginala K, Mohammed A, Vakiti A, et al. Epidemiology of renal cell carcinoma. *World J Oncol* 2020;11:79–87.
- [3] Bray F, Ferlay J, Soerjomataram I, Siegel RL, Torre LA, Jemal A. Global cancer statistics 2018: GLOBOCAN estimates of incidence and mortality worldwide for 36 cancers in 185 countries. *CA Cancer J Clin* 2018;68:394–424.
- [4] Ljungberg B, Albiges L, Abu-Ghanem Y, Bensalah K, Dabestani S, Fernandez-Pello S, et al. European Association of Urology guidelines on renal cell carcinoma: the 2019 update. *Eur Urol* 2019;75:799–810.
- [5] Moch H, Cubilla AL, Humphrey PA, Reuter VE, Ulbright TM. The 2016 WHO classification of tumours of the urinary system and male genital organs—part A: renal, penile, and testicular tumours. *Eur Urol* 2016;70:93–105.
- [6] Han S, Hwang SI, Lee HJ. The classification of renal cancer in 3-phase CT images using a deep learning method. *J Digit Imaging* 2019;32:638–43.
- [7] Thorstenson A, Bergman M, Scherman-Plogell AH, Hosseinnia S, Ljungberg B, Adolfsson J, et al. Tumour characteristics and surgical treatment of renal cell carcinoma in Sweden 2005-2010: a population-based study from the

- national Swedish kidney cancer register. *Scand J Urol* 2014;48:231–8.
- [8] Tahbaz R, Schmid M, Merseburger AS. Prevention of kidney cancer incidence and recurrence: lifestyle, medication and nutrition. *Curr Opin Urol* 2018;28:62–79.
- [9] Gill IS, Aron M, Gervais DA, Jewett MA. Clinical practice. Small renal mass. *N Engl J Med* 2010;362:624–34.
- [10] Almassi N, Gill BC, Rini B, Fareed K. Management of the small renal mass. *Transl Androl Urol* 2017;6:923–30.
- [11] Abou Youssif T, Kassouf W, Steinberg J, Aprikian AG, Laplante MP, Tanguay S. Active surveillance for selected patients with renal masses: updated results with long-term follow-up. *Cancer* 2007;110:1010–4.
- [12] Jewett MA, Mattar K, Basiuk J, Morash CG, Pautler SE, Siemens DR, et al. Active surveillance of small renal masses: progression patterns of early stage kidney cancer. *Eur Urol* 2011;60:39–44.
- [13] Xu Q, Zhu Q, Liu H, Chang L, Duan S, Dou W, et al. Differentiating benign from malignant renal tumors using T2- and diffusion-weighted images: a comparison of deep learning and radiomics models versus assessment from radiologists. *J Magn Reson Imaging* 2022;55:1251–9.
- [14] Finelli A, Cheung DC, Al-Matar A, Evans AJ, Morash CG, Pautler SE, et al. Small renal mass surveillance: histology-specific growth rates in a biopsy-characterized cohort. *Eur Urol* 2020;78:460–7.
- [15] Abel EJ, Culp SH, Matin SF, Tamboli P, Wallace MJ, Jonasch E, et al. Percutaneous biopsy of primary tumor in metastatic renal cell carcinoma to predict high risk pathological features: comparison with nephrectomy assessment. *J Urol* 2010;184:1877–81.
- [16] Richard PO, Lavallée LT, Pouliot F, Komisarenko M, Martin L, Lattouf JB, et al. Is routine renal tumor biopsy associated with lower rates of benign histology following nephrectomy for small renal masses? *J Urol* 2018;200:731–6.
- [17] Marconi L, Dabestani S, Lam TB, Hofmann F, Stewart F, Norrie J, et al. Systematic review and meta-analysis of diagnostic accuracy of percutaneous renal tumour biopsy. *Eur Urol* 2016;69:660–73.
- [18] Hameed B, Dhavileswarapu S, Aiswarya V, Raza SZ, Karimi H, Khanuja HS, et al. Artificial intelligence and its impact on urological diseases and management: a comprehensive review of the literature. *J Clin Med* 2021;10:1864–82.
- [19] Hashimoto DA, Rosman G, Rus D, Meireles OR. Artificial intelligence in surgery: promises and perils. *Ann Surg* 2018;268:70–6.
- [20] Watson DS, Krutzinna J, Bruce IN, Griffiths CE, McInnes IB, Barnes MR, et al. Clinical applications of machine learning algorithms: beyond the black box. *BMJ* 2019;364:l886. <https://doi.org/10.1136/bmj.l886>.
- [21] Garrow CR, Kowalewski KF, Li L, Wagner M, Schmidt MW, Engelhardt S, et al. Machine learning for surgical phase recognition: a systematic review. *Ann Surg* 2020;273:684–93.
- [22] JSC LQA Data annotation for machine learning: A to Z guide. Available from: <https://www.lotus-qa.com/data-annotation-guide/>. [Accessed 30 November 2021].
- [23] Willemink MJ, Koszek WA, Hardell C, Wu J, Fleischmann D, Harvey H, et al. Preparing medical imaging data for machine learning. *Radiology* 2020;295:4–15.
- [24] Cheng JY, Abel JT, Balis UG, McClintock DS, Pantanowitz L. Challenges in the development, deployment, and regulation of artificial intelligence in anatomic pathology. *Am J Pathol* 2021;191:1684–92.
- [25] Mendelson EB. Artificial intelligence in breast imaging: potentials and limitations. *AJR Am J Roentgenol* 2019;212:293–9.
- [26] Xu Y, Goodacre R. On splitting training and validation set: a comparative study of cross-validation, bootstrap and systematic sampling for estimating the generalization performance of supervised learning. *J Anal Test* 2018;2:249–62.
- [27] Liaw A, Wiener M. Classification and regression by randomForest. *R News* 2002;2:18–22.
- [28] Formisano E, De Martino F, Valente G. Multivariate analysis of fMRI time series: classification and regression of brain responses using machine learning. *Magn Reson Imaging* 2008;26:921–34.
- [29] Carmichael I, Marron J. Data science vs. statistics: two cultures? *Jpn J Stat Data Sci* 2018;1:117–38.
- [30] Bennett M, Hayes K, Kleczyk EJ, Mehta R. Similarities and differences between machine learning and traditional advanced statistical modeling in healthcare analytics. 2022. arXiv preprint arXiv:2201.02469. <https://arxiv.org/abs/2201.02469>.
- [31] Tsili AC, Andriotis E, Gkeli MG, Krokidis M, Stasinopoulou M, Varkarakis IM, et al. The role of imaging in the management of renal masses. *Eur J Radiol* 2021;141:109777. <https://doi.org/10.1016/j.ejrad.2021.109777>.
- [32] Kaur R, Juneja M, Mandal AK. An overview of non-invasive imaging modalities for diagnosis of solid and cystic renal lesions. *Med Biol Eng Comput* 2020;58:1–24.
- [33] Warshauer DM, McCarthy SM, Street L, Bookbinder MJ, Glickman MG, Richter J, et al. Detection of renal masses: sensitivities and specificities of excretory urography/linear tomography, US, and CT. *Radiology* 1988;169:363–5.
- [34] Hallscheidt PJ, Fink C, Haferkamp A, Bock M, Luburic A, Zuna I, et al. Preoperative staging of renal cell carcinoma with inferior vena cava thrombus using multidetector CT and MRI: prospective study with histopathological correlation. *J Comput Assist Tomogr* 2005;29:64–8.
- [35] Kay FU, Canvasser NE, Xi Y, Pinho DF, Costa DN, Leon AD, et al. Diagnostic performance and interreader agreement of a standardized MR imaging approach in the prediction of small renal mass histology. *Radiology* 2018;287:543–53.
- [36] Cornelis F, Grenier N. Multiparametric magnetic resonance imaging of solid renal tumors: a practical algorithm. *Semin Ultrasound CT MR* 2017;38:47–58.
- [37] Li F, Du L, Xing J, Su Y, Wu Y. Diagnostic efficacy of contrast-enhanced ultrasonography in solid renal parenchymal lesions with maximum diameters of 5 cm. *J Ultrasound Med* 2008;27:875–85.
- [38] Olson MC, Abel EJ, Mankowski Gettle L. Contrast-enhanced ultrasound in renal imaging and intervention. *Curr Urol Rep* 2019;20:73. <https://doi.org/10.1007/s11934-019-0936-y>.
- [39] Tanaka T, Huang Y, Marukawa Y, Tsuboi Y, Masaoka Y, Kojima K, et al. Differentiation of small (≤ 4 cm) renal masses on multiphase contrast-enhanced CT by deep learning. *AJR Am J Roentgenol* 2020;214:605–12.
- [40] Ursprung S, Beer L, Bruining A, Woitek R, Stewart GD, Gallagher FA, et al. Radiomics of computed tomography and magnetic resonance imaging in renal cell carcinoma—a systematic review and meta-analysis. *Eur Radiol* 2020;30:3558–66.
- [41] Gillies RJ, Kinahan PE, Hricak H. Radiomics: images are more than pictures, they are data. *Radiology* 2016;278:563–77.
- [42] Mühlbauer J, Egen L, Kowalewski KF, Grilli M, Walach MT, Westhoff N, et al. Radiomics in renal cell carcinoma—a systematic review and meta-analysis. *Cancers* 2021;13:1348. <https://doi.org/10.3390/cancers13061348>.
- [43] Ma YC, Xu F, Ma W. Can whole-tumor radiomics-based CT analysis better differentiate fat-poor angiomyolipoma from clear cell renal cell carcinoma: compared with conventional CT analysis? *Abdom Radiol (NY)* 2020;45:2500–7.
- [44] Goh VG, Nathan P, Juttla JK, Vinayan A, Miles KA. Assessment of response to tyrosine kinase inhibitors in metastatic renal cell cancer: CT texture as a predictive biomarker. *Radiology* 2011;261:165–71.
- [45] Karimi D, Ruan D. Synergistic combination of learned and hand-crafted features for prostate lesion classification in

- multiparametric magnetic resonance imaging. In: Descoteaux M, Maier-Hein L, Franz A, Jannin P, Collins D, Duchesne S, editors. Medical image computing and computer assisted intervention—MICCAI 2017, Part III, LNCS 10435. New York: Springer-Verlag; 2017. p. 391–8.
- [46] Cao R, Bajgirani AM, Mirak SA, Shakeri S, Zhong X, Enzmann D, et al. Joint prostate cancer detection and Gleason score prediction in mp-MRI via FocalNet. *IEEE Trans Med Imaging* 2019;38:2496–506.
- [47] Chen FG, Hwang D, Cen S, Yap F, Ugwueze C, Varghese B, et al. Voxel-based whole-lesion enhancement parameters: a study of its clinical value in differentiating clear cell renal cell carcinoma from renal oncocytoma. *Abdom Radiol (NY)* 2017;42:552–60.
- [48] Li YH, Xia Y, Long L. Value of radiomics in differential diagnosis of chromophobe renal cell carcinoma and renal oncocytoma. *Abdom Radiol (NY)* 2020;45:3193–201.
- [49] Nassiri N, Maas G, Cacciamani B, Varghese B, Hwang D, Lei X, et al. A radiomic-based machine learning algorithm to reliably differentiate benign renal masses from renal cell carcinoma. *Eur Urol Focus* 2021;16:232–7.
- [50] Qin F, Yuan J. [Research status and trend of artificial intelligence in the diagnosis of urinary diseases]. *Sheng Wu Yi Xue Gong Cheng Xue Za Zhi* 2020;37:230–5. [Article in Chinese].
- [51] Lee M, Wei S, Anaokar J, Uzzo R, Kutikov A. Kidney cancer management 3.0: can artificial intelligence make us better? *Curr Opin Urol* 2021;31:409–15.
- [52] Lin F, Cui E, Lei Y, Luo L. CT-based machine learning model to predict the Fuhrman nuclear grade of clear cell renal cell carcinoma. *Abdom Radiol (NY)* 2019;44:2528–34.
- [53] Nazari M, Shiri I, Zaidi H. Radiomics-based machine learning model to predict risk of death within 5-years in clear cell renal cell carcinoma patients. *Comput Biol Med* 2021;129:104135. <https://doi.org/10.1016/j.compbiomed.2020.104135>.
- [54] Kocak B, Kaya OK, Erdim C, Kus EA, Kilickesmez O. Artificial intelligence in renal mass characterization: a systematic review of methodologic items related to modeling, performance evaluation, clinical utility, and transparency. *AJR Am J Roentgenol* 2020;215:1113–22.
- [55] Doyle PW, Kavoussi NL. Machine learning applications to enhance patient specific care for urologic surgery. *World J Urol* 2021;40:679–86.
- [56] Kowalewski KF, Garrow CR, Schmidt MW, Benner L, Müller-Stich BP, Nickel F. Sensor-based machine learning for workflow detection and as key to detect expert level in laparoscopic suturing and knot-tying. *Surg Endosc* 2019;33:3732–40.
- [57] Kowalewski KF, Hendrie JD, Schmidt MW, Garrow CR, Bruckner T, Proctor T, et al. Development and validation of a sensor- and expert model-based training system for laparoscopic surgery: the iSurgeon. *Surg Endosc* 2017;31:2155–65.
- [58] Nakawala H, Bianchi R, Pescatori LE, De Cobelli O, Ferrigno G, De Momi E. “Deep-Onto” network for surgical workflow and context recognition. *Int J Comput Assist Radiol Surg* 2019;14:685–96.
- [59] Zhao B, Waterman RS, Urman RD, Gabriel RA. A machine learning approach to predicting case duration for robot-assisted surgery. *J Med Syst* 2019;43:32. <https://doi.org/10.1007/s10916-018-1151-y>.
- [60] Bhandari M, Nallabasannagari AR, Reddiboina M, Porter JR, Jeong W, Mottrie A, et al. Predicting intra-operative and postoperative consequential events using machine-learning techniques in patients undergoing robot-assisted partial nephrectomy: a Vattikuti Collective Quality Initiative database study. *BJU Int* 2020;126:350–8.
- [61] Ross T, Zimmerer D, Vemuri A, Isensee F, Wiesenfarth M, Bodenstedt S, et al. Exploiting the potential of unlabeled endoscopic video data with self-supervised learning. *Int J Comput Assist Radiol Surg* 2018;13:925–33.
- [62] Hung AJ, Chen J, Che Z, Nilanon T, Jarc A, Titus M, et al. Utilizing machine learning and automated performance metrics to evaluate robot-assisted radical prostatectomy performance and predict outcomes. *J Endourol* 2018;32:438–44.
- [63] Hung AJ, Chen J, Gill IS. Automated performance metrics and machine learning algorithms to measure surgeon performance and anticipate clinical outcomes in robotic surgery. *JAMA Surg* 2018;153:770–1.
- [64] Ghodoussipour S, Reddy SS, Ma R, Huang D, Nguyen J, Hung AJ. An objective assessment of performance during robotic partial nephrectomy: validation and correlation of automated performance metrics with intraoperative outcomes. *J Urol* 2021;205:1294–302.
- [65] Amparore D, Pecoraro A, Checucci E, Piramide F, Verri P, De Cillis S, et al. Three-dimensional virtual models’ assistance during minimally invasive partial nephrectomy minimizes the impairment of kidney function. *Eur Urol Oncol* 2022;5:104–8.
- [66] Schiavina R, Bianchi L, Chessa F, Barbaresi U, Cercenelli L, Lodi S, et al. Augmented reality to guide selective clamping and tumor dissection during robot-assisted partial nephrectomy: a preliminary experience. *Clin Genitourin Cancer* 2021;19:e149–55. <https://doi.org/10.1016/j.clgc.2020.09.005>.
- [67] Porpiglia F, Checucci E, Amparore D, Piramide F, Volpi G, Granato S, et al. Three-dimensional augmented reality robot-assisted partial nephrectomy in case of complex tumours (PADUA≥10): a new intraoperative tool overcoming the ultrasound guidance. *Eur Urol* 2020;78:229–38.
- [68] Nosrati MS, Amir-Khalili A, Peyrat JM, Abinahed J, Al-Alao O, Al-Ansari A, et al. Endoscopic scene labelling and augmentation using intraoperative pulsatile motion and colour appearance cues with preoperative anatomical priors. *Int J Comput Assist Radiol Surg* 2016;11:1409–18.
- [69] Amir-Khalili A, Hamarneh G, Peyrat JM, Abinahed J, Al-Alao O, Al-Ansari A, et al. Automatic segmentation of occluded vasculature via pulsatile motion analysis in endoscopic robot-assisted partial nephrectomy video. *Med Image Anal* 2015;25:103–10.
- [70] Haifler M, Pence I, Sun Y, Kutikov A, Uzzo RG, Mahadevan A, et al. Discrimination of malignant and normal kidney tissue with short wave infrared dispersive Raman spectroscopy. *J Biophotonics* 2018;11:e201700188. <https://doi.org/10.1002/jbio.201700188>.
- [71] Nagpal K, Foote D, Liu Y, Chen PC, Wulczyn E, Tan F, et al. Development and validation of a deep learning algorithm for improving Gleason scoring of prostate cancer. *NPJ Digit Med* 2019;2:48. <https://doi.org/10.1038/s41746-019-0112-2>.
- [72] Wessels F, Schmitt M, Krieghoff-Henning E, Jutzi T, Worst TS, Waldbillig F, et al. Deep learning approach to predict lymph node metastasis directly from primary tumour histology in prostate cancer. *BJU Int* 2021;128:352–60.
- [73] Holdbrook DA, Singh M, Choudhury Y, Kalaw EM, Koh V, Tan H, et al. Automated renal cancer grading using nuclear pleomorphic patterns. *JCO Clin Cancer Inform* 2018;2:1–12.
- [74] Tabibu S, Vinod P, Jawahar C. Pan-renal cell carcinoma classification and survival prediction from histopathology images using deep learning. *Sci Rep* 2019;9:1–9.
- [75] Tian K, Rubadue CA, Lin DI, Veta M, Pyle ME, Irshad H, et al. Automated clear cell renal carcinoma grade classification with prognostic significance. *PLoS One* 2019;14:e0222641. <https://doi.org/10.1371/journal.pone.0222641>.
- [76] Fenstermaker M, Tomlins SA, Singh K, Wiens J, Morgan TM. Development and validation of a deep-learning model to assist with renal cell carcinoma histopathologic interpretation. *Urology* 2020;144:152–7.
- [77] Yeh FC, Parwani AV, Pantanowitz L, Ho C. Automated grading of renal cell carcinoma using whole slide imaging. *J Pathol Inform* 2014;5:23. <https://doi.org/10.4103/2153-3539.137726>.

- [78] Khoshdeli M, Borowsky A, Parvin B. Deep learning models differentiate tumor grades from H&E stained histology sections. *Annu Int Conf IEEE Eng Med Biol Soc* 2018;2018:620–3.
- [79] He Z, Liu H, Moch H, Simon HU. Machine learning with autophagy-related proteins for discriminating renal cell carcinoma subtypes. *Sci Rep* 2020;10:720. <https://doi.org/10.1038/s41598-020-57670-y>.
- [80] Singh NP, Bapi RS, Vinod PK. Machine learning models to predict the progression from early to late stages of papillary renal cell carcinoma. *Comput Biol Med* 2018;100:92–9.
- [81] Singh NP, Vinod P. Integrative analysis of DNA methylation and gene expression in papillary renal cell carcinoma. *Mol Genet Genomics* 2020;295:807–24.
- [82] Brennan K, Metzner TJ, Kao CS, Massie CE, Stewart GD, Haile RW, et al. Development of a DNA methylation—based diagnostic signature to distinguish benign oncocytoma from renal cell carcinoma. *JCO Precis Oncol* 2020;4:1141–51.
- [83] Hung AJ, Chen J, Ghodoussipour S, Oh PJ, Liu Z, Nguyen J, et al. Deep learning on automated performance metrics and clinical features to predict urinary continence recovery after robot-assisted radical prostatectomy. *BJU Int* 2019;124.
- [84] Hung AJ, Chen J, Jarc A, Hatcher D, Djaladat H, Gill IS. Development and validation of objective performance metrics for robot-assisted radical prostatectomy: a pilot study. *J Urol* 2018;199:296–304.
- [85] Katzman JL, Shaham U, Cloninger A, Bates J, Jiang T, Kluger Y. DeepSurv: personalized treatment recommender system using a Cox proportional hazards deep neural network. *BMC Med Res Methodol* 2018;18:24. <https://doi.org/10.1186/s12874-018-0482-1>.
- [86] Wong NC, Lam C, Patterson L, Shayegan B. Use of machine learning to predict early biochemical recurrence after robot-assisted prostatectomy. *BJU Int* 2019;123:51–7.
- [87] Kattan MW. Comparison of Cox regression with other methods for determining prediction models and nomograms. *J Urol* 2003;170:S6–10.
- [88] Kattan MW, Reuter V, Motzer RJ, Katz J, Russo P. A post-operative prognostic nomogram for renal cell carcinoma. *J Urol* 2001;166:63–7.
- [89] Kim H, Lee SJ, Park SJ, Choi IY, Hong SH. Machine learning approach to predict the probability of recurrence of renal cell carcinoma after surgery: prediction model development study. *JMIR Med Informatics* 2021;9:e25635. <https://doi.org/10.2196/25635>.
- [90] Guo Y, Braga L, Kapoor A. PD07-08 machine learning to predict recurrence of localized renal cell carcinoma. *J Urol* 2019;201:e145. <https://doi.org/10.1097/01.JU.0000555241.27498.f6>.
- [91] Brodie A, Dai N, Teoh YCJ, Decaestecker K, Dasgupta P, Vasdev N. Artificial intelligence in urological oncology: an update and future applications. *Urol Oncol* 2021;39:379–99.
- [92] Buchner A, Kendlbacher M, Nuhn P, Tüllmann C, Haseke N, Stief CG, et al. Outcome assessment of patients with metastatic renal cell carcinoma under systemic therapy using artificial neural networks. *Clin Genitourin Cancer* 2012;10:37–42.