



Radiographic displacement of acute acromioclavicular joint dislocations fixed with AC TightRope

Anell Olivos-Meza, PhD, Arturo Almazán-Díaz, MD, José Alberto Calvo, MD, César Alejandro Jiménez-Aroche, MD, Marco Vinicio Valdez-Chávez, MD, Francisco Pérez-Jiménez, MD, Clemente Ibarra, PhD, Francisco Cruz-López, MD *

Orthopedic Sports Medicine, Instituto Nacional de Rehabilitación Luis Guillermo Ibarra Ibarra, Mexico City, Mexico

ARTICLE INFO

Keywords:

Acromioclavicular joint dislocation
acromioclavicular joint reduction
arthroscopic fixation
TightRope device
radiologic displacement
functional outcomes

Level of evidence: Level IV; Case Series;
Treatment Study

Background: The arthroscopic approach to acromioclavicular (AC) dislocation with methods such as AC TightRope fixation has reported radiographic failure rates between 18% and 50% with functional results graded as good or excellent. Our objective was to review the outcomes after arthroscopic fixation for acute AC joint dislocation using the TightRope device.

Methods: We reviewed the records of 52 patients, with a mean age of 31 years, who underwent arthroscopic fixation with the TightRope device for acute AC joint dislocation. Outcomes were evaluated using the Constant and University of California, Los Angeles scores. The coracoclavicular (CC) distance before and after surgery was compared by radiography.

Results: The mean follow-up period was 36.7 months (range, 6–65 months). Postoperatively, the mean Constant score was 97.13 and the mean University of California, Los Angeles score was 33.2. The CC distance was maintained in 73% of the patients, whereas partial loss of reduction occurred in 19.2% and failure of reduction occurred in 7.7%.

Conclusion: Arthroscopic fixation using the TightRope device for acute AC joint dislocation achieves satisfactory clinical outcomes. However, CC reconstruction appears to result in subluxation in cases with AC dislocation for a period of more than 10 days.

© 2019 Published by Elsevier Inc. on behalf of American Shoulder and Elbow Surgeons. This is an open access article under the CC BY-NC-ND license (<http://creativecommons.org/licenses/by-nc-nd/4.0/>).

Approximately 12% of shoulder injuries involve damage to the acromioclavicular (AC) joint, with many of these injuries being underdiagnosed.⁶ Forty-three percent occur in adults who practice high-impact sports such as football, rugby, or hockey.^{4,11,12,19} More than 60 procedures have been described for the surgical management of AC dislocations; however, none is considered the gold standard.^{1,14} There is controversy in the management of this lesion, especially with a type III dislocation; some schools prefer conservative treatment over surgical treatment.^{8,17,18}

Multiple novel procedures have been developed with the objective of reconstructing the joint in an anatomic form, reproducing the coracoclavicular (CC) ligaments with allograft and autograft.^{7,16,22} Studies have reported improvement in biomechanical strength with these techniques; however, there are no studies showing improvement in clinical outcomes.^{9,15} Some

arthroscopic techniques involve reconstruction using devices such as the TightRope device (Arthrex, Naples, FL, USA), designed to stabilize the AC joint with a nonrigid fixation. These techniques are used in acute cases with the aim to repair the ligaments, periosteum, and AC capsule and maintain clavicle reduction.^{13,23,25}

Arthroscopic management of these dislocations stabilized with the TightRope device in acute cases allows one to perform a minimally invasive, nonrigid procedure that re-creates the CC ligaments to maintain the reduction temporally and permit the repair of the AC joint ligaments.²³ According to a biomechanical study by Walz et al,²⁵ the vertical force required for this system to fail is 982 N whereas the force required for native ligaments to fail is 598 N. There is little literature showing the clinical and radiologic results of these techniques in the short, medium, and long term, and the published studies are case series with very small study populations. The aim of this study was to review the outcomes after arthroscopic fixation for acute AC joint dislocation using the TightRope device.

Materials and methods

A retrospective, descriptive, transverse study of patients with acute AC dislocation of grade III, IV, or V (according to the

Institutional review board approval was received from Instituto Nacional de Rehabilitación Luis Guillermo Ibarra Ibarra.

* Corresponding author: Francisco Cruz-López, MD, Orthopedic Sports Medicine, Instituto Nacional de Rehabilitación Luis Guillermo Ibarra Ibarra, Calzada Mexico-Chochimilco 289, ZC 14389, Mexico City, Mexico.

E-mail address: hombro2000@gmail.com (F. Cruz-López).

<https://doi.org/10.1016/j.jseint.2019.11.002>

2666-6383/© 2019 Published by Elsevier Inc. on behalf of American Shoulder and Elbow Surgeons. This is an open access article under the CC BY-NC-ND license (<http://creativecommons.org/licenses/by-nc-nd/4.0/>).

Rockwood classification measured with a radiographic viewer by a single observer using the true anterior-posterior projection) operated on with an arthroscopic technique and stabilized with the AC TightRope device (Arthrex) was performed at the National Rehabilitation Institute of Mexico between January 2013 and March 2018. We selected 52 patients with the following indications for surgery (104 patients underwent the surgical procedure during this period but not all met the requirements or underwent follow-up for the required period for selection): acute (<2 weeks) AC dislocation (Rockwood grade III, IV or V), with no fractures, treated with arthroscopic reduction and stabilization with the AC TightRope device with a minimum follow-up period of 6 months.

A clinical evaluation was carried out with the Constant and University of California, Los Angeles (UCLA) scores before and after surgery. To evaluate maintenance of reduction, the CC distance was measured and compared between the immediate postoperative radiograph and the last control by the same radiographic viewer system and observer. The radiographic measurements were classified as follows: “without changes” when the CC distance was maintained, “lost reduction” when displacement of less than 50% of the distance was noted between the preoperative and postoperative radiographs, and “failed reduction” when displacement of at least 50% of the distance was noted between the preoperative and postoperative radiographs.

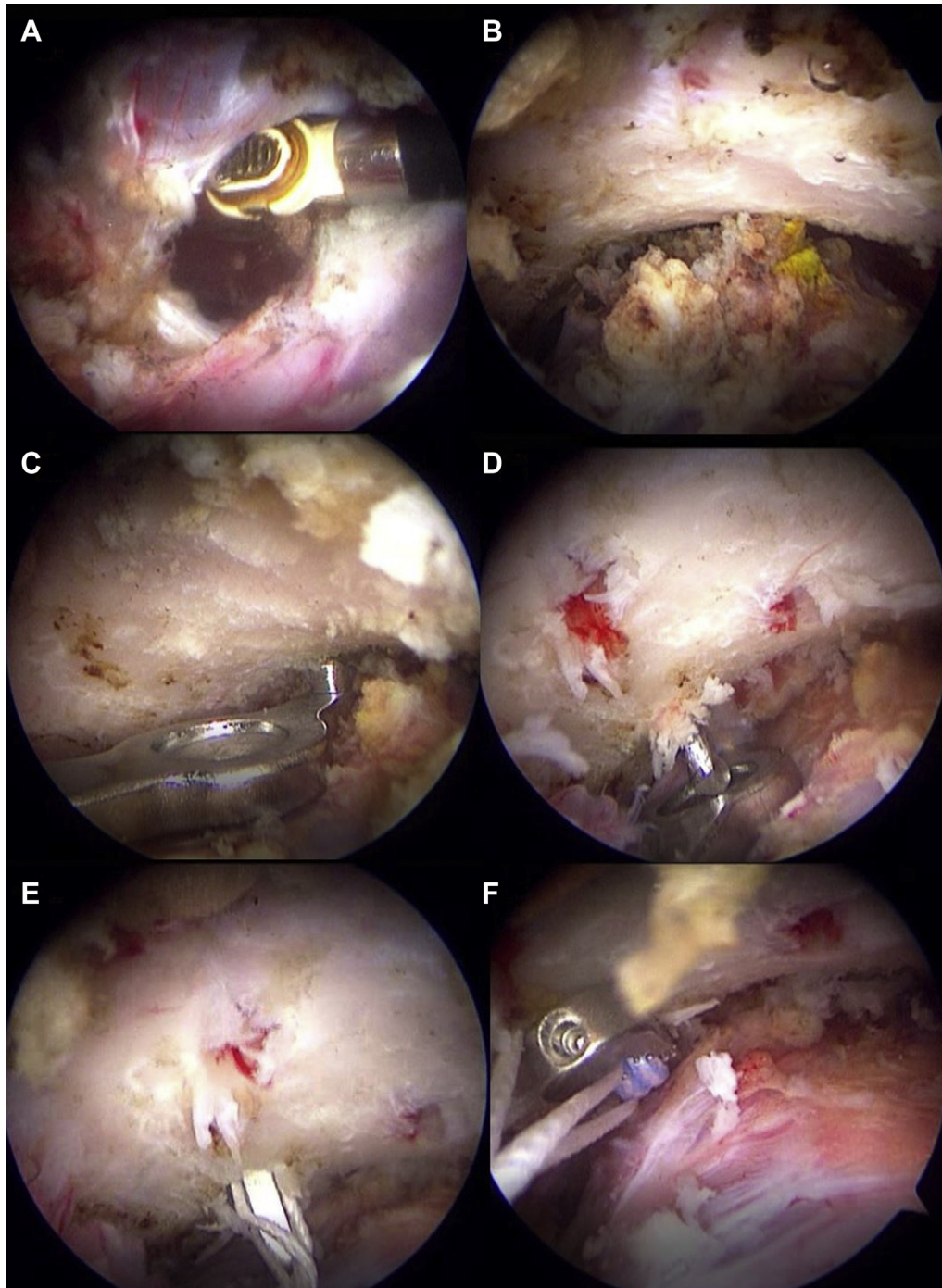


Figure 1 (A-F) Step-by-step arthroscopic surgical technique.

Table 1

Loss of reduction according to grade of displacement by Rockwood classification (evaluated by radiographic imaging)

| | Cases | Frequency, % | Reduction | | |
|----------------------|-------|-----------------|------------|----------------------------------------|---------|
| | | | Maintained | Loss | Failure |
| Grade | | | | | |
| III | 21 | 40.4 | 16 | 4 | 1 |
| IV | 4 | 7.7 | 3 | 1 | 0 |
| V | 27 | 51.9 | 19 | 5 | 3 |
| Total | 52 | 100 | 38 | 10 | 4 |
| % | | | 73 | 19 | 8 |
| Reduction time, d | | | 11.7 | 27.8 (loss and failure combined) | |

SPSS software (version 21; IBM, Armonk, NY, USA) was used to analyze the data. Outcomes were evaluated using the Constant score. The CC distance before vs. after surgery was compared using the Student *t* test. $P < .05$ was considered statistically significant.

Surgical technique

In all cases, surgery was performed with the patient in the beach-chair position. The arthroscope was introduced through the posterior portal to inspect the shoulder joint. An anterior-superior portal was created with an outside-in technique using a spinal needle for positioning. Then, a 7-mm partially threaded cannula was inserted into this portal. Near the tip of the coracoid, an anterior-inferior portal was established with an outside-in technique using the spinal needle to ensure that the base of the coracoid could be reached; an 8.25-mm Twist-In Cannula (Arthrex) was inserted through this portal, and débridement of the rotator interval was started until the coracoid base could be visualized. Once the interval was cleared, exposure of the coracoid base was performed with a mechanical shaver and radiofrequency device (Fig. 1, A and B). Through the anterior-inferior portal, the AC TightRope Constant Guide (Arthrex) was inserted, and its tip was positioned under the coracoid base (Fig. 1, C). The Guide Pin Sleeve (Arthrex) was placed over the clavicle at its midline approximately 35 mm from the distal clavicle through a 1.5-cm incision made in the Langer lines by splitting the deltotracheal fascia. By use of a power drill, the 2.4-mm Drill Tip Guide (Arthrex) was inserted (Fig. 1, D).

A pin was introduced into the guide pin sleeve and advanced through the clavicle and coracoid. The tip of the guide pin was captured by the drill stop at the coracoid base under direct visualization. The Constant Guide was removed, and the guide pin was

left in situ. By use of a power drill, a 4-mm cannulated drill was slowly advanced over the pin and through the clavicle and coracoid. The reamer was left in position while the inner guide pin was removed. A nitinol suture-passing wire was advanced downward through the cannulated drill, and the tip was grasped with an arthroscopic grasper. The drill was removed prior to delivering the wire tip out of the anterior-inferior portal, leaving the wire loop superiorly. The 2 white traction sutures from the oblong button were inserted through the wire loop of the nitinol suture-passing wire. The suture-passing wire was pulled to retrieve the 2 white traction sutures out of the anterior-inferior cannula; then, 1 of the 2 white traction sutures was pulled to flip the oblong button into a vertical position suitable for advancement through the bone tunnels (Fig. 1, E). Once the security of the oblong button was confirmed, the arthroscope was placed into the subacromial bursa through the posterior portal, and the clavicle was reduced until the position was considered satisfactory under direct visualization (Fig. 1, F). Both of the blue TightRope suture tails were pulled to advance the round button down to the surface of the clavicle. The sutures were tied on top of the TightRope, making a surgeon's knot and 4 additional half-hitches.

Postoperative care

The patients used a shoulder immobilizer for 4 weeks. They were only allowed to remove the shoulder immobilizer for washing and elbow flexion-extension exercises. Motion below shoulder height was permitted after 4 weeks. Heavy-resistance work was avoided until 3 months postoperatively.

Results

Demographic characteristics

The study included 52 patients, comprising 1 female and 51 male patients, with a mean age of 31.2 years (range, 14–57 years). There were 26 right shoulders (50%, 21 dominant arms) and 26 left shoulders (50%, 7 dominant arms). The mean postoperative follow-up period was 36.7 months, ranging from 6 to 65 months.

Dislocation mechanisms

The most frequent cause of AC dislocation was trauma by high-energy sports, occurring in 21 cases (40.3%), followed by falls while standing, in 20 (38.6%), and traffic accidents, in 11 (21.1%).

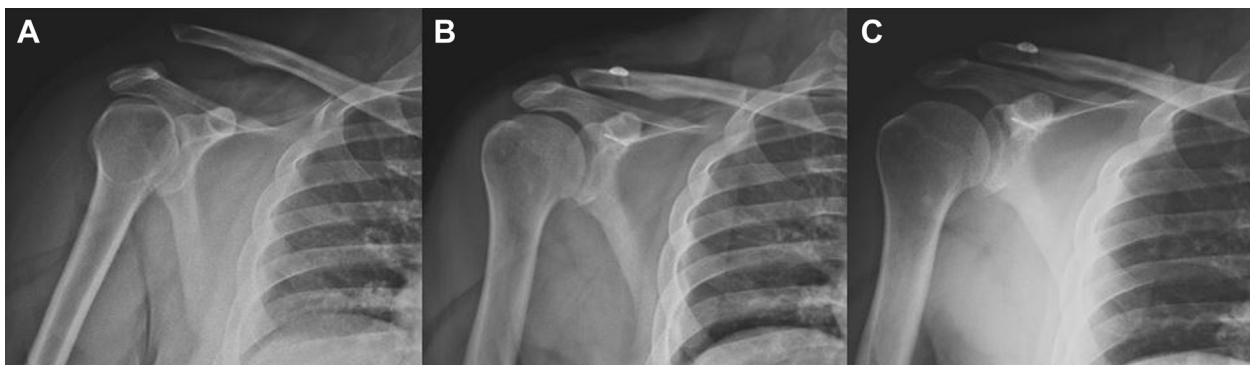

Figure 2 (A–C) Radiographic projections in right shoulder of patient classified as “without changes.”

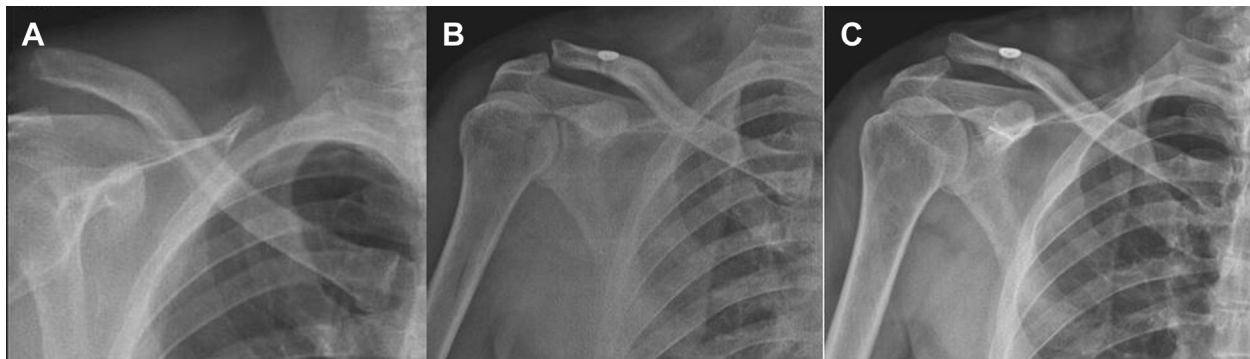

Figure 3 (A-C) Radiographic projections in right shoulder of patient classified as “lost reduction.”

Degree of injury by rockwood classification

In all patients, the degree of injury was graded by the Rockwood classification. We found a higher prevalence of grade V, occurring in 27 cases (51.9%), followed by grade III, with 21 cases (40.4%); grade IV showed the lowest frequency, with only 4 cases (7.7%) (Table I).

CC distance correction

The CC distance decreased from 19.3 ± 5.2 mm to 9.21 ± 3.5 mm on immediate postoperative radiographs ($P = .0001$) and was 10.83 ± 3.2 mm at the average final endpoint ($P = .05$ for immediate postoperative vs. average final endpoint). No overcorrection occurred.

Clavicular displacement after surgery

Reduction of the CC joint was maintained in 38 cases (73%) (Fig. 2). At follow-up, 14 patients (27%) had postoperative displacement; 10 patients (19%) showed loss of reduction (Fig. 3), whereas 4 (8%) had reduction failure (Fig. 4). Of the 10 cases with loss of reduction, 5 (50%) were classified as Rockwood grade V; 4 (40%), Rockwood grade III; and 1 (10%), Rockwood grade IV. Of the cases with reduction failure, 3 (75%) had an initial Rockwood grade of V whereas 1 (25%) was classified as Rockwood grade III; failure did not occur in any Rockwood grade IV cases (Table I). The groups more associated with loss of reduction or with failure were Rockwood grade III cases (23%) and Rockwood grade V cases (29.6%), with no statistically significant difference between them ($P = .8646$).

Time from injury to surgery

The mean time from injury to surgery was 12.8 days (range, 3–30 days). Patients in whom the reduction was preserved were operated on after a shorter period, comprising 11.7 days, whereas patients with a loss of reduction or with reduction failure had a longer time from injury to surgery, comprising 27.8 days (Table I). Comparison of the average number of days between injury and surgery comparing successes vs. failures (11.7 days vs. 27.8 days), assuming equal variance for both groups, yielded a t statistic of 14.6, with $P = .0001$.

Clinical results

On clinical evaluation, 31 cases (59.6%) showed excellent results whereas 21 (40.4%) showed good results on the UCLA scale, with a mean score of 33.2 points. The total UCLA score was 33.6 points in patients in whom the reduction was maintained; this result decreased to 32.1 points in patients with loss of reduction or with failure. However, no significant difference was found in function and symptoms between patients in whom the reduction was maintained and those with loss of reduction or with failure ($P = .095$). Among patients in whom the reduction was maintained, the UCLA score was excellent in 24 (64.9%) and good in 13 (35.1%); in contrast, among patients with loss of reduction or with failure, the percentage of excellent results was lower (33.3%) and the percentage of good results was higher (66.7%). The relative risk of adequate outcomes on the UCLA scale for partial reduction or for failure was 1.7 (95% confidence interval, 0.8–3.7; $P = .07$) (Table II). The mean Constant score was 97.2 points in patients in whom the reduction was maintained compared with

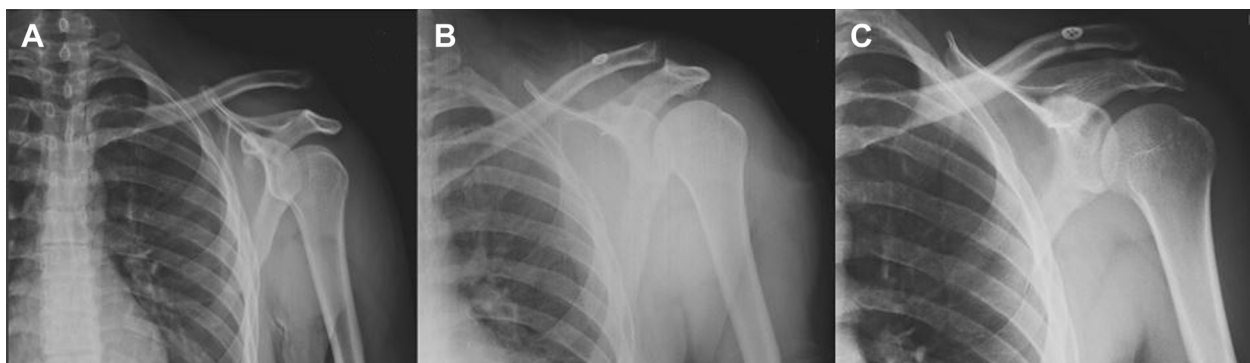

Figure 4 (A-C) Radiographic projections in left shoulder of patient classified as “failed reduction.”

Table II
Clinical results evaluated with shoulder scores

| Scale | Mean | Excellent, % | Good, % | Reduction | | P value |
|-------------------|-----------------|-----------------|------------|----------------|-----------------------|------------|
| | | | | Maintained | Loss or failure | |
| UCLA score | 33.2 points | 59.6 | 40.4 | 33.6 points | 32.1 points | .095 |
| Excellent, % | | | | 64.9 | 33.3 | |
| Good, % | | | | 35.1 | 66.7 | |
| Constant score | 97.13 points | 100 | — | 97.2 points | 96.9 points | .75 |
| Excellent, % | | | | 100 | 100 | |

UCLA, University of California, Los Angeles.

$P \leq .05$ is defined as statistically significant.

96.9 points in patients with loss of reduction or with failure, without a significant functional difference between them ($P = .7553$) (Table II).

Associated lesions

Of the cases with AC joint dislocation, 9 (17.3%) were associated with concomitant intra-articular pathologies: superior labrum anterior-posterior lesion in 6 (11.54%), rotator cuff rupture in 2 (3.8%), and rupture of the coracohumeral ligament in 1 (1.9%).

Complications

Some degree of complication was noted in 8 cases (15.6%): subclavicular calcification in 3 (5.8%), clavicle pain over the TightRope device in 2 (3.8%), arthrofibrosis in 1 (2%), coracoid fracture in 1 (2%), and superficial abscess in 1 (2%).

Discussion

There are multiple publications on the management of AC lesions; however, most are works with few patients and short follow-up periods. Our study includes 52 patients, comprising one of the largest reported caseloads, comparable to the study by Kany et al.¹⁰ The average age of the patients in our study was 31.2 years, and this does not differ from what is found in the literature in which it is mentioned that this injury is frequent between the first and third decades of life.⁴ The majority of our cases were caused by sports trauma, with most being related to cycling. The latter factor differs from previous reports in the literature, in which football was the more prevalent cause.¹²

In terms of radiologic outcomes, a satisfactory result was achieved in 73.1% of cases in which the initial reduction was maintained compared with 26.9% in which some grade of postoperative displacement was shown. The latter result is lower than the findings reported by Lim et al.,¹³ with a failure rate of up to 50%; Scheibel et al.,²¹ with 42%; and Salzman et al.,²⁰ with 34%. In the cases in which the joint dislocation was stabilized with 2 implants, radiologic displacement also was observed in 16% to 18%. In our study, the CC distance was 19.3 mm preoperatively and was reduced to 9.21 mm when evaluated in the immediate postoperative period. At the last radiologic follow-up, the mean CC distance was 10.83 mm, showing a statistically significant increase ($P < .05$).^{3,23} Many hypotheses could explain these results: Thiel et al.²³ mentioned that many studies report high failure rates because of the use of a single device, and they recommended the use of 2 devices to decrease the failure rate. However, the anatomy of the Latin American population is different from that of the European and Anglo-Saxon

population; we often operate on small patients in whom it is difficult to place 2 devices because of the small size of the coracoid process. In addition, Scheibel et al.²¹ and Salzman et al.²⁰ reported failure rates very similar to our finding using 2 devices. Our results are similar to those described by Cohen et al.,³ who showed lower rates of failure using 1 device compared with double-device fixation.

We consider that the reported index of failures is more related to the time between AC dislocation and surgical treatment. We found that patients in whom reduction was maintained were operated on in a shorter time (11.7 days) than those who had some grade of displacement after surgery (27.8 days), with a difference of 16 days between these groups. We consider that the TightRope device, either single or double, should be used only for acute injuries with a period of less than 10 days to secure the repair of the native ligaments; for those AC dislocations with a period of more than 10 days, an anatomic reconstruction with graft or TightRope plus graft could probably show better results.^{2,5}

In terms of functional results, we found that all patients had excellent or good results according to both the UCLA and Constant scores. However, when we compared these outcomes between patients with some degree of postoperative displacement and those with maintained reduction, no statistically significant differences were found in both the UCLA and Constant scores. These findings are similar to those reported by different authors showing that the functional results are good to excellent without differences between patients with failure and those in whom reduction in maintained.^{20,21,23} However, in our study, we found that almost 18% of the cases with AC dislocation had concomitant intra-articular lesions; this has been reported in 14%–15% of patients by some authors in the literature.^{5,24}

Conclusion

Arthroscopic fixation using the TightRope device for acute AC joint dislocation achieves satisfactory clinical outcomes. However, CC reconstruction appears to result in subluxation in cases with AC dislocation for a period of more than 10 days.

Disclaimer

The authors, their immediate families, and any research foundations with which they are affiliated have not received any financial payments or other benefits from any commercial entity related to the subject of this article.

References

- Arce G, Bak K, Shea KP, Savoie F III, Kibler WB, Itoi E, et al. editors. *Shoulder concepts 2013: consensus and concerns*. New York: Springer; 2013.
- Carofino BC, Mazzocca AD. The anatomic coracoclavicular ligament reconstruction: surgical technique and indications. *J Shoulder Elbow Surg* 2010;19:37–46. <https://doi.org/10.1016/j.jse.2010.01.004>.
- Cohen G, Boyer P, Pujol N, Hamida FB, Massin P, Hardy P. Endoscopically assisted reconstruction of acute acromioclavicular joint dislocation using a synthetic ligament. Outcomes at 12 months. *Orthop Traumatol Surg Res* 2011;97:145–51. <https://doi.org/10.1016/j.otsr.2010.10.004>.
- Collins DN. Disorders of the acromioclavicular joint. In: Rockwood CA, Matsen FA, editors. *The shoulder*. 4th ed. Philadelphia: Saunders Elsevier; 2009. p. 453–514.
- DeBerardino TM, Pensak MJ, Ferreira J, Mazzocca AD. Arthroscopic stabilization of acromioclavicular joint dislocation using the AC Graftrape system. *J Shoulder Elbow Surg* 2010;19:47–52. <https://doi.org/10.1016/j.jse.2009.12.014>.
- Emery R. Acromioclavicular and sternoclavicular joints. In: Copeland S, editor. *Shoulder surgery*. London: WB Saunders; 1997.
- Epstein D, Day M, Rokito A. Current concepts in the surgical management of acromioclavicular joint injuries. *Bull NYU Hosp Jt Dis* 2012;70:11–24.
- Gladstone J, Wilk K, Andrews J. Nonoperative treatment of acromioclavicular joint injuries. *Oper Tech Sports Med* 1997;5:78–87.

9. Jari R, Costic RS, Rodosky MW, Debski RE. Biomechanical function of surgical procedures for acromioclavicular joint dislocations. *Arthroscopy* 2004;20: 237–45. <https://doi.org/10.1016/j.arthro.2004.01.011>.
10. Kany J, Amaravathi RS, Guinand R, Valenti P. Arthroscopic acromioclavicular joint reconstruction using a synthetic ligament device. *Eur J Orthop Surg Traumatol* 2011;22:357–64. <https://doi.org/10.1007/s00590-011-0856-0>.
11. Kaplan LD, Flanigan DC, Norwig J, Jost P, Bradley J. Prevalence and variance of shoulder injuries in elite collegiate football players. *Am J Sports Med* 2005;33: 1142–6. <https://doi.org/10.1177/0363546505274718>.
12. Kelly BT, Barnes RP, Powell JW, Warren RF. Shoulder injuries to quarterbacks in the National Football League. *Am J Sports Med* 2004;32:328–31. <https://doi.org/10.1177/0363546503261737>.
13. Lim YW, Sood A, Van Riet RP, Bain GI. Acromioclavicular joint reduction, repair and reconstruction using metallic buttons—early results and complications. *Tech Shoulder Elbow Surg* 2007;8:213–21. <https://doi.org/10.1097/bte.0b013e3181578965>.
14. Mazzocca AD, Arciero RA, Bicos J. Evaluation and treatment of acromioclavicular joint injuries. *Am J Sports Med* 2007;35:316–29. <https://doi.org/10.1177/0363546506298022>.
15. Mazzocca AD, Santangelo SA, Johnson ST, Rios CG, Dumonski ML, Arciero RA. A biomechanical evaluation of an anatomical coracoclavicular ligament reconstruction. *Am J Sports Med* 2006;34:236–46. <https://doi.org/10.1177/0363546505281795>.
16. Modi CS, Beazley J, Zywiol MG, Lawrence TM, Veillette CJH. Controversies relating to the management of acromioclavicular joint dislocations. *Bone Joint J* 2013;95-B:1595–602. <https://doi.org/10.1302/0301-620x.95b12.31802>.
17. Mouhsine E, Garofalo R, Crevoisier X, Farron A. Grade I and II acromioclavicular dislocations: results of conservative treatment. *J Shoulder Elbow Surg* 2003;12: 599–602. [https://doi.org/10.1016/s1058-2746\(03\)00215-5](https://doi.org/10.1016/s1058-2746(03)00215-5).
18. Phillips AM, Smart C, Groom AF. Acromioclavicular dislocation. *Conservative or surgical therapy*. *Clin Orthop Relat Res* 1998:10–7.
19. Salter EG Jr, Nasca RJ, Shelley BS. Anatomical observations on the acromioclavicular joint and supporting ligaments. *Am J Sports Med* 1987;15:199–206.
20. Salzmann GM, Walz L, Buchmann S, Glabgyl P, Venjakob A, Imhoff AB. Arthroscopically assisted 2-bundle anatomical reduction of acute acromioclavicular joint separations. *Am J Sports Med* 2010;38:1179–87. <https://doi.org/10.1177/0363546509355645>.
21. Scheibel M, Dröschel S, Gerhardt C, Kraus N. Arthroscopically assisted stabilization of acute high-grade acromioclavicular joint separations. *Am J Sports Med* 2011;39:1507–16. <https://doi.org/10.1177/0363546511399379>.
22. Smith TO, Chester R, Pearse EO, Hing CB. Operative versus non-operative management following Rockwood grade III acromioclavicular separation: a meta-analysis of the current evidence base. *J Orthop Traumatol* 2011;12: 19–27. <https://doi.org/10.1007/s10195-011-0127-1>.
23. Thiel E, Mutnal A, Gilot G. Surgical outcome following arthroscopic fixation of acromioclavicular joint disruption with the TightRope device. *Orthopedics* 2011;34:e267–74. <https://doi.org/10.3928/01477447-20110526-11>.
24. Tischer T, Salzmann GM, El-Azab H, Vogt S, Imhoff AB. Incidence of associated injuries with acute acromioclavicular joint dislocations types III through V. *Am J Sports Med* 2009;37:136–9. <https://doi.org/10.1177/0363546508322891>.
25. Walz L, Salzmann GM, Fabbro T, Eichhorn S, Imhoff AB. The anatomic reconstruction of acromioclavicular joint dislocations using 2 TightRope devices. *Am J Sports Med* 2008;36:2398–406. <https://doi.org/10.1177/03635465083225>.