

# Reciprocal Changes in the Whole-Body Following Realignment Surgery in Adult Spinal Deformity

Jae-Koo Lee, Seung-Jae Hyun, Ki-Jeong Kim

Department of Neurosurgery, Spine Center, Seoul National University Bundang Hospital, Seoul National University College of Medicine, Seongnam, Korea

The idea of the global balance of spine stems from Jean Dubousset, who first introduced the concept of cone of economy. Through the compensatory mechanisms, the human body maintains an upright posture and horizontal gaze in the setting of the spinal malalignment. Compensation takes place not only in the mobile spine segments, but also in the pelvis and lower extremities. Patients with a malalignment exhibit compensatory changes in the cervical hyper-lordosis, posterior pelvic shift, knee/ankle flexion, hip extension, and the pelvic retroversion. The advent of whole-body stereo radiography has yielded an improved understanding of global changes among the patients. Deformity-induced compensatory changes in the sagittal alignment could be resolved reciprocally after the surgical correction of the malalignment. Thoracolumbar realignment surgery restores the pathologic compensatory changes in the unfused spinal segments, pelvis, and the lower extremities. Similarly, reciprocal changes in the thoracolumbar spine may harmonize global sagittal alignment after the cervical reconstruction. This study reviews the compensatory mechanisms and reciprocal changes in global sagittal alignment caused by the surgical correction and highlights, the factors that should be considered while assessing a patient's compensatory status.

**Keywords:** Global alignment; Reciprocal changes; Whole body imaging; Deformity

## Introduction

The idea of the global balance of spine stems from Dubousset [1], who first introduced the concept of the cone of economy (COE). The notion of a sagittal alignment subsequently emerged in the field of the thoracolumbar spine based on the pelvic parameters [2]. Over the last few decades, the importance of the sagittal plane and its contour has gained a significant recognition. The regions of the spine are not independent of each other. The concept of a sagittal alignment regarding the spinopelvic parameters and reciprocal changes in the thoracolumbar spine

has been well documented [3-7]. Spinopelvic balance, described in terms of the reciprocal changes of thoracic kyphosis (TK) and lumbar lordosis (LL) is based on the morphology and orientation of the pelvis. Pelvic incidence (PI) significantly affects the sagittal alignment of the spine, especially LL [8-10]. In the thoracolumbar spine, the PI minus LL mismatch significantly affects the sagittal imbalance and health-related quality of life (HRQoL) [11-17].

With the advent of full-body stereo radiography, our understanding regarding the compensatory mechanisms in the patients with a spinopelvic imbalance has pro-

Received Oct 31, 2021; Revised Dec 14, 2021; Accepted Jan 3, 2022

Corresponding author: Seung-Jae Hyun

Department of Neurosurgery, Spine Center, Seoul National University Bundang Hospital, Seoul National University College of Medicine, 82 Gumi-ro 173beon-gil, Bundang-gu, Seongnam 13620, Korea

Tel: +82-31-787-7164, Fax: +82-31-787-4097, E-mail: [hyunsj@snu.ac.kr](mailto:hyunsj@snu.ac.kr)

gressed rapidly, and the concept of the reciprocal change has expanded to the field of cervical spine and the lower extremities. During the last decade, correlations of the cervical alignment with a thoracolumbar spine and HRQoL have been researched extensively [18-22]. The cervical spine is an adaptive spinal segment regarding a global sagittal alignment (GSA). The PI correlates with LL, LL with TK, and TK with the cervical lordosis (CL) [3]. The chain of correlation between the PI and sagittal parameters are well established. A large PI requires a large LL, which results in an increased TK. An increase in the TK correlates with an increased CL [3]. In the cervical spine, a sequential linkage of correlation of the parameters from T1 slope (T1S) to the cranium has been demonstrated. Small T1S results in a small CL to maintain the physiological neck tilting [23]. The T1S determines the amount of sub axial lordosis required to maintain the head-balance and changes depending on the GSA [3]. The maintenance of a horizontal gaze is an essential function of the upright posture and GSA [24]. Cervical alignment is affected by GSA through the compensatory mechanisms to maintain an upright posture and a horizontal gaze [24-28]. In the past, cervical alignment was regarded as a bridge between the cranium and thoracolumbar spine. However, research on the relationship between a cervical alignment and GSA has developed further. This study aims to review the compensatory mechanisms and the reciprocal changes in the whole-body caused by a spinal realignment surgery.

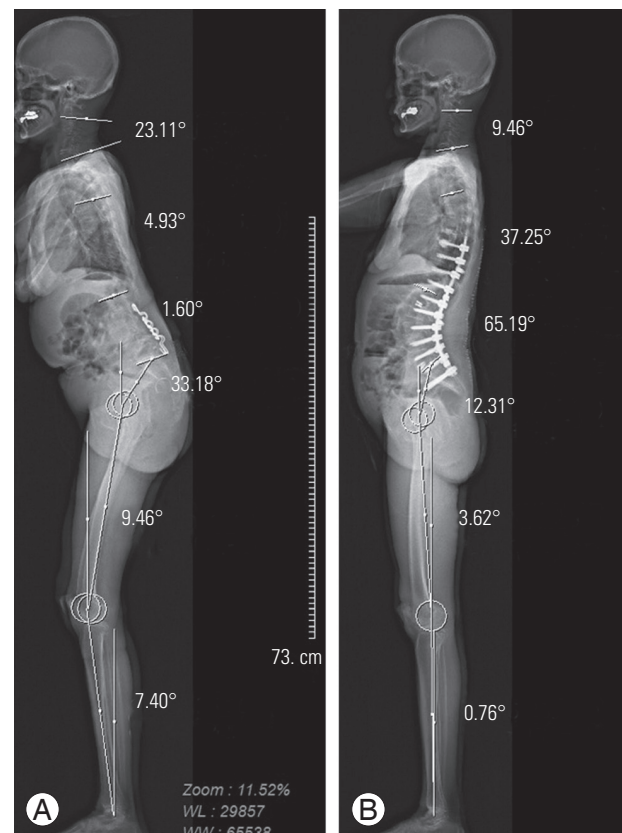
### Compensatory Mechanisms in Standing Sagittal Alignment

The sagittal balance reflects the spine's shape, allowing the individuals to maintain a standing position with a minimal muscle force. Recent investigations have shown that cervical alignment is affected by the GSA through the compensatory mechanisms to maintain an upright posture and a horizontal gaze [24-26,29-32]. Patients with thoracolumbar malalignment exhibit compensatory changes in the form of cervical hyper-lordosis, posterior pelvic shift, ankle dorsiflexion, knee flexion, hip extension, and the pelvic retroversion [31,33-35]. A radiographic analysis of the Scheuermann's disease showed a cervical hyper-lordosis, a similar compensatory mechanism for the hyperkyphotic thoracic spine [36].

Likewise, changes in cervical kyphosis (CK) reduce TK to correct the alignment and maintain the COE of global

spinal balance. Compensation in the CK occurs via a posterior shifting of the C7 sagittal vertical axis (SVA), small T1S, and a large LL [35,37]. Moreover, increased TK causes hyper-lordotic cervical alignment and vice versa [35].

The normal aging process induces the truncal stooping [38]. Several compensatory mechanisms have been implemented to maintain the optimal GSA, including increased CL, PT, ankle flexion, and the knee flexion (Fig. 1) [39-41]. The aging-related deterioration of the GSA is compensated by supportive functions of the spine, pelvis, and the lower limbs [30]. The reciprocal changes from the thoracolumbar to the cervical spine, and lower extremities occur in a staged fashion to maintain a horizontal gaze and global balance [41]. Roussouly and Pinheiro-Franco [42] hypothesized the following sequential mechanism of the compensation of progressive kyphosis: (1) a normal stage with the slight pelvic retroversion and the C7 plumb



**Fig. 1.** (A) Whole-body image of thoracolumbar malalignment exhibits cervical hyperlordosis, posterior pelvic shift, and knee flexion. (B) Postoperative whole-body image of the same patient exhibits restoration of lumbar lordosis (from 1.6° to 65.2°) with reciprocal changes of thoracic kyphosis (from -4.9° to 37.2°), cervical lordosis (from 23.1° to 9.5°), pelvic tilt (from 33.1° to 12.3°), knee flexion (from 9.5° to 3.6°), and ankle dorsiflexion (from 7.4° to 0.7°).

line (PL) over the sacral endplate, (2) a compensated stage with a progressive loss of LL and the pelvic retroversion to maintain the C7 PL behind the femoral heads, and (3) a decompensated stage, wherein hip extension limits the pelvic retroversion, which is compensated by a knee flexion, and the C7 PL passes forward to the femoral heads. With the hips maximally extended and the knees flexed, the last posture is well known in severe kyphosis, and it is very uncomfortable and uneconomical [42]. Therefore, it is necessary to evaluate the GSA, particularly in older patients with a cervical spondylotic myelopathy, because of their compensatory mechanism for the global malalignment [43].

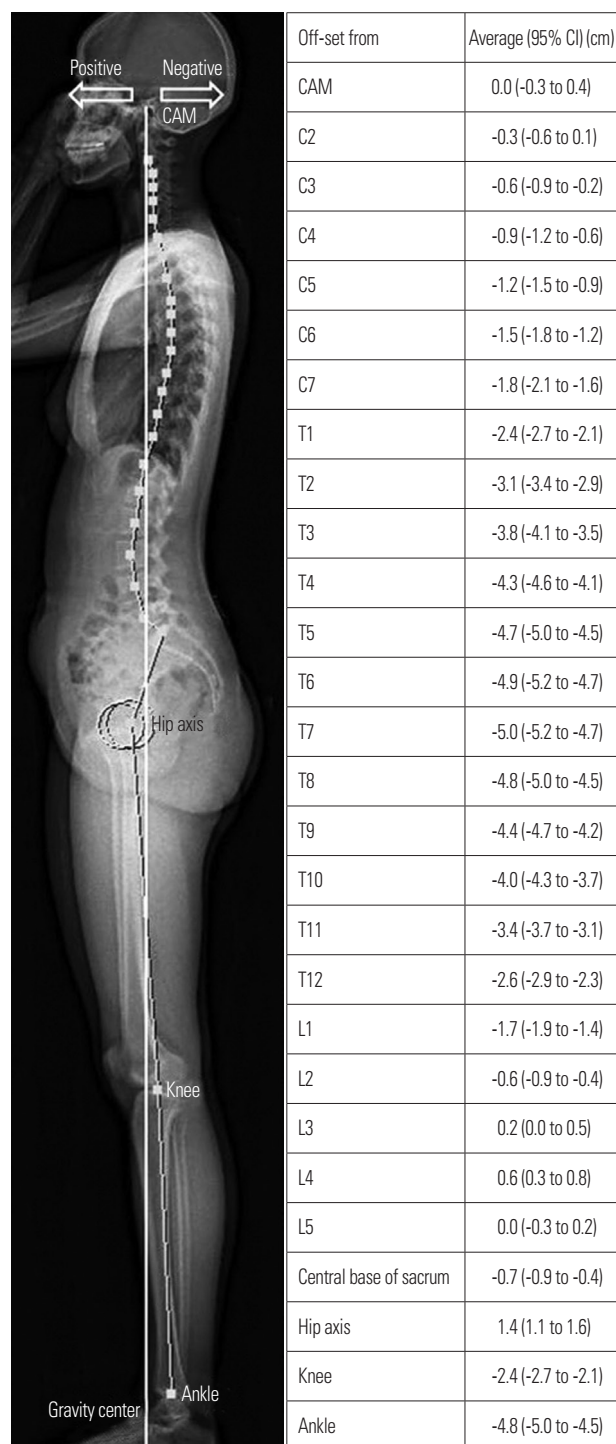
### The Era of Whole-Body Imaging

A new X-ray imaging system, the EOS system (EOS imaging, Paris, France), was developed by the interdisciplinary investigators to overcome the limitations of a conventional radiography. Using a three-dimensional bone external envelope technique, EOS allows bilateral long-length images (whole-body or localized) in either the standing or seated position, with the overall enhanced image quality, and lower radiation dose for the patient [44,45]. Obtaining a whole-body image in a single scan provides a full-scale image without a vertical distortion, improving the accuracy of the surgical planning measurements.

The advent of whole-body radiographs has led to a better understanding of the reciprocal changes in the cervical spine and the lower extremities in patients with the horacolumbar deformities. Using the EOS imaging system, the normal location of the bony landmarks in standing whole-body radiographs in reference to the gravity line (GL) has been reported (Fig. 2) [30]. The mean value of the offset distance from GL to the center of the acoustic meatus was 0, and this value was not affected by the aging [30]. With the age, the L4 and L5 vertebrae and sacrum shifted posteriorly. Loss of lordosis and an increase in the PT were induced by the posterior shift of the lower lumbar vertebrae and the sacrum, maintaining an optimal positioning of the GL [30].

Previous studies have been reported that the measurements made using an EOS lateral whole-body stereoradiographs showed an equivalent reliability to those obtained by using the conventional cervical lateral radiographs [46]. EOS resulted in the lower measurements for C2–7 SVA (0.68 cm lower) and C1–7 SVA (1.02 cm lower)

than the conventional X-rays, with significant differences between the groups. However, there were no differences in the C2–7 lordosis, T1S, neck tilt, or the thoracic inlet angle [46].



**Fig. 2.** Normative offset distances between bony landmarks and the gravity line. Positive values denote locations anterior to the gravity line and negative values indicate locations posterior to the gravity line. CAM, center of the acoustic meatus, CI, confidence interval.

Unlike the conventional radiographs, the EOS imaging system presents the information on the alignment of the spine and lower extremities, emphasizing the significance of a full-body analysis to comprehend the patient's status. Without a detailed analysis of the lower extremities, the spine cannot be evaluated properly. The key to understand the sagittal balance is detecting the imbalance, severity, and diagnosing combined problems involving the lower extremities [41,47]. The compensatory mechanisms implemented to maintain an optimal GSA also occur in the lower extremities, including the hip extension, knee flexion, and the ankle dorsiflexion [30,41]. Accordingly, all the elements of the chain of balance considered to evaluate the static global balance [41]. However, it is difficult to use the conventional radiographs to assess the lower extremities or head position [39]. Therefore, using the preoperative EOS evaluation aids full-body analysis of a patient, leading to an optimal preoperative planning.

### Reciprocal Changes from the Thoracolumbar to the Cervical Spine

Patients with a thoracolumbar malalignment exhibit compensatory changes in the form of cervical hyper-lordosis, posterior pelvic shift, ankle dorsiflexion, knee flexion, hip extension, and the pelvic retroversion [33,34]. Maligned patients showed a larger CL, Sacro-femoral, and knee flexion angles than the well-aligned patients [34]. These compensatory mechanisms resolve reciprocally in a linear fashion following the optimal surgical correction of malalignment [29,33].

Correction of the thoracolumbar malalignment has been shown to result in a reciprocal change in the adjacent thoracolumbar regions [48-51]. Pedicle subtraction osteotomy (PSO) of the thoracic or lumbar spine results in a reciprocal change (decreased TK in the lumbar PSO, decreased LL in the thoracic PSO) [48]. Protosaltis et al. [50] reported that the reciprocal TK could be predicted in preoperative planning, and the surgeon should consider the extent of the surgical instrumentation accordingly. After the correction of a sagittal thoracic deformity, the lordotic compensatory mechanisms occur at the closest mobile curve by decreasing the LL, especially in the lower thoracic deformity [51].

Multiple studies have been reported about the reciprocal changes in the cervical alignment ensuing surgical correction of thoracolumbar deformity over a last decade

[26,29,33,34,51-54]. Thoracolumbar realignment surgery restores the pathologic compensatory mechanisms in the unfused spinal segments and the lower extremities, especially in patients fused from the upper thoracic spine [34,51]. Similarly, after a thoracolumbar arthrodesis, changes in the TK and LL were significantly associated with a CL. Reciprocal change in the T1S and C2-7 SVA were associated with the selection of the upper instrumented vertebra (UIV). If the UIV was in the lower thoracic spine (T9 or lower), reciprocal changes were not observed, whereas if the UIV was in the upper thoracic spine (T1-8), there were significant reciprocal changes [54]. The spontaneous correction of the CK is due to the restoration of TK and reciprocal changes between the cervical and thoracic spine.

Ha et al. [26] reported that the changes in the CL after a deformity correction were correlated with the magnitude of the sagittal deformity. The high C7 SVA group showed a decreased CL, postoperatively; whereas, in the lower C7 SVA group, CL significantly increased after a thoracolumbar deformity correction [26].

### Reciprocal Changes from the Cervical to the Thoracolumbar Spine

The primary goal of the cervical reconstruction surgery is to achieve an occiput-trunk concordance [55]. Occiput-

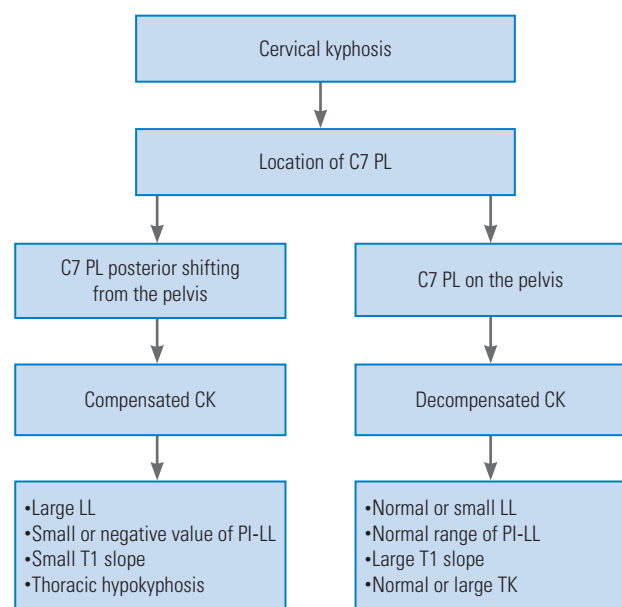
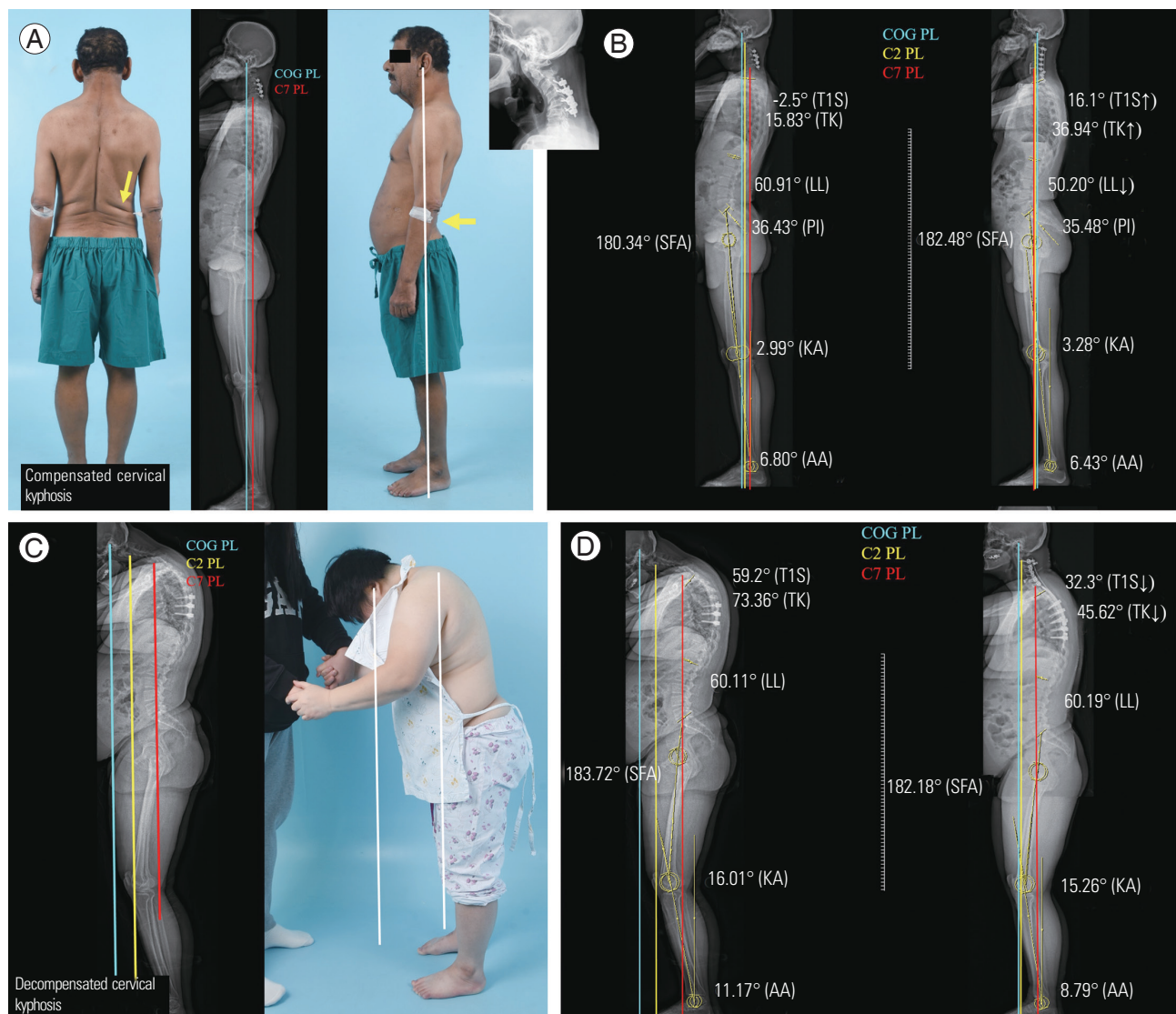


Fig. 3. Compensatory mechanisms in patients with symptomatic cervical kyphosis. PL, plumb line; CK, cervical kyphosis; LL, lumbar lordosis; PI, pelvic incidence; TK, thoracic kyphosis.

trunk discordance is defined as a distance over 30 mm between the GL and C7 PL [56]. Once occiput-trunk concordance is achieved, the subsequent thoracolumbar alignment changes occur as needed to harmonize the GSA, showing that the cervical reconstruction may restore both cervical deformities and GSA [55].

A few studies have analyzed the compensatory mechanism of the CK and reciprocal changes after the CK correction [37,55,57-59]. Mizutani et al. [55] thoroughly

investigated the reciprocal changes on radiographs after the correction of cervical deformities. They classified the patients into two CK groups according to the preoperative C7 PL location (Fig. 3). The head-balanced patients were those with the negative SVA values, hyper-LL, and a low T1S. Trunk-balanced patients had positive SVA values, upper-limit PI-LL values, and a normal T1S. Subsequently, thoracolumbar alignment changed to harmonize the entire spinal alignment. Correction in the head-balanced group



**Fig. 4.** A representative case of a patient with cervical kyphosis. Preoperative and postoperative wholebody stereoradiographs showing the center of gravity (COG) plumb line (PL) (blue line) and C7 PL (red line). **(A)** A preoperative clinical picture of a compensated cervical kyphosis patient. Hyperlordotic thoracolumbar compensation resulted in skin redundancy and a crease in the lumbar spine (yellow arrow). **(B)** Compensated cervical kyphosis patient with the COG PL located on the femoral head, but the C7 PL located markedly posteriorly. Cervical malalignment was corrected to achieve global sagittal balance and occiput-trunk (OT) concordance. However, the lowerextremity alignment parameters did not change significantly. **(C)** Clinical picture of a decompensated cervical kyphosis patient. **(D)** Decompensated cervical kyphosis patient with the COG PL located markedly anteriorly, but the C7 PL located on the femoral head. Sagittal PLs indicated cervical sagittal imbalance and OT discordance before surgery. No significant changes were found in lumbopelvic alignment or the lowerextremity alignment parameters. T1S, T1 slope; TK, thoracic kyphosis; LL, lumbar lordosis; PI, pelvic incidence; SFA, sacrofemoral angle; KA, knee angle; AA, ankle angle.

resulted in the anterior shifting of C7 PL, a subsequent increase in the T1S and TK, and a decrease in the LL.

Reciprocal changes after the correction of CK suggest that the patients exhibit different patterns depending on whether they have an adequate compensatory capacity in the thoracolumbar spine. In our practice, we divide the patients into two CK subgroups (Fig. 4). In patients with a compensated CK (i.e., head-balanced) (Fig. 4A, B), the posteriorly shifted C7 PL before the surgery moves anteriorly after a correction. Subsequently, TK and T1S increase while the LL decreases. In contrast, no significant changes in thoracolumbar alignment occur in the patients with a decompensated CK (i.e., trunk-balanced) (Fig. 4C, D) following a surgical correction. In a previous study of these two groups, patients with a decompensated CK decreased in the T1S and TK, but no changes occurred in the spinopelvic and lower extremity parameters. In addition, the C0–1 and C1–2 angles became kyphotic and less lordotic, after the surgery [57]. No changes were observed in the pelvic and lower extremity parameters in both the groups [57]. As specific implications, selective cervical correction would be possible for the compensated subtype, whereas both the cervical and thoracic correction would be necessary for the decompensated subtype [57].

### Relationship between HRQoL and Sagittal Alignment

It has been reported that aging affects the HRQoL with a deteriorating sagittal alignment [60]. With an increasing age, spinopelvic mismatch increases in a normal population, resulting in the higher Oswestry Disability Index (ODI) score, suggesting that the spinopelvic malalignment correlates with a poor HRQoL in an aging population due to a spinopelvic mismatch [40].

Likewise, the severity of disability increases with a positive global malalignment in both cervical and thoracolumbar spine following the surgical correction of the deformity [11,57,61]. The C7 SVA is a vital parameter regarding the GSA. The C7 PL significantly correlates with the HRQoL [11]. The normal C7 SVA should be <5 cm, but the parameter is age-dependent [62]. Any pathology interfering with the equilibrium instigates a sagittal malalignment resulting in the significant change in HRQoL. Even the mild imbalance is detrimental, and a linear correlation of the HRQoL and sagittal imbalance has been demonstrated [11].

In the thoracolumbar spine, the spinopelvic mismatch significantly affects the sagittal imbalance and HRQoL [11–13]. Higher grades of the spinopelvic mismatch significantly correlate with the poorer HRQoL [12]. Combining spinopelvic mismatch with the C7 SVA provides a guideline in patient assessment and in the therapeutic decision-making [13]. The correlation between the ODI score and compensatory mechanisms of the pelvis and the lower extremities has been shown [41]. Changes in the regional cervical sagittal parameters correlate with the HRQoL in patients, and improvement in the regional cervical alignment improves the HRQoL [28]. The C2–7 SVA and T1S–CL are correlated with the multiple measures of HRQoL [22,63,64]. The C2–7 SVA is positively correlated with the Neck Disability Index (NDI) scores [22,28,61,65]. In addition, T1S–CL is correlated positively with the C2–7 SVA and NDI scores [65]. Achieving operative goals, including the proper GSA or cervical alignment, maximal correction of the focal kyphosis, and correcting the horizontal gaze leads to the optimal HRQoL [66].

### Discussion

The study provides a comprehensive background material on the compensatory mechanism of the spine after the reconstructive surgery. The association between a cervical alignment and GSA has not been thoroughly investigated. The cervical alignment adjusts to maintain an upright posture and a horizontal gaze through the compensatory mechanisms of the GSA [10–16]. In CK patients, the C7 SVA shifts posteriorly, T1S decreases, and the LL increases to compensate the GSA [20,23]. LL influences TK and has only an indirect effect on the cervical alignment [43]. Similarly, compensation in the thoracolumbar malalignment patients occurs through a cervical hyper-lordosis, posterior pelvic shift, knee flexion, hip extension, and the pelvic retroversion [18–20].

Adults with a spinal deformity and positive sagittal malalignment compensate with an abnormally increased CL to maintain their horizontal gaze, and correction of the sagittal malalignment results in the correction of the abnormal cervical hyper-lordosis through the reciprocal changes. Patients who achieved full correction of the positive sagittal malalignment had the greatest relaxation of cervical hyper-lordosis [15]. Changes in the CL after a deformity correction are correlated with the magnitude of the sagittal deformity [26]. Patients show different pat-

terns of reciprocal changes after the cervical deformity correction depending on the compensatory capacity of the thoracolumbar spine [57].

Therefore, assessing the whole-body alignment rather than the whole-spine images is necessary to understand patients' GSA and their compensatory status thoroughly. Previous reports regarding a cervical deformity did not take GSA into account, and instead focused only on the local parameters.

The normal locations of the bony landmarks in standing whole-body radiographs in reference to the GL using the EOS imaging system have been reported [30]. The mean value of offset distance from the GL to the center of an acoustic meatus was 0, and this value was not affected by the aging [30]. Accordingly, reconstruction surgery aims to achieve the occiput-trunk concordance by positioning the center of the gravity above the femoral heads [34].

Achieving the optimal alignment leads to potential improvements in the clinical outcomes. The patient's degree of disability rises with a positive global malalignment following the surgical correction of a deformity [8,36,39]. Cervical alignment parameters such as: C2–7 SVA and T1S–CL are positively correlated with the HRQoL [22,61,63,65]. Achieving the proper GSA, cervical alignment, maximal correction of focal kyphosis, and correcting the horizontal gaze could lead to optimal HRQoL [42]. Therefore, future research on the surgical correction of the sagittal malalignment should focus on the compensatory status of the patient's GSA to provide an ideal correction. Furthermore, the active use of the whole-body stereo radiography is highly recommended, as the results measured by the EOS lateral whole-body stereo radiography show results with a comparable reliability to those obtained using conventional cervical lateral radiographs [29].

## Conclusions

Understanding of compensatory mechanisms among the spine, pelvis, and lower extremities is mandatory for treating the spinal deformity. These compensatory mechanisms could be evaluated using a whole-body imaging. The proverb, "Do not miss the forest for the trees." is helpful to understand a malalignment of the spine. A meticulous preoperative evaluation of the whole-body alignment, including the pelvis and lower extremities, is paramount to appreciate the optimal GSA in the correction of spinal malalignment.

## Conflict of Interest

No potential conflict of interest relevant to this article was reported.

## References

1. Dubousset J. Three-dimensional analysis of the scoliotic deformity. In: Weinstein SL, editor. Pediatric spine: principle and practice. New York (NY): Raven Press; 1994. p. 479-96.
2. Legaye J, Duval-Beaupere G, Hecquet J, Marty C. Pelvic incidence: a fundamental pelvic parameter for three-dimensional regulation of spinal sagittal curves. *Eur Spine J* 1998;7:99-103.
3. Ames CP, Blondel B, Scheer JK, et al. Cervical radiographical alignment: comprehensive assessment techniques and potential importance in cervical myelopathy. *Spine (Phila Pa 1976)* 2013;38(22 Suppl 1):S149-60.
4. Roussouly P, Pinheiro-Franco JL. Sagittal parameters of the spine: biomechanical approach. *Eur Spine J* 2011;20(Suppl 5):578-85.
5. Dumpa SR, Shetty AP, Aiyer SN, Kanna RM, Rajasekaran S. Reciprocal changes in sagittal alignment in adolescent idiopathic scoliosis patients following strategic pedicle screw fixation. *Asian Spine J* 2018;12:300-8.
6. Nakashima H, Kanemura T, Satake K, et al. Changes in sagittal alignment following short-level lumbar interbody fusion: comparison between posterior and lateral lumbar interbody fusions. *Asian Spine J* 2019;13:904-12.
7. Kim KR, Le Huec JC, Jang HJ, et al. Which is more predictive value for mechanical complications: fixed thoracolumbar alignment (T1 pelvic angle) versus dynamic global balance parameter (odontoid-hip axis angle). *Neurospine* 2021;18:597-607.
8. Legaye J, Duval-Beaupere G. Sagittal plane alignment of the spine and gravity: a radiological and clinical evaluation. *Acta Orthop Belg* 2005;71:213-20.
9. Roussouly P, Gollogly S, Berthonnaud E, Labelle H, Weidenbaum M. Sagittal alignment of the spine and pelvis in the presence of L5-S1 isthmic lysis and low-grade spondylolisthesis. *Spine (Phila Pa 1976)* 2006;31:2484-90.
10. Vialle R, Levassor N, Rillardon L, Templier A, Skalli

- W, Guigui P. Radiographic analysis of the sagittal alignment and balance of the spine in asymptomatic subjects. *J Bone Joint Surg Am* 2005;87:260-7.
11. Glassman SD, Bridwell K, Dimar JR, Horton W, Berven S, Schwab F. The impact of positive sagittal balance in adult spinal deformity. *Spine (Phila Pa 1976)* 2005;30:2024-9.
  12. Terran J, Schwab F, Shaffrey CI, et al. The SRS-Schwab adult spinal deformity classification: assessment and clinical correlations based on a prospective operative and nonoperative cohort. *Neurosurgery* 2013;73:559-68.
  13. Schwab FJ, Blondel B, Bess S, et al. Radiographical spinopelvic parameters and disability in the setting of adult spinal deformity: a prospective multicenter analysis. *Spine (Phila Pa 1976)* 2013;38:E803-12.
  14. Shahi P, Chadha M, Sehgal A, et al. Sagittal balance, pulmonary function, and spinopelvic parameters in severe post-tubercular thoracic kyphosis. *Asian Spine J* 2021 May 10 [Epub]. <https://doi.org/10.31616/asj.2020.0464>
  15. Shimokawa T, Miyamoto K, Hioki A, et al. Compensatory pelvic retro-rotation associated with a decreased quality of life in patients with normal sagittal balance. *Asian Spine J* 2021 May 11 [Epub]. <https://doi.org/10.31616/asj.2020.0449>.
  16. Moon BJ, Han MS, Kim JY, Lee JK. Thoracolumbar slope is useful parameter for evaluating health-related quality of life and sagittal imbalance aggravation in adult spinal deformity: a prospective observational cohort study. *Neurospine* 2021;18:467-74.
  17. Noh SH, Ha Y, Park JY, et al. Modified global alignment and proportion scoring with body mass index and bone mineral density analysis in global alignment and proportion score of each 3 categories for predicting mechanical complications after adult spinal deformity surgery. *Neurospine* 2021;18:484-91.
  18. Kim CW, Hyun SJ, Kim KJ. Surgical impact on global sagittal alignment and health-related quality of life following cervical kyphosis correction surgery: systematic review. *Neurospine* 2020;17:497-504.
  19. Alijani B, Rasoulian J. The sagittal balance of the cervical spine: radiographic analysis of interdependence between the occipitocervical and spinopelvic alignment. *Asian Spine J* 2020;14:287-97.
  20. Oe S, Togawa D, Yoshida G, et al. Difference in spinal sagittal alignment and health-related quality of life between males and females with cervical deformity. *Asian Spine J* 2017;11:959-67.
  21. Massaad E, Hadzipasic M, Kiapour A, et al. Association of spinal alignment correction with patient-reported outcomes in adult cervical deformity: review of the literature. *Neurospine* 2021;18:533-42.
  22. Hyun SJ, Kim KJ, Jahng TA, Kim HJ. Clinical impact of T1 slope minus cervical lordosis after multilevel posterior cervical fusion surgery: a minimum 2-year follow up data. *Spine (Phila Pa 1976)* 2017;42:1859-64.
  23. Lee SH, Kim KT, Seo EM, Suk KS, Kwack YH, Son ES. The influence of thoracic inlet alignment on the craniocervical sagittal balance in asymptomatic adults. *J Spinal Disord Tech* 2012;25:E41-7.
  24. Lafage R, Challier V, Liabaud B, et al. Natural head posture in the setting of sagittal spinal deformity: validation of chin-brow vertical angle, slope of line of sight, and McGregor's slope with health-related quality of life. *Neurosurgery* 2016;79:108-15.
  25. Le Huec JC, Saddiki R, Franke J, Rigal J, Aunoble S. Equilibrium of the human body and the gravity line: the basics. *Eur Spine J* 2011;20(Suppl 5):558-63.
  26. Ha Y, Schwab F, Lafage V, et al. Reciprocal changes in cervical spine alignment after corrective thoracolumbar deformity surgery. *Eur Spine J* 2014;23:552-9.
  27. Pan Z, Xi Y, Huang W, et al. Independent correlation of the C1-2 Cobb angle with patient-reported outcomes after correcting chronic atlantoaxial instability. *Neurospine* 2019;16:267-76.
  28. Protopsaltis TS, Scheer JK, Terran JS, et al. How the neck affects the back: changes in regional cervical sagittal alignment correlate to HRQOL improvement in adult thoracolumbar deformity patients at 2-year follow-up. *J Neurosurg Spine* 2015;23:153-8.
  29. Smith JS, Shaffrey CI, Lafage V, et al. Spontaneous improvement of cervical alignment after correction of global sagittal balance following pedicle subtraction osteotomy. *J Neurosurg Spine* 2012;17:300-7.
  30. Hasegawa K, Okamoto M, Hatsushikano S, et al. Standing sagittal alignment of the whole axial skeleton with reference to the gravity line in humans. *J Anat* 2017;230:619-30.
  31. Diebo BG, Ferrero E, Lafage R, et al. Recruitment of compensatory mechanisms in sagittal spinal malalignment is age and regional deformity dependent: a full-standing axis analysis of key radiographical parameters. *Spine (Phila Pa 1976)* 2015;40:642-9.
  32. Lee SH, Hyun SJ, Jain A. Cervical sagittal alignment:



- literature review and future directions. *Neurospine* 2020;17:478-96.
33. Day LM, Ramchandran S, Jalai CM, et al. Thoracolumbar realignment surgery results in simultaneous reciprocal changes in lower extremities and cervical spine. *Spine (Phila Pa 1976)* 2017;42:799-807.
  34. Shimizu T, Lehman RA Jr, Sielatycki JA, et al. Reciprocal change of sagittal profile in unfused spinal segments and lower extremities after complex adult spinal deformity surgery including spinopelvic fixation: a full-body X-ray analysis. *Spine J* 2020;20:380-90.
  35. Lamartina C, Berjano P. Classification of sagittal imbalance based on spinal alignment and compensatory mechanisms. *Eur Spine J* 2014;23:1177-89.
  36. Janusz P, Tyrakowski M, Kotwicki T, Siemionow K. Cervical sagittal alignment in Scheuermann disease. *Spine (Phila Pa 1976)* 2015;40:E1226-32.
  37. Lee DH, Ha JK, Chung JH, Hwang CJ, Lee CS, Cho JH. A retrospective study to reveal the effect of surgical correction of cervical kyphosis on thoraco-lumbopelvic sagittal alignment. *Eur Spine J* 2016;25:2286-93.
  38. Kang KB, Kim YJ, Muzaffar N, Yang JH, Kim YB, Yeo ED. Changes of sagittal spinopelvic parameters in normal Koreans with age over 50. *Asian Spine J* 2010;4:96-101.
  39. Kim CW, Hyun SJ, Kim KJ. Systematic review of reciprocal changes after spinal reconstruction surgery : do not miss the forest for the trees. *J Korean Neurosurg Soc* 2021;64:843-52.
  40. Hasegawa K, Okamoto M, Hatsushikano S, Shimoda H, Ono M, Watanabe K. Normative values of spinopelvic sagittal alignment, balance, age, and health-related quality of life in a cohort of healthy adult subjects. *Eur Spine J* 2016;25:3675-86.
  41. Ferrero E, Liabaud B, Challier V, et al. Role of pelvic translation and lower-extremity compensation to maintain gravity line position in spinal deformity. *J Neurosurg Spine* 2016;24:436-46.
  42. Roussouly P, Pinheiro-Franco JL. Biomechanical analysis of the spino-pelvic organization and adaptation in pathology. *Eur Spine J* 2011;20(Suppl 5):609-18.
  43. Yoshida G, Alzakri A, Pointillart V, et al. Global spinal alignment in patients with cervical spondylotic myelopathy. *Spine (Phila Pa 1976)* 2018;43:E154-62.
  44. Deschenes S, Charron G, Beaudoin G, et al. Diagnostic imaging of spinal deformities: reducing patients radiation dose with a new slot-scanning X-ray imager. *Spine (Phila Pa 1976)* 2010;35:989-94.
  45. Dubousset J, Charpak G, Dorion I, et al. Le systeme EOS: nouvelle imagerie osteo-articulaire basse dose en position debout [The EOS system: new low-dose osteoarticular imaging in a standing position]. *e-Mem Acad Natl Chir* 2005;4:22-7.
  46. Singhatanadgige W, Kang DG, Luksanaprukpa P, Peters C, Riew KD. Correlation and reliability of cervical sagittal alignment parameters between lateral cervical radiograph and lateral whole-body EOS stereoradiograph. *Global Spine J* 2016;6:548-54.
  47. Lazennec JY, Folinais D, Bendaya S, Rousseau MA, Pour AE. The global alignment in patients with lumbar spinal stenosis: our experience using the EOS full-body images. *Eur J Orthop Surg Traumatol* 2016;26:713-24.
  48. Klineberg E, Schwab F, Ames C, et al. Acute reciprocal changes distant from the site of spinal osteotomies affect global postoperative alignment. *Adv Orthop* 2011;2011:415946.
  49. Smith JS, Singh M, Klineberg E, et al. Surgical treatment of pathological loss of lumbar lordosis (flatback) in patients with normal sagittal vertical axis achieves similar clinical improvement as surgical treatment of elevated sagittal vertical axis: clinical article. *J Neurosurg Spine* 2014;21:160-70.
  50. Protopsaltis TS, Diebo BG, Lafage R, et al. Identifying thoracic compensation and predicting reciprocal thoracic kyphosis and proximal junctional kyphosis in adult spinal deformity surgery. *Spine (Phila Pa 1976)* 2018;43:1479-86.
  51. Cacho-Rodriguez P, Campana M, Obeid I, Vital JM, Gille O. Sagittal correction and reciprocal changes after thoracic pedicle subtraction osteotomy. *Spine (Phila Pa 1976)* 2016;41:E791-7.
  52. Obeid I, Boniello A, Boissiere L, et al. Cervical spine alignment following lumbar pedicle subtraction osteotomy for sagittal imbalance. *Eur Spine J* 2015;24:1191-8.
  53. Oh T, Scheer JK, Eastlack R, et al. Cervical compensatory alignment changes following correction of adult thoracic deformity: a multicenter experience in 57 patients with a 2-year follow-up. *J Neurosurg Spine* 2015;22:658-65.
  54. Neuman BJ, Harris A, Jain A, et al. Reciprocal chang-

- es in cervical alignment after thoracolumbar arthrodesis for adult spinal deformity. *Spine (Phila Pa 1976)* 2019;44:E1311-6.
55. Mizutani J, Strom R, Abumi K, et al. How cervical reconstruction surgery affects global spinal alignment. *Neurosurgery* 2019;84:898-907.
  56. Yagi M, Takeda K, Machida M, Asazuma T. Discordance of gravity line and C7PL in patient with adult spinal deformity: factors affecting the occiput-trunk sagittal discordance. *Spine J* 2015;15:213-21.
  57. Hyun SJ, Kim KJ, Jahng TA. The differential effect of cervical kyphosis correction surgery on global sagittal alignment and health-related quality of life according to head-and trunk-balanced subtype. *J Neurosurg Spine* 2021 Apr 2 [Epub]. <https://doi.org/10.3171/2020.9.SPINE201309>
  58. Mizutani J, Verma K, Endo K, et al. Global spinal alignment in cervical kyphotic deformity: the importance of head position and thoracolumbar alignment in the compensatory mechanism. *Neurosurgery* 2018;82:686-94.
  59. Miyamoto H, Hashimoto K, Ikeda T, Akagi M. Effect of correction surgery for cervical kyphosis on compensatory mechanisms in overall spinopelvic sagittal alignment. *Eur Spine J* 2017;26:2380-5.
  60. Daubs MD, Hung M, Neese A, et al. Scoliosis research society-22 results in 3052 healthy adolescents aged 10 to 19 years. *Spine (Phila Pa 1976)* 2014;39:826-32.
  61. Tang JA, Scheer JK, Smith JS, et al. The impact of standing regional cervical sagittal alignment on outcomes in posterior cervical fusion surgery. *Neurosurgery* 2012;71:662-9.
  62. Diebo BG, Varghese JJ, Lafage R, Schwab FJ, Lafage V. Sagittal alignment of the spine: what do you need to know? *Clin Neurol Neurosurg* 2015;139:295-301.
  63. Ames CP, Smith JS, Eastlack R, et al. Reliability assessment of a novel cervical spine deformity classification system. *J Neurosurg Spine* 2015;23:673-83.
  64. Pierce KE, Passias PG, Brown AE, et al. Prioritization of realignment associated with superior clinical outcomes for cervical deformity patients. *Neurospine* 2021;18:506-14.
  65. Hyun SJ, Han S, Kim KJ, Jahng TA, Kim HJ. Assessment of T1 slope minus cervical lordosis and C2-7 sagittal vertical axis criteria of a cervical spine deformity classification system using long-term follow-up data after multilevel posterior cervical fusion surgery. *Oper Neurosurg (Hagerstown)* 2019;16:20-6.
  66. Virk S, Passias P, Lafage R, et al. Intraoperative alignment goals for distinctive sagittal morphotypes of severe cervical deformity to achieve optimal improvements in health-related quality of life measures. *Spine J* 2020;20:1267-75.