

# Localizing a metabolic focus during a functional seizure with fluorodeoxyglucose positron emission tomography-computed tomography

### ABSTRACT

Traumatic brain injuries can lead to long-term mental seizures that are difficult to differentiate from dissociative psychogenic symptoms, respectively, psychogenic nonepileptic seizures. Recent articles have drawn attention to the need of differentiation of psychological and brain trauma-related symptoms in survivors of violence. This case study reflects a diagnostic step in a 20-year-male who reported to have been subjected to torture, including blunt force to the head 2 years before examination. He suffers from episodic headaches followed by mental bouts of aggression and restlessness. We performed a brain  $^{18}\text{F}$ -fluorodeoxyglucose positron emission tomography (PET)-computed tomography to identify a cerebral correlate of the psychogenic seizures. The examination yielded a hypermetabolic focus in the frontal superior parasagittal region. Psychogenic seizures can frequently be observed as culture-specific "idioms of distress" and can challenge diagnostic evaluation, especially in the victims of violence with an additional history of blunt brain trauma. The advances in molecular imaging such as PET can be expected to play a crucial role in forensic and clinical assessment in the increasing number of such patients.

**Keywords:** Brain imaging, fluorodeoxyglucose positron emission tomography, functional seizures, posttraumatic stress disorder, torture

### INTRODUCTION

Traumatic brain injuries can lead to long-term mental seizures that are difficult to differentiate from dissociative psychogenic symptoms, respectively, psychogenic nonepileptic seizures (PNES).<sup>[1]</sup>

It has been estimated that 10%–30% of patients with suspected epilepsy in fact suffer from nonepileptic events. Some authors suggest that head injury may contribute to the pathogenesis of PNES.<sup>[1]</sup>

Recent articles have drawn attention to the need of differentiation of psychological and brain trauma-related symptoms in survivors of violence.<sup>[2]</sup> Treatment would differ substantially, as culture-sensitive psychotherapy and psychopharmacological treatment would usually be provided in PNES, which might be inefficient or might require substantial adaptation of the treatment regime in brain trauma patients.

We describe the case of a 20-year-male who reported to have been subjected to torture in his home country Afghanistan about 2 years ago. Afghan refugees have been recognized as an especially highly distressed population in a recent review.<sup>[3]</sup>

**SIROOS MIRZAEI<sup>1,2</sup>, BARBARA PREITLER<sup>2</sup>, THOMAS WENZEL<sup>3,4</sup>**

<sup>1</sup>Institute of Nuclear Medicine with PET-Center, Wilhelminenspital, <sup>2</sup>Hemayat, Organisation for Support of Victims of Torture and War, <sup>3</sup>Department of Psychiatry, Medical University of Vienna, Vienna, Austria, <sup>4</sup>World Psychiatric Association Section of Psychological Aspects of Torture and Persecution, Geneva, Switzerland


**Address for correspondence:** Prof. Siroos Mirzaei, Wilhelminenspital, Montleartstrasse 37, 1160 Vienna, Austria. E-mail: mirzaei@gmx.at

**Submitted:** 21-Feb-2020, **Revised:** 02-Apr-2020, **Accepted:** 04-Apr-2020, **Published:** 27-Jun-2020

This is an open access journal, and articles are distributed under the terms of the Creative Commons Attribution-NonCommercial-ShareAlike 4.0 License, which allows others to remix, tweak, and build upon the work non-commercially, as long as appropriate credit is given and the new creations are licensed under the identical terms.

**For reprints contact:** WKHLRPMedknow\_reprints@wolterskluwer.com

**How to cite this article:** Mirzaei S, Preitler B, Wenzel T. Localizing a metabolic focus during a functional seizure with fluorodeoxyglucose positron emission tomography-computed tomography. World J Nucl Med 2021;20:96-8.

Access this article online	
<b>Website:</b> <a href="http://www.wjnm.org">www.wjnm.org</a>	<b>Quick Response Code</b> 
<b>DOI:</b> 10.4103/wjnm.WJNM_22_20	

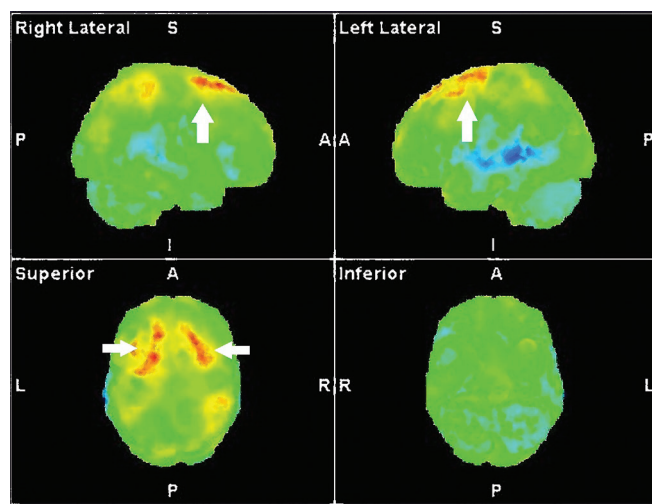
## CASE REPORT

The patient reported to have been subjected to torture, including blunt force to the head 2 years before examination.

He suffered from episodic headaches that were followed by mental bouts of aggression and restlessness, with no history of any symptom before the alleged torture.

No other illnesses were known. Neurological examination was unremarkable. Electroencephalography (EEG) and magnetic resonance imaging (MRI) of the brain yielded no pathological findings; psychiatric assessment yielded a diagnosis of posttraumatic stress disorder and dysthymia.<sup>[4]</sup>

The “seizures” were refractory to long-term psychotherapy and psychopharmaca. We performed a brain <sup>18</sup>F-fluorodeoxyglucose (<sup>18</sup>F-FDG) positron emission tomography computed tomography (PET-CT) (Siemens Healthineers, Biograph mCT 20, Erlangen) to identify a cerebral correlate of the psychogenic seizures, as it is done in the ictal PET.<sup>[5]</sup> During the presentation in the nuclear medicine department, the patient developed a “seizure” which was typical according to the accompanied caregiver with headache and dysthymia. After information and written consent, he was administered 177 MBq <sup>18</sup>F-FDG during the onset of one “seizure.” A software-based analysis compared to an age-matched normal collective on a Syngovia workstation (Siemens Healthineers, Erlangen) yielded a hypermetabolic focus [Figure 1] in the frontal superior parasagittal region, accentuated on the left side.



**Figure 1:** <sup>18</sup>F-fluorodeoxyglucose positron emission tomography-computed tomography of the brain after voxel-based comparison of the metabolic positron emission tomography images with an age-matched normal control group a hypermetabolic focus in the left frontal area was found. The illustrated statistical parametrical mapping images (right lateral, left lateral, and superior and inferior views) show this area in red color (white arrows)

## DISCUSSION

### Etiology and demographics

Traumatic brain injuries can lead to seizures that are often difficult to differentiate from dissociative psychogenic symptoms, respectively, PNES.<sup>[6]</sup> Recent articles have drawn attention to the need of better differentiation of psychological and brain trauma-related symptoms in survivors of violence<sup>[7]</sup> such as war or torture-related events who are frequently suffering from a combination of both factors.

### Clinical and imaging findings

The above-described brain metabolic brain study revealed a hypermetabolic focus [Figure 1] in the superior frontal parasagittal region. Psychogenic (dissociative or “conversion” nonepileptic) seizures can frequently be observed as culture-specific “idioms of distress”<sup>[8]</sup> and can challenge diagnostic evaluation, especially in victims of violence, which was the final diagnosis of the interdisciplinary team.

### Treatment and prognosis

The patient continued with psychotherapy. Anticonvulsive treatment was discussed, but according to a lack of data on their successful use in PNES, not given. To our knowledge, it is the first report of a metabolic PET-CT image of a patient during the onset of a psychogenic seizure after suspect complex, including psychological and possible blunt brain trauma.

### Differential diagnoses

EEG or even Magnetic Resonance Tomography (MRT) are frequently inconclusive in psychogenic seizures and might not help to differentiate etiology. Advances in molecular imaging such as especially <sup>18</sup>F-FDG PET can be expected to play a crucial role for differential diagnosis in forensic and clinical assessment in the increasing number of such patients. This might also be relevant in regard to forensic questions such as those outlined in the UN/WMA Istanbul protocol for the documentation and investigation of torture due to the frequent combination of both factors.

## CONCLUSION

Psychogenic seizures can frequently be observed as culture-specific “idioms of distress” and can challenge diagnostic evaluation, especially in the victims of violence with an additional history of blunt brain trauma. Advances in molecular imaging such as PET can be expected to play a crucial role in forensic and clinical assessment in the increasing number of such patients.

### Declaration of patient consent

The authors certify that they have obtained all appropriate patient consent forms. In the form, the patient has given his

consent for his images and other clinical information to be reported in the journal. The patient understands that name and initials will not be published and due efforts will be made to conceal identity, but anonymity cannot be guaranteed.

#### Financial support and sponsorship

Nil.

#### Conflicts of interest

There are no conflicts of interest.

#### REFERENCES

1. Auxéméry Y, Hubsch C, Fidelle G. Psychogenic non epileptic seizures: A review. *Encephale* 2011;37:153-8.
2. Keatley E, d'Alfonso A, Abeare C, Keller A, Bertelsen NS. Health outcomes of traumatic brain injury among refugee survivors of torture. *J Head Trauma Rehabil* 2015;30:E1-8.
3. Alemi Q, James S, Cruz R, Zepeda V, Racadio M. Psychological distress in afghan refugees: A mixed-method systematic review. *J Immigr Minor Health* 2014;16:1247-61.
4. American Psychiatric Association. *Diagnostic and Statistical Manual of Mental Disorders. DSM-5*. 5<sup>th</sup> ed. Washington DC: American Psychiatric Association; 2013.
5. Meltzer CC, Adelson PD, Brenner RP, Crumrine PK, Van Cott A, Schiff DP, *et al.* Planned ictal FDG PET imaging for localization of extratemporal epileptic foci. *Epilepsia* 2000;41:193-200.
6. Auxéméry Y, Hubsch C, Fidelle G. Psychogenic non epileptic seizures: A review. *Encephale* 2011;37:153-8.
7. Keatley E, d'Alfonso A, Abeare C, Keller A, Bertelsen NS. Health outcomes of traumatic brain injury among refugee survivors of torture. *J Head Trauma Rehabil* 2015;30:E1-8.
8. Im H, Ferguson A, Hunter M. Cultural translation of refugee trauma: Cultural idioms of distress among Somali refugees in displacement. *Transcult Psychiatry* 2017;54:626-52.