

Available online at [www.sciencedirect.com](http://www.sciencedirect.com)

ScienceDirect

journal homepage: [www.elsevier.com/locate/radcr](http://www.elsevier.com/locate/radcr)

## Case report

# Medical treatment of brain aspergilloma followed by MRI: A case report

Abdulwahab F. Alahmari, B.Sc.

College of Medicine, King Saud University, Riyadh, Saudi Arabia

## ARTICLE INFO

## Article history:

Received 3 June 2018

Revised 29 August 2018

Accepted 28 September 2018

Available online 26 October 2018

## Keywords:

Brain aspergilloma

Aspergilloma

Aspergillus

MRI

CT

## ABSTRACT

This is a brain aspergilloma case in an immunocompetent patient who suffered from a rare fungal infection transmitted from the mediastinum to the brain and eventually caused pancreatitis. This fungal infection affected the thalamus, hypothalamus, and extended to the midbrain. This case showed a good prognosis for the brain aspergilloma without need for any surgical intervention. The radiological documentation for the brain aspergilloma shows a positive response to a combination of voriconazole and Keppra.

© 2018 The Authors. Published by Elsevier Inc. on behalf of University of Washington.

This is an open access article under the CC BY-NC-ND license.

(<http://creativecommons.org/licenses/by-nc-nd/4.0/>)

## Case report

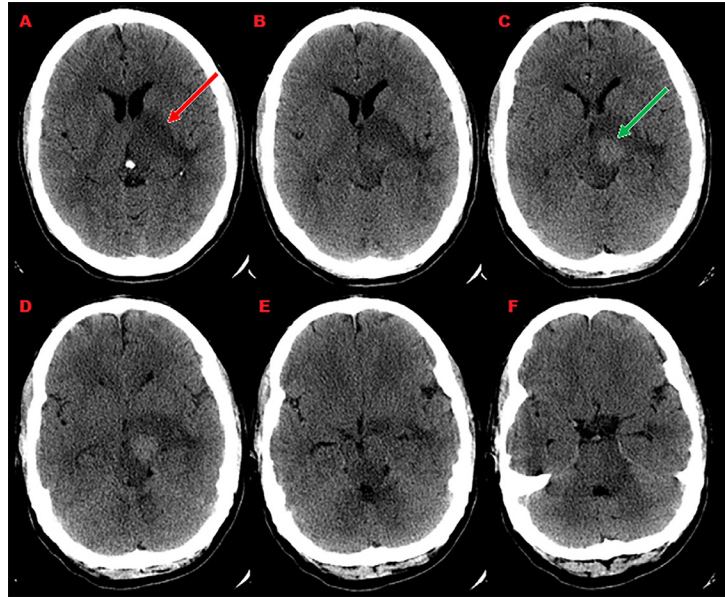
A 32-year-old male patient who came to the emergency room at King Khalid University Hospital (King Saud University) complained of a severe migraine. After a routine clinical examination, the patient was referred for a computed tomography (CT) scan, which showed a normal brain. The physician on duty prescribed Propranolol and Imipramine to the patient to decrease the pain. The patient then visited the emergency room many times in 8 years with the same complaint and the same prescription was given to him.

Then after an additional 2 years, he came in with a migraine, left orbital pain, a headache, and vomiting. In the physical examination, the patient had unilateral severe ptosis on the left side. The CT scan was performed a second time and revealed deep left intracerebral bleeding in the

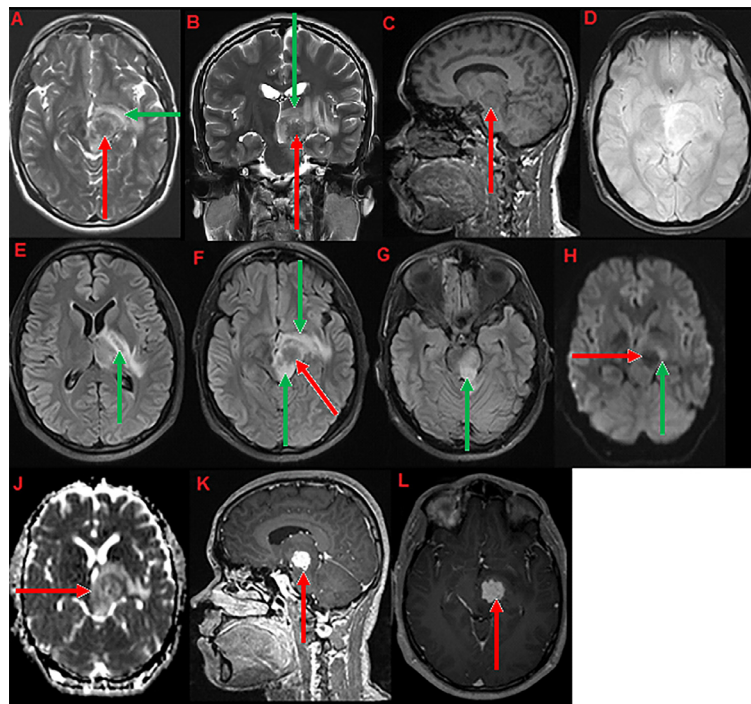
hypothalamus as shown in Fig. 1. The patient's status was stable, conscious glasgow coma scale (GCS) 15/15 and was not required any surgical intervention, even though the CT scan showed bleeding. The patient had the following vital signs: blood pressure (BP): 120/83, pulse rate (PR): 89, respiratory rate (RR): 15, temperature (T): 37.4. The patient was transferred to the neurosurgery department for monitoring. A magnetic resonance imaging (MRI) was performed the next day, and it revealed that the patient had a 32.4526.45 mm thalamic tumor affecting the thalamus and the hypothalamus as shown in Fig. 2.

A biopsy, in this case, cannot be obtained due to the tumor's location. Twelve days later, an MRI perfusion was performed, and it showed primary lesion as a focused decrease of the values as seen in Fig. 3. Keratoconus was noticed at this stage and the patient was complaining of blurry and distorted vision. Suddenly, the patient started experiencing a

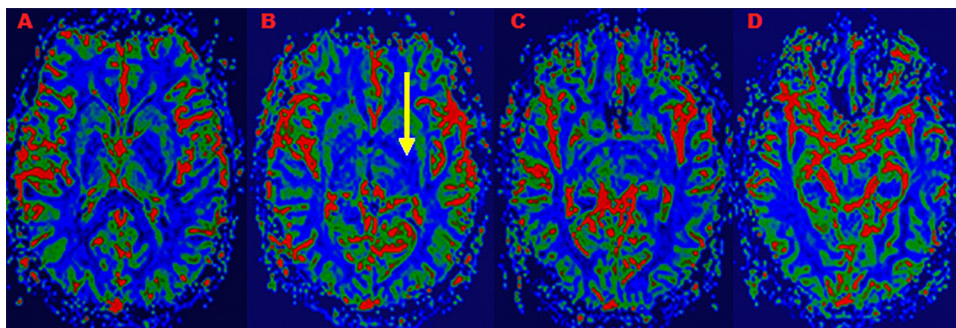
E-mail address: [abdulwahabalahmari@yahoo.com](mailto:abdulwahabalahmari@yahoo.com)<https://doi.org/10.1016/j.radcr.2018.09.021>1930-0433/© 2018 The Authors. Published by Elsevier Inc. on behalf of University of Washington. This is an open access article under the CC BY-NC-ND license. (<http://creativecommons.org/licenses/by-nc-nd/4.0/>)



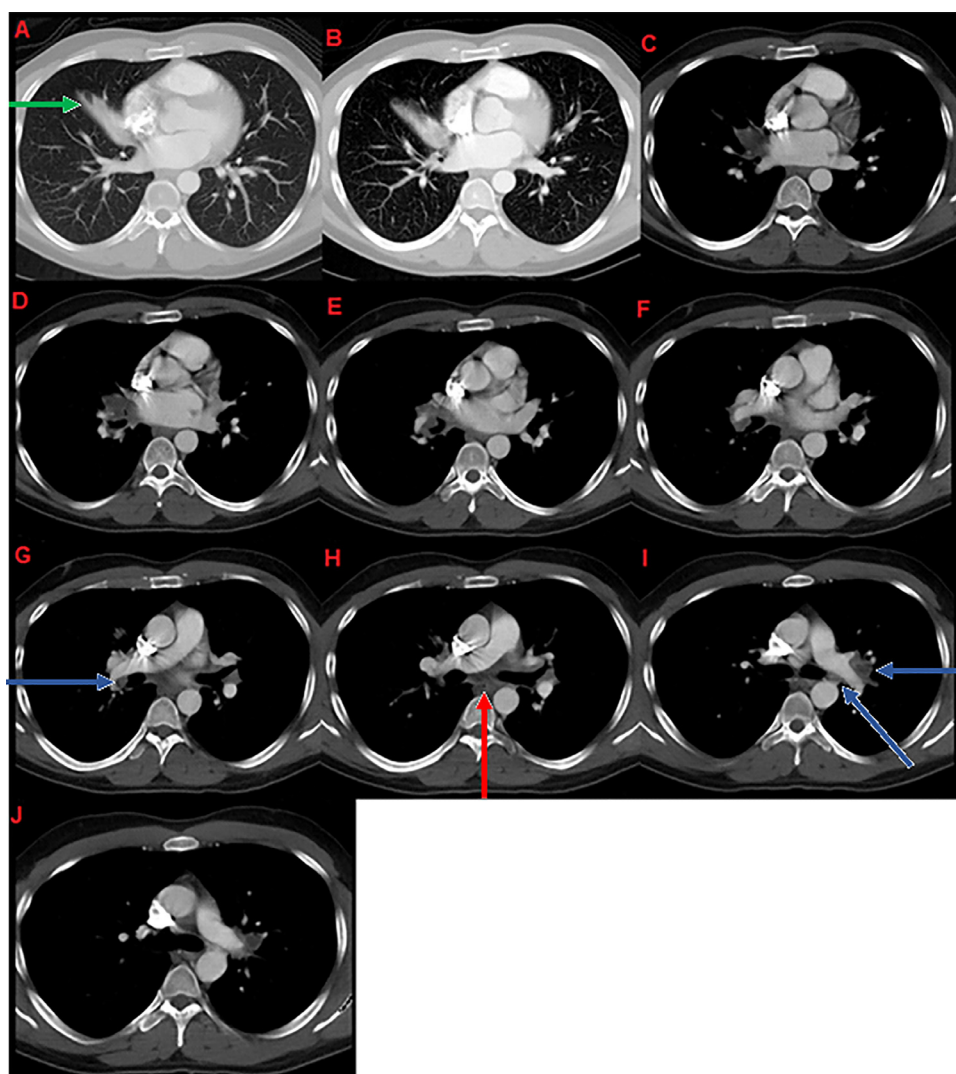
**Fig. 1 – (Forty-two-year male)** The brain CT axial with contrast shows a hyperdense focus in the left thalamus and midbrain which was thought to represent hemorrhage (green arrow) at initial interpretation with surrounding hypodensity which most likely represents edema (red arrow).



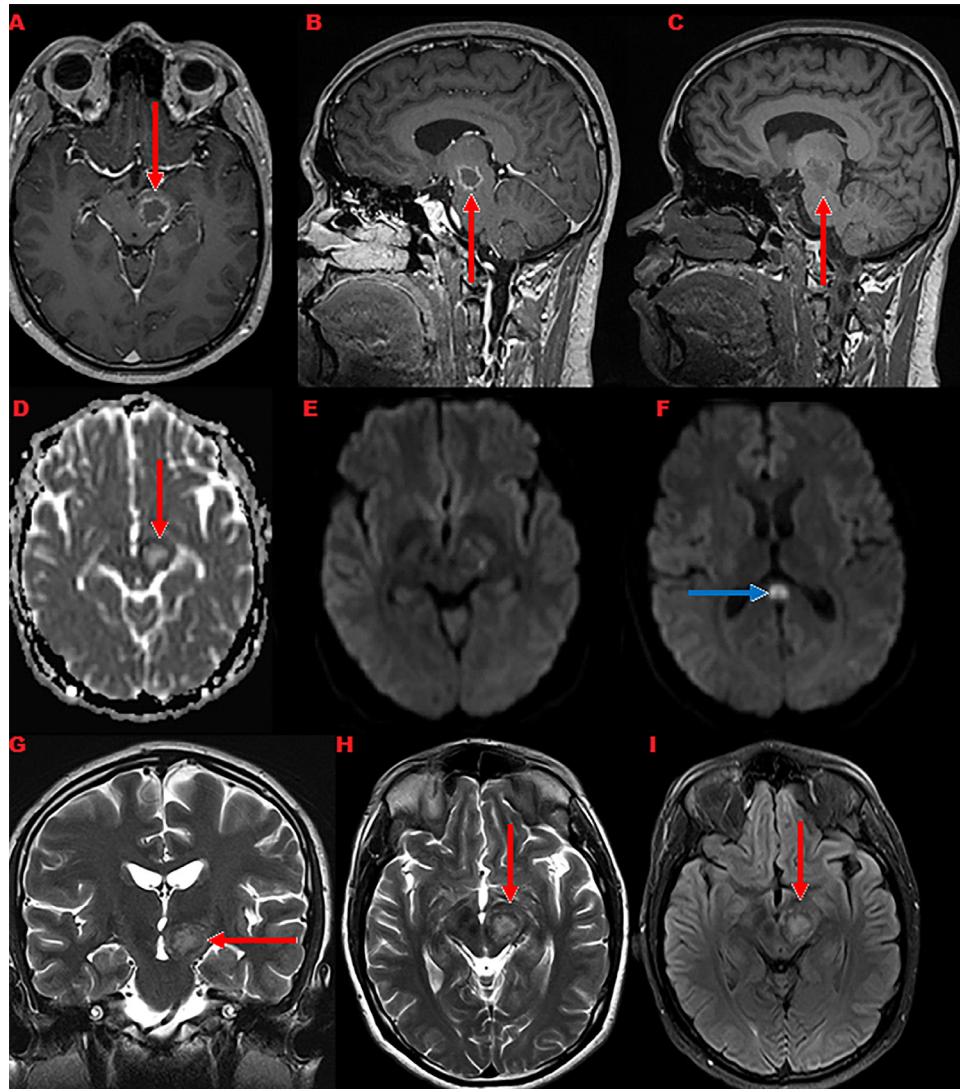
**Fig. 2 – (Forty-two-year male)** The brain MRI axial T2 (A), coronal T2 (B) show primary focus of decreased signal intensity (red arrow) with surrounding edema of increased signal intensity (green arrow) in the thalamus and midbrain. The sagittal T1 (C) shows mixed isointense to hypointense with mild focal mass effect over the third ventricle. The axial gradient echo image (D) shows no evidence of hemorrhage. The axial FLAIR images (E, F, G) show hypointense primary focus with hyperintense surrounding edema. The DWI (H) shows edema is out of proportion to the size of the primary lesion. It shows the primary focus as hypointense with intense enhancement of the primary focus with irregular outline. The ADC map (I) the initial impression based on these images was a mass lesion, with suspicion of tumor versus infection. The sagittal and axial post contrast images respectively (K, L) show bright homogenous enhancement with irregular outline due to necrosis and fungal vascular involvement. (For interpretation of the references to color in this figure legend, the reader is referred to the web version of this article.)



**Fig. 3 - (Forty-two-year male)** The brain MRI perfusion rCBV maps show the primary lesion as focus decreased of values compared to normal appearance of the white matter (yellow arrow). Based on this observation, the possibility of infection like tuberculosis was considered as first possibility. (For interpretation of the references to color in this figure legend, the reader is referred to the web version of this article.)



**Fig. 4 - (Forty-two-year male)** The chest CT axial with contrast shows bilateral hilar and subcarinal lymphadenopathy. Soft tissue or lung window (A, B) and mediastinal window (C-J). The CT shows bilateral hilar (blue arrows), and subcarinal (red arrow) lymphadenopathy with very low-density center suggestive of necrosis. There is also partial atelectasis (green arrow) in the right middle lobe. The findings are thought to be due to infective process like tuberculosis. (For interpretation of the references to color in this figure legend, the reader is referred to the web version of this article.)



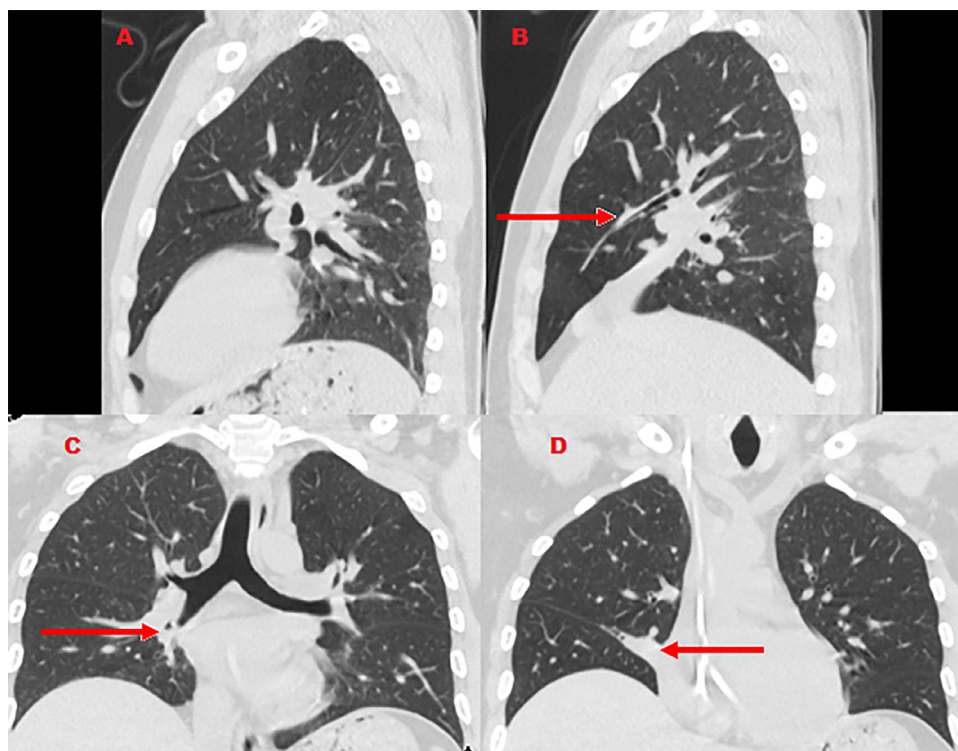
**Fig. 5 – (Forty-two-year male)** The brain MRI axial T2 (A), sagittal T2 (B, C), axial ADC map (D), axial DWI (E, F), coronal T2 (G), axial T2 (H), and axial FLAIR (I) show a remarkable resolution of surrounding edema around the lesion with some decrease in size of the enhancing lesion (red arrow) in the midbrain. The center of the lesion is hyperintense on T2 and FLAIR images and pattern of enhancement has also changed from the previous scan with central non-enhancing area and ring enhancement. The focus of diffusion restriction is seen in the splenium of corpus callosum (blue arrow). (For interpretation of the references to color in this figure legend, the reader is referred to the web version of this article.)

chest pain accompanied with coughing. The chest X-ray was not clear, and the decision was made for a CT scan which revealed bilateral hilar and subcarinal lymphadenopathy with a very low-density center, suggestive of necrosis as shown in Fig. 4. There was also partial atelectasis in the right middle lobe. The findings were thought to be tuberculosis due to an infective process. A laboratory test of an endotracheal biopsy taken in the histopathology lab, using PAS and GMS fungal stain +ve+, showed a result of granulomatous inflammation with focal necrosis and fungal infection. The patient underwent bronchial lavage, which showed fungal elements were present in acute and chronic inflammation cells, which recommended a bronchial wash cytology. Unfortunately, the fungal elements were still present with acute and chronic inflammation cells, even after the wash. An endobronchial biopsy

showed septate fungal hyphae and *A. flavus* was found in the pulmonary secretions.

The laboratory test came back and there was no evidence of immune disease: HIV 1 and 2: negative, CGD: negative, WBC: 15,000/mcl, CH50: 45, C3, and C4: normal, HBCAb: negative, HB-SAg: negative. IgA, IgE, IgG, IgM: normal, and Hb: 149 m/dL. Furthermore, the patient was not under immune suppressant medications or steroids.

After being under medication for more than one month, a follow-up MRI was performed, which showed disseminated *Aspergillus*. One month later, the patient experienced a progressive invasive *Aspergillus* in the brain, affecting the mid-brain and causing right hemiparesis. On the neurological examination, the patient suffered from unilateral ptosis on the left side, tremors, numbness, hemiparesis, and kerato-



**Fig. 6 – (Forty-two-year male) The chest HRCT sagittal (A, B) and coronal (C, D) show a significant resolution of the collapsed lateral segment of the right middle lobe with no sign of hilar or mediastinal lymphadenopathy.**

conus. A medical team from different departments agreed on a treatment plan that included a combination of Keppra (Levetiracetam) 500 mg, two times a day, Neurontin (Gabapentin) 400 mg, three times a day, and Voriconazole (Voraze). The Voriconazole was given 6 mg per kg twice a day, which led to an improved patient status and it reduced the volume of the brain aspergilloma after persistence on treatment for two months as shown in Fig. 5. The tremor was less, compared to the previous visit, and there was no numbness according to the patient.

It was followed by chest high resolution computed tomography (HRCT), which showed a collapsed lateral segment of the right middle lung but no sign of hilar or mediastinal lymphadenopathy, which was considered progress as shown in Fig. 6. In this stage, the plan was to decrease the dose of the voriconazole to 4 mg/kg twice a day and then repeat MRI after 6 months.

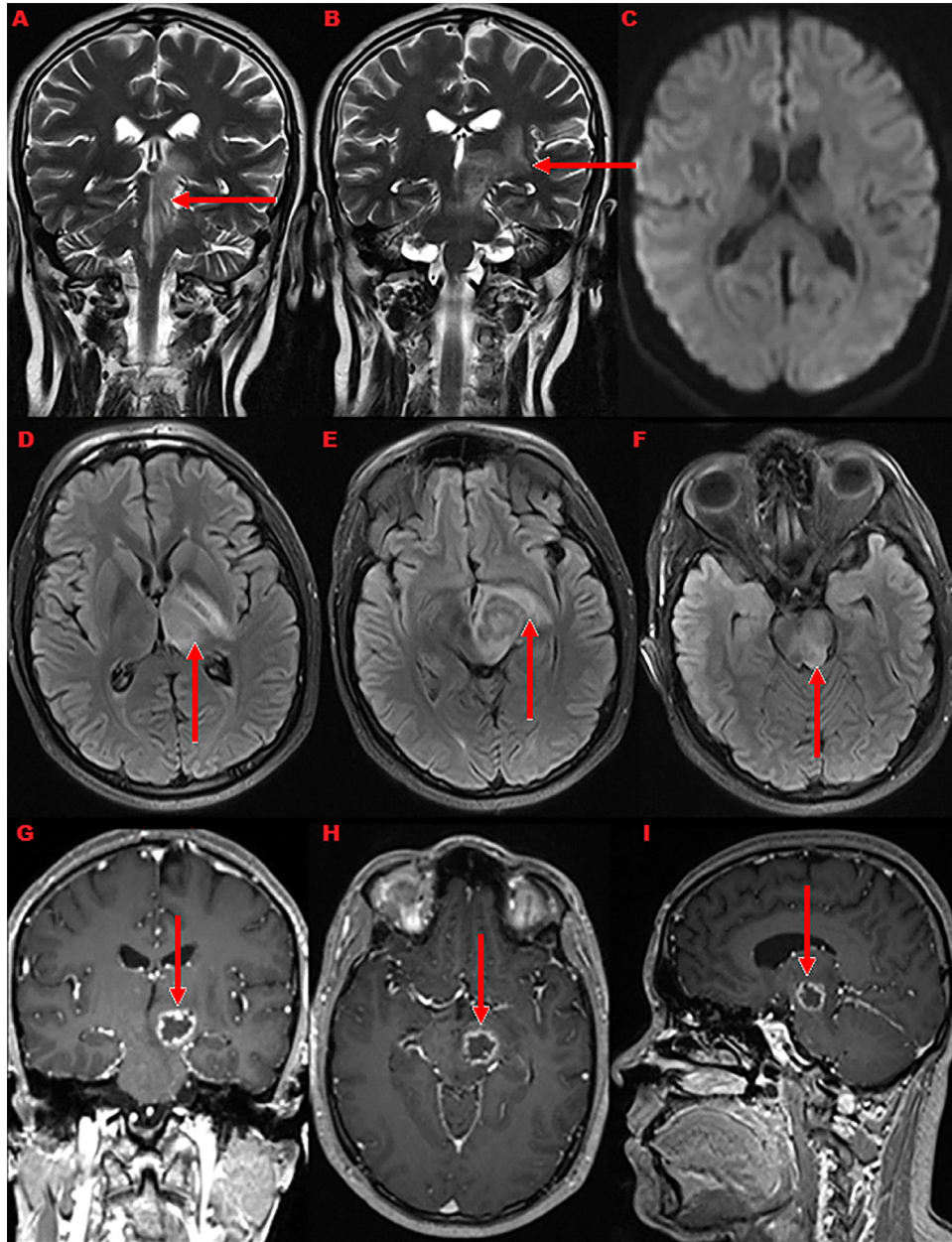
The patient felt very well, and refused to continue the treatment, and he left the hospital. However, his physician insisted that he should come every month for a follow-up and to continue using the medications regularly. During the follow-up visits; five MRI scans and one HRCT were performed for the chest. The patient stopped the medications by himself for 4 months and an MRI scan showed that the brain lesion was still the same size and increased the edema see Fig. 7. Later, a CT scan for the abdomen showed pancreatitis, which is medically considered a prognostic complication of the aspergilloma as shown in Fig. 11.

The doctor prescribed Keppra again with antifungal to the patient. After one month of persistence with the treatment, there was a reduction of the chest infection on HRCT, but no change in the brain was reported. The plan in this stage was to continue medication with Voriconazole, continue MRI follow-ups, and refer the patient to physiotherapy. After three months, the brain tumor that appeared on the MRI was a very small hyperintense dot, while the patient experienced no symptoms or complaints, as seen in Fig. 10.

This case is an example of the rare presentation of aspergilloma, where the patient's immune system was normal according to lab tests although the infection affected the brain and pancreas as well. The patient data and scans follow-ups for more than ten years are available, which shows progress in response to the treatment, with the brain lesion shrinking in direct relation to elimination of the chest infection.

## Discussion

A fungal infection that affects the central nervous system (CNS) is the result of the neuroimmune system's failure to detect or defend the nervous system from any harmful organisms. Aspergilloma is a fungal infection that rarely affects the CNS through hematogenous distribution. The clinical presentation of brain aspergilloma typically includes a headache, decreased consciousness, seizures, palsy of the sixth nerve, and increased intracranial pressure [1]. Radiologically, it can



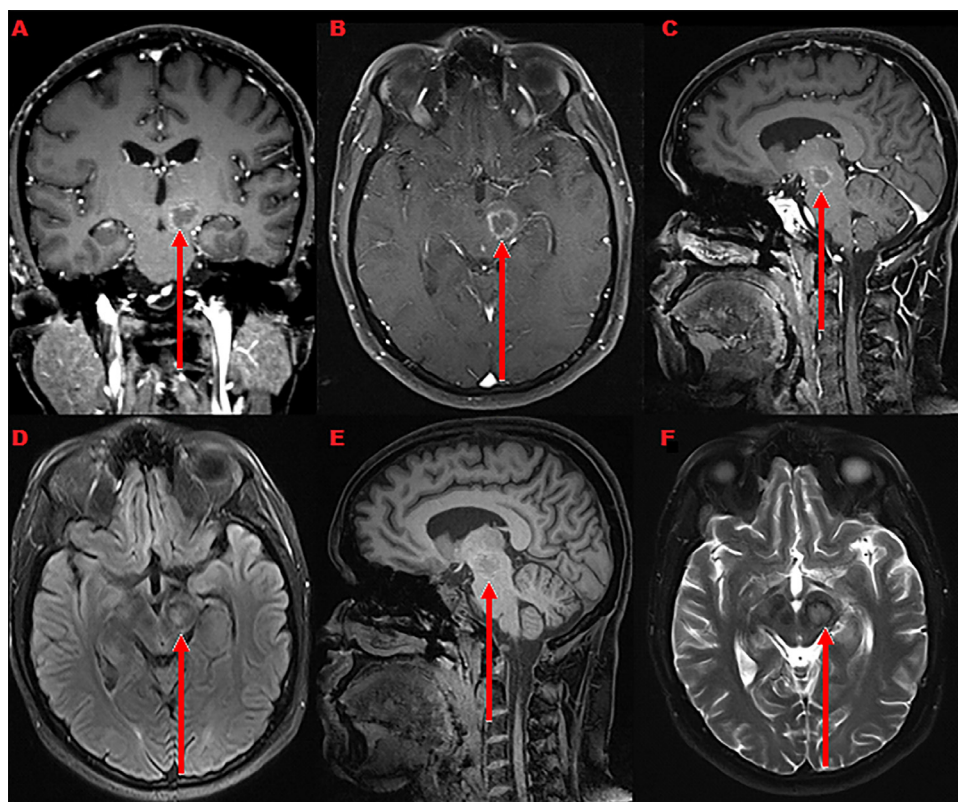
**Fig. 7 – (Forty-three-year male)** The brain MRI coronal T2 (A, B), DWI axial (C), axial FLAIR (D, E, F), coronal T1 with contrast (G), axial T1 with contrast (H), and sagittal T1 with contrast (I) show the brain lesion still with same size and increased the edema. The coronal T2 and axial FLAIR images show increased edema around the lesion compared to previous study. The enhancing lesion remains almost same in size and pattern. The diffusion restricted focus in the splenium of corpus callosum has resolved (C).

be mistakenly diagnosed either as a brain tumor, a hemorrhage, or an abscess.

Aspergilloma is one of the *Aspergillus* molds, which is characterized by saprophytic involvement of the body in the form of a fungal ball. Typically, aspergilloma starts as a fungal growth inside a cavity which was formed by a previous disease. Aspergilloma spore penetrate then, germinate in the cavity. Eventually, the aspergilloma will form a ball inside the cavity. Aspergilloma spreads by hematogenous dissemination into the CNS, paranasal sinuses, and respiratory tract.

#### Etiology and demographics

The prevalence of aspergilloma in CNS is very rare in immunocompetent patients. Aspergilloma infects patients who have CGD, AIDS, or under immune suppressant medications (i.e., for organ transplantation). Nontypical radiological signs are shown in immunocompetent host cases [2]. The most common cultured pathogen in immune component hosts is *A. flavus*, especially in hot and dry regions [2].



**Fig. 8 – (Forty-three-year male) The brain MRI coronal T1 with contrast (A), axial T1 with contrast (B), sagittal T1 with contrast (C), axial FLAIR (D), sagittal T1 without contrast (E), and axial T2 (F) show remarkable decrease in the surrounding edema with minimal decrease in size of the ring enhancing lesion.**

The fungi of *Aspergillus* spreads through respiration, which explains commonly affected sites which are the maxillary sinuses and the respiratory system [3]. The fungi can spread through hematogenous dissemination or directly through bone to the brain [2]. *Aspergillus* remains outer to the dura mater and in some cases, it can penetrate the dura mater, then start secreting necrotizing material, which participates in brain lesions [4]. Other types of aspergilloma are activated with heat and some can be heat resistant [4]. The severity of aspergilloma depends on the plurality of abscess, vascular inclusion, and presence of thrombosis.

#### Clinical and imaging findings

Hyphae fungi affect all vessels and commonly affect the anterior and middle cerebral arteries. This may induce a hemorrhagic infarction, which could contain gliotic tissue in order to avoid hemorrhagic spread. In acute cases, aspergilloma may contain pus, and in chronic cases, may contain seminecrotic areas [4]. In early stage, aspergilloma is invisible on CT or MRI [5].

In more progressed stages, a typical lesion is infarcted, and it starts forming an abscess combined with ring enhancement, which usually involves vascular infiltration coming from orbit or paranasal sinuses. This may form intra-axial or extra-axial space occupying lesion [6]. On CT images, the lesion appears hyperdense with calcification, and mass effect signs may be

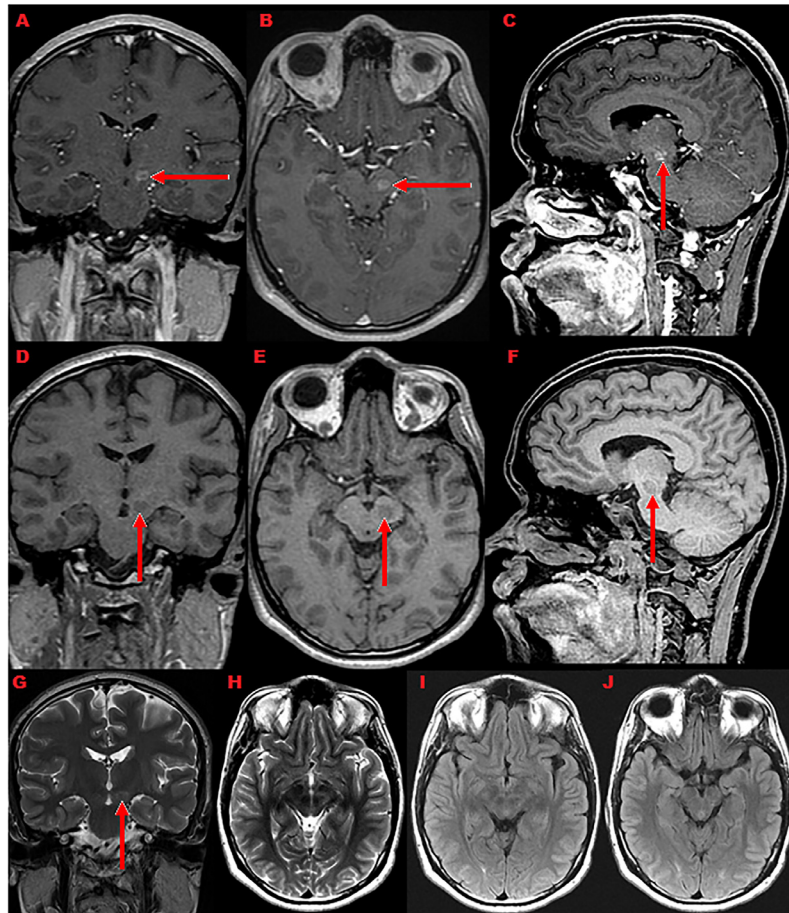
visualized [1]. The abscess appears homogeneous with ring enhancement and low absorption area, without contrast enhancement.

On MRI images, show irregular space occupying lesion from isointense to hypointense. On T1 post gadolinium, there is a bright homogenous ring enhancement due to necrosis, fungal, and vascular involvement. On T2, the mass appears as primary focus of decreased signal intensity with surrounding edema of increased signal intensity [7]. On diffusion-weighted imaging, the aspergilloma lesion appears as a small infarction and the edema is out of proportional size to the primary lesion [1].

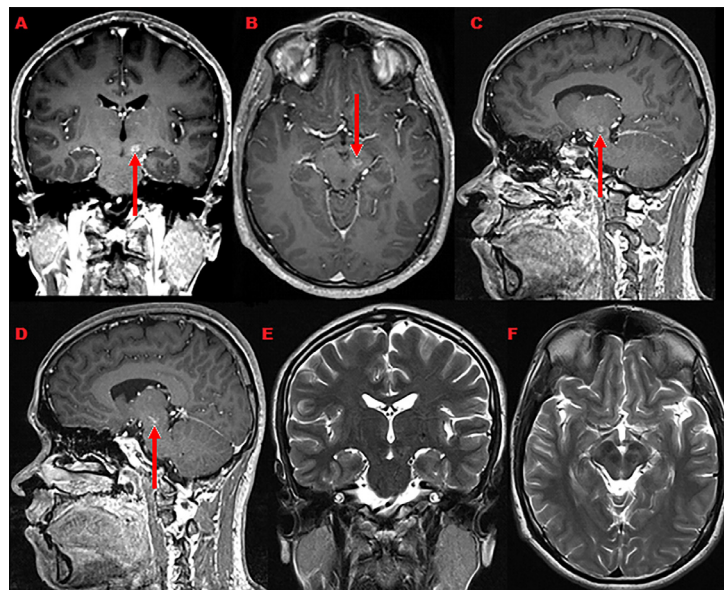
Aspergilloma usually affects the thalamus through thalamoperforator or lenticulostriate vessel more common than corticomedullary [8]. The frontal and temporal lobes are the areas most affected by aspergilloma [9]. The thrombotic infarcts or pyogenic granuloma infection does not occur in the corpus callosum [10].

#### Treatment and prognosis

CNS aspergilloma and the associated neurological affect can be treated with a combination of antifungal medication, Voriconazole, and Keppra. CNS aspergilloma has poor prognosis in AIDS patients [11]. Eventually, the prognosis in this case was good since this patient did not have HIV. This case

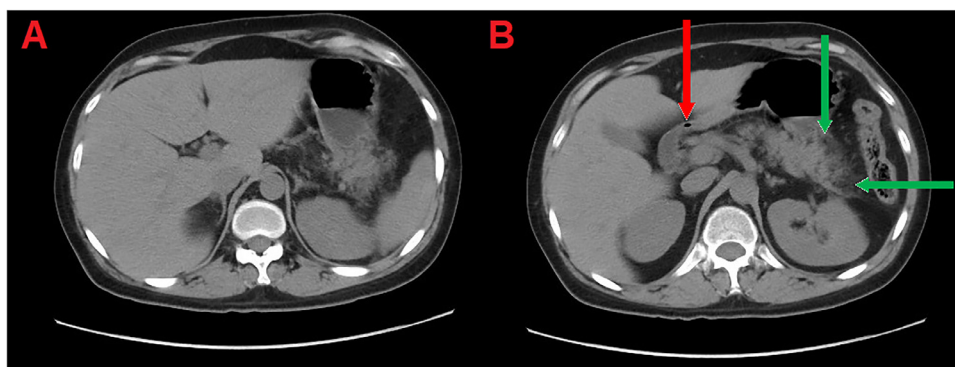


**Fig. 9** – (Forty-three-year male) The brain MRI coronal T1 with contrast (A), axial T1 with contrast (B), Sagittal T1 with contrast (C), coronal T1 (D), axial T1 with contrast (E), sagittal T1 with contrast (F), coronal T2 (G), axial T2 (H), axial T1 (I), and axial T1 (J) show shrinking of the midbrain aspergilloma.



**Fig. 10** – (Forty-three-year male) The brain MRI axial T1 with contrast (A), axial T1 with contrast (B), sagittal T1 with contrast (C), sagittal T1 with contrast (D), coronal T2 (E), and axial T2 (F) show the midbrain lesion as small hyperintense dot on T1 (red arrow). (For interpretation of the references to color in this figure legend, the reader is referred to the web version of this article.)





**Fig. 11 – (Forty-three-year-male) The abdomen CT axial at the level of the pancreatic tail (A) and pancreas (B) show the pancreatic borders diffusely swollen with peripancreatic fat stranding (green arrow) and homogenous post contrast enhancement with definite hemorrhagic or necrotic areas (red arrow). The picture is suggestive of acute pancreatitis for clinicolaboratory correlation. (For interpretation of the references to color in this figure legend, the reader is referred to the web version of this article.)**

is unique because it shows complex infection spreading in a person with an unknown immune disease.

### Teaching points

The brain aspergilloma can be confused with intracerebral bleeding on the CT scan. The combination of Keppra, Voriconazole, and antifungal medication was the best treatment for the brain aspergilloma.

### Supplementary materials

Supplementary material associated with this article can be found, in the online version, at [doi:10.1016/j.radcr.2018.09.021](https://doi.org/10.1016/j.radcr.2018.09.021).

### REFERENCES

- [1] Scully EP, Baden LR, Katz JT. Fungal brain infections. *Curr Opin Neurol* 2008;21(3):34752.
- [2] Shamim MS, Siddiqui AA, Enam SA, Shah AA, Jooma R, Anwar S. Craniocerebral aspergillosis in immunocompetent hosts: surgical perspective. *Neurol India* 2007;55(3):274.
- [3] Shankar SK, Mahadevan A, Sundaram C, Sarkar C, Chacko G, Lanje-war DN, et al. Pathobiology of fungal infections of the central nervous system with special reference to the Indian scenario. *Neurol India* 2007;55(3):198.
- [4] Speth C, Rambach G, Lass-Flrl C, Wrzner R, Gasque P, Mohsenipour I, et al. Culture supernatants of patient-derived *Aspergillus* isolates have toxic and lytic activity towards neurons and glial cells. *FEMS Immunol Med Microbiol* 2000;29(4):30313.
- [5] Sorensen AG, Buonanno FS, Gonzalez RG, Schwamm LH, Lev MH, Huang-Hellinger FR, et al. Hyperacute stroke: evaluation with combined multisection diffusion-weighted and hemodynamically weighted echo-planar MR imaging. *Radiology* 1996;199(2):391401.
- [6] Tempkin AD, Sobonya RE, Seeger JF, Oh ES. Cerebral aspergillosis: radiologic and pathologic findings 1. *Radiographics* 2006;26(4):123942.
- [7] Zinreich SJ, Kennedy DW, Malat J, Curtin HD, Epstein JI, Huff LC, et al. Fungal sinusitis: diagnosis with CT and MR imaging. *Radiology* 1988;169(2):43944.
- [8] Gabelmann A, Klein S, Kern W, Krger S, Brambs H, RieberBrambs A, et al. Relevant imaging findings of cerebral aspergillosis on MRI: a retrospective case based study in immunocompromised patients. *Eur J Neurol* 2007;14(5):54855.
- [9] Fardoun R, Rao NK, Miskeen AK. Cerebral aspergilloma. Review of the literature apropos of a case. *Neurochirurgie* 1989;36(1):4551.
- [10] da Rocha AJ, Antonio Carlos Martins Maia J, Ferreira NPFD, do Amaral LLF. Granulomatous diseases of the central nervous system. *Top Magn Reson Imaging* 2005;16(2):15587.
- [11] Greenberg AK, Knapp J, Rom WN, Addrizzo-Harris DJ. Clinical presentation of pulmonary mycetoma in HIV-infected patients. *Chest* 2002;122(3):886892.