

An Original Backup Technique to Assess the Correct Positioning of Right-sided Double-lumen Tubes without Fiberoptic Bronchoscopy: A Pilot Feasibility Study

Abstract

Background: Accurate positioning of a right-sided double-lumen tube is essential but challenging due to the location and the potential obstruction of the right upper lobe bronchus. Fiberoptic bronchoscopy is, therefore, necessary but requires a specific training period for the anesthesiologist and might not always be available. **Objective:** We describe an original backup technique to assess the correct placement of these tubes in cases a fiberoptic bronchoscopy is lacking. **Design:** Prospective pilot feasibility study with 10 adult patients scheduled for a left thoracic surgery. **Setting:** Operating theater in a university hospital. **Materials and Methods:** The new technique uses a fluoroscopy and an adult central venous catheter wire. The time needed to perform the new technique, its success rate and its efficacy in properly exclude the left lung were evaluated. Any oxygen desaturation episode ($\text{SpO}_2 < 90\%$) was considered. The technique was performed by two anesthesiologists with different experience in thoracic anesthesia. **Results:** The success rate of our technique was 90%, which did not depend on the anesthesiologist's experience. The range of time to successfully place the tube in the dorsal decubitus position and subsequently in the right lateral decubitus position was respectively 1 min–6 min and 1 min–15 min. None of the patients presented any desaturation episodes. **Conclusions:** We describe an original, safe, and acceptable backup technique to properly insert right-sided double-lumen endobronchial tubes, whenever a fiberoptic bronchoscopy is not available. Moreover, this technique is easy enough to be performed by anesthesiologists with limited experience in thoracic anesthesia.

Keywords: Double-lumen tubes, lung isolation, thoracic anesthesia

Introduction

Accurate positioning of a double-lumen tube is essential because misplacement leads to hypoxia and hypoventilation, incomplete collapse of the operative lung, contamination of the dependent lung, and an increase of postoperative lower-respiratory-tract infections.^[1]

Until the availability of suitable fiberoptic bronchoscopes, confirmation of the correct positioning of those tubes was achieved by clinical assessment: appropriate inflation of the bronchial cuff, observation of the chest wall movements and auscultation of the both lungs.^[1,2]

Otherwise, several studies conclude that the exact placement of right-sided double-lumen tubes causes more problems than placement of left-sided double-lumen tubes.^[3-6] Indeed, to place correctly a right-sided double-lumen tube, an important

notion to remember is that the right mainstem bronchus is shorter than the left bronchus and in most of the cases, the right upper lobe bronchus originates at a distance of 1.5–2 cm from the carina. Therefore, in these cases, the location and the potential obstruction of the right upper lobe bronchus must be taken into account. Accurate diagnosis of upper lobe obstruction by auscultation alone is not usually possible because breath sounds are transmitted from the ipsilateral lower lobe and across the mediastinum from the contralateral lung. According to Brodsky, the incidence of right upper lobe obstruction is still clinically unacceptable and far too high to justify the use of right-sided double-lumen tubes for routine thoracotomy. Because the risk of upper lobe collapse is great whenever a right-sided double-lumen tube is used, a bronchoscopic confirmation of the correct positioning of this type of tube is crucial.^[7]

This is an open access journal, and articles are distributed under the terms of the Creative Commons Attribution-NonCommercial-ShareAlike 4.0 License, which allows others to remix, tweak, and build upon the work non-commercially, as long as appropriate credit is given and the new creations are licensed under the identical terms.

For reprints contact: reprints@medknow.com

How to cite this article: Khalifa C, Fossoul S, Momeni M, Lacroix V, Watremez C. An original backup technique to assess the correct positioning of right-sided double-lumen tubes without fiberoptic bronchoscopy: A pilot feasibility study. *Ann Card Anaesth* 2020;23:75-9.

Céline Khalifa,
Sophie Fossoul¹,
Mona Momeni,
Valérie Lacroix²,
Christine Watremez

*Departments of Anesthesiology,
Acute and Emergency Medicine
and Cardiothoracic and
Vascular Surgery, Cliniques
Universitaires Saint-Luc,
Brussels, Belgium*

Submitted: 19-Jun-2018
Revised: 13-Aug-2018
Accepted: 16-Sep-2018
Published: 07-Jan-2020

Address for correspondence:
Dr. Céline Khalifa,
Department of Anesthesiology,
Cliniques Universitaires
Saint-Luc, Hippocrate Avenue,
10-1200 Brussels, Belgium.
E-mail: celkhalifa@gmail.com

Access this article online

Website: www.annals.in

DOI: 10.4103/aca.ACA_127_18

Quick Response Code:



However, two issues should be considered when a fiberoptic bronchoscope needs to be used for the placement and the positioning of a double-lumen tube. First, this technique requires a learning curve. Second, a bronchoscope is not always available for this indication.^[8]

Recently, because of a technical failure of our bronchoscope, we were faced with the challenging task to correctly position a right-sided double-lumen tube. Therefore, we hypothesized that managing the placement of this right-sided double-lumen tube using fluoroscopy and a central venous catheter wire could be an acceptable alternative. After managing this case with success, we decided to validate this original backup technique in 10 other patients.

Materials and Methods

Ethical approval for this study (reference number 2016/29DEC/565) was provided by “Comité d’ Ethique Hospitalo-Facultaire” from Brussels, Belgium on February 16, 2017.

This work is a pilot feasibility study in its design. It focuses on safety, learning how the technique can be implemented and whether this technique is acceptable for the proposed surgery. Therefore, we arbitrarily decided to include ten patients undergoing left thoracic surgery, without a strict indication of a right-sided double-lumen tube.

Patients were included from May 1th to December 31th, 2017. Written informed consent was obtained from all patients. The trial was registered before patient enrollment at clinicaltrials.gov (NCT03144479, Date of registration: May 8th, 2017). Exclusion criteria were emergencies, hemodynamic instability, and predictable difficult airway management.

After the induction of anesthesia and the administration of muscle relaxant, the right-sided double lumen tube (Mallinckrodt® – Endobronchial tube) was introduced into the glottis via direct laryngoscopy. Once the endotracheal lumen tube had passed through the vocal cords, the corresponding stylet was removed, the tube was rotated 90° clockwise, and advanced slightly until resistance was encountered. Auscultation was then performed to check the proper side where the endobronchial tube was inserted to. The anatomy of the carina and the origins of the right and left upper bronchus were then identified by the anesthesiologist in charge by fluoroscopy (BV-Pulsera, Philips®).

The procedure is detailed in Figures 1 and 2. After mild plication of the distal extremity of an adult central venous catheter wire (Arrow®, 0.53 mm diameter, 45 cm length, one straight soft tip on one end and one “J” tip on the other), the wire was introduced through the endobronchial lumen under fluoroscopic control. Then, it was slowly removed to achieve proper alignment between the wire extremity and the right upper lobe. The wire

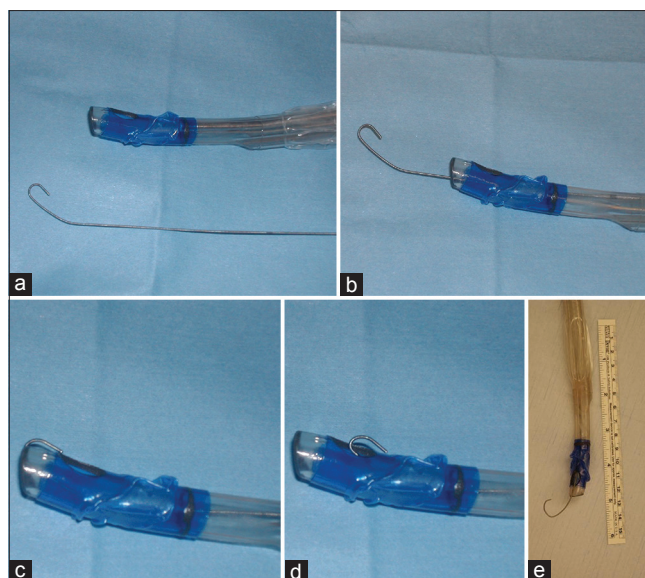


Figure 1: (In color): Different *in vitro* stages for correct placement of a right-sided double lumen tube by making use of an adult central venous catheter wire. (a) Mild plication of the supple distal extremity of the wire. (b) The wire is introduced through the endobronchial lumen. (c) The wire is slowly removed so that proper alignment between the wire extremity and the right upper lobe ventilation slot occurs. (d) The wire is removed again until its J-shaped extremity appears through the right-upper lobe ventilation slot. (e) When the location of the orifice of the right upper lobe is identified, the guide is moved forward through the slot into the upper lobe bronchus

was removed again until its J-shaped extremity appeared through the right-upper lobe ventilation orifice. To align the orifice of the tube with the upper lobe bronchus, a rotational movement of the double-lumen tube was occasionally performed. When the location of the orifice of the right upper lobe was identified, the wire was moved forward through the orifice into the upper lobe bronchus. Once a satisfactory initial placement was achieved, the wire of the central venous catheter was removed and replaced by the fiberoptic bronchoscope to confirm the correct positioning of the tube [Figure 3].

Once the patient was turned to the right lateral decubitus position, the correct placement of the double-lumen tube was again checked by the previously described technique.

At the end of the procedure, the fiberoptic bronchoscope was introduced through the tracheal lumen to visualize the blue bronchial cuff at the origin of the right mainstem bronchus below the level of the carina.

We arbitrarily decided that the entire procedure (except the time allocated to the right lateral decubitus installation), should last <20 min. Our technique was considered as a failure whenever the time required to correctly insert the tube exceeded 20 min.

For each patient, the following informations were recorded in the operating room:

- The duration of the procedure by the new technique in dorsal decubitus position, which corresponds to the radiation exposure time for this part of the technique

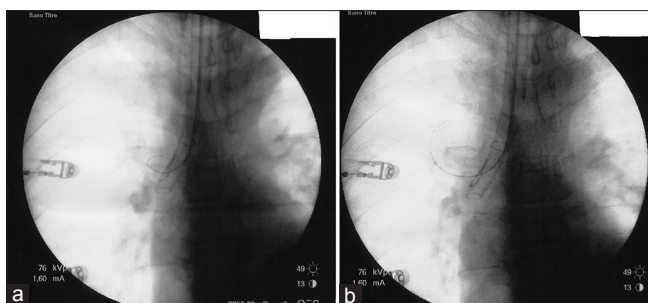


Figure 2: (In color): Radioscopy for proper placement of a right-sided double lumen tube by using a central venous catheter wire. (a) The location of the orifice of the right upper lobe is identified by virtue of the J-shaped extremity of the wire. (b) The wire is moved forward though the slot into the upper lobe bronchus

- The duration of the procedure by the new technique in the right lateral decubitus position, which corresponds to the radiation exposure time for this part of the technique
- The total amount of exposure to X-rays
- The presence of a significant desaturation during the procedure ($\text{SpO}_2 < 90\%$)
- The success rate (<20 min).

The quality of the left pulmonary exclusion as judged by the surgeon:

- Fair: The surgeon was able to operate on the lung without any replacement of the tube
- Poor: The surgeon was not able to operate on the lung without a replacement of the tube.

Results

The characteristics of the patients and intraoperative data are illustrated in Table 1. All the 10 patients underwent a thoracic surgery and were operated by a single surgeon (VL). In each case, the size of the right-sided double-lumen tube (Mallinckrodt® endobronchial tube) was chosen according to the patient's sex and height. Five patients were managed by a senior anesthesiologist experienced in thoracic anesthesia, and fiberoptic bronchoscopy handling (CW) and five other patients were managed by an anesthesiologist recently graduated (CK).

Table 2 shows the necessary information regarding the new technique.

Table 3 specifies the ventilatory parameters during the procedures.

Discussion

Since 1980's, improvements have been developed for the correct positioning of the double-lumen tubes: Circular radiograph opaque markers near the endotracheal and the endobronchial cuffs, radiograph marker surrounding the ventilation slot for the right upper lobe bronchus, bright blue-colored, low-volume, and low-pressure endobronchial cuffs for easier visualization during the fiberoptic bronchoscopy.^[3] Moreover, concerning right-sided

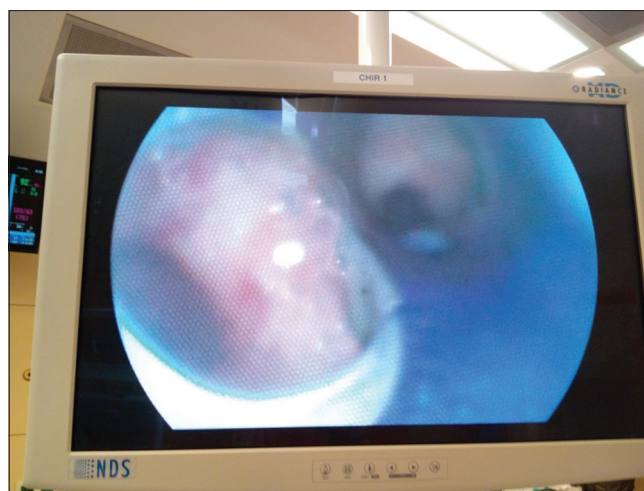


Figure 3: (In color): Validation of the new technique by fiberoptic bronchoscopy: Proper alignment between the slot and the origin of the right upper bronchus is visualized

double-lumen tubes, several designs incorporate a modified cuff or slot on the endobronchial side that allow ventilation of the right upper lobe.

Controversial results persist in the literature about the clinical performance of right-versus left-sided double-lumen tubes, in terms of adequacy of gas exchanges or sufficient deflation of the lung, even when managed by experienced anesthesiologists. Some studies still recommend the systematic use of a left-sided double-lumen tube whenever it is suitable for the procedure.^[4] Others affirm that, although there is a statistically significant difference in terms of positioning time, clinical relevance is trivial.^[6,9] Indeed, recent studies using improved placement techniques have shown no increase in the incidence of obstruction of the right upper lobe bronchus orifice with a right-sided double-lumen tube when compared to a left-sided double-lumen tube.^[6]

However, evidence strongly suggests that clinical assessment alone is insufficient and unreliable to confirm the proper placement of both right- and left-sided double-lumen tubes and that a bronchoscopic examination of the proper positioning is crucial to avoid dramatic complications.^[1] Unfortunately, fiberoptic bronchoscopy is not always available^[4] and requires a learning curve for the anesthesiologists. In this regard, approximately 20–50 surgical cases under supervision are required to perform fiberoptic bronchoscopy examinations in an autonomous way, depending on the possibility to attend simulation exercises.

In this manuscript, we propose a simple alternative backup technique to assess the exact placement and positioning of a right-sided double-lumen tube using materials which are probably easier to obtain in an operating room: A central venous catheter wire and a fluoroscopy device. In order to analyze the feasibility of this technique, we decided to include patients undergoing left thoracic surgery who did not *per se* required a

Table 1: Characteristics of the patients and intraoperative data

| Sex | Weight (kg)/Height (cm) | Preoperative spirometry | Size of the tube | Intervention | Anesthesiologist |
|--------|-------------------------|---|------------------|---|------------------|
| Male | 60/170 | Normal | 39F | Lower left lobectomy by robotic technique | CW |
| Male | 110/178 | GOLD I | 41F | Upper left lobectomy by robotic technique | CW |
| Female | 85/170 | Low DLCO | 37F | Upper left lobectomy by robotic technique | CW |
| Male | 70/165 | Low DLCO | 39F | Upper left segmentectomy by thoracotomy | CW |
| Male | 100/174 | Mild restrictive ventilatory deficit - low DLCO | 39F | Lower left wedge-resection by thoracotomy | CK |
| Female | 51/158 | Low DLCO | 35F | Upper left lobectomy by thoracotomy | CK |
| Female | 93/156 | Normal | 37F | Lower left lobectomy by thoracotomy | CK |
| Male | 88/173 | GOLD II - low DLCO | 39F | Upper left segmentectomy by thoracotomy | CK |
| Female | 87/160 | GOLD II - low DLCO | 37F | Upper left lobectomy by robotic technique | CW |
| Male | 86/179 | Normal | 39F | Upper left wedge-resection by thoracotomy | CK |

GOLD classification: Global initiative for chronic obstructive lung disease, DLCO: Diffusing capacity of the lungs for carbon monoxide, CW: Christine Watremez (author): Senior anesthesiologist experienced in thoracic anesthesia, CK: Céline Khalifa (author): Anesthesiologist recently graduated

Table 2: Time needed to perform the new technique and the corresponding implications

| Time needed in DD | Time needed RLD | Exposure to X-rays (mGy) | Significative desaturation | Success/failure | Quality of exclusion |
|-------------------|-----------------|--------------------------|----------------------------|-----------------|----------------------|
| 4 min | 3 min | 17.5 | No | Success | Fair |
| 2 min | 2 min | 39.2 | No | Success | Fair |
| 6 min | 2 min | 39 | No | Success | Fair |
| 2 min | 3 min | 15.3 | No | Success | Fair |
| 1 min | 1 min | 9.3 | No | Success | Fair |
| 4 min | 2 min | 6.9 | No | Success | Fair |
| 5 min | 2 min | 49.3 | No | Success | Fair |
| 1 min | 1 min | 6.1 | No | Success | Fair |
| 4 min | 15 min | 103 | No | Failure | / |
| 4 min | 1 min | 38.4 | No | Success | Fair |

DD: Dorsal decubitus position, RLD: Right lateral decubitus position

Table 3: Ventilation parameters during the procedure

| FiO ₂ (%) | SpO ₂ minimum (%) | EtCO ₂ maximum (cm H ₂ O) | Ventilation mode | Insufflation pressures (2 lungs) (cm H ₂ O) | Insufflation pressures (1 lung) (cm H ₂ O) | One lung ventilation time (min) |
|----------------------|------------------------------|---|------------------|--|---|---------------------------------|
| 100 | 100 | 42 | VC | 20/11+6 | 22/12+0 | 137 |
| 100 | 98 | 40 | PRVC | 19/11+5 | 24/12+0 | 217 |
| 100 | 98 | 50 | PRVC | 22/11+5 | 25/12+5 | 161 |
| 100 | 100 | 39 | PRVC | 22/9+5 | 18/10+5 | 126 |
| 100 | 99 | 38 | PRVC | 22/10+5 | 20/11+5 | 53 |
| 100 | 97 | 36 | VC | 15/8+5 | 19/10+5 | 101 |
| 100 | 91 | 37 | PRVC | 33/13+7 | 23/13+7 | 116 |
| 100 | 97 | 39 | VC | 22/11+7 | 24/9+4 | 116 |
| 100 | 98 | 49 | VC | 22/10+6 | 28/11+5 | 119 |
| 100 | 96 | 43 | VC | 18/8+5 | 26/10+5 | 65 |

FiO₂: Fraction of inspired of O₂, SpO₂: Pulse oximetry, EtCO₂: End-tidal CO₂, VCV: Volume-controlled ventilation mode, PRVC: Pressure regulated volume control ventilation mode. Insufflation pressures are expressed as (max pressure/mean pressure+positive end expiratory pressure)

right-sided double lumen tube. We tested this technique in 10 patients and the light of the results obtained; some points deserve to be discussed.

We had a success rate of 90%. This means that, in most of the cases, this technique can easily be performed by the anesthesiologist. Moreover, the success rate did not depend on the level of the experience of the anesthesiologist. This technique can, therefore, be used by any anesthesiologist. Unfortunately, the procedure failed in one patient. Indeed, we had to deal with identification difficulties of the wire in the right lateral decubitus in a female patient with very large breasts. After removing the breasts from the fluoroscopy field by using plasters, we obtained a better view. However, the time limit of 20 min was exceeded. This case illustrates that correct exposition of the chest before using fluoroscopy is mandatory to successfully position the tube and to avoid exposing the patient and the staff to large amounts of X-rays. In this regard, adopting radiation protection criteria is advised to limit the risk of exposure of the operating room personnel and the patient. The operator could use markers, such as a laser pointer, to determine the area of interest before using the radioscopy. Moreover, choosing the pulse mode rather than the continuous mode and using collimator allow to significantly reduce the dose of X-rays.

Despite the fact that our patients had different preoperative respiratory spirometry results, no significant desaturation was observed during the entire procedure. To avoid this complication, we used an inspired fraction of oxygen of 100% (FiO₂ 100%) during the positioning. This technique can as such be considered safe.

One shortcoming of this new technique is that it is impossible to know whether the tracheal cuff makes protrusion in the left bronchial tree. However, in most of the cases, if the exclusion of the left lung is not sufficient for the surgeon, inserting the tube a few millimeters further improves the exsufflation without a complete obstruction of the right upper lobe bronchus. Moreover, even if the tube is correctly positioned before surgical incision, it does not preclude any displacement during surgery, which makes the reposition of the tube almost impossible with this technique.

Conclusions

Although the right-sided double-lumen endobronchial tube can be avoided in most of the cases of left-sided thoracic surgery, its frequent use gives the opportunity to gain the necessary skills to correctly and safely control its position in any circumstance even in cases when a fiberoptic bronchoscope is unavailable. Here, we describe a new, safe and acceptable backup technique to properly insert a right-sided double-lumen endobronchial tube. Moreover, this technique is easily applicable as it can be performed by anesthesiologists with limited experience in thoracic anesthesia.

Financial support and sponsorship

Nil.

Conflicts of interest

There are no conflicts of interest.

References

1. de Bellis M, Accardo R, Di Maio M, La Manna C, Rossi GB, Pace MC, *et al.* Is flexible bronchoscopy necessary to confirm the position of double-lumen tubes before thoracic surgery? *Eur J Cardiothorac Surg* 2011;40:912-6.
2. Brodsky JB. Fiberoptic bronchoscopy need not be a routine part of double-lumen tube placement. *Curr Opin Anaesthesiol* 2004;17:7-11.
3. Campos JH. Current techniques for perioperative lung isolation in adults. *Anesthesiology* 2002;97:1295-301.
4. Kaplan T, Ekmekçi P, Kazbek BK, Ogan N, Alhan A, Koçer B, *et al.* Endobronchial intubation in thoracic surgery: Which side should be preferred? *Asian Cardiovasc Thorac Ann* 2015;23:842-5.
5. Kim JH, Park SH, Han SH, Nahm FS, Jung CK, Kim KM, *et al.* The distance between the carina and the distal margin of the right upper lobe orifice measured by computerised tomography as a guide to right-sided double-lumen endobronchial tube use. *Anaesthesia* 2013;68:700-5.
6. Campos JH, Massa FC, Kernstine KH. The incidence of right upper-lobe collapse when comparing a right-sided double-lumen tube versus a modified left double-lumen tube for left-sided thoracic surgery. *Anesth Analg* 2000;90:535-40.
7. Brodsky JB. Lung separation. In: Cohen E, editor. *The Practice of Thoracic Anesthesia*. Philadelphia, PA: Lippincott; 1995. p. 308-9.
8. Cohen E. Con: Right-sided double-lumen endotracheal tubes should not be routinely used in thoracic surgery. *J Cardiothorac Vasc Anesth* 2002;16:249-52.
9. Ehrenfeld JM, Mulvoy W, Sandberg WS. Performance comparison of right- and left-sided double-lumen tubes among infrequent users. *J Cardiothorac Vasc Anesth* 2010;24:598-601.