

Extremely low bispectral index value during robotic-assisted laparoscopic prostatectomy: A case report

ABSTRACT

The steep Trendelenburg position and pneumoperitoneum during surgery may affect intracranial pressure and cerebral oxygenation, which in turn may affect the values of the bispectral index (BIS). Prolonged maintenance of the Trendelenburg position and pneumoperitoneum may impair cerebrovascular autoregulation. We present a case of a patient with an extremely low BIS value during robotic-assisted laparoscopic prostatectomy (RALP). We managed the patient under general anesthesia and he showed a prominent decrease in BIS values 6 h after the start of surgery. Suppression ratio (SR) of electroencephalography (EEG) is also decreased, suggesting that the brain activity decreased. The BIS value increased quickly after the Trendelenburg position was released and the anesthesia was terminated. The patient recovered without any neurological deficits and was discharged. Steep Trendelenburg position and pneumoperitoneum can cause EEG abnormalities.

Key words: Bispectral index, pneumoperitoneum, robotic-assisted laparoscopic prostatectomy, Trendelenburg position

Introduction

EEG monitoring is used to monitor the neurophysiology of the brain. RALP requires a steep Trendelenburg position and induction of pneumoperitoneum, both of which increase intracranial pressure (ICP).^[1] Cerebral perfusion and cerebral oxygenation may decrease as a result of elevated ICP.^[2]

We encountered a major decrease in BIS value with major increase in SR of a patient during general anesthesia for a scheduled RALP, however, the patient discharged with no neurological deficits. Written informed consent was obtained from the patient for publication of this case report.


Case Report

The patient was a 76-year-old man (height, 169 cm; weight, 84 kg; body mass index, 29 kg/m²). He was diagnosed with prostate cancer and was scheduled to undergo RALP. He had a history of hypertension on valsartan, but poorly controlled at around 160–190/90–100 mm Hg preoperatively. His respiratory function tests were normal. His preoperative intraocular pressure which routinely measured by ophthalmologists before RALP surgery was normal. There were no abnormal findings in preoperative tests, including electrocardiography, chest radiography, blood cell count, blood chemistry tests and he showed no signs of heart failure.

This is an open access journal, and articles are distributed under the terms of the Creative Commons Attribution-NonCommercial-ShareAlike 4.0 License, which allows others to remix, tweak, and build upon the work non-commercially, as long as appropriate credit is given and the new creations are licensed under the identical terms.

For reprints contact: WKHLRPMedknow_reprints@wolterskluwer.com

How to cite this article: Hoshi T. Extremely low bispectral index value during robotic-assisted laparoscopic prostatectomy: A case report. Saudi J Anaesth 2022;16:214-6.

Access this article online	
Website: www.saudija.org	Quick Response Code 
DOI: 10.4103/sja.sja_659_21	

TAKUO HOSHI

Department of Anaesthesiology and Critical Care Medicine, Ibaraki Clinical Education and Training Center, University of Tsukuba, Kasama, Ibaraki, Japan

Address for correspondence: Takuo Hoshi, Department of Anaesthesiology and Critical Care Medicine, Ibaraki Clinical Education and Training Center, University of Tsukuba, Koibuchi 6528, Kasama, Ibaraki, 309-1793 Japan. E-mail: 124stern@gmail.com

Submitted: 09-Sep-2021, **Accepted:** 12-Sep-2021, **Published:** 17-Mar-2022

General anesthesia was induced by intravenous infusion of remifentanyl 0.5 µg/kg/min, bolus administration of propofol 1 mg/kg and rocuronium 70 mg were given after pre-oxygenation. After tracheal intubation, anesthesia was maintained with continuous infusion of remifentanyl (0.1 ~ 0.2 µg/kg/min), intermittent boluses of fentanyl and rocuronium, and 4% desflurane with oxygen and air (F_IO₂ 0.3). Neuromuscular blockade was maintained throughout the surgery to keep the post-tetanic count below 4. The RALP procedure was performed in the steep Trendelenburg position at 24.7°. The BIS value remained in the 40–60 range until about 6 h after the start of the surgery, but it began to decline after that, and we applied a new sensor, but it kept showing low value [Figure 1]. At that time, we observed prominent bulbar conjunctival edema and facial edema of the patient. The BIS value continued to drop and finally showed isoelectric EEG with contamination of ECG waveform, indicating zero value (SR 100). Although we did not observe any significant changes in the patient's blood pressure or oxygen saturation, we administered ephedrine to increase blood pressure. The surgeon was asked to change the low head position as soon as possible. The extremely low BIS value lasted for about an hour, and when administration of the anesthetic agents was discontinued at the end of surgery, it rose, and the patient awoke without delay. Patient interviews and manual muscle tests revealed no neurological

deficits, and an MRI performed on the third postoperative day did not show any abnormalities. He discharged 9 days after surgery without any neurological deficits.

Discussion

The Trendelenburg position and pneumoperitoneum cause a significant increase in ICP when each is applied alone or in combination.^[1,2] However, Park *et al.*^[3] have shown that brain oxygenation assessed with regional saturation of oxygen (rSO₂) during RALP surgery is slightly elevated, and this procedure does not induce cerebral ischemia. In addition, Doe *et al.*^[4] showed that RALP conducted with sevoflurane inhalation anesthesia did not significantly alter intraoperative regional saturation or jugular venous bulb oxygenation. Both of these studies had shorter operation times and observation periods than our case, and they did not use the steep Trendelenburg position for more than 6 h as we had.

Normally, blood flow in the brain is automatically regulated. Cerebrovascular autoregulation is known to be impaired over time by the steep Trendelenburg position and pneumoperitoneum.^[5] In a previous case report by Pandey *et al.*,^[6] unpredicted neurological complications were observed after 8 h of surgery using the steep Trendelenburg position combined with pneumoperitoneum. They hypothesized that the deterioration of neurological function was associated with the deterioration in neuronal function and the formation of brain edema.^[6] In our case, we observed prominent bulbar conjunctival edema and facial edema 6 h after the start of surgery. The edema may have caused the recorded amplitudes to drop below the amplitude threshold for EEG suppression set by the BIS. This may have led to a “total suppression” signal and BIS values around 0. However, the BIS value immediately increased after the patient was returned to the horizontal position and the anesthesia was turned off.

Cerebral hypoxia is correlated with early cognitive dysfunction.^[7] Although diffusion-weighted MRI is known to detect early cerebral ischemic changes,^[8] we did not observe any ischemic change of MRI 3 days of surgery. Blecha *et al.*^[9] showed that intraocular pressure increased over time during RALP, but no postoperative eye complications occurred in this case.^[9] We believed that impairment in transient cerebral blood flow was caused by the dysfunction of cerebrovascular autoregulation and venous return over time due to the steep Trendelenburg position and pneumoperitoneum. However, we did not measure cerebral blood flow or cerebral oxygenation.

There have been several reports of patients who have awakened without neurological deficits while showing

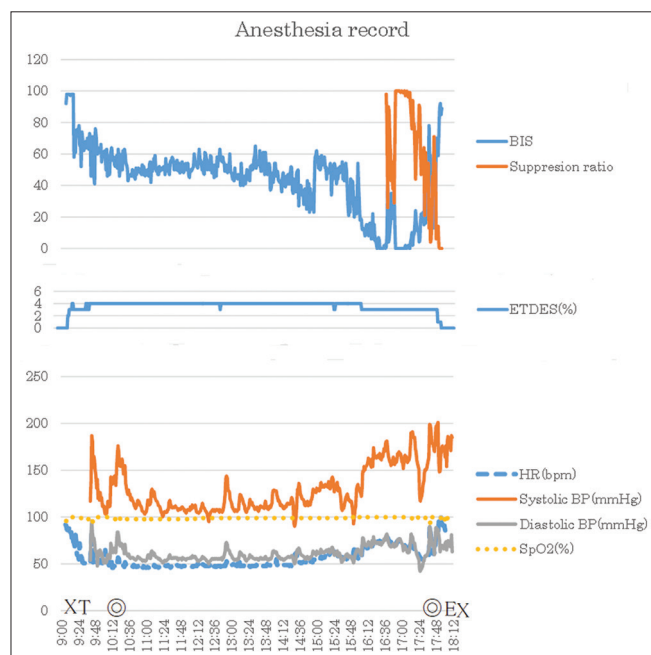


Figure 1: Anesthesia record for this patient is shown. In the graph above, the value of BIS and suppression ratio (%) were shown. In the graph of middle, end tidal desflurane (ETDES:%) was shown. In the graph below, heart rate (HR: bpm), systolic and diastolic blood pressure (BP: mm Hg), oxygen saturation of pulse oximetry (SpO₂: %). X: Start of anesthesia or end of anesthesia. T: Tracheal intubation. E: Extubation from trachea. ©: Start of surgery or end of surgery

very low BIS values during surgery.^[10] In these cases, hypoglycemia and hypercarbia were the reasons for the decreased BIS values. In our case, no abnormalities were seen in the ETCO₂ or blood glucose levels during the surgery.

In conclusion, a prolonged steep Trendelenburg position and pneumoperitoneum can cause EEG abnormalities and should be limited to a short period of time. Further studies on effect of prolonged Trendelenburg positioning and pneumoperitoneum cerebral blood flow and cerebral oxygenation are needed.

Declaration of patient consent

Consent for publications: Written informed consent was obtained from the patient for publication of this case report.

Acknowledgements

The author would like to thank Editage™ for English language editing and also would like to thank Dr. Hiromitsu Fukai and Dr. Takako Yokouchi who managed patient anesthesia and curation of data. Both doctors are anesthesiologists working at Ibaraki Prefectural Central Hospital.

Financial support and sponsorship

Nil.

Conflicts of interest

There are no conflicts of interest.

References

1. Mavrocordatos P, Bissonnette B, Ravussin P. Effects of neck position and head elevation on intracranial pressure in anesthetized neurosurgical patients. *J Neurosurg Anesth* 2000;12:10-4.
2. Dunham CM, Sosnowski C, Porter JM, Siegal J, Kohli C. Correlation of noninvasive cerebral oximetry with cerebral perfusion in the severe head injured patient: A pilot study. *J Trauma* 2002;52:40-6.
3. Park EY, Koo BN, Min KT, Nam SH. The effect of pneumoperitoneum in the steep Trendelenburg position on cerebral oxygenation. *Acta Anaesthesiol Scand* 2009;53:895-9.
4. Doe A, Kumagai M, Tamura Y, Sakai A, Suzuki K. A comparative analysis of the effects of sevoflurane and propofol on cerebral oxygenation during steep Trendelenburg position and pneumoperitoneum for robotic-assisted laparoscopic prostatectomy. *J Anesth* 2016;30:949-55.
5. Schramm P, Treiber AH, Berres M, Pestel G, Engelhard K, Welner C, *et al.* Time course of cerebrovascular autoregulation during extreme Trendelenburg position for robotic-assisted prostatic surgery. *Anaesthesia* 2014;69:58-63.
6. Pandey R, Garg R, Darlong V, Punj J, Chandralekha, Kumar A. Unpredicted neurological complications after robotic laparoscopic radical cystectomy and ileal conduit formation in steep Trendelenburg position: Two case reports. *Acta Anaesthesiol Belg* 2010;61:163-6.
7. Tang L, Kazan R, Taddei R, Zaouter C, Cyr S, Hemmerling TM. Reduced cerebral oxygen saturation during thoracic surgery predicts early postoperative cognitive dysfunction. *B J Anaesth* 2012;108:623-9.
8. Kawahara H, Takeda Y, Tanaka A, Nagano O, Katayama H, Hirakawa M, *et al.* Does diffusion-weighted magnetic resonance imaging enable detection of early ischemic change following transient cerebral ischemia. *J Neurol Sci* 2000;181:73-81.
9. Blecha S, Harth M, Schlachetzki F, Zeman F, Blecha C, Flora P, *et al.* Changes in intraocular pressure and optic nerve sheath diameter in patients undergoing robotic-assisted laparoscopic prostatectomy in steep 45 Trendelenburg position. *BMC Anesthesiol* 2017;17:1-8.
10. Xi C, Pan C, Li T. Abnormally low bispectral index and severe hypoglycemia during maintenance of and recovery from general anesthesia in diabetic retinopathy surgery: Two case reports. *BMC Anesthesiol* 2018;18:1-4.