



Contents lists available at ScienceDirect

International Journal of Surgery Case Reports

journal homepage: www.casereports.com

Operative management of idiopathic myositis ossificans of lateral pterygoid muscle

Luis Eduardo Almeida^{a,*}, Andrea Doetzer^b, Flavio Camejo^b, Jose Bosio^c^a Marquette University, School of Dentistry, Surgical Sciences, Oral Surgery, United States^b Pontifícia Universidade Católica do Paraná, Brazil^c Marquette University, School of Dentistry, Dental Development Sciences, Orthodontic Department, United States

ARTICLE INFO

Article history:

Received 10 June 2014

Accepted 3 September 2014

Available online 16 September 2014

Keywords:

Myositis
Ossificans
Pterygoid muscle
Surgery

ABSTRACT

INTRODUCTION: Myositis ossificans (MO) is characterized as heterotopic bone formation within muscle. MO rarely occurs in the head and neck region. Excision of the heterotopic bone is the standard treatment. This report summarizes a case of a 12-year old female with MO involving the lateral pterygoid muscle. The heterotopic bone was excised using an intraoral incision. Despite intensive physical therapy, the operation failed as evidenced by new bone formation in the area within three weeks of the operation.

PRESENTATION OF CASE: A twelve years old female patient presenting with mouth opening of 10 mm, no facial asymmetry, and no jaw joint pain or other symptoms. Computer tomography (CT) exam was requested and revealed calcification of the left lateral pterygoid muscle. No other masticatory or head muscles showed any signs of calcification. The calcified muscle was completely removed beyond the ossified segment and a 35 mm mouth opening was achieved immediately after the procedure. One month after total bone structure removal (first surgery) the patient could not open her mouth anymore due to a significant calcified mass.

DISCUSSION: The surgical technique used in this case avoided invasive gap arthroplasty to access lateral pterygoid muscle and anaesthetic scarring formation, by using an intraorally incision accessing the muscle directly.

The authors of these study did not see any relation with the condylar dislocation that the patient had five years prior to the pathology, and they could not find any real cause for the myositis ossificans of lateral pterygoid muscle.

CONCLUSION: The outcome of the surgical procedure was not successful, perhaps due to the expression of the disease, indicating the need to further physiologic and genetic studies to elucidate the aetiology of MO as well as to provide directions to an adequate treatment choice for such cases.

© 2014 The Authors. Published by Elsevier Ltd. on behalf of Surgical Associates Ltd. This is an open access article under the CC BY-NC-ND license (<http://creativecommons.org/licenses/by-nc-nd/3.0/>).

1. Case report

A five-year-old girl suffered a traumatic injury (left condylar dislocation) during a regular dental appointment. She had no history of other diseases or trauma on the face that could lead to a misinterpretation of the diagnosis before and after the condyle dislocation. At 10 years of age she began to progressively develop left side facial pain and jaw joint limitation on range of motion. No procedures were conducted at the time and continuous close monitoring was determined. Patient should return in three months. Unfortunately, she returned only two years later, presenting with mouth opening of 10 mm, no facial asymmetry, and no jaw joint pain or other symptoms (Figs. 1 and 2). Computer tomography (CT) exam was requested and revealed calcification of the left lateral pterygoid

muscle, extending from the head of the mandible to the pterygoid process (Fig. 3). No other masticatory or head muscles showed any signs of calcification. Thus, in order to allow the patient to open her mouth wider, the proposed treatment plan included left side pterygoid muscle excision. Patient signed the consent form and she was scheduled for surgery.

After general anaesthesia, an intraoral incision was done along the anterior mandibular ramus and the ossified mass was easily detected after detachment of mucosa. The calcified muscle was completely removed beyond the ossified segment (Fig. 4) and a 35 mm mouth opening was achieved immediately after the procedure (Fig. 5). Fat pad was placed in the excised muscle space to prevent recurrence. The patient was medicated with corticosteroid and referred for intensive physical therapy. New post-operative CT images showed absence of calcified mass over the medial left mandibular. Laboratories tests of calcium, alkaline phosphatase presented normal results and histopathological examination showed simply calcified bone confirming the pathology diagnosed pre-surgically. However, three weeks after surgery

* Corresponding author at: School of Dentistry, 352 PO Box 1881, Milwaukee 53201-1881, United States. Tel.: +1 414 288 6022.

E-mail address: luis.almeida@Marquette.edu (L.E. Almeida).

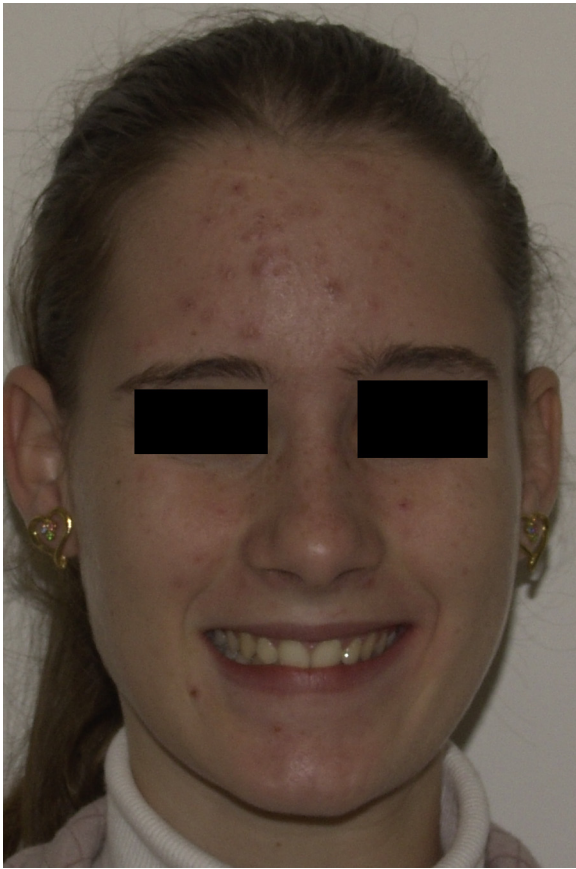


Fig. 1. Frontal view.

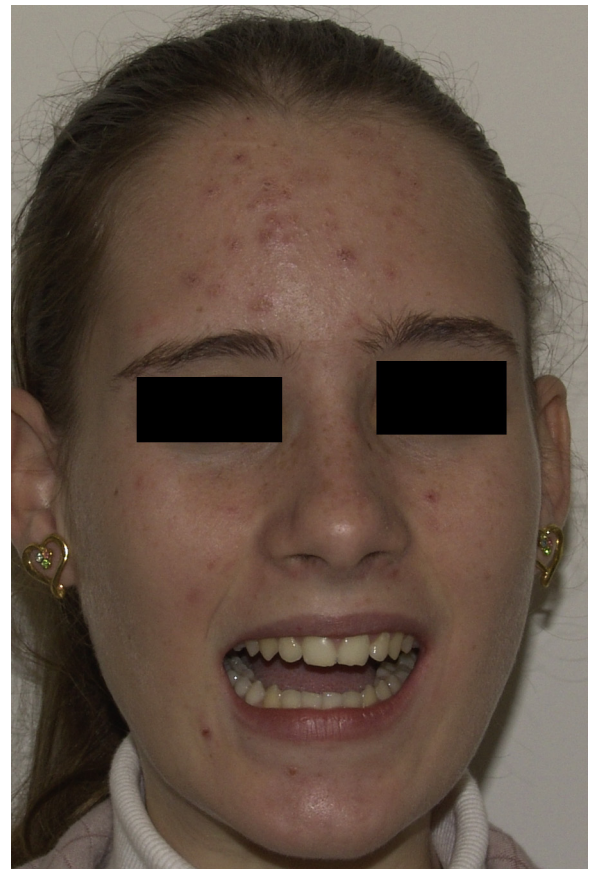


Fig. 2. Maximum mouth opening (10 mm).

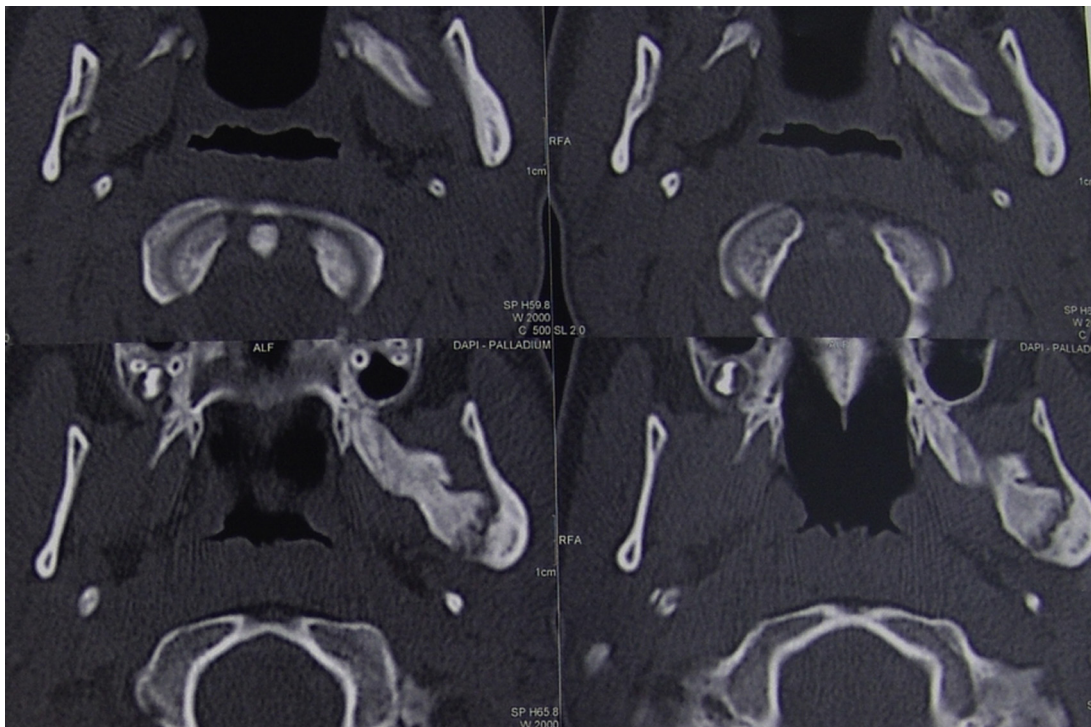


Fig. 3. Axial CT scan showing the myositis on the left side.

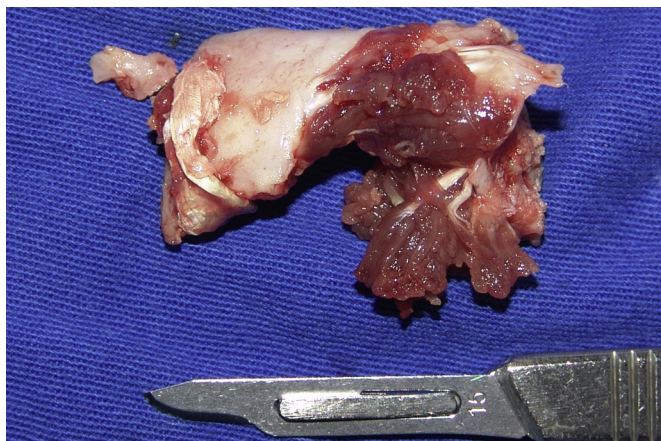


Fig. 4. Lateral pterygoid muscle removed. Note the bone structure.

patient started to feel limitation upon mouth opening and a new CT showed a new big mass of bone formation along the surgical tract. One month after total bone structure removal (first surgery) the patient could not open her mouth anymore (Figs. 6 and 7) due to a significant calcified mass.

2. Discussion

Traumatic myositis ossificans is a rare clinical pathology, uncommon in the region of head and neck, and was first described by Thoma in 1958 as a calcification and an intramuscular haematoma ossification after trauma.¹ Several other trauma injuries have been reported as the main cause for this condition, including third molar extraction,² neck immobilization with cervical

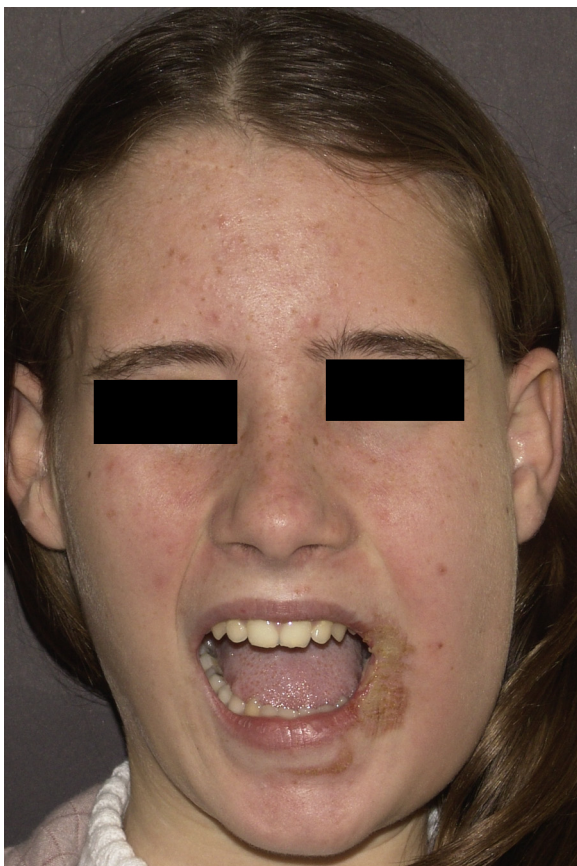


Fig. 5. Maximum mouth opening of 35 mm at second day post-op.

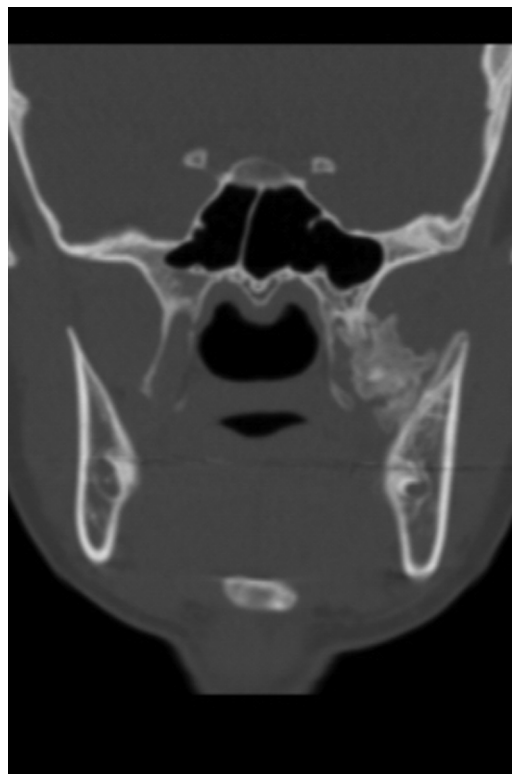

Fig. 6. Post-op coronal CT scan showing recurrence of myositis.

collar after laminoplasty,³ repeated absolute alcohol injection as trigeminal neuralgia treatment,⁴ temporomandibular joint luxation caused by 3-h mouth opening during periodontal surgery,⁵ direct or proximal physical trauma,^{6,7} odontogenic infection⁸ and anaesthetic injection.⁹

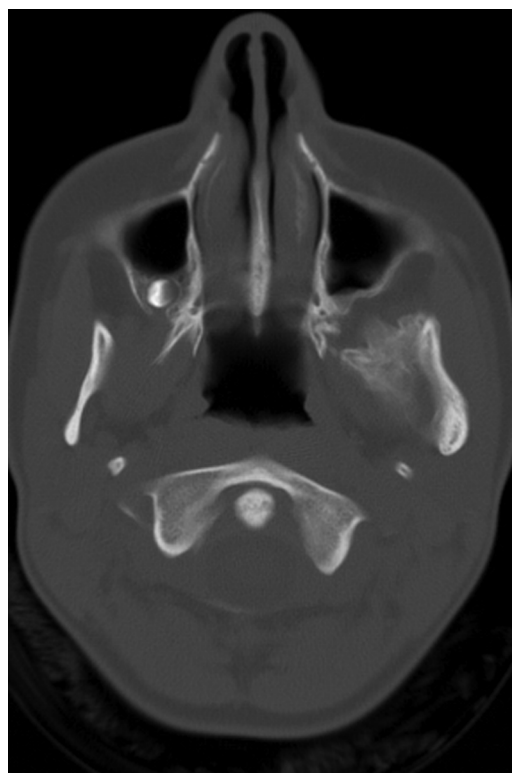

Fig. 7. Post-op axial CT scan showing recurrence of myositis.

It is not completely understood why some patients developed an ossification of muscles after trauma, but it has many pathogenesis theories as follows: (1) displacement of bony fragments into the soft tissue and haematoma with following proliferation; (2) detachment of periosteal fragments into the surrounding tissue with proliferation of osteoprogenitor cells; (3) migration of subperiosteal osteoprogenitor cells into surrounding soft tissue, through periosteal perforation induced by trauma; and, the most feasible and more accepted content among clinician, (4) metaplasia of extraosseous cells in contact to bony morphogenetic proteins derived from the lysis of bone fragments displaced within the soft tissue during traumatic injury.¹⁰ Another possibility could be a genetic polymorphism inducing the disease in certain patients as in fibrodysplasia ossificans progressive, as described by Carey.¹¹

The masseter has been reported to be the predominant muscle involved with ossification, followed by temporalis, genioglossus, buccinator, medial pterygoid and lateral pterygoid.¹² And males are more affected than females.¹³ Elevated alkaline phosphatase was cited during evolution in some MO cases, perhaps resulting from disease inflammatory progress.

Early and complete excision of the involved muscles plus additional procedures in order to try to avoid recurrence are the worldwide therapy of choice for most surgeons. All procedures conducted in this case, such as osteotomy of the muscle attachment region,¹⁴ fat insertion (considered to prevent heterotopic bone formation) for haematoma formation prevention,⁴ associated to non-surgical treatments, such as corticosteroids, nonsteroidal anti-inflammatory drugs, bisphosphonates, and a low-dose radiotherapy and warfarin,⁵ have been reported as successful. Unfortunately, the results from this case were not as expected and the patient developed a new calcified bone.

As current follow up, this patient could benefit from a new surgical procedure or TMJ prosthesis insertion. Also, fractioned radiotherapy has shown some benefit for this pathology, but it compromises the region and contraindicates a surgery afterwards. Another surgical procedure could result in scarring and recidive

and TMJ prosthesis would not prevent heterotopic bone formation. After all considerations, her father has decided to wait until his daughter grows older.

The surgical technique used in this case avoided invasive gap arthroplasty to access lateral pterygoid muscle and anaesthetic scarring formation, by using an intraorally incision accessing the muscle directly as reported previously.⁵ The authors of these study did not see any relation with the condylar dislocation that the patient had five years prior to the pathology, and they could not find any real cause for the myositis ossificans of lateral pterygoid muscle.

3. Conclusion

The outcome of the surgical procedure was not successful, perhaps due to the expression of the disease, indicating the need to further physiologic and genetic studies to elucidate the aetiology of MO as well as to provide directions to an adequate treatment choice for such cases.

Conflicts of interest

None.

Funding

None.

Ethical approval

None.

Author contributions

All authors participated in the treatment of the patient, before and after surgery.

Key learning point

- Intra oral access is a viable surgical option.
- Post-operative images (CT) is mandatory for this kind of pathology.
- Recurrence should be discussed and addressed with patient and family.

References

1. Thoma KH. *Oral Surgery*. St Louis, MO: Mosby; 1958. p. 1568.
2. Parkash H, Goyal M. Myositis ossificans of medial pterygoid muscle. *Oral Surg Oral Med Oral Pathol Oral Radiol Endod* 1992;**73**:27.
3. Takahashi K, Sato K. Myositis ossificans traumatica of the medial pterygoid muscle. *J Oral Maxillofac Surg* 1999;**57**:451.
4. Rattan V, Rai S, Vaiphei K. Use of buccal pad of fat to prevent heterotopic bone formation after excision of myositis ossificans of medial pterygoid muscle. *J Oral Maxillofac Surg* 2008;**66**:1518–22.
5. Spinazze RP, Heffez LB, Bays RA. Chronic, progressive limitation of mouth opening. *J Oral Maxillofac Surg* 1998;**56**:1178–86.
6. Sarac S, Sennaroglu L, Hosal AS, Sozeri B. Myositis ossificans in the neck. *Eur Arch Otorhinolaryngol* 1999;**256**(4):199–201.
7. Kim D, Lazow S, Har-El G, Berger J. Myositis ossificans traumatica of the masticatory musculature: a case report and literature review. *J Oral Maxillofac Surg* 2002;**60**:1072.
8. Abdin HA, Prabhu SR. Traumatic myositis ossificans of lateral pterygoid muscle. *J Oral Med* 1984;**39**(January–March (1)):54–6.
9. Ramieri V, Bianca C, Arangio P, Cascone P. Myositis ossificans of the medial pterygoid muscle. *J Craniofac Surg* 2010;**21**.
10. Eresen Yazıcıoğlu C, Karatosun V, Kızıldağ S, Özsoylu D, Kavukçu S. ACVR1 gene mutations in four Turkish patients diagnosed as fibrodysplasia ossificans progressive. *Gene* 2013;**515**(February (2)):444–6.
11. Carey EJ. Multiple bilateral parosteal bone and callus formations of the femur and left innominate bone. *Arch Surg* 1924;**8**:592.
12. Trester PH, Markovitch E, Zambito RF, Stratigos GT. Myositis ossificans, circumscripta and progressiva, with surgical correction of the masseter muscle: report of two cases. *J Oral Surg* 1969;**27**(March (3)):201–5.
13. St.-Hilare H, Weber WD, Ramer M, Lumerman H. Clinicopathologic conference: trismus following dental treatment. *Oral Surg Oral Med* 2004;**98**(September (3)):261–6.
14. Aoki T, Naito H, Ota Y, Shiiki K. Myositis ossificans traumatica of the masticatory muscles: review of the literature and report of a case. *J Oral Maxillofac Surg* 2002;**60**:1083–8.

Open Access

This article is published Open Access at sciendo.com. It is distributed under the [IJSCR Supplemental terms and conditions](#), which permits unrestricted non commercial use, distribution, and reproduction in any medium, provided the original authors and source are credited.