

Efficiency of inferior petrosal sinus sampling in the diagnosis of Cushing's disease and comparison with magnetic resonance imaging

 **Tumay Bekci**,  **Umit Belet**,  **Aysegul Idil Soylu**,  **Fatih Uzunkaya**,
 **Mesut Ozturk**,  **Aysegul Atmaca**

Department of Radiology, Ondokuz Mayıs University Faculty of Medicine, Samsun, Turkey

ABSTRACT

OBJECTIVE: The purpose of this study is to assess the efficiency of inferior petrosal sinus sampling (IPSS) in the diagnosis of adrenocorticotrophic hormone-dependent Cushing's disease and to compare it with magnetic resonance imaging (MRI).

METHODS: The diagnostic efficiency of IPSS in the differentiation of pituitary Cushing's disease from ectopic Cushing's disease was retrospectively evaluated in 37 patients who had IPSS in our clinic. Six patients were excluded from the study due to missing data. Hypophysis MRI examinations of 31 patients before IPSS were also evaluated. The contributions of MRI and IPSS to the detection of pituitary adenoma and the determination of lateralization were researched.

RESULTS: Bilateral IPSS was successfully performed in 30 patients of the 31 patients in the study group. The sensitivity, specificity, positive predictive value, negative predictive value, and accuracy of IPSS in differentiating between central and ectopic Cushing's syndrome before corticotrophin-releasing hormone (CRH) stimulation were 93.3%, 100%, 100%, 33.3%, and 93%, respectively, whereas after CRH stimulation were 100%, 100%, 100%, 100%, and 100%, respectively. The accuracy of both the rates was significantly higher compared with MRI.

CONCLUSION: IPSS has the highest diagnostic efficiency in differentiating central Cushing's disease from ectopic Cushing's disease.

Keywords: Angiography; Cushing syndrome; inferior petrosal sinus sampling; magnetic resonance imaging; pituitary.

Cite this article as: Bekci T, Belet U, Soylu AI, Uzunkaya F, Ozturk M, Atmaca A. Efficiency of inferior petrosal sinus sampling in the diagnosis of Cushing's disease and comparison with magnetic resonance imaging. *North Clin Istanbul* 2019;6(1):53-58.

Cushing's syndrome defines the various clinical presentations caused by chronic glucocorticoid excess due to various reasons. Cushing's syndrome can develop as an adrenocorticotrophic hormone (ACTH)-dependent or ACTH-independent disease. About 80–85% of the patients have ACTH-dependent pituitary Cushing's disease. 80% of these are hypophyseal tumors, while the remaining 20% are tumors that cause ectopic ACTH syndromes. Solitary corticotroph adenomas are the reason for almost all pituitary Cushing's diseases. A great

number of these tumors are intrasellar microadenomas (<1 cm), while 10% are macroadenomas [1].

Since the clinical and laboratory findings of Cushing's disease that develops secondary to pituitary ACTH hypersecretion and Cushing's syndrome that develops secondary to ectopic ACTH secretion are similar, it is considerably difficult to make a definitive diagnosis. Various endocrinological tests and radiological imaging methods are used in the definitive diagnosis. Inferior petrosal sinus sampling (IPSS) is used for localization and/or lat-



Received: July 31, 2017 Accepted: February 01, 2018 Online: August 07, 2018

Correspondence: Dr. Tumay BEKCI. Zonguldak Ataturk Devlet Hastanesi, Radyoloji Klinigi, Merkez, Zonguldak, Turkey.
Tel: +90 372 252 19 00 e-mail: tmybkc@gmail.com

© Copyright 2019 by Istanbul Provincial Directorate of Health - Available online at www.northclinist.com

eralization in patients when the lesion in the pituitary gland cannot be observed using radiological imaging techniques. Pituitary computed tomography (CT) shows poor specificity and sensitivity (about 47%), whereas the sensitivity is about 50–60% in magnetic resonance imaging (MRI), thus indicating a slight improvement [1, 2]. The other problems in imaging are whether the lesion in detected microadenomas can be held clinically responsible. If a tumor bigger than 6-mm diameter is found using MRI, surgical verification of this is between 75% and 98% [1]. Only 52% of the patients are correlated with surgery who has microadenomas smaller than 6 mm and some diagnosis methods are required, such as bilateral inferior petrosal or cavernous sinus sampling [3]. While the detection of a lesion in MRI does not certainly show that it is the source of ACTH, the fact that it is not detected on MRI necessitates advanced examination such as IPSS since the microadenomas that secrete ACHT may be too small to be detected with MRI. Although IPSS is an invasive procedure, it is still the most reliable diagnosis method in the identification of central or ectopic disease.

Our study investigated the contribution of IPSS to the diagnosis and treatment in patients who were found to have none or adenomas <6-mm diameter on MRI.

MATERIAL AND METHODS

Patients

This study includes patients with Cushing's disease, who were diagnosed at an endocrinology clinic with a detailed clinical and laboratory assessment and who had IPSS in our Interventional Radiology Unit of Medical Faculty Hospital for the differentiation between the central and ectopic diseases by means of DSA device (Siemens Medical Solutions, Erlangen, Germany) between the years 2005 and 2016. Three patients were excluded since their laboratory results were not found, and three other patients were excluded since they had not undergone surgery. All patients had hypophysis MRI as a standard protocol. The study group included a total of 31 patients (6 males and 25 females) between the age of 16 and 54 years (mean age: 28.5). MRI and recorded DSA images; surgical, pathological, and laboratory results; and post-procedure clinical information of the patients were examined retrospectively and statistical analyses were made. University Ethical Board approved this study.

Biochemical assessment

The source of ACTH secretion was investigated in all patients by performing non-invasive tests that included the high-dose dexamethasone test and corticotropin-releasing hormone (CRH) test.

Imaging protocol

All the patients were assessed with hypophysis MRI before the procedure. MRI examinations were performed using the same hypophysis MRI protocol using the 1.5-T Siemens MR unit (Magnetom Symphony Quantum, Siemens Medical Systems Erlangen, Germany) or 1.5-T Philips MR unit (Achieva; Philips Healthcare, Best, the Netherlands). T1-weighted and T2-weighted spin echo sequences were obtained with a slice thickness of 3 mm at the coronal and sagittal planes. Later, T1-weighted turbo spin echo dynamic sequences were obtained with 3-mm slice thickness at the coronal and sagittal plans after gadolinium injection (0.1 mmol/kg). IPSS was planned for the patients who were not found to have pituitary gland adenoma or who were found to have adenoma with a diameter <6 mm.

Catheterization protocol

4F diagnostic catheters (Cordis Corporation, Miami Lakes, FL, USA) over a 0.035-inch hydrophilic guidewire (Terumo 0.035 Guidewires, Boston Scientific Corp.) through the introducer sheath placed on both the femoral veins (right 7F and left 5F) were advanced to cannulate the orifices of inferior petrosal sinuses at C1-2 level. The patients were heparinized with 3000 units of heparin after the introducer sheaths were placed. Anatomies of the inferior petrosal and cavernous and intercavernous sinuses were monitored by the hand injection of contrast agent and they were recorded (Fig. 1). After the catheters were placed, 3 ml blood sample was taken (–5 min) from the 7F introducer sheath of the femoral vein and from both the catheter systems for basal ACTH measurement for the first sample. After CRH (Acthrel, 1 µg/kg; Ben Venue Laboratories, Ohio, USA) injection, samples were taken from both catheters simultaneously at 0, 3, 5, 8, 10, and 15 min. Blood samples were sent to laboratory in pre-labeled tubes on ice. After the catheters and sheaths were taken out, vascular entrance hemostasis was ensured by manual compression, and the patients were transferred to their services. The procedure was accepted as successful in patients whose blood samples were taken with the catheterization of both inferior petrosal sinuses. Plasma ACHT measure-

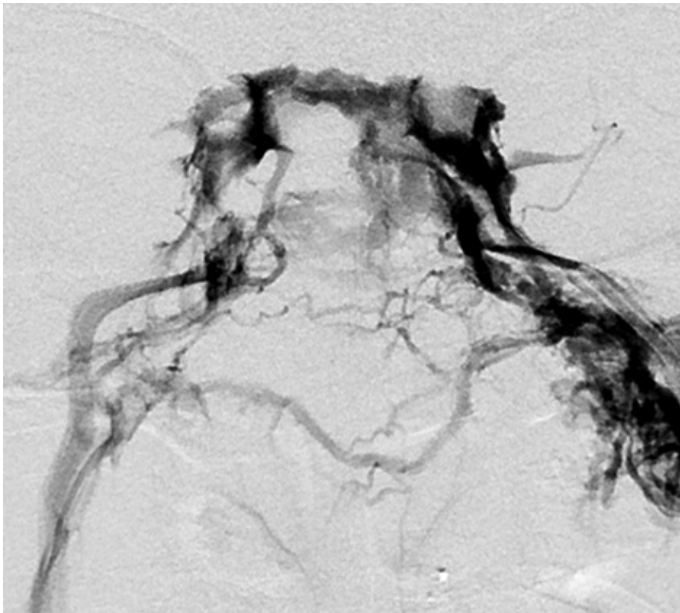


FIGURE 1. No lesions in hypophysis magnetic resonance imaging of a patient with the initial diagnosis of Cushing's disease. The patient is found to have bilateral Type 3 drainage and right-sided lateralization in inferior petrosal sinus sampling. Right-sided transsphenoidal hypophysectomy resulted in hypophysis adenoma.

ments were made using high specificity immunoradiometric assay kits. The highest values of the ratio of ACTH level in blood samples obtained from petrosal sinuses to ACTH level obtained from peripheral blood (PB) were used in statistical calculations.

Diagnostic criteria and definitive diagnosis

The diagnostic criteria of Cushing's disease were as follows: 50% or higher decrease in plasma cortisol levels in the high-dose dexamethasone test when compared with the basal level; 20% and higher increase in basal cortisol level, or 50% or higher increase in ACTH levels in CRH test. The patients were referred to the neurosurgery department for transsphenoidal pituitary gland surgery after IPSS. Transsphenoidal hypophysectomy was performed on the lateralized side according to the results of the sampling.

The confirmation that ACTH secretion was centralized was made by the detection of ACTH-secreting adenoma by the examination of pathology preparation after transsphenoidal pituitary gland surgery or with post-surgery clinical improvement in patients who were not found to have adenoma in their surgical specimen pathologically.

Statistical analysis

Sensitivity, specificity, and negative and positive predictive values of IPSS and MRI in patients whose definitive diagnoses were made using surgery were calculated by comparing the results of each procedure with surgical definitive diagnoses and clinical results.

RESULTS

Bilateral IPSS was successfully performed in 30 patients of the 31 patients in the study group (success rate: 96%). Unilateral inferior petrosal sinus catheterization was performed in the patient who did not successfully undergo bilateral IPSS and the other sample was taken from where the petrosal sinus drains the cavernous sinus into the internal jugular vein.

IPS/PB ACTH ratio was higher than 2 in 28 of 31 patients (90%) before CRH stimulation, while it was higher than 3 in 30 of the patients after CRH stimulation. Except for one patient, all the other patients had a pituitary source (96%). In the patient who did not have a pituitary source, adrenal adenoma was detected using abdominal imaging and adrenalectomy was performed. Of the 30 patients with a pituitary source, only one patient did not have lateralization (96%). This patient's MRI showed a microadenoma with 3-mm diameter on the left half. The left transsphenoidal hypophysectomy was performed on the patient, and the patient was cured.

The right IPS was lateralized in the patient who had unilateral IPS catheterization. Of the remaining patients, eight were lateralized to the left side, while 21 patients were lateralized to the right side. According to these results, the sensitivity, specificity, positive predictive value, negative predictive value, and accuracy calculations of IPSS in differentiating between central and ectopic Cushing's syndrome before CRH stimulation were 93.3%, 100%, 100%, 33.3%, and 93%, respectively, whereas the sensitivity, specificity, positive predictive value, negative predictive value, and accuracy calculations of IPSS in differentiating between central and ectopic Cushing's syndrome after CRH stimulation were 100%, 100%, 100%, 100%, and 100%, respectively (Fig. 2). Hypophysis MRI was conducted on all patients before IPSS, and hypophyseal lesions were not detected in 10 patients (Fig. 3). In three patients, the lesions detected by MRI and the sides lateralized as a result of IPSS were different. MRI results showed that one patient had centralized macroadenoma, and IPSS results showed that it

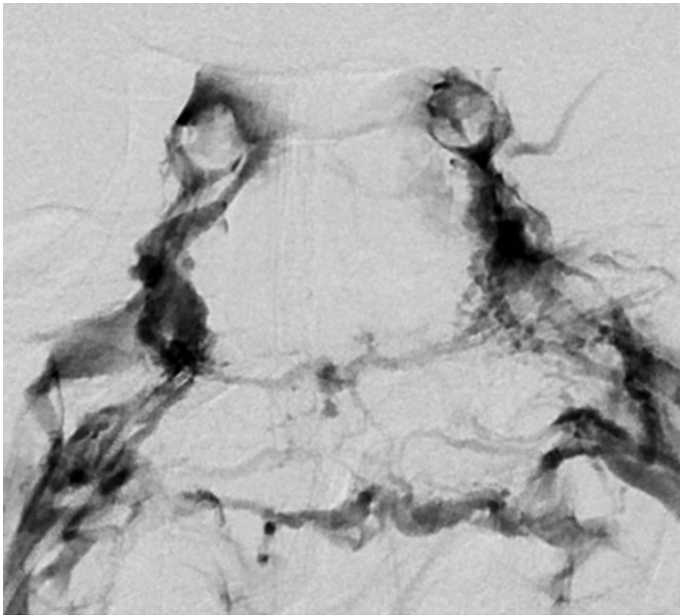


FIGURE 2. Inferior petrosal sinus sampling (IPSS) is planned for the patient with an initial diagnosis of Cushing's disease, and a lesion with a diameter of 4 mm in the right half of pituitary gland is detected in the magnetic resonance imaging. The patient is found to have Type 1 drainage on the right, Type 3 drainage on the left, and right-sided lateralization in IPSS. Right-sided transsphenoidal hypophysectomy confirms adenoma on the right half of pituitary gland.

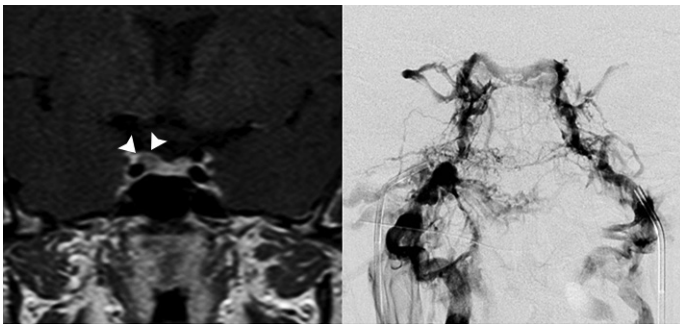


FIGURE 3. Lesion with a diameter of 5 mm on the right half of pituitary gland (arrowheads) detected in hypophysis magnetic resonance imaging of the patient with the initial diagnosis of Cushing's disease (left panel). Bilateral symmetric drainage in inferior petrosal sinus sampling (right panel). Procedure results show right-sided lateralization. Right-sided transsphenoidal hypophysectomy confirmed hypophysis adenoma. No complaints are obtained from the patient post operation.

was lateralized to the right side. Of the 10 patients who were not found to have a lesion on MRI, eight were right lateralized and two were left-lateralized. According to the

TABLE 1. Diagnostic performance of MRI and IPSS before CRH and after CRH stimulation

	Sensitivity %	Specificity %	Positive predictive value %	Negative predictive value %
IPSS-Before CRH	93.3	100	100	33.3
IPSS-After CRH	100	100	100	100
MRI	56	100	100	7.14

MRI: Magnetic resonance imaging; IPSS: Inferior petrosal sinus sampling; CRH: Corticotrophin releasing hormone.

surgery results, the adenomas were found in the lateralized side as indicated in petrosal sinus sampling. According to these results, the sensitivity, specificity, positive predictive value, negative predictive value, and accuracy calculations of MRI in differentiating between central and ectopic Cushing's syndrome were 56%, 100%, 100%, 7.14%, and 58%, respectively.

Table 1 summarizes the diagnostic performances of MRI and IPSS before and after CRH stimulation.

Post-surgery, the reversal of clinical symptoms was observed in patients who had a pituitary source and underwent IPSS. In all the patients, ACHT-secreting pituitary adenoma was detected in histopathological examination. The patient without a pituitary source and who was detected with adrenal adenoma was found to have ACHT-secreting adenoma as a result of adrenalectomy.

No complications developed in our patients during and after the sampling procedure. None of the patients were found to have ectopic ACHT-secreting source.

DISCUSSION

IPSS has high accuracy and efficiency in the diagnosis of Cushing's syndrome in experienced centers. In a meta-analysis consisting of 21 researches, the sensitivity and specificity of IPSS were found to be 96% and 100%, respectively. CRH stimulation increases the sensitivity to 100% [1]. In our study, CRH stimulation increased the sensitivity from 93.3% to 100%. Wiggam et al. [4] found that the sensitivity was 48% for high-dose dexamethasone test, 70% for CRH test, and 82% for IPSS.

When compared with other imaging modalities, IPSS was found to have a high accuracy. In a study conducted on 54 patients, Kaskarelis et al. [5] found that the accu-

racy of MRI was 54% and IPSS was 88%. In a study performed on 84 patients, Colao found the sensitivity to be 40% for CT, 50% for MRI, and 90% for IPSS [6]. In our study, the diagnostic accuracy of MRI in differentiating central and ectopic Cushing's syndrome was found to be 58% while the accuracy of IPSS was found to be 100%.

Bilateral IPSS is considered a reliable method when performed by an experienced interventional radiologist. The most common complication related to IPSS is hematoma development that can be seen in 3–4% of the patients in venous access site [7]. Serious complications are quite rare. In a series of 508 patients, pontine hemorrhage was reported in one patient and vasovagal reaction was reported in one patient as serious neurological complications. In the same series, temporary complications such as vertigo and paresthesia were reported in three patients. In a different case report, the same authors reported medial medullar syndrome in a patient who developed non-hemorrhagic right medullary infarct [7]. In a study of 86 patients, authors reported temporary 6th nerve paralysis in two patients [8]. In a series of 94 patients, authors reported venous subarachnoid hemorrhage that caused acute obstructive hydrocephaly in a patient [9]. In another series of 44 patients, brain stem infarct that caused pontomedullary dysfunction as detected by MRI was found in a patient [10]. Since the aforementioned complications are very rare, it is considerably difficult to obtain the predisposing factors due to reasons such as catheter selection and venous anatomy variations. Thromboembolic complications related to IPSS have been reported in literature. Patients with Cushing's syndrome are predisposed to hypercoagulability due to the nature of the disease. Thus, prophylactic heparinization is significant during the procedure. In a study conducted in Vanderbilt University, 2 of 43 patients developed deep vein thrombosis after IPSS, and in one of the patients, this situation caused pulmonary thromboembolism. However, it was stated that no prophylactic heparinization was conducted in this center during the procedure [11]. In another study, deep vein thrombosis was reported in one of the 94 patients [12]. In our study, intravenous heparin was given to all patients and none of the patients developed complications during and after the procedure.

The fact that IPSS is a difficult procedure has caused people to look for more simple ways. At this point, jugular venous sampling has come to the forefront. Doppman et al. compared both the methods and reported the sensitivities of jugular venous sampling as

80% and IPSS as 95% [13]. Another group reported the sensitivities of jugular venous sampling as 83% and IPSS as 94% [14]. In these studies, the general opinion of authors is that although incorrect results should be reevaluated using IPSS, jugular venous sampling can be used as an alternative procedure in centers that have little technical experience. In our study, since IPS was not catheterized in one side in one of the cases, unilateral high jugular venous sampling was conducted. Cavernous sinus sampling has occurred as a result of the procedure taken one step ahead since it is closer to pituitary venous drainage to prevent cases where IPSS cannot be catheterized. However, the results are not enough for a common opinion for now. Prospective studies with bigger patient groups are required [7].

The limitations of our study are as follows: Small number of patients and the use of images from low-Tesla power devices in a period of 10 years when compared with MRI.

Conclusion

IPSS has shown high diagnostic efficiency in differentiating central Cushing's disease from ectopic Cushing's disease. IPSS values obtained after CRH stimulation were found to indicate higher diagnostic efficiency in comparison to MRI. In centers that have experience in implementing the procedure, IPSS can be used as the golden standard in the diagnosis of Cushing's disease with minimal complications and failure rates.

Conflict of Interest: The authors declare no conflict of interest.

Financial Disclosure: The authors declared that this study has received no financial support.

Authorship Contributions: Concept – T.B.; Design – T.B.; Supervision – U.B., A.I.S., F.U., A.A.; Materials – T.B.; Data collection &/or processing – T.B., M.O., A.I.S.; Analysis and/or interpretation – U.B., T.B.; Writing – T.B.; Critical review – T.B., U.B., A.A.

REFERENCES

1. Newell-Price J, Trainer P, Besser M, Grossman A. The diagnosis and differential diagnosis of Cushing's syndrome and pseudo-Cushing's states. *Endocr Rev* 1998;19:647–72.
2. Buchfelder M, Nistor R, Fahlbusch R, Huk WJ. The accuracy of CT and MR evaluation of the sella turcica for detection of adrenocorticotrophic hormone-secreting adenomas in Cushing disease. *AJNR Am J Neuroradiol* 1993;14:1183–90.
3. Yogi-Morren D, Habra MA, Faiman C, Bena J, Hatipoglu B, Kennedy L, et al. Pituitary MRI findings in patients with pituitary and ectopic acth-dependent Cushing syndrome: Does a 6-mm pituitary tumor size cut-off value exclude ectopic acth syndrome? *Endocr Pract*

- 2015;21:1098–103.
4. Wiggam MI, Heaney AP, McIlrath EM, McCance DR, Sheridan B, Hadden DR, et al. Bilateral inferior petrosal sinus sampling in the differential diagnosis of adrenocorticotropin-dependent Cushing's syndrome: A comparison with other diagnostic tests. *J Clin Endocrinol Metab* 2000;85:1525–32.
 5. Kaskarelis IS, Tsatalou EG, Benakis SV, Malagari K, Komninos I, Vasiliadi D, et al. Bilateral inferior petrosal sinuses sampling in the routine investigation of Cushing's syndrome: A comparison with MRI. *AJR Am J Roentgenol* 2006;187:562–70.
 6. Colao A, Faggiano A, Pivonello R, Pecori Giralardi F, Cavagnini F, Lombardi G, et al. Inferior petrosal sinus sampling in the differential diagnosis of Cushing's syndrome: Results of an Italian multicenter study. *Eur J Endocrinol* 2001;144:499–507.
 7. Deipolyi A, Karaosmanoğlu A, Habito C, Brannan S, Wicky S, Hirsch J, et al. The role of bilateral inferior petrosal sinus sampling in the diagnostic evaluation of Cushing syndrome. *Diagn Interv Radiol* 2012;18:132–8.
 8. Lefournier V, Martinie M, Vasdev A, Bessou P, Passagia JG, Labat-Moleur E, et al. Accuracy of bilateral inferior petrosal or cavernous sinuses sampling in predicting the lateralization of Cushing's disease pituitary microadenoma: Influence of catheter position and anatomy of venous drainage. *J Clin Endocrinol Metab* 2003;88:196–203.
 9. Bonelli FS, Huston J 3rd, Meyer FB, Carpenter PC. Venous subarachnoid hemorrhage after inferior petrosal sinus sampling for adrenocorticotrophic hormone. *AJNR Am J Neuroradiol* 1999;20:306–7.
 10. Gandhi CD, Meyer SA, Patel AB, Johnson DM, Post KD. Neurologic complications of inferior petrosal sinus sampling. *AJNR Am J Neuro-radiol* 2008;29:760–5.
 11. Blevins LS Jr., Clark RV, Owens DS. Thromboembolic complications after inferior petrosal sinus sampling in patients with Cushing's syndrome. *Endocr Pract* 1998;4:365–7.
 12. Swearingen B, Katznelson L, Miller K, Grinspoon S, Waltman A, Dorer DJ, et al. Diagnostic errors after inferior petrosal sinus sampling. *J Clin Endocrinol Metab* 2004;89:3752–63.
 13. Doppman JL, Oldfield EH, Nieman LK. Bilateral sampling of the internal jugular vein to distinguish between mechanisms of adrenocorticotrophic hormone-dependent Cushing syndrome. *Ann Intern Med* 1998;128:33–6.
 14. Ilias I, Chang R, Pacak K, Oldfield EH, Wesley R, Doppman J, et al. Jugular venous sampling: An alternative to petrosal sinus sampling for the diagnostic evaluation of adrenocorticotrophic hormone-dependent Cushing's syndrome. *J Clin Endocrinol Metab* 2004;89:3795–800.