

# Intraoperative Laser Speckle Contrast Imaging in DIEP Breast Reconstruction: A Prospective Case Series Study

Johan Zötterman, MD\*†  
 Dries Opsomer, MD‡  
 Simon Farnebo, MD\*†  
 Phillip Blondeel, PhD‡  
 Stan Monstrey, MD, PhD‡  
 Erik Tesselaar, PhD§†

**Introduction:** Laser speckle contrast imaging (LSCI) is a laser-based perfusion imaging technique that recently has been shown to predict ischemic necrosis in an experimental flap model and predicting healing time of scald burns. The aims were to investigate perfusion in relation to the selected perforator during deep inferior epigastric artery perforator (DIEP) flap surgery, and to evaluate LSCI in assisting of prediction of postoperative complications.

**Methods:** Twenty-three patients who underwent DIEP-procedures for breast reconstruction at 2 centers were included. Perfusion was measured in 4 zones at baseline, after raising, after anastomosis, and after shaping the flap. The perfusion in relation to the selected perforator and the accuracy of LSCI in predicting complications were analyzed.

**Results:** After raising the flap, zone I showed the highest perfusion ( $65 \pm 10$  perfusion units, PU), followed by zone II ( $58 \pm 12$  PU), zone III ( $53 \pm 10$  PU), and zone IV ( $45 \pm 10$  PU). The perfusion in zone I was higher than zone III ( $P = 0.002$ ) and zone IV ( $P < 0.001$ ). After anastomosis, zone IV had lower perfusion than zone I ( $P < 0.001$ ), zone II ( $P = 0.01$ ), and zone III ( $P = 0.02$ ). Flaps with areas  $< 30$  PU after surgery had partial necrosis postoperatively ( $n = 4$ ).

**Conclusions:** Perfusion is highest in zone I. No perfusion difference was found between zones II and III. Perfusion  $< 30$  PU after surgery was correlated with partial necrosis. LSCI is a promising tool for measurement of flap perfusion and assessment of risk of postoperative ischemic complications. (*Plast Reconstr Surg Glob Open* 2020;8:e2529; doi: [10.1097/GOX.0000000000002529](https://doi.org/10.1097/GOX.0000000000002529); Published online 21 January 2020.)

## INTRODUCTION

Breast reconstruction using free flaps has become a standard surgical procedure in most plastic surgical departments today. It has been shown to increase the quality of life of patients after ablative surgery and is preferred over implants when the mastectomy site tissues are of bad quality, for example, when the tissues have been irradiated.<sup>1,2</sup> Although the reported success rate of free flap-based breast reconstruction is high, partial necrosis

of either the free flap or the mastectomy skin is still a relatively common concern.<sup>3</sup>

Postoperative necrosis may necessitate revisionary procedures and leads to worse aesthetic outcomes, increased risk for infection, poor wound healing, anastomotic thrombosis, and fat necrosis.<sup>4,5</sup> To decrease the risk of postoperative necrosis, the surgeon relies on the fact that the flap contains angiosomes related to the chosen perforator.<sup>6</sup> Schefflan and Dinner and Hartrampf et al described these perfusion zones in the transverse rectus abdominis myocutaneous flap by dividing it into 4 equal zones based on their perfusion.<sup>7,8</sup> Holm et al later used fluorescent perfusion to show that blood flows to the ipsilateral side first before crossing the midline on the deep inferior epigastric artery perforator (DIEP) flap and therefore suggested that zones II and III of the Hartrampf classification should be inverted.<sup>9</sup>

To evaluate the viability in different parts of the flap, the microcirculation is repeatedly assessed by the surgeon intraoperatively. This can be achieved by evaluating skin color and temperature, dermal edge bleeding, or capillary

From the \*Department of Hand and Plastic Surgery and Burns, Linköping University, Linköping, Sweden; †Department of Clinical and Experimental Medicine, Linköping University, Linköping, Sweden; ‡Department of Plastic and Reconstructive Surgery, University of Ghent, Ghent, Belgium; and §Department of Medical Radiation Physics, Linköping University, Linköping, Sweden.

Received for publication April 5, 2019; accepted October 3, 2019.

Copyright © 2020 The Authors. Published by Wolters Kluwer Health, Inc. on behalf of The American Society of Plastic Surgeons. This is an open-access article distributed under the terms of the [Creative Commons Attribution-Non Commercial-No Derivatives License 4.0 \(CCBY-NC-ND\)](https://creativecommons.org/licenses/by-nc-nd/4.0/), where it is permissible to download and share the work provided it is properly cited. The work cannot be changed in any way or used commercially without permission from the journal.

DOI: [10.1097/GOX.0000000000002529](https://doi.org/10.1097/GOX.0000000000002529)

**Disclosure:** The authors have no financial interest to declare in relation to the content of this article.

refill time. All of these methods are rather user dependent and will differ from measurement to measurement.

Less subjective methods for intraoperative assessment of free flaps are therefore in use, or under development. Examples of such techniques are infrared imaging, hyperspectral imaging, dynamic infrared thermography, optical diffusion imaging spectroscopy, near-infrared spectroscopy, spatial frequency domain imaging, different laser Doppler-based techniques, Doppler-based ultrasound technology, transit-time flow volume measurement, and different techniques based on fluorescence angiography.<sup>10–14</sup>

Although the abovementioned techniques give objective assessment of microvascular viability, many of them have limitations that have prevented them from becoming mainstream techniques in the clinic. Fluorescence angiography requires the repeated injection of fluorescent dyes, whereas many of the other laser-based techniques have long measurement times and often complicated analysis. Laser speckle contrast imaging (LSCI) is an easy-to-use, full-field imaging technique for the measurement of tissue perfusion that does not require any contrast agents and that enables measurement times of typically a few seconds. In skin, it measures microvascular perfusion at a depth of approximately 300  $\mu\text{m}$ , corresponding to the dermal microcirculation. We have previously evaluated LSCI for intraoperative assessment of tissue viability, to investigate the distribution of the perfusion in flaps and to predict ischemic necrosis in flaps using an experimental flap model.<sup>15,16</sup> LSCI perfusion measurements have also been used to predict healing time of scald burns.<sup>17</sup> In a recent study by To et al, the feasibility of LSCI as an instrument for intraoperative assessment of perfusion during free flap breast reconstruction has been evaluated. In the study, zonal perfusion analyses were shown to match the Holm classification and areas with the risk of developing postoperative complications were identified.<sup>18</sup>

The aims of our current study were to (1) investigate the perfusion distribution in relation to the selected perforator during DIEP flap surgery, as measured with LSCI, and (2) to evaluate whether LSCI can assist in predicting postoperative complications.

## METHODS

### Study Design

This was a prospective case series study in 2 centers to make microcirculatory evaluations of women having breast reconstruction with a DIEP flap. The study was done in the University Hospital in Gent, Belgium, and the University Hospital in Linköping, Sweden. A total of 4 different plastic surgeons did the procedures. The research protocol was approved by the local ethics committees in Linköping, Sweden (Dnr 2012/31/31), and Ghent, Belgium (KW/1792/PLA/001/022). The study was carried out according to the Declaration of Helsinki (1983).

### Patients

Twenty-three patients who underwent a primary, secondary, or tertiary DIEP procedure, either unilateral or

bilateral, were included in the study. Seven of the patients were not included in the part of the study in which the perfusion in relation to the location of the perforator was investigated. This was either because the DIEP procedure was bilateral (6) or because of missing data on the exact location of the perforator (1). Patient demographics and surgical parameters for the patients who were followed up postoperatively are shown in Table 1.

There were no preestablished exclusion criteria for participation in the study. The age of the patients ranged between 38 and 55 years, and the mean (SD) body mass index was 24.4 (3.6)  $\text{kg}/\text{m}^2$ . None of the patients were current smokers or diabetics. One patient had a history of Hodgkin lymphoma and suffered from arterial hypertension. All patients were followed up daily for surgical complications such as stiffness, partial flap necrosis, and flap loss for at least 3 days after surgery, and later complications were registered if they required intervention. Postoperative evaluations were done by plastic surgeons who were blinded to the perfusion data.

### LSCI

A Laser Speckle Contrast Imager (Pericam PSI system, Perimed AB, Järfälla, Sweden) was used to measure skin perfusion intraoperatively. The system uses a divergent laser beam with a wavelength of 785 nm. A complementary metal oxide semiconductor (CMOS) camera captures the speckle pattern created by the laser light on the assessed surface. From this pattern, a perfusion value is calculated, given as perfusion units (PU). PU is an arbitrary unit, proportional to the concentration and mean velocity of the red blood cells. The theoretical principles of LSCI are further described by Briers et al.<sup>19,20</sup>

During measurements, the distance between the LSCI camera and the flap was kept between 25 and 35 cm, which is within the 10–40 cm range recommended by the manufacturer. The field of view was set to 25 by 20 cm. The point density was set to normal, resulting in a spatial resolution of 0.05 mm/pixel. The frame rate was set to 21 images per second, and 10 consecutive images were averaged, yielding an effective frame rate of 2.1 images per second. In most patients, 2 images had to be acquired to cover the complete flap (Fig. 1).

### Experimental Protocol

A baseline measurement on the abdomen was performed after anesthesia before the first incision. After the

**Table 1. Patient Demographics and Surgical Parameters**

Age, y (SD)	53.9 (8.8)
BMI, $\text{kg}/\text{m}^2$ (SD)	24.9 (3.6)
Ischemia time, min (SD)	69.1 (20.1)
Flap weight, g (SD)	721 (321)
No. perforators at each side	
Left (%)	5 (22%)
Right (%)	11 (48%)
Bilateral (%)	6 (26%)
Unknown (%)	1 (4%)
Blood pressure (during raised flap)	
Systolic, mmHg (SD)	99.8 (8.1)
Diastolic, mmHg (SD)	55.3 (7.0)
Pulse (during raised flap), BPM (SD)	72.9 (7.9)

BMI, body mass index; BPM, beats per minute.



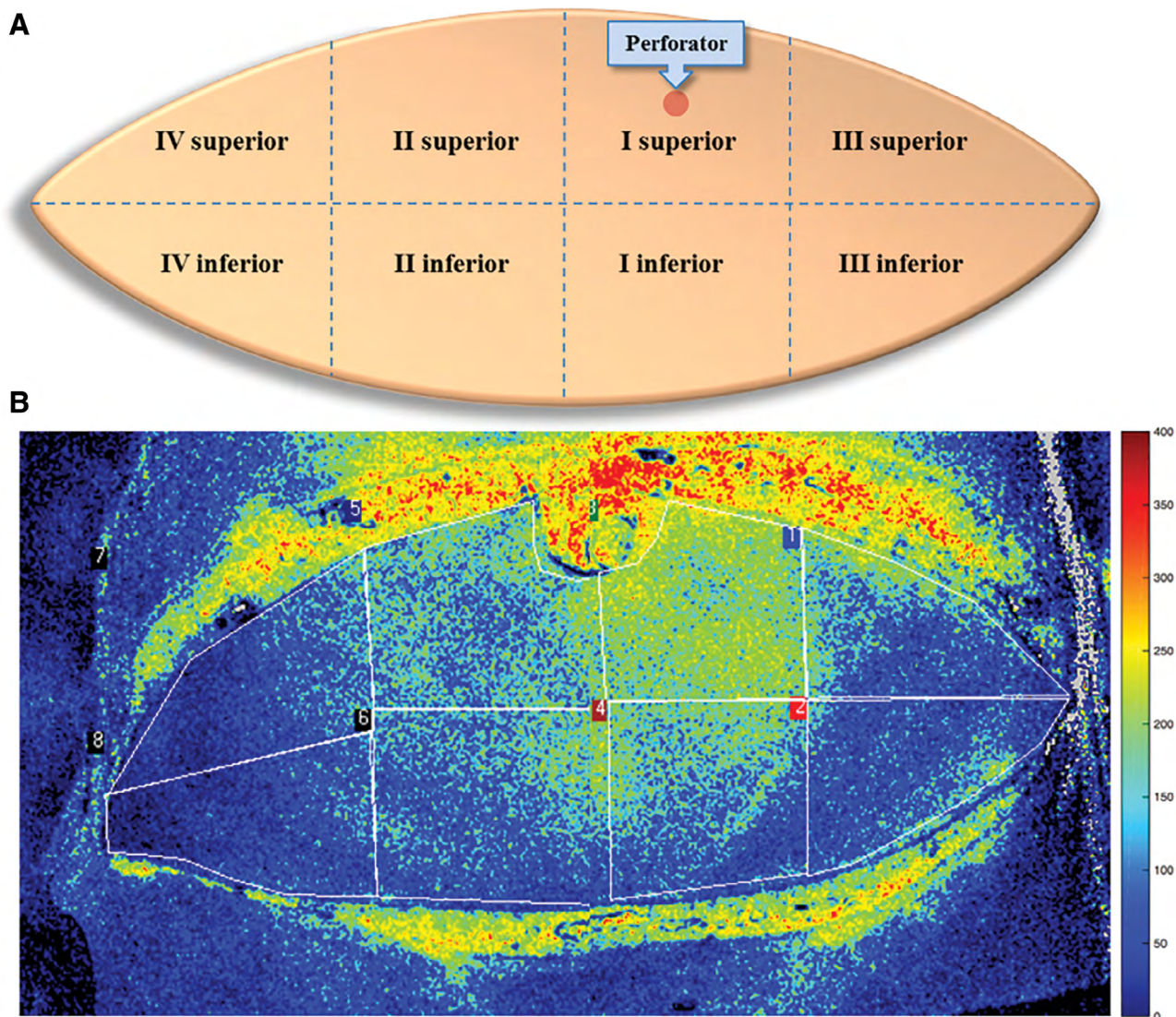
flap was completely raised, but before clipping the pedicle, a second measurement was made.

Blood pressure and heart rate were registered during the second measurement. A third measurement was done after anastomosis of the pedicle to the internal mammary vessels. Finally, a fourth measurement was made after the breast was shaped and sutured in place. Each measurement covered the complete surface area of the flap. To avoid motion artifacts, ventilation was withheld during the measurements.

#### Data Analysis

Flaps were divided into 8 regions of interest which were manually selected using the LSCI system's software (PimSoft 1.5; Perimed AB, Järfalla, Sweden): left lateral superior, left lateral inferior, left medial

superior, left medial inferior, right medial superior, right medial inferior, right lateral superior, right lateral inferior (Fig. 1). Then, cranial and caudal regions were combined to analyze the perfusion zones similar to the zones described by Hartrampf et al.<sup>8</sup> The bilateral reconstructions were excluded from this analysis as each flap contains only 2 zones of perfusion (I and III). Descriptive statistics about the perfusion in the different zones during different measurement points are expressed as mean (SD). Two-way analyses of variance were performed to test whether differences in perfusion between region of interest were significant. Statistical calculations were performed using Graph-Pad Prism version 7.0 for Windows (GraphPad Software, San Diego, CA, USA). With all analyses, probabilities of less than 0.05 were accepted as significant.



**Fig. 1.** Schematic representation (A) and typical LSCI perfusion image (B) showing the regions in the DIEP flaps in which perfusion was analyzed (the perfusion map is composed of 2 images taken at the same time point). Hartrampf zones I–IV were subdivided into superior and inferior parts. The perforator is found in the superior part of region I. The warmer colors represent higher perfusion values, and the image clearly shows a well-perfused area above the perforator. In this particular flap, the surgeon would preferably have chosen zones I and II for the reconstruction and discarded the rest of the flap.

After flap shaping, the perfusion in all flaps, including bilateral flaps, was reassessed in specific areas considered to be at risk for postoperative complications. Specifically, the lowest mean perfusion averaged over a 4-cm<sup>2</sup> circular region was considered as “minimal PU” of each flap. The perfusion in the adjacent mastectomy skin was also measured using this method. Areas of the flap or the adjacent skin were then categorized as either having no complications or having necrosis of tissue occurring within 3 days after surgery). A receiver operator characteristic curve was calculated using all “minimal PU” values to determine sensitivity and specificity of the “minimal PU” to predict postoperative complications.

**RESULTS**

Table 2 shows the measured perfusion values for the different Hartrampf zones divided into superior and inferior parts. The 2-way analyses of variance indicated significantly different perfusion values between the Hartrampf zones ( $P < 0.001$ ), but no significant difference between the superior and the inferior part of a zone; therefore, superior and inferior parts were merged and only the traditional Hartrampf zones were considered in further analyses.

The perfusion in the different Hartrampf zones of the flaps during baseline, in the raised flap and after anastomosis, is shown in Figure 2. At baseline, the perfusion in zone I was significantly higher than the perfusion in zone III ( $61 \pm 16$  and  $51 \pm 13$  PU,  $P = 0.006$ ), and in zone IV ( $53$

$\pm 12$ ,  $P = 0.02$ ). Zone II was significantly higher than zone III ( $62 \pm 15$  and  $51 \pm 13$  PU,  $P < 0.004$ ).

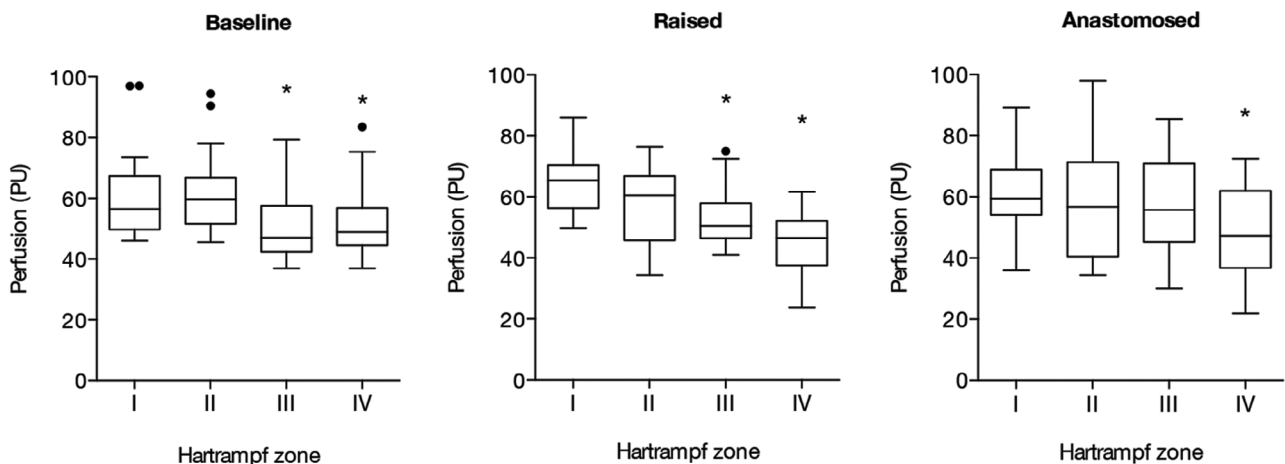
After raising the flap, the perfusion in zone I was significantly higher than that in zone III ( $65 \pm 10$  and  $53 \pm 10$  PU,  $P = 0.002$ ) and zone IV ( $45 \pm 11$ ,  $P < 0.001$ ), but not zone II ( $58 \pm 12$  PU,  $P = 0.21$ ). There was no longer a significant difference between zones II and III ( $P = 0.45$ ).

After anastomosis, perfusion was significantly lower in zone IV compared with all other zones ( $P < 0.02$ ) and there were no significant differences in perfusion between zones I, II, and III.

There were postoperative complications in 4 flaps (Table 3). All the flaps with a minimum perfusion  $< 30$  PU directly after surgery had postoperative complications and required revision (Fig. 3). In 3 flaps, partial necrosis occurred either in the medial or lateral parts, and perfusion in those parts was  $< 30$  PU directly after surgery (18, 22, and 26 PU, respectively). In 1 patient, necrosis occurred in the adjacent mastectomy skin that showed low perfusion after surgery (16 PU). In another patient, stiffness of the lower pole was observed but without need for revision. The affected area had a perfusion of 30 PU directly after surgery. In another patient, the flap had adequate perfusion ( $> 50$  PU) and was without complications for 2 weeks. However, a full necrosis eventually developed, but this was attributed to an infection in the flap. Receiver operator characteristic analysis of the perfusion data revealed a cutoff of 30 PU to predict postoperative complications with 100% accuracy.

**Table 2. Mean (SD) PU in the Different Zones at Different Phases of the Surgery, Measured Using LSCI**

	Zone I Superior	Zone I Inferior	Zone II Superior	Zone II Inferior	Zone III Superior	Zone III Inferior	Zone IV Superior	Zone IV Inferior
Baseline	59.8 (14.4)	58.0 (14.1)	60.5 (12.1)	59.9 (15.3)	49.3 (11.7)	49.3 (11.9)	51.4 (12.3)	52.3 (12.6)
Raised	69.6 (13.3)	59.9 (9.7)	60.8 (9.4)	53.0 (11.9)	54.9 (10.8)	49.9 (11.4)	46.3 (9.0)	43.6 (10.2)
Anastomosis	64.3 (15.2)	62.7 (18.5)	62.1 (26.4)	57.3 (13.4)	56.6 (15.6)	57.2 (18.7)	49.1 (17.2)	48.3 (12.5)

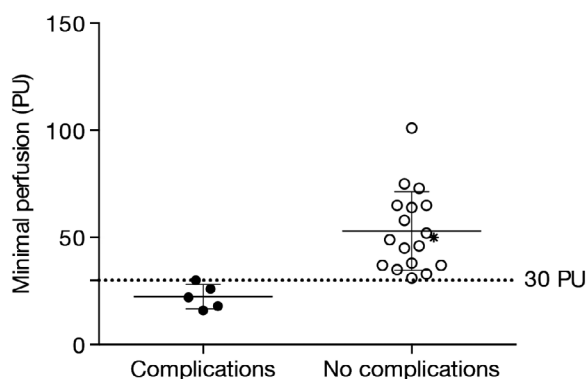


**Fig. 2.** Box plots of the perfusion, specified in PU, in different Hartrampf zones of the DIEP flaps. The perfusion was significantly lower in zones III and IV compared with zone I at baseline ( $P = 0.006$ , respectively,  $P = 0.02$ ) and when the flaps were raised ( $P = 0.002$ , respectively,  $P < 0.001$ ). When the vessels were anastomosed, the perfusion in zone IV was significantly lower than that in zones I-III ( $P < 0.02$ ). \* indicates a significant difference between zones. Closed circles indicate outliers. A, Baseline; B, Raised; C, Anastomosed.

**Table 3. Relation between Perfusion Values Directly after Surgery and Postoperative Outcome**

PU	No. Flaps (n)	Postoperative Complications (n)	Comments
<20	2	2	Partial necrosis lateral (1), necrosis of mastectomy skin flap (1)
20–29	2	2	Partial necrosis, lateral (1) and medial (1)
30–39	7	0	No postoperative complications (1 flap showed stiffness of the tissue in the lower pole without need for revision)
>40	12	0	No postoperative complications*
Total	23	4	

\*In 1 flap with adequate perfusion >40 PU, necrosis occurred 14 d after surgery, which was related to an infection.



**Fig. 3.** All cases of postoperative complications (closed circles) were found in the group with minimum perfusion values at 30 PU or below. \* indicates the flap that went necrotic after 2 weeks due to infection.

## DISCUSSION

Understanding the perfusion pattern in DIEP flaps aids surgeons with surgical planning and in deciding which parts of the flaps are viable. Measurement of perfusion during surgery may give even further insight into which parts are to be discarded, as regions with low perfusion may be at risk for postoperative necrosis. Lee and Mun have recently described what is currently known about perfusion in DIEP flaps.<sup>21</sup> They found that different studies have shown considerable discrepancy regarding the distribution of perfusion, in particular with respect to the perfusion in zones II and III. This may be related to spatial differences of the blood flow due to localization of the perforator. For example, medial perforators more often give branches that cross the midline, whereas lateral perforators seldom branch across the midline. A more thorough study would stratify lateral and medial perforators although our study included too few lateral perforators to show any significant differences.

In this study, we chose to divide flaps in perfusion zones according to Hartrampf, as this method has traditionally been used in our clinic.<sup>8</sup> We have focused on differences between zone I and the remaining zones and

differences between zones II and III because we believe these to be the most clinically relevant. Unlike the meta study done by Lee and Mun, we could see no significant difference in perfusion between zones II and III, neither directly after the flap was raised, nor after anastomosis, when comparing absolute perfusion.<sup>21</sup> However, neither the change in perfusion after raising the flap, nor after anastomosis, compared to baseline was significantly different between zones II and III. This might suggest that, at least with medial perforators, zones II and III will have a similar risk of postoperative complications. On the other hand, we cannot rule out the possibility that the lack of significance is due to the limited number of patients included in this study.

To assess flap viability, surgeons usually rely on subjective methods such as color of the skin, temperature of the flap, capillary refill time, and dermal edge bleeding. These methods require surgical experience and can be unreliable in some patients, for instance, when the vascular anatomy varies from the normal or when patients have a very dark skin.

Objective measurement of perfusion is sometimes used as a complement to visual and tactile methods, and the most commonly used technique is indocyanine green (ICG) angiography. ICG angiography overcomes many drawbacks that other techniques, such as laser Doppler flowmetry and fluorescein angiography, have and has been found to be accurate in assessing flap perfusion.<sup>22</sup> Still, a limitation of ICG angiography is that it requires intravenous dye injection and that it takes a relatively long time, particularly with repeated measurements. Also, it may fail to identify venous congestion.<sup>23</sup>

LSCI on the other hand is a fast and completely non-invasive technique. It is based on the fact that the speckle pattern created on a surface by a laser source will contain information about the speed and concentration of erythrocytes in the superficial capillaries of the skin. The pattern is analyzed by a computer that presents an arbitrary value of the perfusion. This means that the flap can be reassessed multiple times before, during, and after the operation.

We have shown in a previous study that the LSCI can detect both partial and complete venous occlusions, as well as arterial occlusions.<sup>15</sup> It does not require injection of fluorescent dyes, and perfusion images over a large area of tissue can be acquired within seconds. A major difference between LSCI and angiography techniques is the vascular bed which is evaluated. LSCI has a measurement depth in intact skin of approximately 0.5 mm, which means that it assesses the dermal microcirculation and not the deeper vasculature. Therefore, LSCI cannot be used for the identification of perforators.

An advantage with LSCI compared to some other non-invasive methods is the high spatial and temporal resolution. Laser Doppler perfusion imaging has been used for free flap imaging and is also completely noninvasive, but much slower with a lower resolution.<sup>24</sup>

Hyperspectral imaging is a fairly new technique using both visible and near-infrared light to create a high-resolution image of tissue perfusion. It seems to be a very



promising method for flap assessment, but the downside of this technique compared to LSCI is its sensitivity to external light interference.<sup>13</sup>

Another advantage of the LSCI system used in this study compared to other methods for perioperative evaluation of free flaps is the relatively low cost per case. The cost for the Pericam PSI system, given by the manufacturer Perimed AB, is about \$56,000. Because the method is completely noninvasive, there is no additional cost per case. This can be compared to the SPY Elite, one of the more widespread systems for ICG angiography in clinical use, where the cost of the operating unit is about \$275,000 with an additional cost of \$275 for the ICG dye and drapes for every additional case.<sup>25</sup>

A shortcoming in this study is the lack of control to other imaging techniques. It would have added value to the study if we had been able to compare our LSCI results with results from more established methods for intraoperative mapping of microcirculation, such as ICG angiography. Unfortunately, neither of the centers involved in the study had access to equipment for ICG angiography.

As with ICG angiography, a major issue in the use of LSCI is to find a reliable perfusion level that can differentiate adequate from inadequate perfusion and that accurately identifies tissue regions at risk for necrosis. Findings in our limited material suggest that there is a cut of around 30 PU to predict postoperative complications. This study had a too small sample size to draw any clear conclusion regarding threshold perfusion values that could predict future complications. Nevertheless, we believe that this and other LSCI studies indicate that such a value might be found. A larger sample will probably give a more reliable value, but the LSCI measurements should still just be a complement to the clinical judgment of an experienced surgeon.

Because measurements are done peri-operatively, perfusion data can only predict morbidity in parts of the flap that have compromised microcirculation related to limitations in branches from the perforators during surgery. As we have shown in previous studies, it is possible to use LSCI to identify postoperative causes of ischemia and flap failure such as venous or arterial occlusions, but this requires continuous or intermittent LSCI monitoring after the surgery.<sup>15,16</sup> As mentioned in the “Results” section, 1 flap that had adequate perfusion intraoperatively and initially was free of complications developed full necrosis after 2 weeks. This was probably caused by a late infection. Still, one might speculate that some of these late complications might partly be caused by inadequate perfusion in parts of the flap and could thereby be prevented by better mapping of the microcirculation intraoperatively.

A limitation of the study is the fact that we did not have a way to identify the different zones after the flap was shaped. It would have been interesting to follow the different zones throughout the operation and postoperatively. This might have been possible with a clearer and longer lasting marking of the flap when it was raised. Another limitation of the study is that we did not control for confounding factors when analyzing flap perfusion and perfusion distribution including the relation to postoperative complications.

A possible improvement of the study could have been to include ultrasound mapping of the new breast in the follow-ups. This would have offered a more objective quantitative evaluation of complications, including fat loss due to fat necrosis. Also, a larger prospective study potentially would make it possible to find a more reliable threshold value that with higher accuracy could predict future complications.

Still, we believe that our findings together indicate that LSCI offers an easy, completely noninvasive, and relatively cost-effective method for intraoperative evaluation of microcirculation in free flaps and that the technique may aid surgeons in intraoperative planning of free flaps and predicting risk for postoperative ischemia and necrosis.

## CONCLUSIONS

The results of this study confirm that the microvascular perfusion in the skin of the DIEP flap is highest in Hartrampf zone I. We found no difference in perfusion between zones II and III, neither directly after flap harvest nor after microsurgical anastomosis.

In our investigation, flap areas with perfusion values of less than 30 PU at the end of surgery correlated with postoperative flap necrosis.

**Johan Zötterman, MD**

Department of Plastic Surgery, Hand Surgery and Burns  
Linköping University Hospital  
58185 Linköping, Sweden  
E-mail: johan.zotterman@liu.se

## REFERENCES

1. Liu T, Freijs C, Klein HJ, et al. Patients with abdominal-based free flap breast reconstruction a decade after surgery: a comprehensive long-term follow-up study. *J Plast Reconstr Aesthet Surg.* 2018;71:1301–1309.
2. Yueh JH, Slavin SA, Adesiyun T, et al. Patient satisfaction in post-mastectomy breast reconstruction: a comparative evaluation of DIEP, TRAM, latissimus flap, and implant techniques. *Plast Reconstr Surg.* 2010;125:1585–1595.
3. Wormald JC, Wade RG, Figus A. The increased risk of adverse outcomes in bilateral deep inferior epigastric artery perforator flap breast reconstruction compared to unilateral reconstruction: a systematic review and meta-analysis. *J Plast Reconstr Aesthet Surg.* 2014;67:143–156.
4. Patel KM, Hill LM, Gatti ME, et al. Management of massive mastectomy skin flap necrosis following autologous breast reconstruction. *Ann Plast Surg.* 2012;69:139–144.
5. Olsen MA, Chu-Ongsakul S, Brandt KE, et al. Hospital-associated costs due to surgical site infection after breast surgery. *Arch Surg.* 2008;143:53–60; discussion 61.
6. Taylor GI, Palmer JH. The vascular territories (angiosomes) of the body: experimental study and clinical applications. *Br J Plast Surg.* 1987;40:113–141.
7. Schefflan M, Dinner MI. The transverse abdominal island flap: part I. Indications, contraindications, results, and complications. *Ann Plast Surg.* 1983;10:24–35.
8. Hartrampf CR, Schefflan M, Black PW. Breast reconstruction with a transverse abdominal island flap. *Plast Reconstr Surg.* 1982;69:216–225.
9. Holm C, Mayr M, Höfter E, et al. Perfusion zones of the DIEP flap revisited: a clinical study. *Plast Reconstr Surg.* 2006;117:37–43.
10. Phillips BT, Munabi NC, Roeder RA, et al. The role of intraoperative perfusion assessment: what is the current state and how can I use it in my practice? *Plast Reconstr Surg.* 2016;137:731–741.

11. Tindholdt TT, Saidian S, Tønseth KA. Microcirculatory evaluation of deep inferior epigastric artery perforator flaps with laser Doppler perfusion imaging in breast reconstruction. *J Plast Surg Hand Surg*. 2011;45:143–147.
12. Ingvaldsen CA, Tønseth KA, Pripp AH, et al. Microcirculatory evaluation of the abdominal skin in breast reconstruction with deep inferior epigastric artery perforator flap. *Plast Reconstr Surg Glob Open*. 2016;4:e616.
13. Kulcke A, Holmer A, Wahl P, et al. A compact hyperspectral camera for measurement of perfusion parameters in medicine. *Biomed Tech (Berl)*. 2018;63:519–527.
14. Chin MS, Chappell AG, Giatsidis G, et al. Hyperspectral imaging provides early prediction of random axial flap necrosis in a pre-clinical model. *Plast Reconstr Surg*. 2017;139:1285e–1290e.
15. Zötterman J, Bergkvist M, Iredahl F, et al. Monitoring of partial and full venous outflow obstruction in a porcine flap model using laser speckle contrast imaging. *J Plast Reconstr Aesthet Surg*. 2016;69:936–943.
16. Zötterman J, Tesselaar E, Farnebo S. The use of laser speckle contrast imaging to predict flap necrosis: an experimental study in a porcine flap model. *J Plast Reconstr Aesthet Surg*. 2019;72:771–777.
17. Mirdell R, Iredahl F, Sjöberg F, et al. Microvascular blood flow in scalds in children and its relation to duration of wound healing: a study using laser speckle contrast imaging. *Burns*. 2016;42:648–654.
18. To C, Rees-Lee JE, Gush RJ, et al. Intraoperative tissue perfusion measurement by laser speckle imaging: a potential aid for reducing postoperative complications in free flap breast reconstruction. *Plast Reconstr Surg*. 2019;143:287e–292e.
19. Briers D, Duncan DD, Hirst E, et al. Laser speckle contrast imaging: theoretical and practical limitations. *J Biomed Opt*. 2013;18:066018.
20. Briers JD, Richards G, He XW. Capillary blood flow monitoring using laser speckle contrast analysis (LASCA). *J Biomed Opt*. 1999;4:164–175.
21. Lee KT, Mun GH. Reply to questions on “serial two-year follow-up after lymphaticovenular anastomosis for the treatment of lymphedema”. *Microsurgery*. 2018;38:435.
22. Sood M, Glat P. Potential of the SPY intraoperative perfusion assessment system to reduce ischemic complications in immediate postmastectomy breast reconstruction. *Ann Surg Innov Res*. 2013;7:9.
23. Ludolph I, Arkudas A, Schmitz M, et al. Cracking the perfusion code?: laser-assisted indocyanine green angiography and combined laser Doppler spectrophotometry for intraoperative evaluation of tissue perfusion in autologous breast reconstruction with DIEP or ms-TRAM flaps. *J Plast Reconstr Aesthet Surg*. 2016;69:1382–1388.
24. Zdolsek JM, Droog EJ, Thorfinn J, et al. Laser Doppler perfusion imaging of the radial forearm flap: a clinical study. *Scand J Plast Reconstr Surg Hand Surg*. 2006;40:101–105.
25. McGregor A, Pavri SN, Tsay C, et al. Use of indocyanine green for sentinel lymph node biopsy: case series and methods comparison. *Plast Reconstr Surg Glob Open*. 2017;5:e1566.