

Management of Giant Retinal Tear Detachments

Maria H. Berrocal¹, MD; Megan L. Chenworth², BS; Luis A. Acaba³, BA

¹Department of Ophthalmology, University of Puerto Rico, San Juan, Puerto Rico, USA

²School of Medicine, University of Pennsylvania Perelman, Pennsylvania, USA

³Sidney Kimmel Medical College, Thomas Jefferson University, Philadelphia, PA, USA

Abstract

Giant retinal tears (GRTs) are full-thickness circumferential tears of more than 90 degrees of the retina that are associated with vitreous detachment. They are related to ocular trauma, high myopia, aphakia, pseudophakia, genetic mutations involving collagen and young age. GRTs comprise 1.5% of all rhegmatogenous retinal detachments and the average age of incidence is 42 years. GRTs are more common in males, as 72% of all cases occur in males. The incidence of GRTs in the general population is estimated to be 0.05 per 100,000 individuals. Common techniques used in the management of GRTs include fluid-air exchange, pneumatic retinopexy, scleral buckling, primary vitrectomy with gas or silicone oil tamponade, and combined scleral buckle-vitrectomies. However, management of GRTs poses a great challenge to physicians due to the high risk of intra- and post-operative complications and the many technical difficulties involved. The advent of perfluorocarbon liquids (PFCL) and the use of micro-incisional surgery for the treatment of GRTs has provided new opportunities for the management of GTRs. Today, retinal reattachment can be achieved in 94-100% of cases.

Keywords: Giant Retinal Tears, Perfluorocarbon Liquids, Micro-incisional Surgery

J Ophthalmic Vis Res 2017; 12(1): 93-97

INTRODUCTION

Giant retinal tears (GRTs) are defined as full-thickness circumferential tears of more than 90 degrees of the retina associated with vitreous detachment.^[1-3] Their management poses significant challenges due to the many complications and technical difficulties involved. Although GRTs can occur spontaneously, they are often associated with a number of conditions; these include ocular trauma, high myopia, aphakia,

pseudophakia, genetic mutations involving collagen and young age.^[4-7] Common techniques used to treat GRTs include fluid-air exchange, pneumatic retinopexy, scleral buckling, primary vitrectomy with gas or silicone oil tamponade, and combined scleral buckle-vitrectomies.^[8] Perfluorocarbon liquids (PFCLs) revolutionized the management of GRTs and the advent of small gauge vitrectomy techniques have further optimized the treatment outcomes.

INCIDENCE AND ETIOLOGY

GRTs comprise about 1.5% of rhegmatogenous retinal detachments.^[9] The average age of incidence is 42 years.^[2,9] There is usually a higher incidence in males than females, with males comprising 72% of cases.^[2] This

Correspondence to:

Maria H. Berrocal, MD. Department of Ophthalmology, University of Puerto Rico, 140 De Diego Ave., Suite 404, San Juan, Puerto Rico 00909, USA.

E-mail: mariaherrocal@hotmail.com

Received: 24-07-2016

Accepted: 20-08-2016

Access this article online

Quick Response Code:



Website:

www.jovr.org

DOI:

10.4103/2008-322X.200158

This is an open access article distributed under the terms of the Creative Commons Attribution-NonCommercial-ShareAlike 3.0 License, which allows others to remix, tweak, and build upon the work non-commercially, as long as the author is credited and the new creations are licensed under the identical terms.

For reprints contact: reprints@medknow.com

How to cite this article: Berrocal MH, Chenworth ML, Acaba LA. Management of giant retinal tear detachments. *J Ophthalmic Vis Res* 2017;12:93-7.

condition can occur as a result of a number of baseline conditions. About 54% of GRTs are idiopathic, 12.3% result from trauma, 25% result from high myopia, and 14% result from other hereditary conditions such as Marfan's, Stickler-Wagner, and Ehler Danlos syndromes.^[2,3,10,11] About 12.8% of patients develop bilateral GRTs.^[9,12] The reported estimates of incidence put this condition at 0.05 per 100,000 of the general population per year.^[2,12-15] Despite its relative rarity, this condition poses great challenges in management due to its high risk of intra- and post-operative complications and the many technical difficulties involved.

Pathogenesis

Giant retinal tears occur from liquefaction of the central vitreous associated with peripheral vitreous condensation with concomitant traction in the region of the vitreous base. The neurosensory retina tears circumferentially in the area of the posterior vitreous base.^[9,12,16] The vitreous gel remains attached to the anterior flap of retina, and the torn posterior retina moves freely and can fold upon itself [Figure 1].^[9] This is the distinguishing feature between GRTs and retinal dialyses. In retinal dialyses the vitreous is adherent to the posterior aspect of the retinal tear, therefore the retina is not very mobile.^[17] As such the management of dialyses is simpler than the repair of GRTs, as dialyses can often be repaired just with laser or a scleral buckle.

Management

Medicine has come a long way in managing GRTs, aided by the innovative use of perfluorocarbon liquids described by Stanely Chang in 1987.^[18] This innovation increased the primary attachment rate from 58% to over 94% and also helped bid farewell to cumbersome and difficult surgical techniques involving inverted surgical beds (Stryker frame) and retinal tacks.^[19,20] Today, management of GRTs includes the use of laser photocoagulation, scleral buckle, primary vitrectomy with perfluorocarbon liquids (PFCL), and vitrectomy with scleral buckle or combined phaco/vitrectomy.^[3,9,21,22] Laser is effective when the retina is attached. The edge of the tear is treated with two to four rows of photocoagulation, with particular emphasis to the radial edges of the tear, treating anteriorly up to the ora serrata. Scleral buckle is effective if the edge of the tear is not inverted, and is a good option in children to preserve the lens and limit positioning issues. Support of the edges of the tear is important, as is thorough cryotherapy or photocoagulation of the tear edges. Primary vitrectomy with intraoperative use of perfluorocarbon liquids and gas or silicone oil tamponade is necessary to unroll and reposition a folded retina. Finally, if proliferate vitreoretinopathy (PVR) is present, vitrectomy with a

scleral buckle can be used, and if a significant cataract is present, combined phaco/vitrectomy is warranted.

The advent of micro-incisional surgery has provided new opportunities and challenges in the management of the giant retinal tear detachment. Advantages of small gauge vitrectomy include less trauma, smaller incisions, reduced sclerotomy complications, and shortened surgical times.^[23] Challenges of 25-gauge vitrectomy in the management of giant tears include a slower removal of vitreous, some difficulty reaching the anterior retina and vitreous near the ora serrata, flexible instruments, and a more prolonged aspiration time during the air/fluid exchange.^[24] This last step is crucial to prevent retinal slippage and extra time should be allotted for this maneuver when using smaller gauge instruments.

Surgical Techniques

Pseudophakic eyes

The specific micro-incisional surgical techniques with 25 or 23g instrumentation for the management of pseudophakic giant retinal tears without PVR include: 1- Removal of all the vitreous posteriorly and injection of perfluoro-octane liquid over the optic nerve. This is done slowly with a dual-bore cannula to prevent trauma to the retina and avoid IOP elevations [Figure 2]. The PFCL is injected as a single bubble to prevent fish eggs and dispersion and to unfold and flatten the posterior retina. 2- Once the retina is stabilized posteriorly, the anterior vitreous and the anterior retinal flap are removed [Figure 3]. Chandelier illumination and scleral depression aid in the visualization of the anterior vitreous and retina [Figure 4]. It is paramount to remove all the vitreous, particularly in the area of the corners of the tear since traction in that area is a common cause of re-detachment. 3- More PFCL is added to further flatten the retina over the level of the edge of the tear. It is important to keep the PFCL level below the infusion to avoid the formation of fish eggs. If retinal folds are

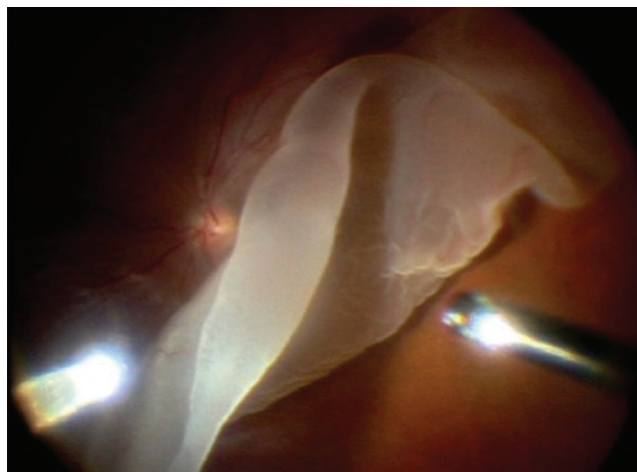


Figure 1. Giant Retinal tear of 180°.

present, the retina can be unfolded with forceps, with a soft-tip cannula or with a vitreous rake loop [Figure 5]. 4- All of the anterior retinal flap and vitreous need to be thoroughly removed with the vitrectomy probe, with complete removal of all possible vitreous traction on the corners since this is the area where any residual vitreous traction can cause proliferation, traction and re-detachment. 5- If epiretinal membranes, star folds, or macular holes are present, membranes and the ILM can be peeled through the PFCL [Figure 6]. Staining with ICG, Trypan Blue, or Brilliant Blue can be done prior to PFCL injection in these situations if deemed useful. 6- Laser is applied to the corners and edge of the tear in two to three rows up to the ora serrata, ideally using a curved laser probe [Figure 7]. The rest of the retina is checked as small breaks in the areas of attached retina can be present and should be treated. 7- A fluid air exchange is performed with aspiration of all the fluid anterior to the PFCL bubble meniscus with a soft tip cannula. As mentioned previously, it is imperative to remove all the

fluid anterior to the PFCL edge to prevent slippage of the retina prior to removing the PFCL. The residual PFCL is aspirated over the optic nerve and the eye is filled with a minimally expanding concentration of perfluoropropane or perfluoroethane gas. If using a silicone oil tamponade, it is ideal to perform a direct silicone oil/PFCL exchange with simultaneous injection of silicone oil and aspiration of PFCL since this maneuver prevents slippage [Figure 8].

Phakic eyes

If the eye is phakic, several management options are possible. Preserving the lens can be done by utilizing chandelier illumination so that scleral depression can be performed to remove the anterior retinal flap without causing trauma to the lens. Advantages of preserving the lens are that if a cataract develops in the future, accurate lens calculations can be performed, and that the risk of losing pupillary dilation from the lens removal is avoided. The main disadvantage of preserving the lens is that it is more technically difficult

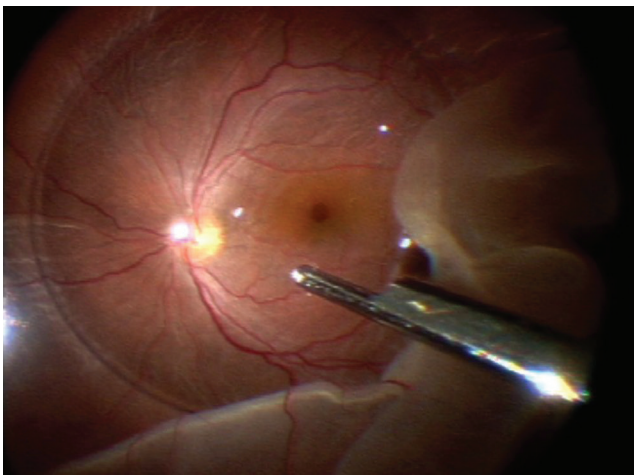


Figure 2. Injection of PFCL with a dual-bore cannula to unfold retina.

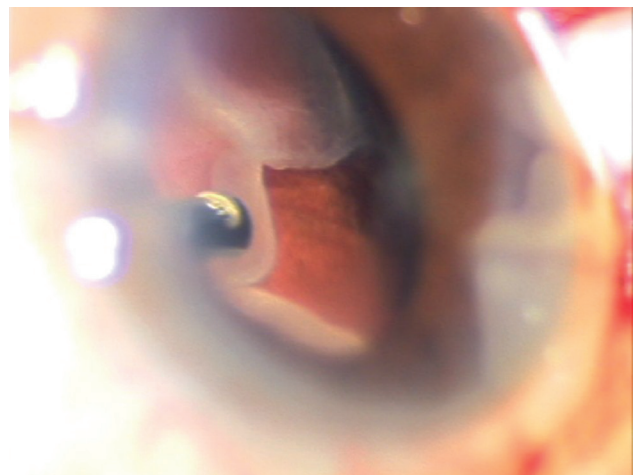


Figure 3. Removal of the anterior vitreous in the corners of the tear.

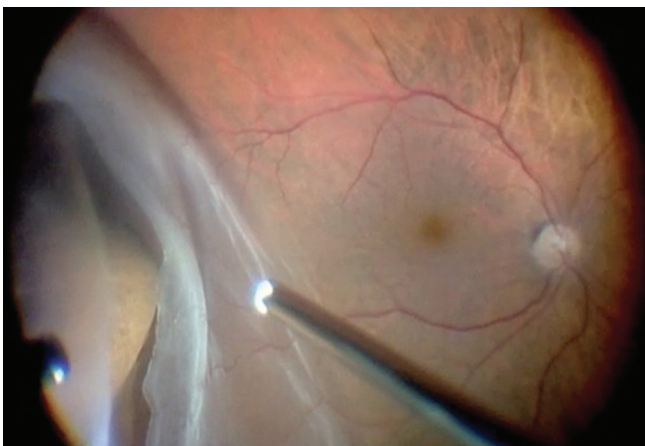


Figure 4. Scleral depression with chandelier illumination in a phakic eye to trim the anterior retinal flap.

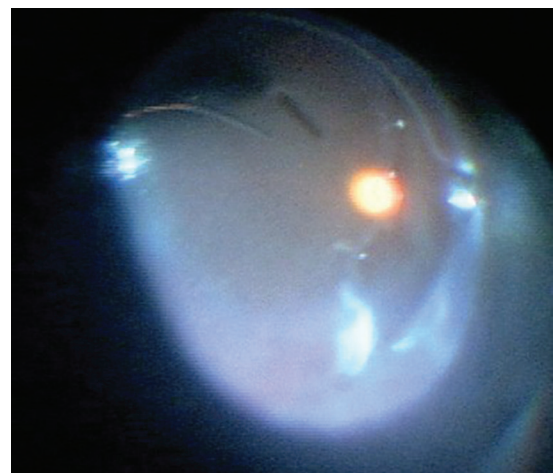


Figure 5. Laser applied to the edges of the GRT.

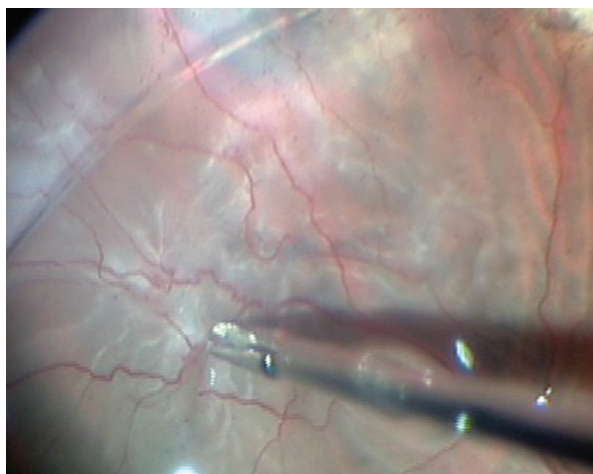


Figure 6. Removal of ERMs with forceps through the PFCL bubble.

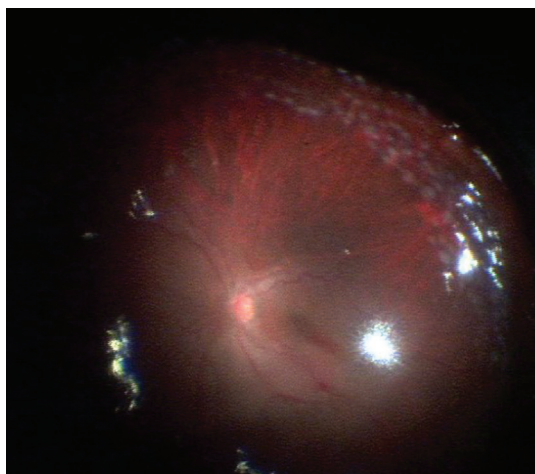


Figure 7. Rows of laser photocoagulation around the 360° GRT.

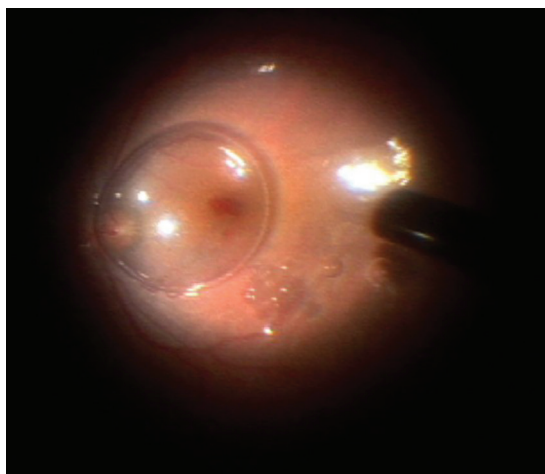


Figure 8. Direct silicone oil/PFCL exchange with remaining PFCL bubbles on the surface of the retina.

to clear the anterior vitreous and retinal flap without causing a traumatic cataract. Other options in phakic eyes include performing a phacoemulsification or pars

plana lensectomy at the time of vitrectomy with either concomitant or second procedure IOL implantation. Advantages of these approaches include easier access to the anterior structures of the eye. Disadvantages include extra procedures, imprecise intraocular lens calculations, and poor visibility due to pupillary miosis.

Proliferative vitreoretinopathy (PVR) is not uncommon in eyes with giant tear detachments due to the significant RPE dispersion and associated vitreous hemorrhage. PVR occurs in 40-50% of GRT detachments and is more common in traumatic and long-standing detachments.^[25]

The repair technique includes pre-placing an encircling #41 or #42 silicone scleral buckle prior to the vitrectomy to compensate for the shortening of the retinal surface induced by membranes in PVR and to support the vitreous base. Removal of all fibrous proliferation on both surfaces of the retina is important to achieve reattachment. Subretinal membranes are removed prior to the injection of PFCL, and membranes on the surface of the retina can be removed through the PFCL bubble. [Figure 6] After the scleral buckle is placed, vitrectomy is performed with the same techniques described above. A scleral buckle is not routinely recommended in eyes without PVR due to the creation of retinal redundancy and ensuing guttering and retinal slippage during the air-fluid exchange.

Complications

The major complications associated with micro-incisional surgery for GRTs include retinal slippage during PFCL removal; retinal folds associated with slippage, SB, or high myopia; residual PFCL; cataract progression and recurrent RD with PVR.^[3,26]

Causes of re-detachment include: anterior traction and re-proliferation at the corners of the tear, missed breaks away from the tear, the presence of concomitant macular holes, and the occurrence of PVR. Re-detachment due to PVR is more common in eyes with old detachments, blood, pre-existing membranes and pre-existing PVR.^[27]

RESULTS

The rate of reattachment following one procedure is 80-90%, while the final reattachment rate is 94-100%.^[28,29] However, if PVR is present, visual prognosis is poor despite reattachment and anatomical success.^[2]

Management of the other eye

While GRTs are fairly rare, about 12.8% of patients develop bilateral GRTs.^[9,12] Therefore, it is important to watch and manage the other eye to prevent bilateral GRTs. Characteristics that suggest a high risk for GRT include myopia over six diopters, white without pressure, and vitreous condensation.^[3,12] It is suggested that peripheral pathology should be treated with

laser.^[30,31] The use of a prophylactic buckle remains controversial.^[32,33]

In conclusion, the advent of modern vitrectomy techniques, with micro-incisional surgery, PFCLs, chandelier illuminations and valved cannulas have dramatically improved our anatomical success in the management of GRT detachments. Surgical times are reduced, complications have been minimized and reattachment rates have been improved. Nevertheless, attention needs to be given to the crucial steps of the vitrectomy procedure to ensure anatomical success. The most important pearls in the management of giant tear retinal detachments include trimming the edges of the tear well, identifying all distant breaks, injecting PFCL as a single bubble and removing all anterior fluid by drying the edges of the break thoroughly to prevent slippage.

Financial Support and Sponsorship

Nil.

Conflicts of Interest

There are no conflicts of interest.

REFERENCES

- Schepens CL, Dobbie JG, Mc MJ. Retinal detachments with giant breaks: Preliminary report. *Trans Am Acad Ophthalmol Otolaryngol* 1962;66:471-479.
- Ang GS, Townend J, Lois N. Epidemiology of giant retinal tears in the United Kingdom: The British giant retinal tear epidemiology eye study (BGEES). *Retina* 2010;51:4781-4787.
- Ghosh YK, Banerjee S, Savant V, Kotamarthi V, Benson MT, Schott RAH, et al. Surgical treatment and outcome of patients with giant retinal tears. *Eye* 2004;18:996-1000.
- Chang S, Lopez JM. Giant retinal tears and proliferative vitreoretinopathy. In: Ryan SJ, editor. *Retina*. 4th ed. St. Louis: Mosby; 2006. p. 2345-2351.
- Ang GS, Townend J, Lois N. Interventions for prevention of giant retinal tear in the fellow eye. *Cochrane Database Syst Rev* 2009;2:CD006909.
- Aylward GW, Cooling RJ, Leaver PK. Trauma-induced retinal detachment associated with giant retinal tears. *Retina* 1993;13:136-141.
- Mehdizadeh M, Afarid M, Hagigi MS. Risk factors for giant retinal tears. *J Ophthalmic Vis Res* 2010;5:246-249.
- Mathis A, Pagot V, Gazagne C, Malecaze F. Giant retinal tears: Surgical techniques and results using perfluorodecalin and silicone oil tamponade. *Retina* 1992;12(Suppl 3):S7-S10.
- Shunmugam M, Ang GS, Lois N. Giant retinal tears. *Surv Ophthalmol* 2014;59:192-216.
- Nagpal M. Giant retinal tears: Size does matter. *Retina Today* 2013; 26-28.
- Asaria RH, Kon CH, Bunce C, Charteris DG, Wong D, Khaw PT, et al. Adjuvant 5-fluorouracil and heparin prevents proliferative vitreoretinopathy: Results from a randomized, double-blind controlled clinical trial. *Ophthalmology* 2001;108:1179-1183.
- Freeman HM. Fellow eyes of giant retinal breaks. *Trans Am Ophthalmol Soc* 1978;76:343e82.
- Yorston DB, Wood ML, Gilbert C. Retinal detachment in East Africa. *Ophthalmology* 2002;109:2279-2283.
- Chou SC, Yang CH, Lee CH. Characteristics of primary rhegmatogenous retinal detachment in Taiwan. *Eye* 2007;21:1056-1061.
- Malbran E, Dodds RA, Hulsbus R, Charles DE, Buonsanti JL, Adrogué E. Retinal break type and proliferative vitreoretinopathy in nontraumatic retinal detachment. *Graefes Arch Clin Exp Ophthalmol* 1990;228:423-425.
- Schepens CL, Freeman HM. Current management of giant retinal breaks. *Trans Am Acad Ophthalmol Otolaryngol* 1967;71:474e87.
- Scott JD. Retinal dialysis. *Trans Ophthalmol Soc UK* 1977;97:33-35.
- Chang S. Low viscosity liquid fluorochemicals in vitreous surgery. *Am J Ophthalmol* 1987;103:38-43.
- Chang S, Lincoff H, Zimmerman NJ, Fuchs S. Giant retinal tears. Surgical techniques and results using perfluorocarbon liquid. *Arch Ophthalmol* 1989;107:761-766.
- Kanski JJ. Giant retinal tears. *Am J Ophthalmol* 1975;79:846-852.
- Pitcher JD. Managing Giant Retinal Tears: A video-enhanced guide to surgical repair. *Retinal Physician* 2014;11:18-21.
- Lakhanpal RR, Albin TA. Current Management of Giant Retinal Tears With Proliferative Vitreoretinopathy. *Retina Today* 2011: 49-50.
- Berrocal MH, Williams DF. Smaller gauge instruments are better and safer. *Retina Today* 2015;62-67.
- Aylward GW. Sutureless vitrectomy. *Ophthalmologica* 2011;225:67-75.
- Glaser BM. Treatment of giant retinal tears combined with proliferative vitreoretinopathy. *Ophthalmology* 1986;93:1193-1197.
- Kunikata H. Management of giant retinal tears using microincision vitrectomy surgery. *Dev Ophthalmol* 2014;54:182-187.
- Ang GS, Townend J, Lois N. Interventions for prevention of giant retinal tear in the fellow eye. *Cochrane Database Syst Rev* 2012;2:CD006909.
- Retinal Detachment. Retina Consultants. Available from: http://www.retinaconsultants.com.au/main/page_common_conditions_retinal_detachment.php. Published 2011 [Last accessed on June 21, 2016].
- Sharma A, Grigoropoulos V, Williamson TH. Management of primary rhegmatogenous retinal detachment with inferior breaks. *Br J Ophthalmol* 2004;88:1372-1375.
- Kazahava M. Prophylaxis of retinal detachment. *Semin Ophthalmol* 1995;10:79-86.
- Mastropasqua L, Carpineto P, Ciancaglini M, Falconio G, Gallenga PE. Treatment of retinal tears and lattice degenerations in fellow eyes in high risk patients suffering retinal detachment: A prospective study. *Br J Ophthalmol* 1999;83:1046-1049.
- Gonzalez MA, Flynn HW Jr, Smiddy WE, Albin TA, Tenzel P. Surgery for retinal detachment in patients with giant retinal tear: Etiologies, management strategies, and outcomes. *Ophthalmic Surg Lasers Imaging Retina* 2013;44:232-237.
- Leaver PK, Billington BM. Vitrectomy and fluid/silicone-oil exchange for giant retinal tears: 5 years follow-up. *Graefes Arch Clin Exp Ophthalmol* 1989;227:323-327.