

Distal Medullary Canal Decompression in Long Stem Hip Replacement in Long Bone Metastasis

Does it Reduce Cardiopulmonary Complications?

Abstract

Background: The femur is the most common long bone affected by metastatic bone disease, with 25% involving the proximal third of the femur. Long stem cemented hip replacement (LHR) is an important option for cases of impending fracture. Pulmonary embolism is a critical complication that can occur. This study evaluates the effectiveness of distal femoral canal decompression in reducing the risk of cardiopulmonary events. **Materials and Methods:** Thirty two patients with metastatic bone disease of the proximal femur undergoing LHR were recruited and randomized. Conventional technique was used in 16 cases and distal decompression of the medullary canal was carried out for the other 16 patients. The decompression was carried out through a trocar inserted into the distal medullary canal, connected to a vacuum suction. Quantity of emboli was detected through A4 chambers transesophageal echocardiography; the blood pressure and oxygen saturation readings were also recorded. **Results:** The decompression group experienced significantly lower Grade 2 and Grade 3 embolic events compared to the conventional group (11 vs. 26), and the duration of the embolic phenomena was shorter. Insertion of the stem and relocating the hip gave the highest amount embolic events. There was a significant drop in systolic blood pressure (SBP) in 12 out of 16 patients (75.0%) in the conventional group and 5 out of 16 patients in the decompression group (31.3%). This is statically significant ($P = 0.0124$). The average drop in SBP for the conventional group is 45.8 mmHg and the decompression group was 32.9 mmHg. Oxygen saturation remained at above 96% in the decompression group. However, in the conventional group, 25% of the patients had their oxygen saturation drop to below 96% during the insertion of stem and relocation of hip joint. **Conclusion:** Distal femoral canal decompression is an effective method in reducing the risk of cardiopulmonary embolic events associated with LHR.

Keywords: Bone metastasis, distal canal decompression, pulmonary embolism, long stem hip replacement

MeSH terms: Metastasis, hip prosthesis, pulmonary embolism, hip joint arthroplasty

**Vivek Ajit Singh,
Siamak Sarrafan,
Ramesh Singh
Veriah¹**

Departments of Orthopaedics (Noceral) and ¹Cardiology, University Malaya Medical Center, Kuala Lumpur, Malaysia

Introduction

Metastatic bone disease affects >1.2 million new patients diagnosed annually with cancer, and >50% will eventually demonstrate skeletal metastasis.¹ After the lungs and liver, the skeleton is the most common site of metastatic disease.^{2,3} Metastatic bone disease is a major contributor to the deterioration of the quality of life of patients with cancer, as it causes pain and pathological fractures, which leads to the loss of function and may also be associated with considerable metabolic alterations.⁴

Femur is the most common long bone affected by metastatic bone disease, with 25% of the cases involving the proximal third of the femur. Femoral bone metastasis are most frequently located in the cancellous bone of the

proximal femur, an area subjected to high biomechanical loads, resulting in frequent pathologic fracture through this region.⁵ The authors prefer the use of a cemented long stem hip replacement as a surgical option for the management of impending fractures and pathological fractures for cases involving the femoral head, neck, and intertrochanteric area. This provides immediate stability and a durable construct that allows early weight bearing and return to function. This in return has a significant impact on the quality of patients' life.⁶

A lethal complication of this technique is the development of cardiopulmonary embolism.⁷ This is due to the passage of normal marrow contents or tumor into the pulmonary circulation, resulting in various biochemical, hemodynamic, or physical responses, which lead to hypotension,

Address for correspondence:
Prof. Vivek Ajit Singh,
Department of Orthopaedics (Noceral), University Malaya Medical Center, Kuala Lumpur, Malaysia.
E-mail: drvivek69@gmail.com

Access this article online

Website: www.ijonline.com

DOI:
10.4103/ortho.IJOrtho_101_17

Quick Response Code:



How to cite this article: Singh VA, Sarrafan S, Veriah RS. Distal medullary canal decompression in long stem hip replacement in long bone metastasis: Does it reduce cardiopulmonary complications?. Indian J Orthop 2018;52:15-21.

This is an open access article distributed under the terms of the Creative Commons Attribution-NonCommercial-ShareAlike 3.0 License, which allows others to remix, tweak, and build upon the work non-commercially, as long as the author is credited and the new creations are licensed under the identical terms.

For reprints contact: reprints@medknow.com

arrhythmia, and O₂ desaturation. Cemented femoral components are commonly used to provide structural support to the weakened bone, and it contributes to a decreased implant failure rate.⁸ For these cases, a long stem femoral component is commonly used to cover the entire length of the femur.

However, cemented femoral arthroplasty is also known to cause perioperative cardiopulmonary complications.⁷ Cement-associated desaturation and hypotension, pulmonary hypertension, cardiogenic shock, cardiac arrest, and intraoperative death are complications that can occur during reaming, femoral cementation, and component placement secondary to canal pressurization.⁹

There have been studies on various methods used to reduce the cardiopulmonary complications such as low-viscosity cement, proximal intramedullary venting, retrograde injection, thorough intramedullary lavage, and intraoperative canal suctioning during cementing.¹⁰ So far, there have been encouraging results from proximal decompressing and distal decompression during a standard total hip replacement.¹¹ However, there is no published literature on distal decompression in long stem total hip replacement in patients with metastatic long bone disease. This is a study to determine the quantum of emboli produced, the procedure during the surgery during which the emboli are produced and the advantages of distal canal decompression in cases of long stem total hip replacement. We hypothesize that distal decompression of the femoral canal will significantly reduce the incidence of cardiopulmonary complications.

Materials and Methods

This prospective study was conducted at our center from January 1, 2011, to December 31, 2011. All the patients with proximal femur bone metastasis scheduled for a long stem total hip replacement or a long stem bipolar replacement were recruited in the study. The length of femoral stems ranged from 250 to 300 mm. Patients with preexisting deep vein thrombosis or history of pulmonary embolism were excluded from the study. Ethical Committee approval was obtained for this study (MEC: 727.67).

The patients were randomized into two groups by drawing lots. In Group A, long stem hip arthroplasty was performed using the conventional method ($n = 16$; 11 total hip replacements and 5 bipolar hemiarthroplasties). In Group B, long stem hip arthroplasty was done using decompression through a trocar that is inserted into the distal part of the femoral canal (lateral femoral condyle) ($n = 16$; 11 total hip replacements and 5 bipolar hemiarthroplasties). The trocar is connected to a suction applying 60 kPa continuous negative pressure throughout the surgery to reduce intramedullary pressure. The cement used was low viscosity cement and the cement was injected into the liquid form without compression. No cement restrictor was

used. For all the cases of long stem total hip replacement, flanged cemented cups were used.

In both groups of patients, the duration and size of embolisms passing through heart were measured using transesophageal four-chamber echocardiography by a consultant cardiologist during each step of the operation. The transesophageal echo is proven more reliable compared to transthoracic echo.¹² It was conducted by the same cardiologist to minimize the intraobserver error. The observations were confirmed by two other independent observers present during the surgery to minimize intraobserver variations.

The surgery was divided into four major phases: 1 - reaming of the acetabulum, 2 - cementation of the cup, 3 - reaming of the femoral canal, and 4 - cementation of femoral canal, insertion of the stem and relocation of the hip joint. The embolic events were correlated to each of these operation steps.

All patients received general anesthesia. No thromboembolic chemoprophylaxis was given to all patients, but all patients were given a mechanical form of deep vein thrombosis prophylaxis (graded compressive stockings) in the postoperative period, following our standard protocol. Intraarterial blood pressure, pulse rate, and oxygen saturation were monitored during the surgery to assess hemodynamic status of the patients during the embolic events. These readings were monitored every 5 min and during each stage of the procedure. Echocardiography was performed before and after operation to evaluate significant sequelae of embolic events to the cardiac function of the patient.

Intraoperatively, patients were placed on lateral position, and anterior lateral approach to the hip was used for all surgeries. A minimum of 250 mm femoral stem (Omnifit® Cemented Long Stem) of the smallest femoral stem was inserted in all patients. The same surgeon carried out all the surgeries. Transesophageal echocardiography was performed for all patients by a single consultant cardiologist. A grading system by Koessler and Pitto was used to categorize the severity of embolic events. The grading is as follows: Grade 0 is when there are no emboli or small echogenic particles, Grade 1 is when “a few fine emboli,” Grade 2 is when a cascade of fine emboli or embolic masses <5 mm in diameter and the right atrium is pacified with echogenic material, and Grade 3 is when there are a large embolic masses >5 mm in diameter or serpentine emboli present.¹³

Results

We had a total of 32 patients during the study period. There were 16 patients in the decompression group and 16 patients in the conventional group. Majority of our patients were females (female = 28 and male = 4). The average age was 55 years (range 37-74 years) [Figure 1]. In most of

the cases, the primary malignancy was breast carcinoma, followed by lung and colon carcinoma [Figure 2].

Intraoperatively, transesophageal echocardiogram showed a variable amount of embolism passing through the heart in all the operated cases. However, the volume and size of the emboli differed between patients in both groups. Table 1 illustrates the grades of the emboli during the different stages of the surgery in both groups.

We also noticed that all cases that experienced the Grade 2 embolism had the Grade 1 embolism during some parts of the surgery and all patients with Grade 3 embolism also experienced some degree of Grade 1 and 2 embolism.

Embolism phenomena

Step 1 and 2: Reaming of the acetabulum and insertion of the cup

During reaming of the acetabulum and insertion of the cup, embolic events could be seen in 86% of cases (19 out of 22 patients) in both groups. However, the severity of it never exceeded Grade 2. There was no significant difference between conventional and decompression groups in terms of the total number of cases who developed embolism and the severity of the embolic phenomena during this phase of surgery.

Step 3: Reaming of the femoral canal

Although the number of cases with Grade 1 embolism does not reveal any statistical difference between the

two surgical methods, there is a significant reduction in Grade 2 ($P < 0.005$) and Grade 3 ($P < 0.01$) embolic events in patients who were operated with vacuum decompression technique, during the femoral reaming procedure. Furthermore, in those patients who developed embolism, the average duration of embolic events was shorter in decompression group. This reduction was about 24%, 34%, and 40% for Grade 1, 2, and 3, respectively [Figure 3]. Hence, the vacuum technique not only reduced the prevalence but also duration of embolic events.

Step 4: Cementation, insertion of the stem, and relocation of the hip joint

The highest incidence of embolic events was noticed during this stage of operation. All patients in both operative groups developed variable grades of embolism during this step of operation. In addition, the mean duration of the embolic events was the highest compared with all the other steps of surgery. However, the decompression group had milder and shorter duration of embolic events. The study demonstrates a significant decrease in the prevalence of Grade 2 ($P < 0.05$) and Grade 3 ($P < 0.001$) embolic events after using the vacuum technique. Furthermore, among these patients, the average duration of embolic events was much less in decompression group. This reduction in time recorded was about 39%, 55%, and 40% for Grade 1, 2, and 3, respectively.

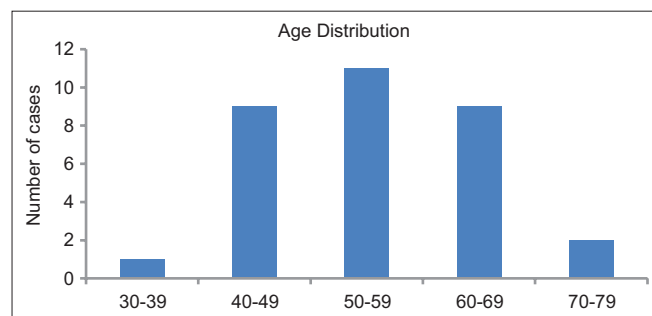


Figure 1: A bar diagram showing the age distributions of the study population

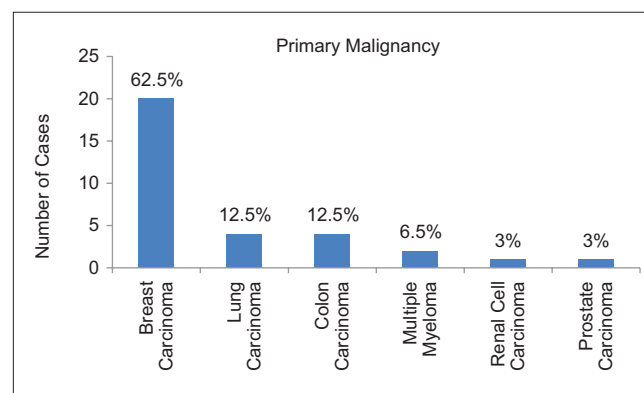


Figure 2: A bar diagram showing the distribution of primary cancers

Table 1: Number of patients who had different grades of embolism during each step of operation in both techniques

Operation steps	Number of patients that embolic events observed in them					
	Grade 1		Grade 2		Grade 3	
	Conventional	Decompression	Conventional	Decompression	Conventional	Decompression
Reaming of the acetabulum ($n=11$)*	9	10	1	1	0	0
Insertion of the cup ($n=11$)*	10	9	2	3	0	0
Reaming of the femoral canal ($n=16$)	16	14	14	6	9	2
Insertion of the stem and relocating the hip ($n=16$)	16	16	14	9	12	2

*10 out of 32 patients underwent bipolar hemiarthroplasty (5 patients from each group). Hence, no procedure was performed on acetabulum

Blood pressure

For this purpose of this study, a blood pressure drop of >40 mmHg was taken as a significant. The blood pressure dropped in almost all patients in both operative groups, most evident after insertion of the stem. There was a significant drop in systolic blood pressure (SBP) in 12 out of 16 patients (75.0%) in the conventional group and 5 out of 16 patients in the decompression group (31.3%). This is statistically significant ($P = 0.0124$). The average drop in SBP in the conventional group is 45.8 mmHg and in the decompression group is 32.9 mmHg [Figure 4].

Oxygen saturation

In the decompression group, oxygen saturation remained above 96%. However, in the conventional group, 4 out of 16 patients had an oxygen saturation dropped below 96% [Table 2]. All of them occurred once and within Step 4 of operation (insertion of stem and relocation of hip joint).

Other observations

There were no cases of implant failures in this series. During the period of the study, one of our patients from the conventional group collapsed in the recovery room a few minutes after the surgical procedure (long stem bipolar hemiarthroplasty). He was a 79-year-old gentleman, a case of carcinoma of the colon with metastasis to proximal femur. Intraoperatively, his vital signs were stable. The patient responded to cardiopulmonary resuscitation and was admitted to Intensive Care Unit for 2 days then transferred back to normal ward and discharged well after that. No obvious permanent sequelae were recognized after recovery. We are unsure about the probable cause of the collapse, but it is postulated that it might be a delayed response to the cementation.

In another incident, a 67 year old female with breast cancer undergoing long stem hemiarthroplasty in the conventional group and had a significant Grade 3 embolus that was trapped in her right ventricle. The cardiologist was able to detect the embolus and inform the anesthetic

team of the potential risks. Fortunately, long stem bipolar hemiarthroplasty was performed successfully, and the vital signs remain stable throughout the surgery. Two days after the surgery, an echocardiogram was repeated, and the emboli had resolved. The patient was discharged home with no cardiopulmonary complication.

Discussion

Long stem bipolar hemiarthroplasty and long stem total hip replacements are frequently carried out for metastatic disease of the proximal femur as it is the most common site in the long bone involved in bone metastasis.¹⁴ Majority of these cases require surgical management^{8,15} as they are less likely to unite.¹⁶

Due to the above mentioned reasons, long stem hip arthroplasty is the preferred choice by the author for fixation of metastatic lesions of proximal femur. The main advantage of these prostheses is that they can be effectively used in the presence of bone loss secondary to the diseased providing there is adequate stable fixation of the stem distally. Fixation of the prosthesis with cement allows immediate full weight bearing and early return to function. The implant survival of these long stem prostheses is excellent over the shortened lifespan of these patients.¹⁷

However, long stem hip arthroplasty is complicated compared to the standard hip replacement. The femoral canal usually needs to be reamed throughout its entire length, and bone cement is usually fill in the entire length of the canal. This increases the risk of fat, marrow, tumor cells, and the cement monomer embolism into the circulation. Furthermore, the tumor itself may give rise to bleeding complications

Table 2: The oxygen concentration for four patients in conventional group who dropped below 96%

Patient	The lowest oxygen saturation (%)	Duration oxygen saturation dropped (s)
1	84	15
2	80	10
3	80	24
4	76	25

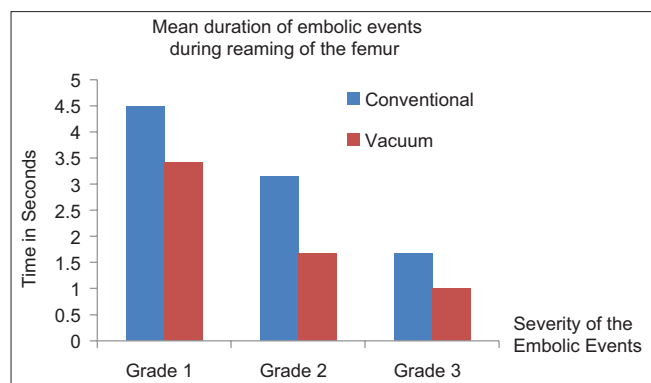


Figure 3: A bar diagram showing comparison between conventional and vacuum technique during reaming of femur. *Note: Only patients with positive embolic findings are compared

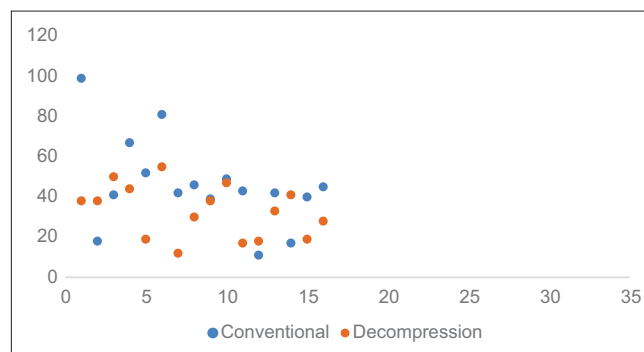


Figure 4: A scattered plot showing the drop in systolic blood pressure for both study groups

due to alteration of the coagulation system.¹⁸⁻²² These characteristics make the surgery of long stem arthroplasty risky, mainly because of the high chance of embolism and cardiopulmonary complications.²³⁻²⁶ As the severity of the cardiopulmonary complications and the related operative risks are directly related to the amount of embolization, reducing the quantity of embolism should decrease morbidity and mortality associated with this procedure.^{10,27-30}

These patients may not have the ability to compensate for the hemodynamic compromise due to the diminished cardiopulmonary reserves.³¹ Therefore, they are more susceptible to the intraoperative and postoperative complications.

Our study demonstrated that all patients who underwent long stem hip arthroplasty experienced variable amounts of cardiopulmonary events. We observed embolic phenomena even during both reaming and cementing of the acetabulum in majority of cases (86%). However, the severity was not significant enough to cause any major hemodynamic complications. There were no reported cases with Grade 3 emboli and only 9% of the patients experienced Grade 2 embolic phenomena during this stage. A comparison between the both steps of the preparation of the acetabulum showed that the number of cases developing Grade 2 emboli was two-fold higher during insertion of the cemented cup as compared to the reaming of the acetabulum (23% vs. 9%). This is probably due to the fact that there is a significant increase in the cement pressure and penetration within the cancellous bone of the acetabulum with the use of pressured flanged cup.³²⁻³⁴ We also observed that the mean duration of the embolic phenomena was longer during insertion of the cup compared to reaming of the acetabulum.

Most of cardiopulmonary events and generation of the bigger size emboli occurred during Step 3 and 4 of the operation. These steps include the preparation of the medullary canal (reaming of the femur) and insertion of cement and the femoral stem.

During reaming of the medullary canal of the femur (Stage 3 of the operation), all the patients (100%) in the conventional group developed some degrees of embolism, whereas only 88% in the decompression group had embolic phenomena. We found that not only the prevalence of the embolic phenomena was less but also the duration of the emboli detected within the heart was also significantly shorter in the decompression group. This difference is more evident for Grade 2 and Grade 3 emboli.

The 4th stage of the operation (insertion of the bone cement followed by the prosthesis stem and relocation of the hip joint) had the highest number of embolic events. At this stage, all patients of both groups experienced a variable degree of embolism and those in the decompression group had significantly lower incidence of embolism compared to the conventional group. Both the size and the duration of

emboli were about 50% less compared to the conventional group. This reduction was noticed in all grades of the emboli (Grade 1, 2, and 3).

We also noticed that all significant hemodynamic complications occurred during the 4th stage of the operation and among patients who were operated using the conventional technique. Four cases had sudden drop in oxygen saturation and one patient collapsed just after the surgery. Another had a significantly sized embolus was trapped in the right ventricle causing potential risk of extensive pulmonary embolism; fortunately, it resolved eventually.

According to the European Society of Cardiology, the presence of hemodynamic instability is defined as a drop of more than 40 mmHg of SBP and is a clinical marker of high-risk patients.³⁵ In our study, majority of the patients experienced some degrees of SBP dropped after insertion of the stem at the 4th stage of the operation, but the number of cases with reduction of more than 40 mmHg in SBP was higher in those patients who were operated with the conventional technique.

Both desaturation and hypotension were noted at Phase 4 of the surgery. This is the stage where bone cement was injected into the medullary canal. Bone cement may contribute in systemic hypotension by increasing intramedullary pressure causing embolization of fat, marrow, and cement implantation syndrome. Thus, decompressing the femoral canal reduces the canal pressure and that in return can reduce cement, fat, and bone marrow embolism. In this study, we used transesophageal echocardiography, and this is not effective in differentiating fat or bone marrow from cement particles.

To the best of our knowledge, we were not able to find any similar study in the published literature comparing distal canal decompression in long stem arthroplasty with conventional long stem hip replacement. However, similar studies on decompression of the canal either proximally or at the linea aspera of the femur or distally in a standard femoral arthroplasty does demonstrate significant reduction in size and quantity of the emboli.¹³

The limitations of this study are that we were unable to measure the exact canal pressure during cementation in both techniques to demonstrate objectively the lower canal pressure during cementation in the decompression technique. The other limitation is that the canal pressure depends on the consistency of the cement when it is injected into that canal. In all cases, we try to inject the cement in when it is still in the liquid state to minimize the increase in pressure, but it is difficult to standardize this.

In summary, embolic phenomena occur during all stages of the long stem hip arthroplasty in the majority of the patients. However, the quantity and duration of this phenomenon is highest during injection of the bone cement,

insertion of the stem, and reduction of the hip joint, followed by reaming of the medullary canal. Therefore, all patients must be optimized before surgery. This is carried out by optimizing the oxygen-carrying capacity by assuring adequate respiratory reserves and hemoglobin level is an acceptable level. The patient also needs to be adequately hydrated before surgery. This is to avoid unnecessary morbidity and mortality, and precautions such as warning the anesthetist early before reaming the femoral canal are essential so that they can be prepared for the potential circulatory collapse.

An intraoperative transesophageal echocardiography is a useful tool, used to monitor circulating emboli during the operative procedure.

Distal decompression of the medullary canal (“vacuum technique”) can significantly decrease both the quantity and duration of the emboli and therefore can effectively reduce the risk of hemodynamic instability and pulmonary embolism in patients undergoing a long stem hip arthroplasty.

Conclusion

Distal decompression of the femoral canal has been shown to be an effective method of reducing perioperative and postoperative cardiopulmonary events during long stem hip arthroplasty in metastatic bone disease.

Declaration of patient consent

The authors certify that they have obtained all appropriate patient consent forms. In the form, the patient(s) has/have given his/her/their consent for his/her/their images and other clinical information to be reported in the journal. The patients understand that their names and initials will not be published and due efforts will be made to conceal their identity, but anonymity cannot be guaranteed.

Financial support and sponsorship

Nil.

Conflicts of interest

There are no conflicts of interest.

References

- Swanson KC, Pritchard DJ, Sim FH. Surgical treatment of metastatic disease of the femur. *J Am Acad Orthop Surg* 2000;8:56-65.
- Manoso MW, Healey JH. Metastatic cancer to the bone. *Principles and Practice of Oncology*. 7th ed. Philadelphia: Lippincott Williams and Wilkins; 2005. p. 2368-80.
- Dorfman HD. *Metastatic Tumors in Bone – Bone Tumors*. St. Louis: Mosby; 1998. p. 1009-40.
- Bickels J, Dadia S, Lidar Z. Surgical management of metastatic bone disease. *J Bone Joint Surg Am* 2009;91:1503-16.
- Roodman GD. Mechanisms of bone metastasis. *N Engl J Med* 2004;350:1655-64.
- Chow E, Hoskin P, van der Linden Y, Bottomley A, Velikova G. Quality of life and symptom end points in palliative bone metastases trials. *Clin Oncol (R Coll Radiol)* 2006;18:67-9.
- Patterson BM, Healey JH, Cornell CN, Sharrock NE. Cardiac arrest during hip arthroplasty with a cemented long-stem component. A report of seven cases. *J Bone Joint Surg Am* 1991;73:271-7.
- Hattori H, Mibe J, Matsuoka H, Nagai S, Yamamoto K. Surgical management of metastatic disease of the proximal femur. *J Orthop Surg (Hong Kong)* 2007;15:295-8.
- Winkler M, Marker E, Hetz H. The peri-operative management of major orthopaedic procedures. *Anaesthesia* 1998;53:37-41.
- Choong PF. Cardiopulmonary Complications of intramedullary fixation of long bone metastases. *Clin Orthop Relat Res* 2003;415:245-53.
- Pitto RP, Koessler M, Kuehle JW. Comparison of fixation of the femoral component without cement and fixation with use of a bone-vacuum cementing technique for the prevention of fat embolism during total hip arthroplasty. A prospective, randomized clinical trial. *J Bone Joint Surg Am* 1999;81:831-43.
- Pearson AC, Labovitz AJ, Tatineni S, Gomez CR. Superiority of transesophageal echocardiography in detecting cardiac source of embolism in patients with cerebral ischemia of uncertain etiology. *J Am Coll Cardiol* 1991;17:66-72.
- Koessler MJ, Pitto RP. Fat and bone marrow embolism in total hip arthroplasty. *Acta Orthop Belg* 2001;67:97-109.
- Ashford RU, Pendlebury S, Stalley PD. Management of metastatic disease of the appendicular skeleton. *Orthop Trauma* 2006;20:299-315.
- Mirels H. Metastatic disease in long bones. A proposed scoring system for diagnosing impending pathologic fractures. *Clin Orthop Relat Res* 1989;249:256-64.
- Gainor BJ, Buchert P. Fracture healing in metastatic bone disease. *Clin Orthop Relat Res* 1983;178:297-302.
- Damron TA, Sim FH. Operative treatment for metastatic disease of the pelvis and proximal end of the femur. *J Bone Joint Surg* 2000;82:113-26.
- Goad KE, Gralnick HR. Coagulation disorders in cancer. *Hematol Oncol Clin North Am* 1996;10:457-84.
- Bick RL. Coagulation abnormalities in malignancy: A review. *Semin Thromb Hemost* 1992;18:353-72.
- Green KB, Silverstein RL. Hypercoagulability in cancer. *Hematol Oncol Clin North Am* 1996;10:499-530.
- DeLoughery TG. Management of acquired bleeding problems in cancer patients. *Emerg Med Clin North Am* 2009;27:423-44.
- Letai A, Kuter DJ. Cancer, coagulation, and anticoagulation. *Oncologist* 1999;4:443-9.
- Enneking FK. Cardiac arrest during total knee replacement using a long-stem prosthesis. *J Clin Anesth* 1995;7:253-63.
- Fitzgerald R, Mason L, Kanumilli V, Kleinhomer K, Sakamoto A, Johnson C, *et al.* Transient cardiac standstill associated with embolic phenomena diagnosed by intraoperative transesophageal echocardiography during cemented total hip arthroplasty. *Anesth Analg* 1994;79:382-5.
- Kerr PS, Jackson M, Atkins RM. Cardiac arrest during intramedullary nailing for femoral metastases. *J Bone Joint Surg Br* 1993;75:972-3.
- Lewis RN. Respiratory complications of bone cement insertion during total hip replacement under spinal anaesthesia. *Eur J Anaesthesiol* 1997;14:52-4.
- Parvizi J, Holiday AD, Ereth MH, Lewallen DG. The frank stinchfield award. Sudden death during primary hip arthroplasty. *Clin Orthop Relat Res* 1999;369:39-48.
- Byrick RJ, Mullen JB, Mazer CD, Guest CB. Transpulmonary

- systemic fat embolism. Studies in mongrel dogs after cemented arthroplasty. *Am J Respir Crit Care Med* 1994;150:1416-22.
29. Edmonds CR, Barbut D, Hager D, Sharrock NE. Intraoperative cerebral arterial embolization during total hip arthroplasty. *Anesthesiology* 2000;93:315-8.
 30. Pell AC, Hughes D, Keating J, Christie J, Busuttill A, Sutherland GR, *et al.* Brief report: Fulminating fat embolism syndrome caused by paradoxical embolism through a patent foramen ovale. *N Engl J Med* 1993;329:926-9.
 31. Peng X, Pentassuglia L, Sawyer DB. Emerging anticancer therapeutic targets and the cardiovascular system: Is there cause for concern? *Circ Res* 2010;106:1022-34.
 32. Panjabi MM, Goel VK, Drinker H, Wong J, Kamire G, Walter SD, *et al.* Effect of pressurization on methylmethacrylate-bone interdigitation: An *in vitro* study of canine femora. *J Biomech* 1983;16:473-80.
 33. Juliusson R, Arve J, Ryd L. Cementation pressure in arthroplasty. *In vitro* study of cement penetration into femoral heads. *Acta Orthop Scand* 1994;65:131-4.
 34. Smith BN, Lee AJ, Timperley AJ, Whitehouse SL, Crawford RW. The effect of the rim cutter on cement pressurization and penetration on cemented acetabular fixation in total hip arthroplasty: An *in vitro* study. *Proc Inst Mech Eng H* 2010;224:1133-40.
 35. Coutance G, Cauderlier E, Ehtisham J, Hamon M, Hamon M. The prognostic value of markers of right ventricular dysfunction in pulmonary embolism: A meta-analysis. *Crit Care* 2011;15:R103.

Planned forthcoming symposia in IJO

IJO has planned symposia on following topics in forthcoming issues:

- **Hind Foot Trauma**
- **Pediatric Trauma**