

Kyphoplasty in the treatment of occult and non-occult metastatic vertebral tumors

Shuangjun He, MD^{a,b}, Zhangzhe Zhou, MD^b, Changhao Zhang, MD^b, Nanning Lv, MD^c, Zhonglai Qian, MD^{b,*}, Zhiyong Sun, MD^{b,*}

Abstract

To compare the efficacy and safety of kyphoplasty (KP) in the treatment of occult metastatic vertebral tumors (OMVT) and non-occult metastatic vertebral tumors (MVT).

From January 2013 to December 2017, 65 cases of occult metastatic vertebral tumors and 82 cases of metastatic vertebral tumors were selected and divided into 2 groups. After KP, they were followed up by a year of outpatient visits and telephone calls. The visual analogue scale (VAS) and Oswestry disability index (ODI) scores, the amount of bone cement injected, the change of vertebral height and the incidence of complications were recorded, compared and analyzed by SPSS software. *t* test was used to compare the differences between the same group of patients at different times and between the 2 groups of patients.

In the OMVT group, the operation time was 24.52 ± 4.24 minutes, the fluoroscopy time was 10.18 ± 1.53 minutes and the volume of bone cement was 3.62 ± 0.93 ml. The VAS score decreased from 7.26 ± 0.108 preoperatively to 2.77 ± 0.93 postoperatively (*P* < .01). The ODI score decreased from 64.89 ± 9.05 preoperatively to 25.82 ± 4.63 postoperatively (*P* < .01). In the MVT group, the operation time was 26.63 ± 4.61 minutes, the fluoroscopy time was 11.04 ± 2.15 minutes and the volume of bone cement was 4.09 ± 1.10 ml. The VAS score decreased from 7.73 ± 0.94 preoperatively to 3.22 ± 0.80 postoperatively (*P* < .01). The ODI score decreased from 69.20 ± 7.14 preoperatively to 28.02 ± 4.40 postoperatively (*P* < .01). The vertebral height of MVT patients was significantly improved after operation (*P* < .01), but there was no difference in OMVT patients (*P* > .05).

Occult metastatic vertebral tumors can be detected by Magnetic Resonance Imaging (MRI), and KP may be more effective and safer in the treatment of OMVT.

Abbreviations: KP = kyphoplasty, MRI = Magnetic Resonance Imaging, MVT = non-occult metastatic vertebral tumor, ODI = Oswestry disability index, OMVT = occult metastatic vertebral tumor, VAS = visual analogue scale.

Keywords: efficacy, kyphoplasty, metastatic vertebral tumor, occult, safety

Editor: Jimmy T. Efird.

SH, ZZ, CZ, and NL contributed equally to this work

The data used to support the findings of this study are available from the author upon request.

No funds were received in support of this work.

No benefits in any form have been or will be received from a commercial party related directly or indirectly to the subject of this manuscript.

All data generated or analyzed during this study are included in this published article [and its supplementary information files].

Supplemental Digital Content is available for this article.

The author(s) of this work have no conflicts of interest to disclose.

^a Department of Orthopedic Surgery, The People's Hospital of Danyang, Affiliated Danyang Hospital of Nantong University, Danyang, Jiangsu Province,

^b Department of Orthopedic Surgery, The First Affiliated Hospital of Soochow University, Suzhou, ^c Department of Orthopedic Surgery, The Second People's Hospital of Lianyungang, Lianyungang, China.

* Correspondence: Zhiyong Sun, Zhonglai Qian, Department of Orthopedic Surgery, The First Affiliated Hospital of Soochow University, 188 Shizi Street, Suzhou, Jiangsu 215006, China (e-mail: sunzhiyongsuzhou@163.com, qzldoctor@163.com).

Copyright © 2020 the Author(s). Published by Wolters Kluwer Health, Inc. This is an open access article distributed under the terms of the Creative Commons Attribution-Non Commercial License 4.0 (CCBY-NC), where it is permissible to download, share, remix, transform, and buildup the work provided it is properly cited. The work cannot be used commercially without permission from the journal.

How to cite this article: He S, Zhou Z, Zhang C, Lv N, Qian Z, Sun Z. Kyphoplasty in the treatment of occult and non-occult metastatic vertebral tumors. *Medicine* 2020;99:25(e20430).

Received: 10 April 2019 / Received in final form: 2 April 2020 / Accepted: 26 April 2020

<http://dx.doi.org/10.1097/MD.00000000000020430>

1. Introduction

With the advancement of medical technology, the survival time of cancer patients is prolonged, and the number of advanced cancer patients with primary tumors metastasis to the spine is also increasing.^[1] Hu et al describe the epidemiological characteristics of patients with spinal metastases in China between 2007 and 2019. The spine is a common site of tumor metastasis, accounting for about 50% of bone metastases, and 40% to 70% of patients with advanced tumors eventually metastasize to the spine, which show that it is necessary for society and people to actively treat tumors.^[2] 80% of spinal metastases involve the vertebral body and the incidence of thoracic vertebrae is the highest, followed by lumbar vertebrae and cervical vertebrae.^[3,4] Tumor transferred to the spine can cause severe pain, vertebral fracture and spinal cord compression.^[5]

Previous studies have shown that at least a quarter of patients who die of cancer suffer from occult spinal diseases.^[6] X-ray is usually the first method of imaging examination for patients with spinal diseases. The destruction and collapse of the vertebral body invaded by the tumors can be observed by X-ray examination.^[7] However, when there is no obvious bone destruction, deformation and collapse in the early stage of metastatic vertebral body, X-ray examination is meaningless.^[8] Magnetic Resonance Imaging (MRI) has high sensitivity and specificity in the diagnosis of metastatic vertebral tumors, and usually shows low signal in T1 sequence and high signal in T2 sequence.^[9,10]

Kyphoplasty (KP) is commonly used in the palliative treatment of metastatic vertebral tumors and needs to restore vertebral

height through an inflatable balloon and reduce the pressure of cement injection and the risk of leakage.^[11,12] From the perspective of elderly patients in the United States, KP are cost-effective compared with non-surgical treatment, even for the oldest patients.^[13] There is little discussion on the treatment of occult metastatic vertebral tumor (OMVT) in clinic, because OMVT patients are not easily detected in time. Therefore, we evaluated the safety and efficacy of KP in the treatment of OMVT and MVT respectively to determine whether it is safer and more effective to detect OMVT patients through MRI in time and treat them with KP.

2. Material and methods

2.1. Patients

This study was approved by the Ethics Committee of the First Affiliated Hospital of Suzhou University. From January 2013 to December 2017, patients with metastatic vertebral tumors in our hospital were screened. Most patients suffer from severe low back pain.

Inclusion criteria-All cases met the following criteria:^[14]

Metastatic vertebral tumors, diagnosed by a multidisciplinary team, which included an experienced radiologist, orthopedic surgeon and oncologist; the ability to maintain prone position for at least 2 hours; a Karnofsky performance score >60; according to the evaluation of oncologists, the expected survival time was longer than 1 year, less than or equal to 2 cases of metastasis, no other serious diseases were found. All follow-up patients were transferred to the oncology department for anti-cancer treatment after KP.

Exclusion criteria-Only one of the following criteria needed to be satisfied: Infections, psychiatric disorders, coagulation disorders, and other systemic diseases; spinal cord compression.

2.2. Surgical operation

The whole operation was performed by the professional spine surgeons. The patients under anesthesia lay prone on the operating table. Pedicle puncture guided by C-arm fluoroscopy. When the puncture needle entered the internal edge of pedicle under frontal fluoroscopy and the puncture needle entered the posterior edge of vertebral body under lateral fluoroscopy, the process indicated that the puncture was successful. After successful puncture, the core of the needle was pulled out. Then the cannula was fixed and used as the working channel, and the pneumatic balloon was inserted. Finally, the bone cement was injected slowly. The operation time, fluoroscopy time and the amount of cement injection were recorded during the operation. After completion of the KP, the patients were monitored for 8 hours postoperatively.

2.3. Clinical evaluation

The anterior and middle vertebral height were measured by X-ray lateral films from case data and outpatient reexamination preoperatively, 3 days and 1 year after operation. All patients were surveyed by questionnaires in hospitals or telephone interviews. Visual analogue scale (VAS) was used to evaluate the degree of back pain. The pain increased with the increase of the numerical value through the horizontal line from 0 to 10. Oswestry disability index (ODI) score was used to assess patients' quality of life from different aspects. The higher the score, the more severe the dysfunction.^[11]

2.4. Complication

Postoperative complications such as fever, infection, pulmonary embolism and death were recorded, and cement leakage rate was evaluated by X-ray examination.

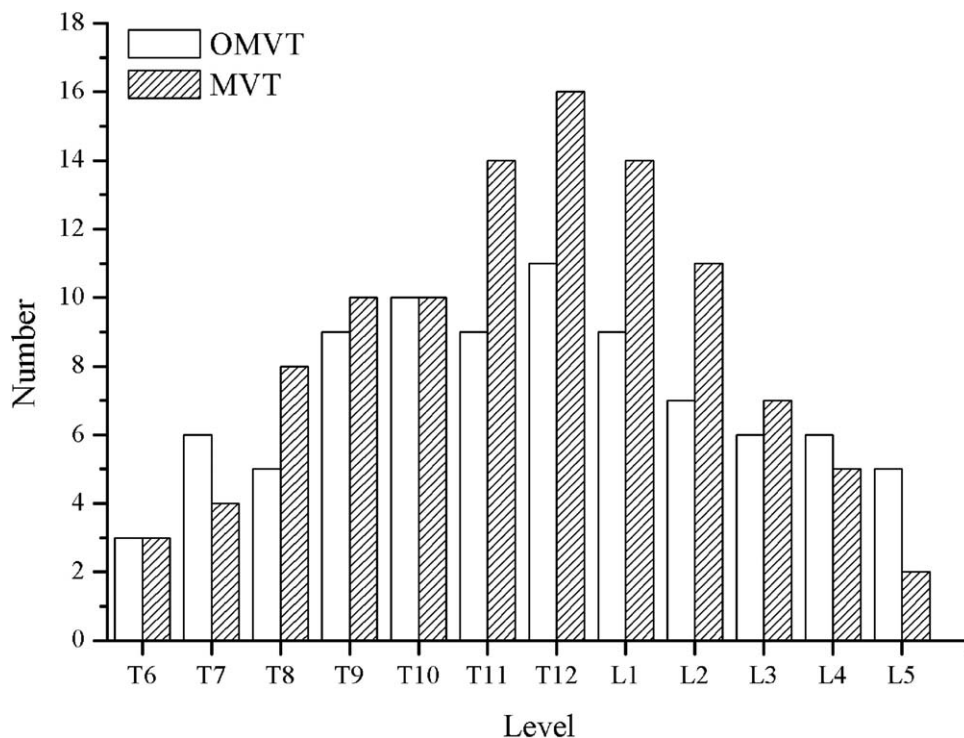


Figure 1. Location of occult metastatic vertebral tumors (n=86) and metastatic vertebral tumors (n=104).

Table 1		
The general characteristics.		
Characteristics	OMVT	MVT
Patient		
Number	65	82
Total number of OMVTs	86	104
Age (years)	70.65±10.07	69.58±9.12
Gender (F/M)	43/22	53/29
Follow-up (months)	12	12
Fracture region (number/percentage)		
T6 through T12 vertebrae	53	65
L1 through L5 vertebrae	33	39
Complications		
Fever	2	3
Cement leakage		
Number of vertebrae	0	5
Location		
Paravertebral soft tissues	0	4
Adjacent disks	0	1

2.5. Statistical analysis

The mean deviation and standard deviation of anterior and middle vertebral height, VAS and ODI scores were calculated and analyzed by SPSS software (SPSS 19.0, USA). The basic characteristics and results evaluation parameters of the 2 groups of data were compared by *t* test of group design data. When $P < .05$, the difference is statistically significant.

3. Results

3.1. Patients

From January 2013 to December 2017, patients with metastatic vertebral tumors received kyphoplasty in our hospital were 257. Patients who met the criteria were followed up after adequate evaluation. We performed a 1-year follow-up for the 147/172

patients. 10 patients died in 1 year because of underlying disease and 15 patients lost follow-up. 65 patients with OMVT received 86 KP and 82 patients with MVT received 104 KP (Supplementary Fig. 1, <http://links.lww.com/MD/E340>). The metastatic vertebrae treated with KP ranged from T6 to L5 in Figure 1. General characteristics are compared of the patients of OMVT in Table 1. A representative case of a male patient with L3 OMVT who received KP treatment in Figures 2 and 3.

3.2. Surgical operation

In OMVT patients, the operation time for every vertebral body was 24.52 ± 4.24 minutes, and the fluoroscopy time was 10.18 ± 1.53 minutes. The amount of cement injected was 3.62 ± 0.93 ml. In MVT patients, the operation time for each vertebral body was 26.63 ± 4.61 minutes, and the fluoroscopy time was 11.04 ± 2.15 minutes. The amount of injected cement is 4.09 ± 1.10 ml. The operation time, fluoroscopy time and the amount of bone cement injection in the 2 groups had statistical significance ($P < .01$).

3.3. Clinical evaluation

In the OMVT group, The VAS score decreased from 7.26 ± 0.108 preoperatively to 2.77 ± 0.93 postoperatively ($P < .01$), and remained at 2.65 ± 0.89 1 year after operation. The ODI score decreased from 64.89 ± 9.05 preoperatively to 25.82 ± 4.63 postoperatively ($P < .01$), and remained at 29.49 ± 6.96 1 year after operation. The vertebral height of OMVT patients preoperatively and postoperatively had no difference ($P > .05$).

In the MVT group, The VAS score decreased from 7.73 ± 0.94 preoperatively to 3.22 ± 0.80 postoperatively ($P < .01$), and remained at 2.61 ± 0.84 1 year after operation. The ODI score decreased from 69.20 ± 7.14 preoperatively to 28.02 ± 4.40 postoperatively ($P < .01$), and remained at 28.37 ± 5.53 1 year after operation. The vertebral height of MVT patients improved significantly compared with that preoperatively ($P < .01$) (Table 2).

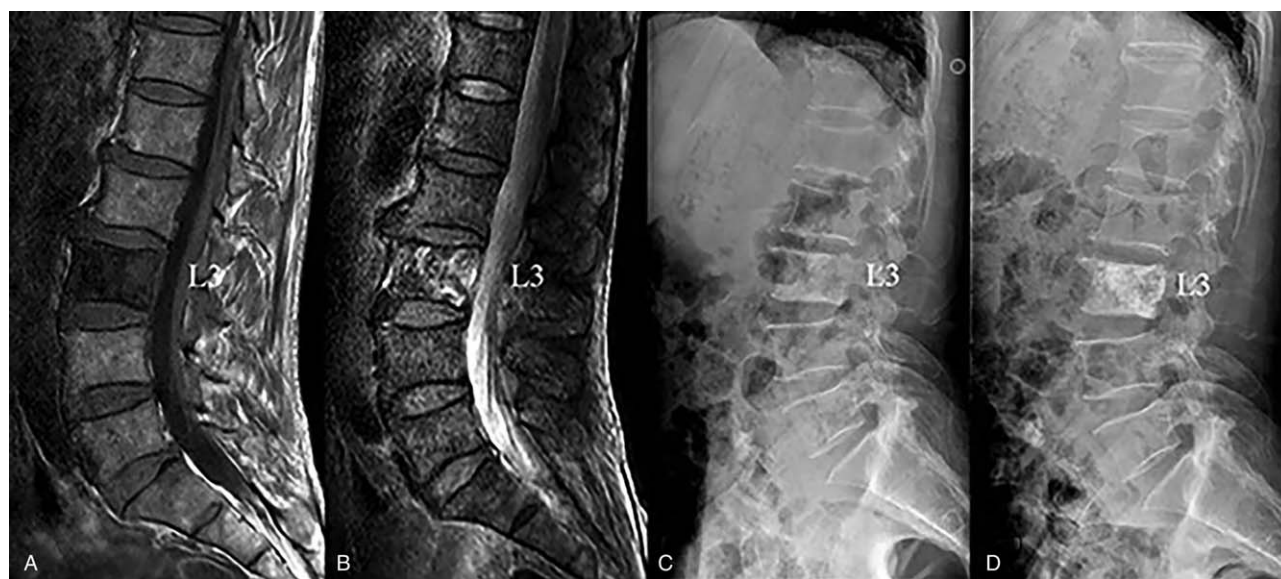

Figure 2. A representative case of a male patient with L3 OMVT who received KP treatment. (A and B) Preoperative MRI examination. There were MRI signal changes in the T1wi and T2wi. Low signals on the T1 sequence and high signals on the T2. (C and D) A comparison of preoperative and postoperative X-ray. No bone destruction and vertebral collapse were observed in preoperative X-ray.

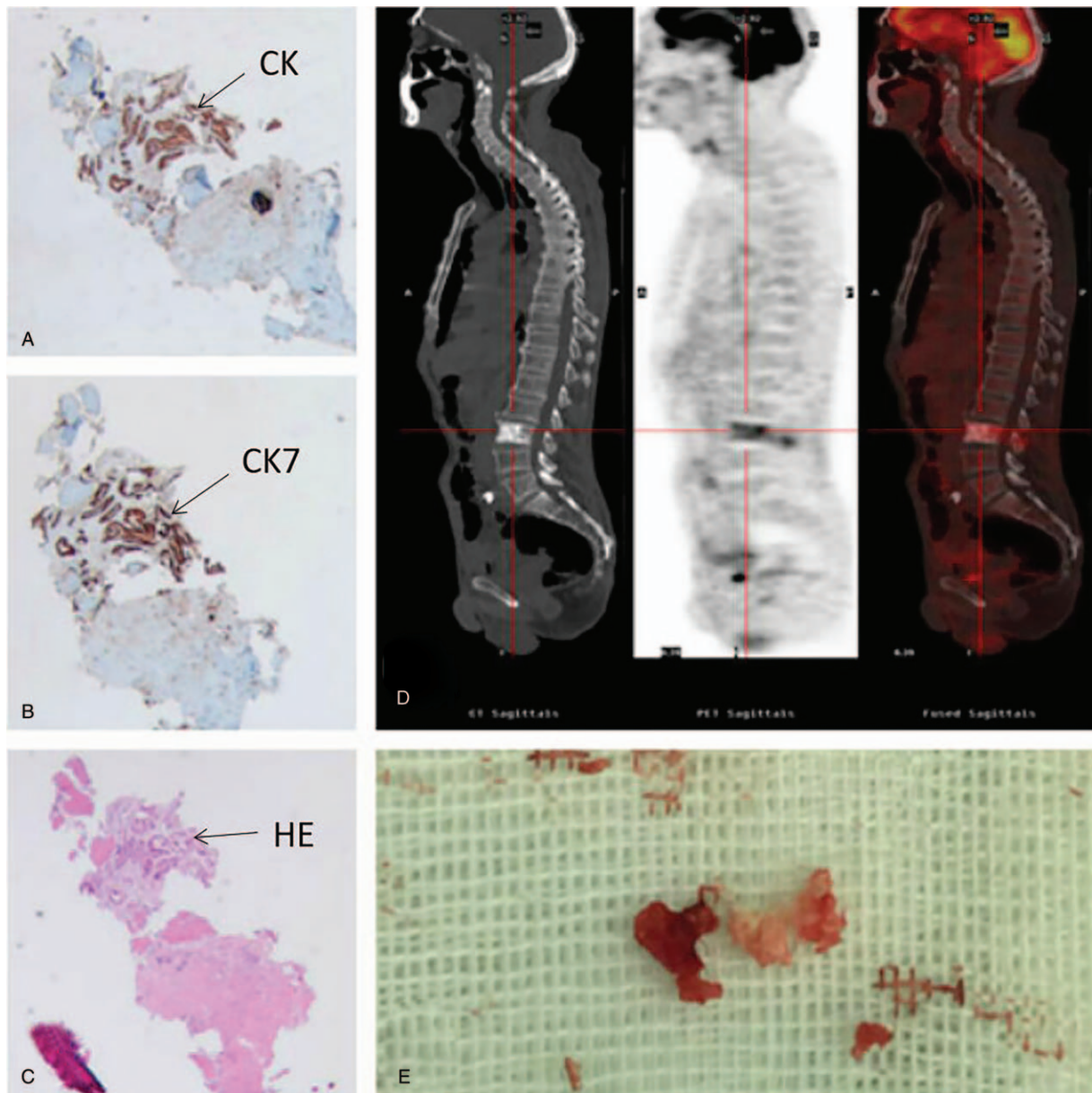


Figure 3. (A–C) Immunohistochemical results of patients were CK (+), CK7 (+) and HE (+), indicating that L3 vertebral lesions were metastatic adenocarcinoma. (D) Patient PET-CT results showed that the uptake rate of tracer in L3 region was higher than that in other parts. (E) Lesion tissue of L3 vertebral body removed during operation.

3.4. Complication

By X-ray examination postoperatively, there was no leakage of bone cement in 65 OMVT patients receiving 86 KP treatments, but in 82 MVT patients receiving 104 KP treatments, 5 of them had leakage of bone cement.

4. Discussions

Jae Hwan-cho et al have found that early vertebral metastases are asymptomatic and only occur when the tumor invades the nerve or develops into a pathological fracture.^[15] Studies have shown that at least 30% of bone destruction or vertebral body deformation and collapse, X-ray can detect diseased tissue.^[16,17]

However, MRI has a good imaging effect on soft tissues such as spinal cord and tumor.^[18] Therefore, X-rays are often prone to missed diagnosis for OMVT, and MRI is an important method for diagnosing OMVT. Treatment options for patients with metastatic vertebral tumors are usually palliative, usually for the purpose of improving quality of life and reducing or eliminating pain. Traditional treatments include painkillers, bed rest, radiation therapy, chemotherapy, and surgery.^[19] Although these treatments are palliative treatment, patients are generally faced with the dependence of painkillers, poor therapeutic effects of radiotherapy and chemotherapy, and inability to tolerate open surgery. With the development of minimally invasive surgery, it provides a new way to solve the above problems. Some studies have shown that KP can significantly reduce pain in patients with

Table 2
Results and scores at different time.

Parameters	OMVT	MVT	P
Kyphoplasty operation			
Operation time per vertebrae (minutes)	24.52 ± 4.24	26.63 ± 4.61	.005
Fluoroscopy time per vertebrae (minutes)	10.18 ± 1.53	11.04 ± 2.15	.008
Injected cement volume (ml)	3.62 ± 0.93	4.09 ± 1.10	.007
VAS			
Preoperatively	7.26 ± 1.08	7.73 ± 0.94	.006
3 days postoperatively	2.77 ± 0.93*	3.22 ± 0.80*	.002
3 months postoperatively	2.72 ± 0.78*	2.66 ± 0.74*	.61
1 year postoperatively	2.65 ± 0.89*	2.61 ± 0.84*	.80
ODI			
Preoperatively	64.98 ± 9.05	69.20 ± 7.14	.002
3 days postoperatively	25.82 ± 4.63*	28.02 ± 4.40*	.004
3 months postoperatively	25.77 ± 4.90*	26.51 ± 5.11*	.37
1 year postoperatively	29.49 ± 6.96*	28.37 ± 5.53*	.31
Anterior vertebral height			
Preoperatively	26.25 ± 4.11	18.09 ± 4.33	.000
3 days postoperatively	26.62 ± 3.51†	25.79 ± 3.93*	.13
1 year postoperatively	25.89 ± 4.25†	26.04 ± 3.75*	.79
Middle vertebral height			
Preoperatively	26.04 ± 3.72	17.72 ± 4.53	.000
3 days postoperatively	25.58 ± 4.05†	25.22 ± 2.96*	.49
1 year postoperatively	25.81 ± 3.76†	25.66 ± 3.25*	.75

* P < .01 compared to preoperative value.

† P > .05 compared to preoperative value.

metastatic vertebral tumors, prevent vertebral collapse and improve quality of life compared with non-surgical treatment.^[20]

The purpose of our study was to describe our experience and assess the safety and effectiveness of KP in the treatment of OMVT and MVT. In 65 patients with OMVT and 82 patients with MVT, we found that VAS and ODI scores were significantly improved after KP treatment. We found that there were significant differences in VAS and ODI between OMVT patients and MVT patients preoperatively, suggesting that patients with MVT suffered more severe pain and lower quality of life than those with OMVT. In OMVT patients, the vertebral height remained unchanged after KP, while in MVT patients, the vertebral height improved significantly after KP. In 1 year after operation, there was no significant difference in vertebral height between the 2 groups. The results showed that KP was effective in the management of OMVT and MVT, and early MRI examination and timely KP treatment can help OMVT patients to suffer from less pain, avoid developing into MVT and improve their quality of life. The exact mechanism of pain relief in these operations remains controversial. It is likely that the pain is relieved by stabilizing the fracture with cement. Another explanation is that monomer toxicity and exothermic aggregation of bone cement lead to necrosis of pain receptors in bone.^[21]

The leakage of bone cement is still the main complication of KP.^[22] It has been reported that the leakage rate of bone cement in the treatment of metastatic spinal tumors with KP is 7%.^[14] According to our experience, good surgical techniques can reduce some leakage caused by vertebral wall defects. Cement injection must be done slowly and carefully. Once a cement leak is detected, the operator can adjust the direction of the needle or stop the injection immediately. When cement reaches the edge of the vertebral body, the injection process stops. In our retrospective study, 65 patients with OMVT underwent 86 KP operations without leakage, and 82 patients with MVT received 104 KP

operations, 5 of which had leakage. First, MVT patients have more cement volume than OMVT patients, so the risk of leakage is higher. In addition, compared with OMVT patients whose shape of the vertebral body is good, the vertebral body destruction of MVT patients is obvious, and even the vertebral body wall is broken, which is considered to increase the risk of bone cement leakage during surgery.^[23] Finally, because of the invasion of tumor tissue, the strength of vertebral body decreases. In the process of KP, the balloon destroys the vertebral bone when restoring the height of vertebral body, and it is easy to cause leakage.^[24]

This study has some limitations. First, the study was retrospective and produced less evidence than prospective studies. Secondly, our study only included patients receiving KP, without control or alternative treatment, such as vertebroplasty. Further prospective studies are needed to evaluate the efficacy and safety of KP therapy. Finally, we studied the efficacy of KP 1 year after surgery. Further studies are needed to determine the safety and effectiveness of KP in the treatment of OMVT and MVT.

5. Conclusion

In order to reduce the pain and improve the quality of life of patients with advanced cancer, patients with back pain, especially those with a history of cancer, even if the X-ray results are normal, also need to be examined by MRI for OMVT. Compared with MVT, KP may be more effective and safer in the treatment of OMVT.

Acknowledgments

Thanks to all patients involved in this study from the First Affiliated Hospital of Soochow University.

Author contributions

Conceptualization: Qian Zhonglai, Sun Zhiyong.

Data curation: He Shuangjun, Zhang Changhao, Lv Nanning.

Formal analysis: He Shuangjun, Qian Zhonglai, Sun Zhiyong.

Project administration: Zhou Zhangzhe.

Resources: Zhou Zhangzhe, Lv Nanning, Qian Zhonglai, Sun Zhiyong.

Software: Zhou Zhangzhe.

Supervision: Qian Zhonglai, Sun Zhiyong.

Writing – original draft: Zhou Zhangzhe.

Writing – review & editing: Zhou Zhangzhe.

References

- [1] Molina CA, Gokaslan ZL, Sciubba DM. Diagnosis and management of metastatic cervical spine tumors. *Orthoped Clin North Am* 2012;43:75–87.
- [2] Wang F, Zhang H, Yang L, et al. Epidemiological characteristics of 1196 patients with spinal metastases: a retrospective study. *Orthop Surg* 2019;11:1048–53.
- [3] Pennington Z, Ahmed AK, Molina CA, et al. Minimally invasive versus conventional spine surgery for vertebral metastases: a systematic review of the evidence[J]. *Ann Transl Med* 2018;6:103–16.
- [4] Guarnieri I, Gianluigi I, Roberto M, et al. Current trends in mini-invasive management of spine metastases. *Intervent Neuroradiol* 2015;21.2:263–72.
- [5] Yilin L, Yuqiang W, Liang Z, et al. Effectiveness and safety of percutaneous vertebroplasty in the treatment of spinal metastatic tumor [J]. *Pak J Med Sci* 2017;33:675–9.

- [6] Wong DA, Fornasier VL, MacNab IAN. Spinal metastases: the obvious, the occult, and the impostors. *Spine* 1990;15:1–4.
- [7] Yang L, Zhang S, Gu R, et al. Imaging features of primary spinal osseous tumors and their value in clinical diagnosis. *Oncol Lett* 2019;17:1089–93.
- [8] Sciubba DM, Petteys RJ, Dekutoski MB, et al. Diagnosis and management of metastatic spine disease. A review. *J Neurosurg Spine* 2010;13:94–108.
- [9] Kumar Y, Hayashi D. Role of magnetic resonance imaging in acute spinal trauma: a pictorial review. *BMC Musculoskeletal Disord* 2016;17:310–23.
- [10] Buhmann S, Becker C, Duerr HR, et al. Detection of osseous metastases of the spine: comparison of high resolution multi-detector-CT with MRI. *Eur J Radiol* 2009;69:567–73.
- [11] Kırçelli A, Çöven İ. Percutaneous balloon kyphoplasty vertebral augmentation for compression fracture due to vertebral metastasis: a 12-month retrospective clinical study in 72 patients. *Med Sci Monitor Int Med J Exp Clin Res* 2018;24:2142–8.
- [12] Sadeghi-Naini M, Aarabi S, Shokraneh F, et al. Vertebroplasty and kyphoplasty for metastatic spinal lesions: a systematic review. *Clin Spine Surg* 2018;31:203–10.
- [13] Clerk-Lamallice O, Beall DP, Ong K, et al. ISASS Policy 2018—vertebral augmentation: coverage indications, limitations, and/or medical necessity. *Int J Spine Surg* 2019;13:1–0.
- [14] Chen F, Xia YH, Cao WZ, et al. Percutaneous kyphoplasty for the treatment of spinal metastases. *Oncol Lett* 2016;11:1799–806.
- [15] Cho JH, Ha JK, Hwang CJ, et al. Patterns of treatment for metastatic pathological fractures of the spine: the efficacy of each treatment modality. *Clin Orthoped Surg* 2015;7:
- [16] Sciubba DM, Gokaslan ZL. Diagnosis and management of metastatic spine disease. *Surg Oncol* 2006;15:141–51.
- [17] Gebauer GP, Farjoodi P, Sciubba DM, et al. Magnetic resonance imaging of spine tumors: classification, differential diagnosis, and spectrum of disease. *JBJS* 2008;90:146–62.
- [18] Araujo JL, Veiga JC, Figueiredo EG, et al. Management of metastatic spinal column neoplasms—an update. *Rev Col Bras Cir* 2013;40:508–14.
- [19] Kirkegaard AO, Sørensen ST, Ziegler DS, et al. Percutaneous vertebroplasty is safe and effective for cancer-related vertebral compression fractures. *Dan Med J* 2018;65:A5509–13.
- [20] Aparisi F. Vertebroplasty and kyphoplasty in vertebral osteoporotic fractures. *Semin Musculoskelet Radiol* 2016;20:382–91.
- [21] Sun ZY, Li XF, Zhao H, et al. Percutaneous balloon kyphoplasty in treatment of painful osteoporotic occult vertebral fracture: a retrospective study of 89 cases. *Med Sci Monitor* 2017;23:1682–90.
- [22] Sebaaly A, Nabhane L, Issa El Khoury F, et al. Vertebral augmentation: state of the art. *Asian Spine J* 2016;10:370–6.
- [23] Koh YH, Han D, Cha JH, et al. Vertebroplasty: magnetic resonance findings related to cement leakage risk. *Acta Radiologica* 2007;48:315–20.
- [24] Liu T, Li Z, Su Q, et al. Cement leakage in osteoporotic vertebral compression fractures with cortical defect using high-viscosity bone cement during unilateral percutaneous kyphoplasty surgery. *Medicine* 2017;96:e7216.