

Case Report

Fungal keratitis caused by a rare ocular pathogen, *Gjaerumia minor*: A case report



Yahya H. Al-Falki^{a,*}; Mohamed A. Alshehri^b; Martin R.P. Joseph^c; Mohamed E. Hamid^c

Abstract

Fungal keratitis is an important infection of the eye that may cause devastating effects. Keratitis caused by fungi has been described in many parts of the world mainly in tropical countries. The objective of this study is to report a serious eye infection in an adult with a known history of diabetes caused by an uncommon yeast fungus with details of clinical findings and laboratory investigations. Left eye visual acuity was no perception of light due to end stage neovascular glaucoma. The patient was pseudophakic in both eyes. Culture of a corneal scraping showed yeast like organism on Sabouraud dextrose agar. *Gjaerumia minor*, a rare yeast but with history of a pulmonary infection in the region, was confirmed with 98% similarity in the large subunit ribosomal RNA gene (accession KY690175). Topical Amphotericin B and oral fluconazole were initiated. The patient showed gradual improvement, epithelial defect healed, infiltration steadily regressed and hypopyon disappeared. We report the first case of fungal keratitis caused by *G. minor* in Saudi Arabia. Fungal Keratitis should be considered in cases where clinical response to the conventional antibacterial antibiotic treatment is not optimal.

Keywords: Fungal keratitis, Oculomycosis, Corneal scraping, Large subunit ribosomal RNA, *Georgesfischeriales*, *Tilletiopsis minor*

© 2017 The Authors. Production and hosting by Elsevier B.V. on behalf of Saudi Ophthalmological Society, King Saud University. This is an open access article under the CC BY-NC-ND license (<http://creativecommons.org/licenses/by-nc-nd/4.0/>). <https://doi.org/10.1016/j.sjopt.2017.09.007>

Introduction

Fungal keratitis is a significant ocular infection that causes potentially devastating visual consequences. It is caused by many fungal species that are capable of colonizing human tissue. Keratitis caused by fungi has been described in many parts of the world but predominantly in tropical countries. Trauma, ocular surface disease, topical steroid use, geographic location and climate are significant risk factors.^{1,2} More than 105 fungal species have been reported to cause oculomycosis. *Fusarium*, *Aspergillus*, *Curvularia* and some

other hyaline hyphomycetes and dematiaceous hyphomycetes are commonly encountered in patients with filamentous fungal keratitis. Whereas, *Candida albicans* is the most frequent cause of keratitis due to yeast-like and related fungi.^{1,2}

A taxonomic revision of yeasts and related fungi in the subphylum *Ustilaginomycotina* has made major transformations in the categorization of some yeast species. The genus *Gjaerumia* gen. nov. was a new genus in the order *Georgesfischeriales* (Ustilaginomycetes).³ The genus *Tilletiopsis* was shown to be polyphyletic.^{3,4} Two *Tilletiopsis* species in the order *Georgesfischeriales*, *T. minor* and *T. penniseti*, formed

Received 5 December 2016; received in revised form 20 September 2017; accepted 21 September 2017; available online 28 September 2017.

^a Division of Ophthalmology, Department of Surgery, College of Medicine, King Khalid University, Abha, Saudi Arabia

^b Division of Ophthalmology, Aseer Central Hospital, Abha, Saudi Arabia

^c Department of Microbiology, College of Medicine, King Khalid University, Abha, Saudi Arabia

* Corresponding author at: Division of Ophthalmology, Department of Surgery, College of Medicine, King Khalid University, PO Box 641, Abha 61314, Saudi Arabia.

e-mail address: yhalfalgi@hotmail.com (Y.H. Al-Falki).

a clade with a teleomorphic species *Gjaerumia ossifragi*, the type of the genus. *G. ossifragi* formed a statistically supported cluster with *T. minor*, *T. penniseti*, and two undescribed species of *Tilletiopsis* based on the Bayesian inference analysis of the LSU rRNA genes.³ The results support transferring *T. minor* and *T. penniseti* into *Gjaerumia*.⁵ Species in the genus *Gjaerumia*, blastoconidia-forming yeasts, are not known pathogens in medical practice. In the literature there are very few reported cases including a keratitis case in 2007 in a diabetic patient post LASIK,⁶ one from cystic lesions in an immunocompromised individual⁷ and a case of pneumonia in a child from the same region (Aseer) where we are reporting this case.⁸

This communication was intended to report a serious eye infection in an adult diabetic patient caused by an uncommon yeast fungus.

Case report

A 65-yr-old Saudi male known to be poorly controlled diabetes type 2 on insulin presented to Emergency Room of Aseer Central Hospital, a referral hospital for the Southern region of Saudi Arabia in January 2016 with left eye pain, photophobia and redness for 8 days. Left eye visual acuity was no perception of light due to end stage neovascular glaucoma. The patient was pseudophakic in both eyes. No history of trauma, contact lens wear or steroid eye drops were reported. Slit lamp examination of left eye revealed conjunctival hyperemia, central corneal epithelial defect measuring 6 × 6 mm with dense stromal infiltration with fuzzy margins and hypopyon measuring 5 mm. B-scan showed clear vitreous. Corneal scraping was done and sent for laboratory investigation requesting aerobes, anaerobes, acanthamoeba and fungal examinations.

The patient was initially started on empiric therapy with fortified vancomycin eye drop 25 mg/mL and fortified cef-tazidime 50 mg/mL alternating hourly. After 48 h of initiating therapy, the patient did not show significant clinical improvement. The preliminary microbiological studies were suggestive of a fungal etiology. The patient was shifted to antifungal therapy (amphotericin B eye drops 0.15% every 6 h and oral fluconazole 200 mg every 12 h for four weeks). The patient showed gradual clinical improvement, the epithelial defect healed, the infiltration gradually regressed, and the hypopyon disappeared completely by the end of the second week. Left eye visual acuity was no perception of light due to end stage neovascular glaucoma. This is the reason behind using four times only of topical amphotericin B and not one hourly, weighing the risk benefit ratio and the clinical response was monitored closely.

The corneal scraping was inoculated onto Sabouraud dextrose agar (SDA; Difco, Becton, Dickinson and Company, Sparks, Maryland) for 5 days at 30 °C. Culture revealed the growth of creamy yellow, irregular, wrinkled yeast like colonies (Fig. 1A). The suspected fungal growth was sub-cultured onto fresh SDA plates to improve the growth and appearance of distinguished fungal elements. The organism was labeled AHS and identified on the basis of colony morphology on SDA and on the basis of microscopic features following recommended guiding principles.⁹

The stained smears made from the grown AHS culture revealed medium-sized irregular hyphae with the evidence

of blastoconidia, but no budding yeast cells were visible (Fig. 1B). Manual bench tests and the automated phenotypic analyses failed to recognize the organism.

Confirmation of the identity of this infrequent organism was completed by the analysis of regions from large subunit rDNA, amplified using primer: 5.8SR (5'-TCGATGAAGAACC GAGCG) and LR7 (5'- TACTACCACCAAGATCT).¹⁰ A neighbor-joining phylogenetic tree was constructed based on sequences from 26S rDNA gene sequence-based analysis. The evolutionary analyses were conducted in MEGA v6 software.¹¹ The analysis showed that the strain AHS (GenBank accession KY690175) is a member of the genus *Gjaerumia*. It falls in the branch which accommodates *Gjaerumia minor* with 98% similarity with the type strain (Fig. 2). It revealed similarity of 95% with *Gjaerumia pennisetum*, and 87% with *Tilletiaria anomala*. The strain AHS had a relatively remote connection to other closely related yeast species. Therefore the strain AHS was identified as *G. minor*.

Discussion

Fungal keratitis is recognized as a major global public health problem particularly in developing countries representing from 6 to 50% of all cases of culture proven infectious keratitis.^{1,2,12} The purpose of this communication was to report a case of fungal keratitis caused by an unusual and rare type of yeasts which is to the best of our knowledge the first case of keratitis caused by *G. minor* in the Middle East.

Few studies stated that risks for developing deep stromal fungal keratitis include persons with diabetes.⁶ Diabetes was identified as a common risk factor with 17.8% of patient has a history of diabetes mellitus.¹³ Diabetes in the present case seems to have predisposed to this rare yeast infection as in the post LASIK case.⁶

Microbial keratitis is an opportunistic, serious sight threatening ocular disease that can be caused by different types of microorganisms. If not diagnosed and treated early it can produce grave consequences.¹⁴ Development and widespread use of broad-spectrum antibiotics and steroids, trauma to the eye, frequent and prolonged use of contact lens, seasonal variation, ocular surface disease and underlying diseases that compromise the immune mechanism of the host have been identified as major factors that contribute to the increasing number of fungal keratitis cases.¹⁵ In spite of low frequency of anti fungal therapy, the patient showed significant improvement. This new fungus is probably different from other known fungal pathogens. Moreover, its virulence is not fully understood given the few reports in the literature.^{7,8}

Microbiological examination should be done when fungal infections of the cornea are suspected. Corneal scrapings or corneal biopsy for microscopy and culture are needed to accomplish a laboratory diagnostic support for clinical picture. If direct microscopic examination of cornea or corneal biopsies produces certain laboratory diagnosis that is consistent with the clinical suspicion, treatment should be started. The treatment might be delayed till culture report is obtained. In the present case, the laboratory report was useful in initiating of antifungal treatment. Amphotericin B eye drops and oral fluconazole was successful which is in line with published reports.¹

The study concludes that fungal keratitis should be considered in cases where treatment to conventional antibacterial

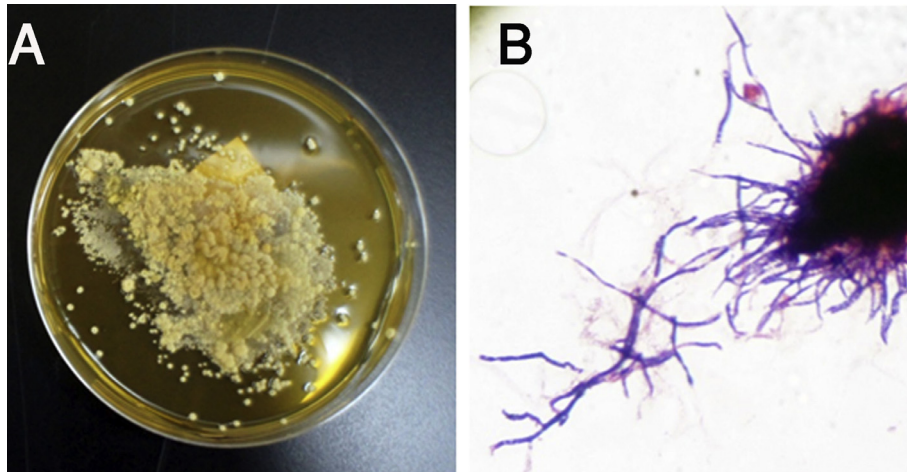


Fig. 1. Culture (A) and microscopic appearance (B) of the strain AHS recovered from a corneal scraping of a 65-yr patient with keratitis on Sabouraud dextrose agar at 30 °C. Note the growth of creamy yellow, irregular, wrinkled yeast-like colonies (A) and microscopic appearance of the strain AHS showing irregular broad filaments in a Gram stained smear.

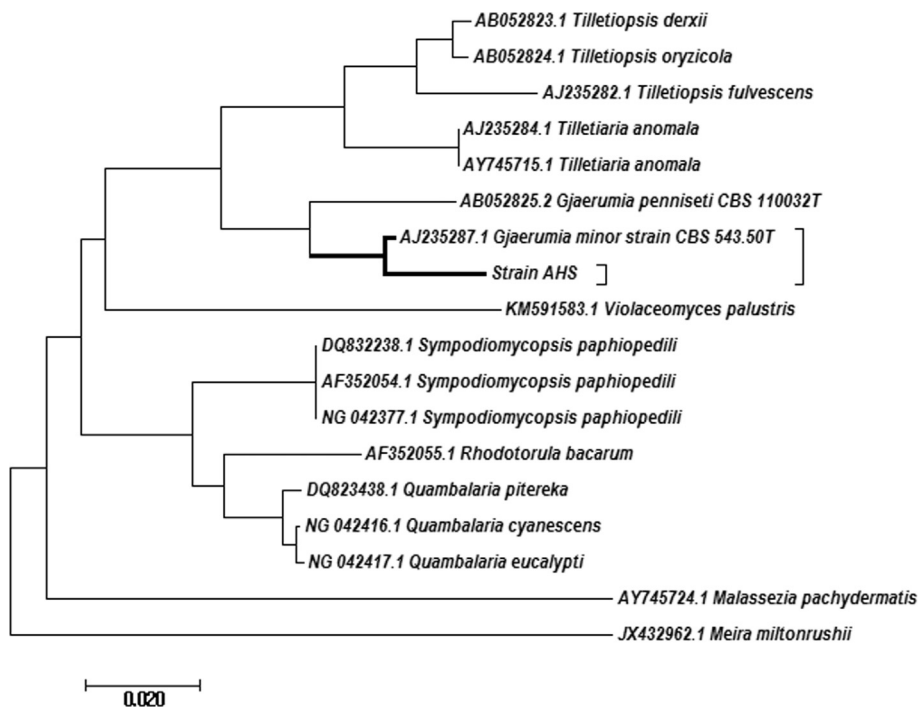


Fig. 2. A phylogenetic tree based on the analysis of regions from large subunit rDNA showing the position of the strain AHS (accession KY690175) with representative yeast species in the order Geogfischeriales. The evolutionary history was inferred using the Neighbor-Joining method. Bar, base substitution rate.

therapy is not successful. The use of amphotericin B eye drops and oral fluconazole antifungal seemed to be valuable in suppressing the fungal infection. Fungal infections should be considered in routine corneal scraping tests and better to wait for the *in vitro* antimicrobial assays as yeasts or molds may possibly respond in a different way to conventional antifungal agents.

Conflict of interest

The authors declared that there is no conflict of interest.

References

1. Thomas PA, Kaliyamurthy J. Mycotic keratitis: epidemiology, diagnosis and management. *Clin Microbiol Infect* 2013;**19**:210–20.
2. Gopinathan U, Garg P, Fernandes M, Sharma S, Athmanathan S, Rao GN. The epidemiological features and laboratory results of fungal keratitis: a 10-year review at a referral eye care center in South India. *Cornea* 2002;**21**:555–9.
3. Bauer R, Lutz M, Oberwinkler F. *Gjaerumia*, a new genus in the Geogfischeriales (Ustilaginomycetes). *Mycol Res* 2005;**109**:1250–8.
4. Fell JW, Boekhout T, Fonseca A, Scorzetti G, Statzell-Tallman A. Biodiversity and systematics of basidiomycetous yeasts as determined by large-subunit rDNA D1/D2 domain sequence analysis. *Int J Syst Evol Microbiol* 2000;**50**(Pt 3):1351–71.

5. Wang QM, Begerow D, Groenewald M, Liu XZ, Theelen B, Bai FY, et al. Multigene phylogeny and taxonomic revision of yeasts and related fungi in the Ustilaginomycotina. *Stud Mycol* 2015;**81**:55–83.
6. Kechkekian A, Gari Toussaint M, Gastaud P, Freton A, Gantier JC. Keratitis due to *Tilletiopsis minor* post LASIK. *J Mycol Med* 2007;**17**:119–21.
7. Ramani R, Kahn BT, Chaturvedi V. *Tilletiopsis minor*: a new etiologic agent of human subcutaneous mycosis in an immunocompromised host. *J Clin Microbiol* 1997;**35**:2992–5.
8. Al-Zaydani IA, Joseph MR, Suheel AM, Al-Hakami AM, Hamid ME. Severe pneumonia with a massive pleural effusion in a child caused by *Tilletiopsis minor*: the first case from Saudi Arabia. *Ann Saudi Med* 2015;**35**:475–8.
9. Chao QT, Lee TF, Teng SH, Peng LY, Chen PH, Teng LJ, et al. Comparison of the accuracy of two conventional phenotypic methods and two MALDI-TOF MS systems with that of DNA sequencing analysis for correctly identifying clinically encountered yeasts. *PLoS One* 2014;**9**:e109376.
10. Bruns TD, White TJ, Taylor JW. Fungal molecular systematics. *Annu Rev Ecol Syst* 1991;**22**:525–64.
11. Tamura K, Stecher G, Peterson D, Filipksi A, Kumar S. MEGA6: Molecular Evolutionary Genetics Analysis version 6.0. *Mol Biol Evol* 2013;**30**:2725–9.
12. Bharathi MJ, Ramakrishnan R, Meenakshi R, Padmavathy S, Shivakumar C, Srinivasan M. Microbial keratitis in South India: influence of risk factors, climate, and geographical variation. *Ophthalmol* 2007;**14**:61–9.
13. Mehta R, Mehta P, Raghavendra Rao MV, Acharya Y, Bala AS, Sowmya JK. A study of fungal keratitis in North Africa: exploring risk factors and microbiological features. *Int J Life Sci Scient Res* 2016;**2**:579–82.
14. Stapleton F, Keay LJ, Sanfilippo PG, Katiyar S, Edwards KP, Naduvilath T. Relationship between climate, disease severity, and causative organism for contact lens-associated microbial keratitis in Australia. *Am J Ophthalmol* 2007;**144**:690–8.
15. Alfonso EC, Forster RK, Garg P. Fungal infections. In: Foster CS, Azar CH, Dohlman CH, editors. *Smolin and Thoft's the Cornea Scientific Foundations & clinical practice*, vol. 4. Baltimore, MD: Lippincott Williams & Wilkins; 2005. p. 405–16.