



Acute thrombosis of the carotid artery associated with positional nystagmus at multiple planes

Sertaç Yetişer^{a, *}, Yaşar Kütükçü^b, Kutlay Kahraman^c

^a Anadolu Medical Center, Dept of ORL & HNS, Kocaeli, 41400, Turkey

^b Anadolu Medical Center, Dept of Neurology, Kocaeli, 41400, Turkey

^c Anadolu Medical Center, Dept of Radiology, Kocaeli, 41400, Turkey

ARTICLE INFO

Article history:

Received 22 May 2019

Received in revised form

30 June 2019

Accepted 6 August 2019

Keywords:

Upbeat nystagmus

Positional maneuver

Carotid artery occlusion

ABSTRACT

Objective: An acute onset central pathology without any clear neurological symptoms may mimic peripheral vestibular problem in an emergency setting. A 54-year-old man suddenly developed dizziness without any cranial nerve symptoms, paresis, cerebellar signs or sensory disturbances except upbeat positional nystagmus at multiple provoked positions which alerted for a possible acute central pathology. **Findings:** An instantaneous magnetic resonance imaging and angiography studies further showed obstruction of the left internal carotid artery above the bifurcation. The patient's subsequent prognosis was consistent with good recovery following anti-coagulant therapy. A follow-up MRI and angiography showed resolution of thrombosis.

Conclusion: It should be kept in mind that positional nystagmus is likely to occur in central pathologies. Differentiation between benign paroxysmal positional vertigo and central positioning nystagmus is critical.

© 2019 PLA General Hospital Department of Otolaryngology Head and Neck Surgery. Production and hosting by Elsevier (Singapore) Pte Ltd. This is an open access article under the CC BY-NC-ND license (<http://creativecommons.org/licenses/by-nc-nd/4.0/>).

1. Introduction

Benign paroxysmal positional vertigo (BPPV) is the most common peripheral cause of vertigo at outpatient ENT clinics. Otoconia inside the semicircular canals make the ampullary hair cells sensitive to gravitational forces in patients with BPPV who experience a sudden sense of vertigo when they turn their head to either side or when they bend their head forward or backward, either intentionally or unintentionally (Bhattacharyya et al., 2017). Up beating clockwise or counter clockwise torsional nystagmus during head-hanging position is indicative of posterior canal involvement which is the most common form of BPPV. However, correct diagnosis of positional vertigo of benign type is based on presence of latency and fatigability of the nystagmus. Clearance of the semicircular canal with liberatory or re-positioning maneuvers provides

complete relief of symptoms.

Upbeat spontaneous nystagmus (UBN) without any stimulation indicates central vestibular dysfunction (Pierrot-Deseilligny and Milea, 2005). It has been associated with space occupying or vascular lesions of the midbrain, midline cerebellum and lower brainstem involving the ponto-mesencephalic junction and medulla. However, the precise anatomic localization still remains unclear. Lesions in the pathways, from vestibular to the oculomotor nuclei could lead slow downward drift of eyes, which is repeatedly corrected by fast compensatory upward movements (Pierrot-Deseilligny and Milea, 2005). It is significant to recognize the positional upbeat nystagmus originating from central pathologies since it may mimic BPPV. Hypotheses for the mechanisms that may cause to UBN suggest (i) interruption of the connections of the vertical vestibulo-ocular reflexes, (ii) an imbalance or a mismatch of vertical neural integrator for conjugate eye movements; and (iii) disruption of vertical smooth pursuit system (Nakada and Remler, 1981). Connections between various brainstem areas contributing eye movements are extremely complex. A range of diseases have been reported including brainstem ischemia or tumors, Wernicke's encephalopathies, and vascular or demyelinating lesions (Hirose et al., 1991; Ohkoshi et al., 1998; Elliott et al., 1989).

* Corresponding author. Anadolu Medical Center, Dept of ORL & HNS, Gebze, Kocaeli, 41400, Turkey.

E-mail addresses: sertac.yetiser@anadolusaglik.org (S. Yetişer), yasar.kutukcu@anadolusaglik.org (Y. Kütükçü), kutlay.kahraman@anadolusaglik.org (K. Kahraman).

Peer review under responsibility of PLA General Hospital Department of Otolaryngology Head and Neck Surgery.

In acute vertigo, upbeat nystagmus that occurs only during positional maneuvers should alert the clinicians especially in patients without any neurological signs and cerebellar ataxia. Central positional nystagmus is rare and may easily mimic BPPV. We report a patient with acute central vascular pathology whose initial presentation consisted of only UBN during positional maneuvers.

2. Case history

A 54-year old man presented to ENT outpatient clinic with acute imbalance, oscillopsia and postural instability which started the same day in the morning. The patient was healthy except occasional head ache which generally resolved with regular pain killers. He had head ache for the last few days as well. Otoloscopic view was not remarkable and the pupils and vision were normal. His hearing was normal. The patient had normal eye movement on every direction and there was no internuclear ophthalmoplegia. His neurological examination (fundoscopy, search of any pathological reflex, search of neck stiffness, skew deviation, mental status, coordination, muscle strength and examination of other cranial nerves etc.) was normal. The patient had normal head impulse test result on every direction. He was subjected to videonystagmographic analysis (VNG, Micromed., Inc, Chatham-III, USA) which revealed no spontaneous nystagmus at primary gaze position while the patient was sitting. He had no gaze-evoked nystagmus while looking to the left and right. However, he had up beating positional nystagmus during Dix-Hallpike in the left and right ear, straight head hanging, and head-roll to the left and right

maneuvers (Fig. 1a, b, c, d and e). Nystagmus had no rotatory component, and was persistent with no latency (Video-1a, b, c, d, e and f). No change in direction of nystagmus was seen in different head positions. Average slow phase velocity of vertical nystagmus was 5°/sec at left Dix-Hallpike, 6°/sec at right Dix-Hallpike, 8°/sec at lying down supine, 4°/sec at right and left head-roll positions. He had normal smooth pursuit and saccadic tracking. However, he was unable to do optokinetic test. He did not have an analysis of vestibular evoked myogenic potentials or caloric testing and he was transferred to neurological clinic in the same day for examination which was otherwise completely normal. He had MRI which demonstrated small acute hyper intense ischemic area (15 mm) of the white matter on the left periventricular region, posterior to the internal capsula, close to the thalamus (Fig. 2a, b and c). Lesion was indicating involvement of the deep terminal branches of the middle cerebellar artery of the left internal carotid. Then, the patient was evaluated with angiography and acute carotid artery occlusion on the left side was confirmed (Fig. 2d). The patient was hospitalized for a week and he received anti-coagulant therapy for 5 weeks. Control MRI showed considerable resolution of hypo perfusion. Nystagmus disappeared in a few weeks most probably due to central compensation even without complete resolution of the lesion in the repeated MRI. An informed consent was obtained from the patient. The procedures were in accordance with the ethical standards of the declaration of Helsinki and with the institutional review board.

Supplementary video related to this article can be found at <https://doi.org/10.1016/j.joto.2019.08.001>

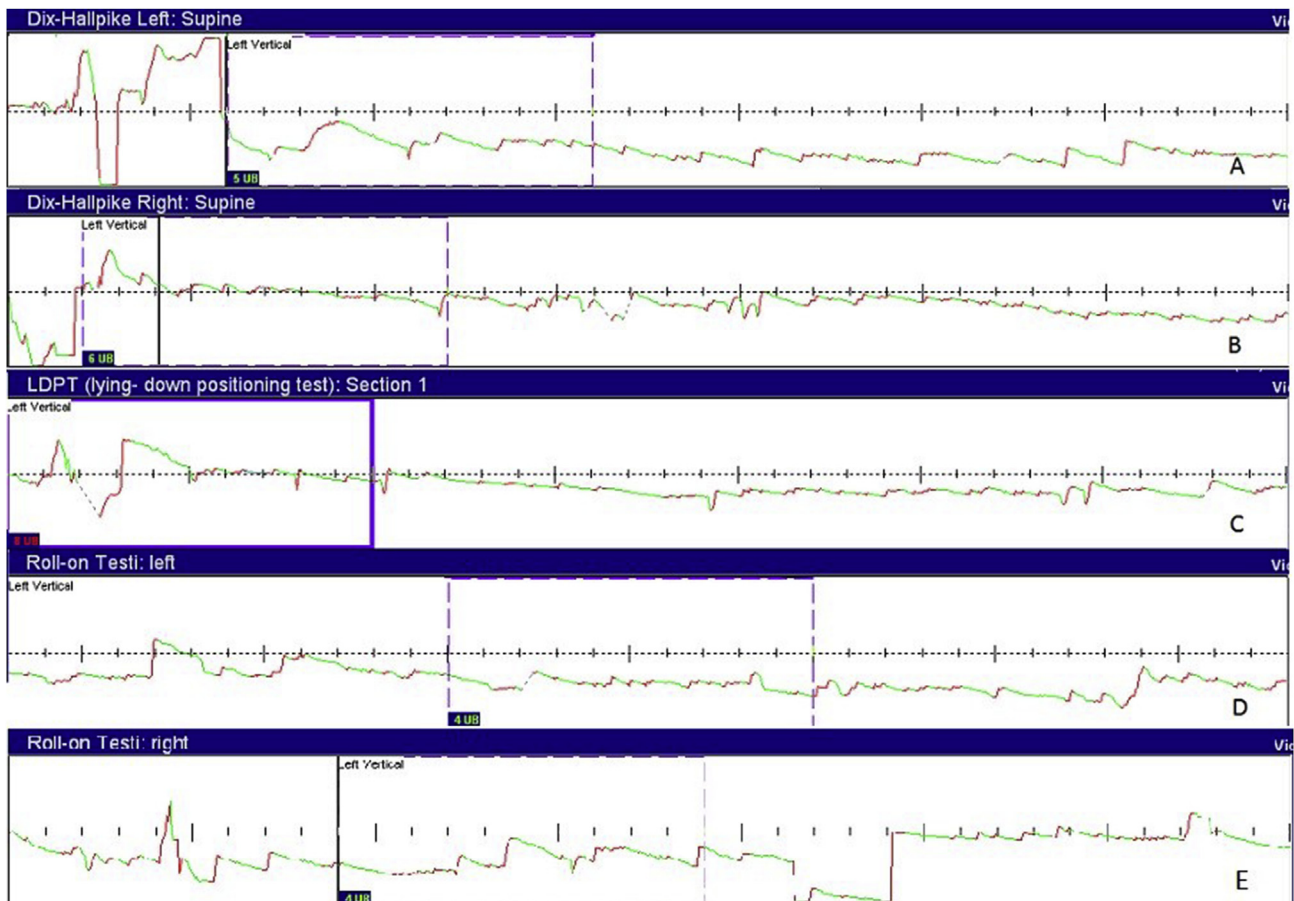


Fig. 1. Up beating positional nystagmus at left Dix-Hallpike (a), right Dix-Hallpike (b) lying down (straight head-hanging) (c), left head-roll (d) and right head-roll positions (e). Note that there is no latency and it lasts as long as the head is kept at that position.

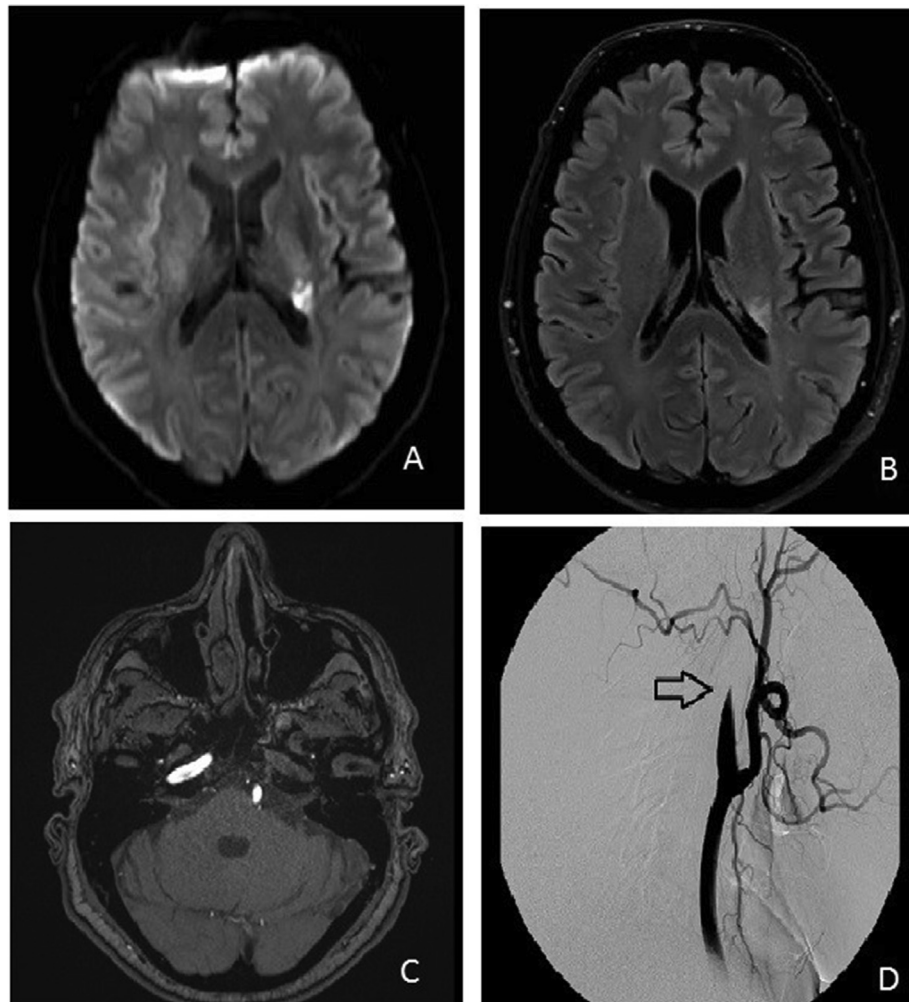


Fig. 2. Hyper intense ischemic area of the white matter in the left periventricular region, posterior to the internal capsula is seen at diffusion (a) and fluid attenuation inversion recovery (FLAIR) (b) sequences of axial T2 MRI. (c) MRI with contrast enhancement demonstrates no blood flow in the left internal carotid. (d) Internal carotid artery thrombosis slightly above the bifurcation is seen on angiography (marked with arrow).

3. Discussion

Saccadic and vestibular systems are the main sources of input to the oculomotor nucleus. Upward and downward vestibulo-ocular pathways from vestibular nuclei to the oculomotor nuclei are partially separated. Asymmetric involvement of these pathways which leads to imbalance of vestibular impulses to the elevator and depressor muscles of the eyes explains occurrence of vertical nystagmus. Type of vertical nystagmus is a mirror to topographic location of central disturbances. Downbeat nystagmus has been described in various disorders. But, the most frequent one is cerebellar pathology (atrophy, infarction, degeneration etc.) leading to a floccular hypofunction (Wagner et al., 2008). Upbeat nystagmus usually occurs with pontine or medullary brainstem disorders and it is rare with cerebellar lesions (Kim et al., 2006; Strupp et al., 2014). There is still uncertainty about the precise anatomical location of the origin of UBN. It reveals distortion of vestibulo-ocular reflex arch from anterior semicircular canals to the contralateral oculomotor nucleus via superior vestibular nucleus (Kim et al., 2006). Interruption of central projections of the semicircular canals from the vestibular to the oculomotor nuclei including the crossing ventral tegmental tract (CVTT), medial longitudinal fasciculus (MLF), and brachium conjunctivum (BC) may cause UBN (Pierrot-Deseilligny and Milea, 2005; Kim et al., 2006).

UBN in our patient was strongly dependent on head position. Amplitude of nystagmus may change by tilt of the head with respect to gravity which implies an otolith-related component in the genesis of nystagmus (Fisher et al., 1983; Pierrot-Deseilligny and Milea, 2005; Kim et al., 2006). UBN in focal lesions is likely to occur with imbalance of central otolithic projections affecting central vestibular connections. Midbrain is the most common area of cerebral ischemic infarcts. Deep periventricular area receives arterial supply from anterior choroidal artery and lenticulostriate arterial branches of the middle cerebral artery. Patients usually have very mild symptoms without any motor or sensorial deficits when the infarct area is too small. However, the area of cerebral ischemia varies significantly with time and early diagnosis is critical. A unilateral lesion could result up beating positional nystagmus on multiple planes because of bilateral connections with other brainstem structures. UBN in this patient might have been caused by vascular ischemia of the midbrain which damage interconnecting pathways involved in vertical slow phases, mainly vertical vestibulo-ocular reflex and smooth pursuit.

Spontaneous up beating nystagmus at primary gaze position indicates central pathology. However, isolated up beating central positioning nystagmus is relatively rare and rather confusing. Habek et al. (2011) have reported a patient with up beating positional nystagmus and proposed damage to the ventral tegmental

tract due to pontine stroke. Pierrot-Deseilligny et al. (2007) have reported that positional vertical nystagmus in central pathologies can be influenced by gravity (Pierrot-Deseilligny and Tilikete, 2008; Pierrot-Deseilligny, 2009). Bisdorff et al., 2000 have also reported that normal subjects may present up-beating positional nystagmus in the dark which could be due to otolithic input. Slow phase velocity of nystagmus is usually low and reversal of direction of nystagmus can be seen in different head positions (right-ear down or left-ear down). We have observed no latency, no fatigue and no change of direction of the positional nystagmus in the presented case. In case of BPPV, a period of latency is usually seen at the beginning of nystagmus until cupular inertia is disturbed following head-down lying movement and positional nystagmus will eventually finish after termination of cupular tilting or termination of endolymphatic flow due to movement of freely floating (canalolithiasis) or attached cristalloids (cupulolithiasis). On the other hand, multiple canal involvement of BPPV, particularly bilateral or pseudobilateral involvement of posterior canal should be borne in mind since vertical up-beating nystagmus is seen not only during Dix-Hallpike maneuver on both sides but also during straight head hanging position (Yetişer and Ince, 2014).

In conclusion, differentiation between BPPV and central positioning nystagmus has utmost importance. It can be sometimes difficult to reach the diagnosis for the unexperienced personnel of the emergency department and those cases require careful observing and ENT or neurology consulting particularly if previous medical record is uncertain (Buttner et al., 1999). Upbeat nystagmus without rotatory component and latency, occurrence at multiple planes, resistance to re-positioning maneuvers should alert clinician. Clear relation between the presence of vertical nystagmus and the anatomical location of the pathology may seem uncertain in the presented case. However, it should be borne in mind that vascular lesions may evolve rapidly within days or even hours and the extension of the stroke is well correlated with the feeding territory of the main vessels. We assume that the lesion has an impact on vestibulo-ocular pathways in one way or another. The interesting point for the presented case is that the only and clear sign was the vertical positional nystagmus alerting us for MRI evaluation.

Conflicts of interest

Authors have no conflict of interest regarding the manuscript.

Appendix A. Supplementary data

Supplementary data to this article can be found online at <https://doi.org/10.1016/j.joto.2019.08.001>.

References

- Bhattacharyya, N., Gubbels, S.P., Schwartz, S.R., Edlow, J.A., El-Kashlan, H., Fife, T., Holmberg, J.M., Mahoney, K., Hollingsworth, D.B., Roberts, R., Seidman, M.D., Steiner, R.W., Do, B.T., Voelker, C.C., Waguespack, R.W., Corrigan, M.D., 2017. Clinical practice guideline: benign paroxysmal positional vertigo (update). *Otolaryngol. Head Neck Surg.* 156 (3 Suppl. 1), S1–S47.
- Bisdorff, A., Sankovic, S., Debatisse, D., Bentley, C., Gresty, M.A., Bronstein, A.M., 2000. Positional nystagmus in the dark in normal subjects. *Neuro-ophthalmol* 24 (1), 283–290.
- Buttner, U., Helmchen, C., Brandt, T., 1999. Diagnostic criteria for central versus peripheral positioning nystagmus and vertigo: a review. *Acta Otolaryngol.* 119, 1–5.
- Elliott, A.J., Simpson, E.M., Oakhill, A., Decock, R., 1989. Nystagmus after medulloblastoma. *Dev. Med. Child Neurol.* 31 (1), 43–46.
- Fisher, A., Gresty, M., Chambers, B., Rudge, P., 1983. Primary position upbeating nystagmus. A variety of central positional nystagmus. *Brain* 106, 949–964.
- Habek, M., Gabelic, T., Pavliša, G., Brinar, V.V., 2011. Central positioning upbeat nystagmus and vertigo due to pontine stroke. *J. Clin. Neurosci.* 18, 978–980.
- Hirose, G., Kawada, J., Tsukada, K., Yoshioka, A., Sharpe, J.A., 1991. Upbeat nystagmus: clinicopathological and pathophysiological considerations. *J. Neurol. Sci.* 105 (2), 159–167.
- Kim, J.S., Yoon, B., Choi, K.D., Oh, S.Y., Park, S.H., Kim, B.K., 2006. Upbeat nystagmus: clinicoanatomical correlations in 15 patients. *J. Clin. Neurol.* 2 (1), 58–65.
- Nakada, T., Remler, M.P., 1981. Primary position upbeat nystagmus. Another central vestibular nystagmus. *J. Clin. Neuroophthalmol.* 1, 185–189.
- Ohkoshi, N., Komatsu, Y., Mizusawa, H., Kanasawa, I., 1998. Primary position upbeat nystagmus increased on downward gaze: clinicopathologic study of a patient with multiple sclerosis. *Neurology* 50 (2), 551–553.
- Pierrot-Deseilligny, C., Milea, D., 2005. Vertical nystagmus: clinical facts and hypotheses. *Brain* 128, 1237–1246.
- Pierrot-Deseilligny, C., Richeh, W., Bolgert, F., 2007. Upbeat nystagmus due to a caudal medullary lesion and influenced by gravity. *J. Neurol.* 254, 120–121.
- Pierrot-Deseilligny, C., Tilikete, C., 2008. New insights into upward vestibulo-oculomotor pathways in the human brainstem. *Prog. Brain Res.* 171, 509–518.
- Pierrot-Deseilligny, C., 2009. Effect of gravity on vertical eye position. *Ann. N. Y. Acad. Sci.* 1164, 155–165.
- Strupp, M., remmyda, O., Adamczyk, C., Böttcher, N., Muth, C., Yip, C.W., Bremova, T., 2014. Central ocular motor disorders, including gaze palsy and nystagmus. *J. Neurol.* 261 (Suppl. 2), 542–558.
- Wagner, J.N., Glaser, M., Brandt, T., Strupp, M., 2008. Downbeat nystagmus; etiology, comorbidity in 117 patients. *J. Neurol. Neurosurg. Psychiatry* 79 (6), 672–677.
- Yetişer, S., Ince, D., 2014. Vertical nystagmus during the seated-supine positional (straight head-hanging) test in patients with benign paroxysmal positional vertigo. *J. Laryngol. Otol.* 128 (8), 674–678.