

Case Report

Open Access

Multislice computed tomography for comprehensive assessment of the heart in acute chest pain: a case report

Andreas Horst Mahnken*^{1,2} and Anil Martin Sinha^{3,4}

Address: ¹Department of Diagnostic Radiology, RWTH Aachen University, Pauwelsstrasse 30, D-52074 Aachen, Germany, ²Applied Medical Engineering, RWTH Aachen University, Pauwelsstrasse 20, D-52074 Aachen, Germany, ³Medical Clinic I, RWTH Aachen University, Pauwelsstrasse 30, D-52074 Aachen, Germany and ⁴Department of Cardiology, Coburg Hospital, Ketchendorfer Str. 33, D-96450 Coburg, Germany

Email: Andreas Horst Mahnken* - mahnken@rad.rwth-aachen.de; Anil Martin Sinha - amsinha@gmx.de

* Corresponding author

Published: 31 October 2009

Received: 15 October 2009

Cases Journal 2009, 2:178 doi:10.1186/1757-1626-2-178

Accepted: 31 October 2009

This article is available from: <http://www.casesjournal.com/content/2/1/178>

© 2009 Mahnken and Sinha; licensee BioMed Central Ltd.

This is an Open Access article distributed under the terms of the Creative Commons Attribution License (<http://creativecommons.org/licenses/by/2.0>), which permits unrestricted use, distribution, and reproduction in any medium, provided the original work is properly cited.

Abstract

Introduction: Over the last decade cardiac computed tomography emerged as a non-invasive imaging modality for the assessment of the heart and the coronary arteries. Only recently its use for patient management in the emergency department was suggested.

Case Presentation: We present an 84-year old male patient with concomitant early in-stent restenosis after coronary artery stent placement, myocardial infarction, left and right ventricular thrombi and aortic valve stenosis. Diagnoses were made on emergency cardiac computed tomography. All findings were confirmed by catheter coronary angiography, echocardiography and cardiac magnetic resonance imaging.

Conclusion: The comprehensive emergency work-up by cardiac computed tomography, illustrates the potential value of cardiac computed tomography in the emergency setting.

Introduction

Over the last decade cardiac multislice computed tomography (MSCT) emerged as a new tool for assessing the coronary arteries, providing a high negative predictive value to exclude coronary artery disease (CAD). It has also been investigated for the assessment of coronary artery stent patency, coronary artery bypass graft patency, ventricular function and myocardial infarction [1]. Subsequently ECG-gated MSCT was used for the non-invasive assess-

ment of patients suffering from acute chest pain and its efficacy for diagnosing acute coronary syndrome could be shown [2,3]. Only recently its potential to reduce costs in the management of emergency patients has also been proved [4]. However, cardiac CT exceeds the simple assessment of the coronary arteries; it is becoming a tool for the comprehensive diagnostic work-up in the emergency setting.

Case presentation

One month after an acute ST-elevation myocardial infarction (CK 7230 U/L [<174], CK-MB 557 U/L [<6.7]) with stent placement in the left anterior descending coronary artery, an 84-year-old Caucasian man (180 cm, 75 kg) was admitted to the emergency department with atypical chest pain. Laboratory testing revealed a mild elevation of CK (CK 188 U/L [<174]) and CK-MB (CK-MB 6.9 U/L [<6.7]), while Troponin (T < 0.03 $\mu\text{g/L}$ [<0.03]) was negative. His current medication included clopidogrel (75 mg), acetylsalicylic acid (100 mg) and (metoprolol 100 mg). The patient's clinical history comprised appendectomy at the age of 16 and a myocardial infarction one month before admission. His cardiovascular risk factors were a history of smoking (45 pack/years) as well as arterial hypertension. The physical examination was unremarkable. There were no new ECG changes comparing to the previous hospital stays. As these findings were considered neither unequivocally indicative for a new occlusive CAD, nor in-stent restenosis, cardiac CT was performed. ECG-gated MSCT coronary angiography (64×0.6 mm, 120 kV, 750 mAs_{eff.}, 80 ml Iopromide 370 injected at 4 ml/s) revealed an in-stent restenosis (Figure 1). An early perfusion deficit was detected during the arterial phase imaging. Late phase images were obtained 10 minutes after contrast injection showing a transmural late-enhancement in the apical-anterior, the apical-septal segments of the left ventricle as well as the right ventricular apex. Moreover, cardiac MSCT depicted left and right ventricular thrombi (Figure 2). Extensive aortic valve calcifications raised the suspicion for aortic valve stenosis (Figure 3).

Based on the CT examination the patient underwent coronary angiography confirming an in-stent restenosis, which was treated with balloon angioplasty. Aortic valve stenosis was echocardiographically confirmed with a mean transvalvular gradient of 24 mm/Hg and MR imaging confirmed the extent of the myocardial late-enhancement and ventricular thrombus. For treating ventricular thrombi the patient was put on warfarin. Enzyme levels returned to normal within 48 hours after angioplasty. Three days later he was discharged in good condition. On follow-up echocardiography 6 months after discharge from hospital the thrombus had completely resolved.

Discussion

Beside the assessment of the coronary arteries, cardiac MSCT is capable of depicting complex cardiac conditions. In this case, MSCT proved its value for a comprehensive imaging workup in a patient with complex cardiac pathology. MSCT triggered additional diagnostic work-up and therapy for previously unknown left-ventricular thrombus. In comparison with magnetic resonance (MR) imaging, it performed equally well regarding the visualization

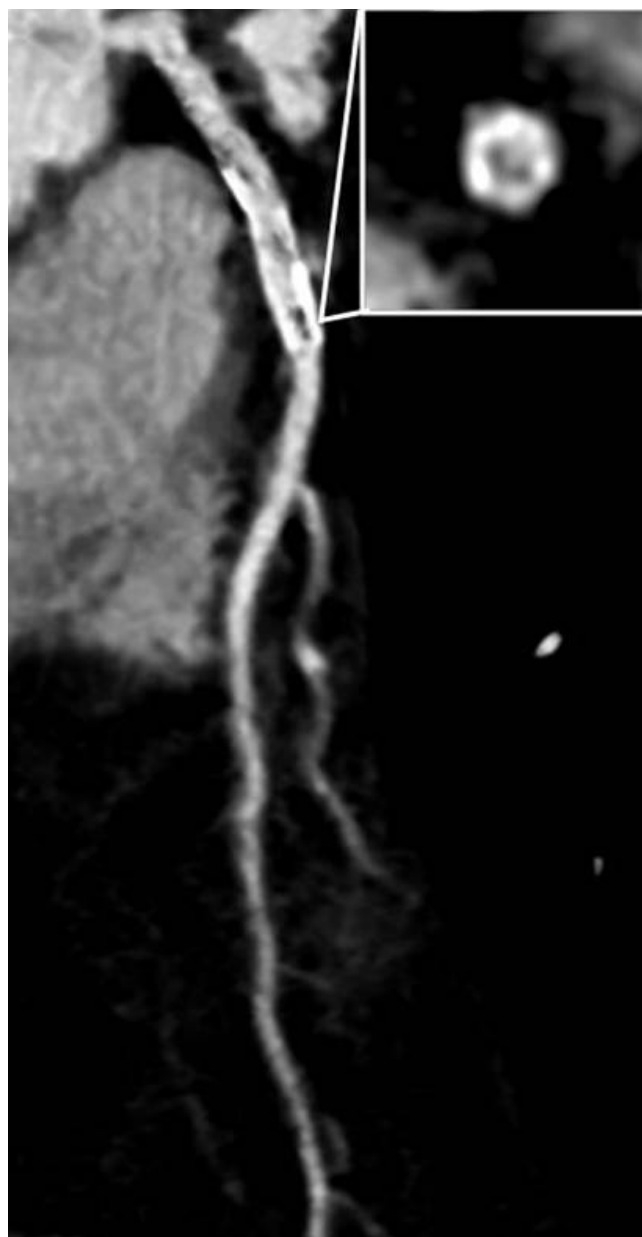


Figure 1
Curved multiplanar reformat of the LAD shows arteriosclerosis and an eccentric in-stent stenosis that is confirmed by an additional orthogonal view.

of the sequels and the detection of complications of myocardial infarction [5]. Although this indication is currently considered uncertain for routine use in the emergency setting [6], cardiac MSCT may be used in well selected emergency patients, providing a comprehensive non-invasive evaluation not only of the coronary arteries, but of the entire heart.

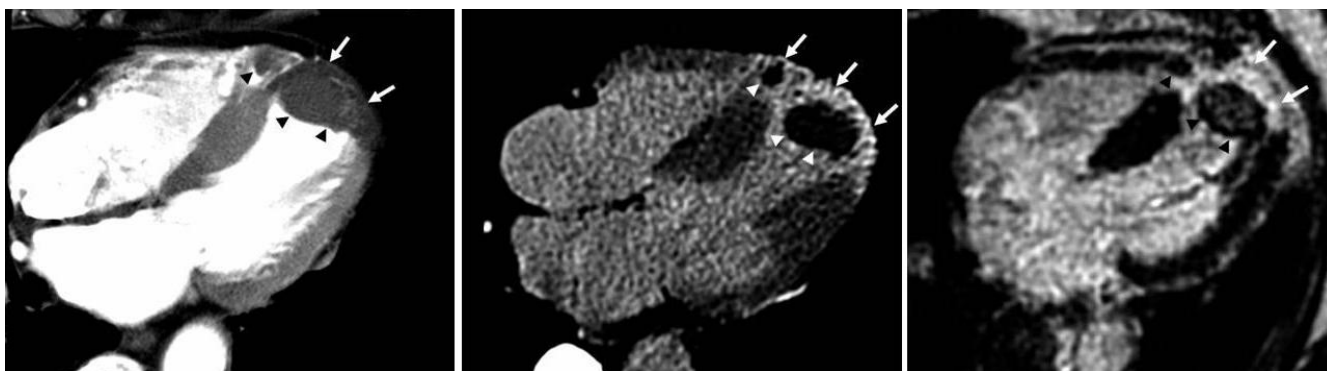


Figure 2

4-chamber view reformat from arterial phase MSCT reveals a perfusion deficit of the left ventricular apex (A). The corresponding late-phase MSCT image presents the delayed myocardial contrast enhancement in the apical-anterior and septal segments of the left ventricle and the right ventricular apex (B; arrows). Left and right ventricular thrombi are shown (arrowheads). Delayed-enhanced MR image confirms the presence myocardial infarction (arrows) and ventricular thrombi (arrowheads) (C).

Abbreviations

CAD: coronary artery disease; CK: creatine kinase; CT: Computed Tomography; ECG: electrocardiogram; LAD: left anterior descending branch of the left coronary artery; MR: magnetic resonance; MSCT: multislice spiral computed tomography; T: Troponin; U: units.

Competing interests

The authors declare that they have no competing interests.

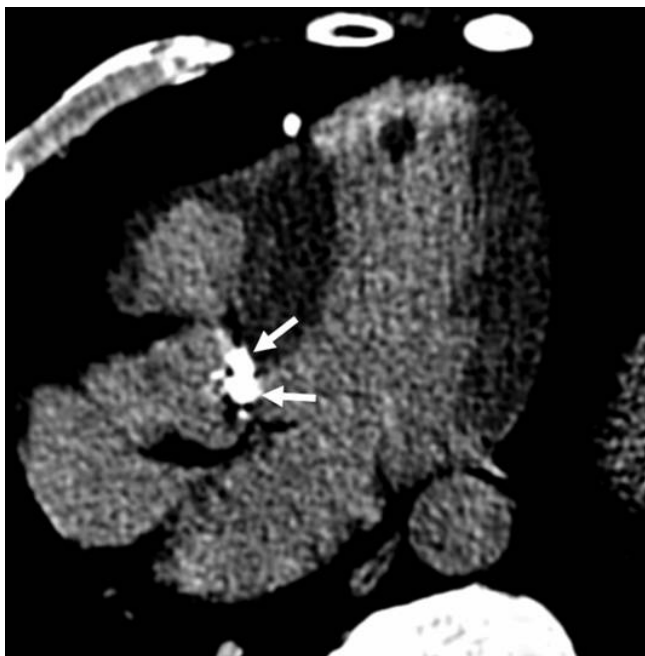

Figure 3

Aortic valve calcifications (arrows) indicate the presence of aortic valve stenosis.

Authors' contributions

AHM analyzed and interpreted cardiac CT data and reviewed the relevant literature. AMS was the responsible cardiologist and reviewed the relative literature. All authors have read and approved the final version of the manuscript.

Consent

Written informed consent was obtained from the patient for publication of this case report and accompanying images. A copy of the written consent is available for review by the journal's Editor-in-Chief.

References

1. Mahnken AH, Mühlenbruch G, Gunther RW, Wildberger JE, Cardiac CT: **coronary arteries and beyond.** *Eur Radiol* 2007, **17**:994-1008.
2. Hoffmann U, Nagurney JT, Moselewski F, Pena A, Ferencik M, Chae CU, Cury RC, Butler J, Abbara S, Brown DF, Manini A, Nichols JH, Achenbach S, Brady TJ: **Coronary multidetector computed tomography in the assessment of patients with acute chest pain.** *Circulation* 2006, **114**:2251-2260.
3. Rubinshtein R, Halon DA, Gaspar T, Jaffe R, Karkabi B, Flugelman MY, Kogan A, Shapira R, Peled N, Lewis BS: **Usefulness of 64-slice cardiac computed tomographic angiography for diagnosing acute coronary syndromes and predicting clinical outcome in emergency department patients with chest pain of uncertain origin.** *Circulation* 2007, **115**:1762-1768.
4. Goldstein JA, Gallagher MJ, O'Neill WW, Ross MA, O'Neil BJ, Raff GL: **A randomized controlled trial of multi-slice coronary computed tomography for evaluation of acute chest pain.** *J Am Coll Cardiol* 2007, **49**:863-871.
5. Mahnken AH, Koos R, Katoh M, Wildberger JE, Spuentrup E, Buecker A, Günther RW, Kühl HP: **Assessment of myocardial viability in reperfused acute myocardial infarction using 16-slice computed tomography in comparison to magnetic resonance imaging.** *J Am Coll Cardiol* 2005, **45**:2042-2047.
6. Hendel RC, Patel MR, Kramer CM, Poon M, Hendel RC, Carr JC, Gerstad NA, Gillam LD, Hodgson JM, Kim RJ, Kramer CM, Lesser JR, Martin ET, Messer JV, Redberg RF, Rubin GD, Rumsfeld JS, Taylor AJ, Weigold WG, Woodard PK, Brindis RG, Hendel RC, Douglas PS, Peterson ED, Wolk MJ, Allen JM, Patel MR, American College of Cardiology Foundation Quality Strategic Directions Committee Appropriateness Criteria Working Group; American College of Radiology;

Society of Cardiovascular Computed Tomography; Society for Cardiovascular Magnetic Resonance; American Society of Nuclear Cardiology; North American Society for Cardiac Imaging; Society for Cardiovascular Angiography and Interventions; Society of Interventional Radiology: **ACCF/ACR/SCCT/SCMR/ASNC/NASCI/SCAI/SIR 2006 appropriateness criteria for cardiac computed tomography and cardiac magnetic resonance imaging: a report of the American College of Cardiology Foundation Quality Strategic Directions Committee Appropriateness Criteria Working Group, American College of Radiology, Society of Cardiovascular Computed Tomography, Society for Cardiovascular Magnetic Resonance, American Society of Nuclear Cardiology, North American Society for Cardiac Imaging, Society for Cardiovascular Angiography and Interventions, and Society of Interventional Radiology.** *J Am Coll Cardiol* 2006, **48**:1475-1497.

Publish with **BioMed Central** and every scientist can read your work free of charge

"BioMed Central will be the most significant development for disseminating the results of biomedical research in our lifetime."

Sir Paul Nurse, Cancer Research UK

Your research papers will be:

- available free of charge to the entire biomedical community
- peer reviewed and published immediately upon acceptance
- cited in PubMed and archived on PubMed Central
- yours — you keep the copyright

Submit your manuscript here:
http://www.biomedcentral.com/info/publishing_adv.asp

