



Contents lists available at ScienceDirect

International Journal of Surgery Case Reports

journal homepage: www.casereports.com

Yersinia pseudotuberculosis infection intractable by antibiotics: A rare case report



Jiro Kimura*, Kiyoshi Sasaki

Department of Pediatric Surgery, Kochi Health Sciences Center, 2125-1, Ike, Kochi 781-8555 Japan

ARTICLE INFO

Article history:

Received 23 December 2015
Received in revised form 6 February 2016
Accepted 28 February 2016
Available online 4 March 2016

Keywords:

Yersinia pseudotuberculosis
Ileocectomy
Intra-abdominal abscess

ABSTRACT

INTRODUCTION: Yersinia pseudotuberculosis infection is usually cured spontaneously or with administration of antibiotics.

PRESENTATION OF CASE: The patient is a twelve-year-old boy with right lower quadrant pain who had enterocolitis one month previously. Contrast-enhanced abdominal computed tomography showed a distended and edematous ileum and an intra-abdominal abscess adjacent to the mesentery with a normal appendix. The patient's general condition did not improve with antibiotics, so an ileocectomy was performed.

DISCUSSION: Yersinia pseudotuberculosis infection requiring an operation is rare. In our case, antibiotics were not effective in treating the abscess therefore surgery was required. An early diagnosis using serological studies, ultrasound of the abdomen, and fecal culture, with appropriate administration of antibiotics, may have avoided the need for surgery. Considering YP infection as a differential diagnosis is therefore important when encountering patients with enterocolitis, especially with right lower quadrant pain. Early diagnosis may assist in avoiding unnecessary operations.

CONCLUSION: Diagnosis of YP infection may be missed or delayed because it is rare and difficult to detect, and must be distinguished from appendicitis. Although most YP infections are self-limiting, some rare cases will require surgery, therefore early diagnosis is essential.

© 2016 The Authors. Published by Elsevier Ltd. on behalf of IJS Publishing Group Ltd. This is an open access article under the CC BY-NC-ND license (<http://creativecommons.org/licenses/by-nc-nd/4.0/>).

1. Introduction

Yersinia species are Gram-negative coccobacilli and are facultative anaerobes [1]. Yersinia pseudotuberculosis (YP) is distributed worldwide but occurs mainly in cooler climates [2]. The most important reservoirs of YP are rodents, lagomorphs and birds. YP infection occurs after oral ingestion of raw pork, well water, feces from dogs or cats or other contaminated materials. YP infection is rare in humans. All YP isolates can be considered pathogenic and in rare cases can cause digestive symptoms [3]. There are many case reports of YP infection, however cases in which an operation is required are rare. We report here a case of YP infection requiring ileocectomy.

2. Case presentation

A 12-year-old boy was admitted to another hospital for vomiting and fever. His symptoms were relieved after five days of intravenous antibiotics and he was discharged. One month

later he presented to our hospital with severe abdominal pain. Physical examination revealed tenderness limited to McBurney's point without muscular defense or rebound tenderness. Laboratory investigations showed elevated white blood cell count ($12,350 \text{ cells/mm}^3$), and C-reactive protein (4.46 mg/dl). Contrast-enhanced abdominal computed tomography (CT) showed wall thickening in the enhanced terminal ileum and fluid collection. The wall at the ventral side of the ascending colon was also contrast-enhanced (Fig. 1). This suggested a diagnosis of terminal ileitis with an ileocecal abscess.

Antibiotic therapy with cefmetazole and amikacin was administered. Fecal culture was negative, and though the abdominal pain improved, it did not disappear completely. On hospital day nine, white blood cell count and C-reactive protein became elevated again. Contrast-enhanced abdominal CT showed that the terminal ileum remained enhanced with fluid collection and the mesentery was also enhanced. It was decided that an operation was required. Laparotomy showed an edematous ileum and ascending colon, with an abscess attached to the ascending colon and some ileocecal lymphadenopathy (Fig. 2). Ileocectomy and ileocolonic anastomosis were performed. Microbiological results from the abscess detected YP. Histopathological examination of lymph nodes showed granulomas with follicle hyperplasia, which were compatible with YP infection (Fig. 3).

* Corresponding author.

E-mail addresses: me17022@s.okadai.jp (J. Kimura), 2kssk2@mail.bbexcite.jp (K. Sasaki).

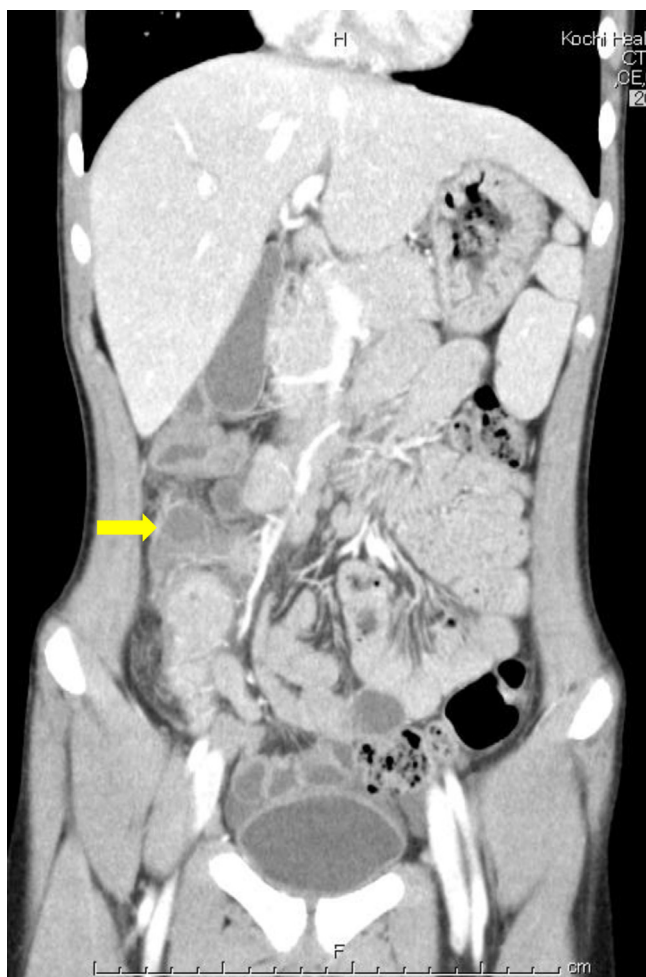

Fig. 1. Preoperative findings. Coronal view of contrast-enhanced computed tomography revealed wall thickening of the well enhanced terminal ileum and fluid collection with a contrast-enhanced wall at the ventral side of the ascending colon.

3. Discussion

YP causes ileitis and mesenteric lymphadenitis by invading the Peyer's patches in the terminal ileum [4]. Mesenteric lymphadenitis is one of the most common presentations of YP infection and involves abdominal pain or appendicitis-like symptoms [5]. The illness usually lasts from one to three months, but symptoms may continue for several more months [6]. This patient had also had enterocolitis one month prior to admission to our hospital. The infection may have been latent until the operation, however we have no evidence regarding the possible source of the organism. The patient was first referred to us for suspected appendicitis.

YP infection is confirmed in the laboratory using serological tests, culture studies, polymerase chain reaction, and histopathological examination [7]. Pathological features are determined by observing the infiltration of various inflammatory cells, including lymphocytes and histiocytes, into necrotic granulomatous mucosa with reactive lymphoid hyperplasia [8].

Most YP infections are self-limiting [7,8] and do not require antibiotic therapy. However, in younger or immunosuppressed patients who are critically ill, beta-lactam antibiotic therapy may be prudent [7].

Some case reports describe the need for surgery because of intestinal obstruction [7], ischemic colitis [9], colonic perforation [10], severe gastrointestinal bleeding and intussusception [11].

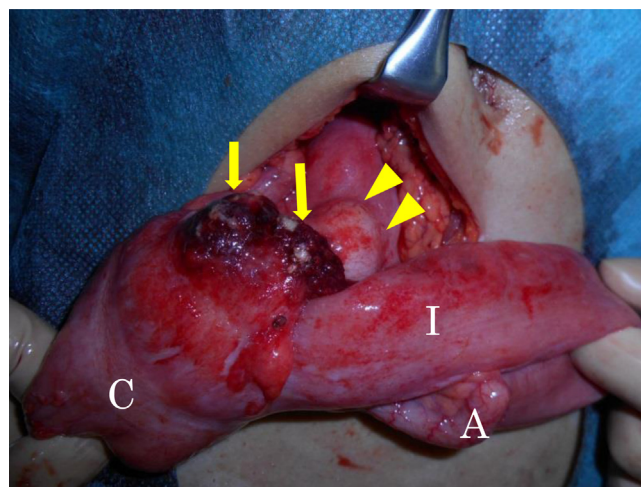


Fig. 2. Operative findings. Laparotomy showed an edematous ileum and ascending colon, an abscess attached to the ascending colon and ileocecal lymphadenopathy. A, appendix; C, cecum; I, ileum; arrow, abscess; arrowhead, lymphadenopathy.

However, there are many cases misdiagnosed with appendicitis in which a laparotomy was performed [5]. Jelloul et al. insisted that the diagnosis should be confirmed by abdominal ultrasound (alternatively CT or Magnetic Resonance Imaging) and serological studies to avoid unnecessary surgery [12]. Furthermore, Bertelli et al. reported that specific microbiological testing for YP should be requested to avoid unnecessary investigations or surgery if the duration of pain is longer than usual [13]. In our case, antibiotics were not effective in treating the abscess therefore surgery could not be avoided. If an early diagnosis could have been achieved using serological studies, ultrasound of the abdomen, and fecal culture, and appropriate antibiotics were administered, surgery may have been avoided. Considering YP infection as a differential diagnosis is therefore important when we encounter patients with enterocolitis, especially with right lower quadrant pain. Early diagnosis may assist in avoiding unnecessary operations.

4. Conclusion

Diagnosis of YP infection may be missed or delayed because it is rare and difficult to detect, and must be distinguished from appendicitis. Although most YP infections are self-limiting, some rare cases will require surgery, therefore early diagnosis is essential.

Conflicts of interest

No conflict of interest.

Funding

No funding.

Ethical approval

No approval is required for this case report.

Consent

Consent from the patient has been obtained.

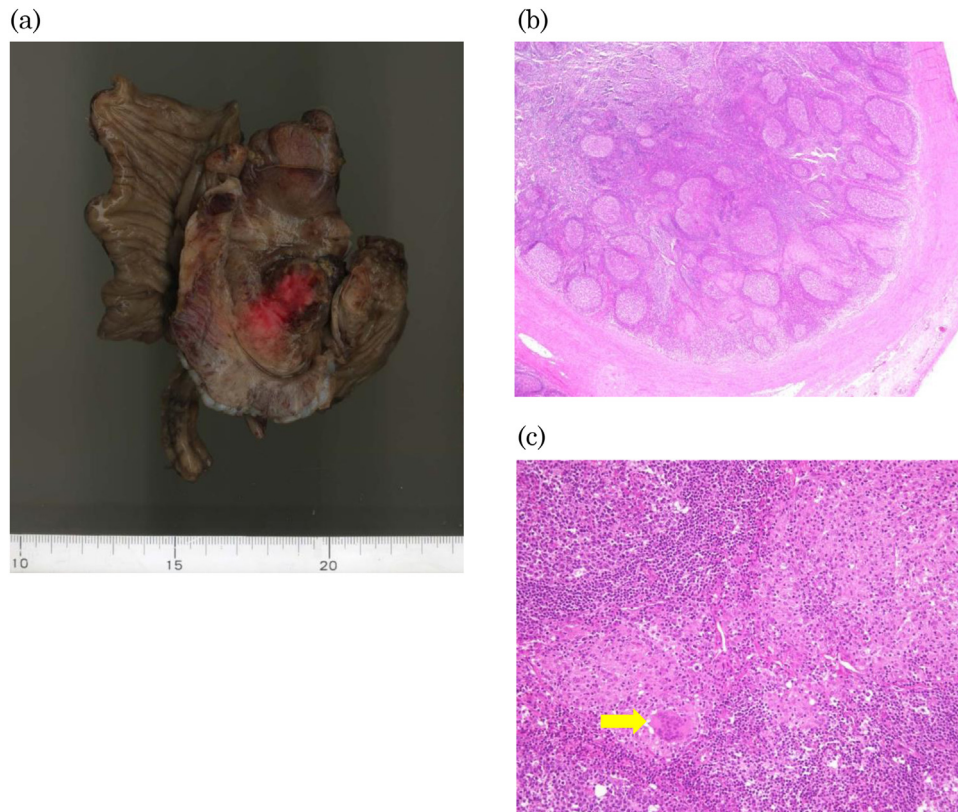


Fig. 3. Macroscopic findings and results of histopathological examination. Macroscopic findings from the resected specimen (a). Histopathological examination of lymph nodes showed granulomas with follicle hyperplasia (H.E. stain, objective; $\times 4$) (b). Granulomas consisted of various inflammatory cells including lymphocytes and polymorphonuclear cells (arrow) (H.E. stain, objective; $\times 20$) (c).

Author contribution

Jiro Kimura (JK) and Kiyoshi Sasaki (KS) made, analyzed, and interpreted our patient’s imaging examinations. JK and KS demonstrated surgery for our patient. The manuscript was prepared by JK under the supervision of KS. All authors read and approved the final manuscript.

References

- [1] E.J. Bottone, *Yersinia enterocolitica*: the charisma continues, *Clin. Microbiol. Rev.* 10 (2) (1997) 257–276.
- [2] J.P. Nuorti, T. Niskanen, S. Hallanvuoto, J. Mikkola, E. Kela, M. Hatakka, et al., A widespread outbreak of *Yersinia pseudotuberculosis* O:3 infection from iceberg lettuce, *J. Infect. Dis.* 189 (5) (2004) 766–774.
- [3] Bockemuhl J, Roggentin P, Intestinal yersiniosis, Clinical importance, epidemiology, diagnosis, and prevention, *Bundesgesundheitsblatt, Gesundheitsforschung, Gesundheitsschutz* 47(7) (2004) 685–691.
- [4] R. Dessein, M. Gironella, C. Vignal, L. Peyrin-Biroulet, H. Sokol, T. Secher, et al., Toll-like receptor 2 is critical for induction of Reg3 beta expression and intestinal clearance of *Yersinia pseudotuberculosis*, *Gut* 58 (6) (2009) 771–776.
- [5] R. Terti, R. Vuento, P. Mikkola, K. Granfors, A.L. Makela, A. Toivanen, Clinical manifestations of *Yersinia pseudotuberculosis* infection in children, *Eur. J. Clin. Microbiol. Infect. Dis.* 8 (7) (1989) 587–591.
- [6] K. Jalava, M. Hakkinen, M. Valkonen, U.M. Nakari, T. Palo, S. Hallanvuoto, J. Ollgren, A. Siitonen, J.P. Nuorti, An outbreak of gastrointestinal illness and erythema nodosum from grated carrots contaminated with *Yersinia pseudotuberculosis*, *J. Infect. Dis.* 194 (9) (2006) 1209–1216.
- [7] K.G. Srinivasa, J.V. Vidhya, T.M. Manohar, M. Naik, Right hemicolectomy for intestinal obstruction due to *Yersinia pseudotuberculosis*: a histopathological surprise, *Indian J. Surg.* 75 (Suppl. 1) (2013) 214–216.
- [8] O. Imataki, M. Uemura, K. Matsumoto, N. Ishibashi, *Yersinia pseudotuberculosis* enterocolitis mimicking enteropathic gammadelta T-cell lymphoma with abnormal clonality, *BMC Infect. Dis.* 14 (2014) 42.
- [9] A.G. Deacon, A. Hay, J. Duncan, Septicemia due to *Yersinia pseudotuberculosis*—a case report, *Clin. Microbiol. Infect.* 9 (11) (2003) 1118–1119.
- [10] A. Gaulier, F. Poulton, The place of anatomo-pathological study in the diagnosis of enterocolitis complicated by *Yersinia pseudo-tuberculosis*, *Ann. Pathol.* 3 (4) (1983) 301–305.
- [11] E. Bulbuloglu, H. Ciralik, B. Kantarceken, A. Cetinkaya, M. Gul, F. Ezberci, *Yersinia pseudotuberculosis* colitis presented with severe gastrointestinal bleeding, *Turk. J. Gastroenterol.* 21 (2) (2010) 179–182.
- [12] L. Jelloul, B. Fremont, J.F. Dyon, R.L. Orme, J.M. Babut, Mesenteric adenitis caused by *Yersinia pseudotuberculosis* presenting as an abdominal mass, *Eur. J. Pediatr. Surg.* 7 (3) (1997) 180–183.
- [13] L. Bertelli, R. Masetti, G. Bardasi, M. Maretti, T. Gargano, I. Corsini, et al., Two cases of abdominal pain in children with mesenteric lymphadenitis due to *Yersinia pseudotuberculosis* infection, *J. Pediatr.* 165 (2) (2014) 411.

Open Access

This article is published Open Access at sciedirect.com. It is distributed under the [IJSCR Supplemental terms and conditions](#), which permits unrestricted non commercial use, distribution, and reproduction in any medium, provided the original authors and source are credited.