



Detection of Ureteral Stump Transitional Cell Carcinoma, Presenting as Bone Metastases from Unknown Primary by 18F-FDG PET/CT: A Case Report with Review of Literature

Petya N. Nikolova¹ Valeria H. Hadzhiyska¹ Kiril B. Mladenov¹ Mihaela G. Ilcheva¹ Stefani Veneva¹
Svetla E. Dineva¹ Boris S. Mladenov²

¹ Clinic of Nuclear Medicine, ¹Clinic of Imaging Diagnostics, University Hospital "Alexandrovska," Sofia, Bulgaria

² Clinic of Urology, UMHATEM "N.I. Pirogov," Sofia, Bulgaria

Address for correspondence Petya N. Nikolova, MD, PhD, Georgi Sofiiski Str. 1, Sofia - 1431, Bulgaria (e-mail: petia.nn@abv.bg).

Indian J Radiol Imaging 2021;31:1065–1069.

Abstract

A case of occult carcinoma of the ureteral stump is reported. A 67-year-old man presented with pain syndrome due to multiple bone metastases from unknown primary origin detected by previous imaging studies as magnetic resonance imaging, whole body contrast-enhanced computed tomography (CT), and technetium-99m methyl-diphosphonate bone scan. He had undergone a right nephrectomy for a benign disease previously. He was referred to our department for an 18F-fluoro-2-deoxy-D-glucose (18F-FDG) positron emission tomography/computed tomography (PET/CT) to help localize possible primary tumor. Our observations in this case show that the use of 18F-FDG PET/CT successfully and more accurately evaluated the overall tumor burden and led to a rapid decision of an adequate therapeutic approach.

Keywords

- ▶ 18F-FDG PET/CT
- ▶ bone metastases
- ▶ cancer of unknown primary
- ▶ ureteral stump

Introduction

Bone metastases are the third most frequent site for metastatic carcinoma after the lung and liver. Prostate and lung cancer are responsible for the majority of the skeletal metastases in men. However, among patients with bone metastases, 22.6 to 30% have no evidence of the primary tumor at presentation. Moreover, patients with skeletal metastases from occult carcinomas show a high incidence of spinal metastases, cord compression, and pathological fractures, and a significantly shorter survival compared with bone lesions secondary to known primaries. In cases of skeletal metastasis of unknown primary, the diagnosis of the cancer of origin is difficult and clinicians often take a long time to identify the primary site.^{1,2}

Urothelial cancers are one of the most common malignancies (ranked fourth after prostate, lung, and colon cancer) of all cancers in Europe. Unlike bladder tumors, which account for nearly 90 to 95% of urothelial carcinomas, tumors of upper urinary tract (UUT) are less common. The peak incidence of these neoplasms is between 70 and 80 years, with three times higher incidence in males than in females.³ In 73%, transitional cell carcinoma (TCC) is localized in the distal ureter, 24% occur in the middle ureter, and only 3% in the proximal ureter. UUT-TCCs are spread by direct invasion and by the lymphatic pathway (with a predisposition to the retroperitoneal area) more commonly than hematogenously, owing to the thin wall and the rich lymphatic drainage of the ureter.⁴ However, in the presence of metastatic

published online
January 10, 2022

DOI <https://doi.org/10.1055/s-0041-1741101>.
ISSN 0971-3026.

© 2022. Indian Radiological Association. All rights reserved.
This is an open access article published by Thieme under the terms of the Creative Commons Attribution-NonDerivative-NonCommercial-License, permitting copying and reproduction so long as the original work is given appropriate credit. Contents may not be used for commercial purposes, or adapted, remixed, transformed or built upon. (<https://creativecommons.org/licenses/by-nc-nd/4.0/>)
Thieme Medical and Scientific Publishers Pvt. Ltd., A-12, 2nd Floor, Sector 2, Noida-201301 UP, India

disease, the most commonly involved organs are the lung, bone, liver, and brain.⁵

Primary ureteral carcinoma is a rare cancer that accounts for ~1% of all malignancies of the upper genitourinary tract. In 90% of the cases, the most common histological type is TCC. De novo malignant tumors in ureteral stump are extremely rare, with limited number of clinical cases reported in the literature so far.⁶

Here, we present an unusual case of occult urothelial carcinoma in a remnant ureter, which manifested as multiple bone metastasis.

Case Report

We present a case of a 67-year-old man who was referred for 18F-fluorodeoxyglucose positron emission tomography combined with computed tomography (18F-FDG PET/CT) with a diagnosis of multiple bone metastases from cancer of unknown primary (CUP). Patient's clinical findings and physical examination revealed nonspecific bone pain syndrome and anamnesis of nephrectomy for a benign disease 7 years ago. Reduced medical data were obtained due to interinstitutional and legislation difficulties. The initial imaging evaluation of the patient was performed with magnetic resonance imaging (MRI), whole body contrast-enhanced computed tomography (CECT), and technetium-99m methyldiphosphonate (Tc-99m MDP) bone scan. His digital records were unavailable. Nevertheless, MRI of the lumbar region showed metastatic lesions in the body of L1, L3, and L4 vertebrae, together with retroperitoneal lymphadenomegaly. The Tc-99m MDP bone scan revealed multiple foci with increased uptake of osteotropic radiopharmaceutical in axial and appendicular skeleton. The full-body CECT failed to display any additional abnormally findings to those already mentioned—a suspicion of bone metastasis in L1, L3, and L4 (differential diagnosis: degenerative disease, fibrous dysplasia). There were obviously discrepancies and uncertainty among different imaging techniques in detection of all secondary bone lesions. MRI and CT imaging show a similar number of pathologic bone findings, whereas whole body CT and bone scintigraphy (BS) have significant differences in the detection of all secondary foci with higher accuracy in favor of BS. None of the conventional imaging techniques, in which the primary tumor area was included in the scope of the study (MRI and CT), were able to detect any pathologic changes suggestive of primary location. Whole body 18F-FDG PET/CT was performed to confirm the exact extent of metastatic foci, provide guidance for conducting a minimally invasive biopsy, and possibly identify a primary lesion.

The result of contrast-enhanced 18F-FDG PET/CT demonstrated intense FDG uptake in the right ureter stump, corresponding to a solid formation in the lumen of the pelvic segment of the ureter by CT, dissemination in mediastinal and retroperitoneal lymph nodes and multiple bone metastases (→ Fig. 1). In conclusion, a suggestion of probable primary tumor process in the right ureteral stump with dissemination in supra- and subdiaphragmatic lymph nodes and generalized bone lesions was established. Under a

diagnosis of a primary ureteral stump tumor based on the PET/CT scan, the latter was excised. A histopathology examination showed a papillary urothelial carcinoma (T3N1M1-IV clinical stage). The patient received postoperative chemotherapy and palliative radiation. He passed away 7 months later.

Literature Review and Discussion

CUP represents a heterogeneous group of metastatic tumors for which medical history, physical examination, and standardized diagnostic workup fail to identify the site of the cancer's origin at the time of diagnosis. Its fundamental characteristics are aggressiveness, early dissemination, unpredictable metastatic pattern, and silent primary tumor. Its clinical course is usually determined by symptoms and signs related to metastasis. Multiple sites of involvement are observed in more than 50% of patients.⁷ Bone is the third most common site of metastatic disease by CUPs, after lymph nodes and lungs. According to the literature data, metastases of unknown primary origin are equivalent to 3 to 4% of all cancer patients, with 10 to 15% of them having skeletal locations. Skeletal metastases in men raise the suspicion of prostate or lung carcinoma. Although patterns of metastases can suggest clues as to the primary tumor, occult carcinomas could be clinically different from their respective manifest forms: with regard to skeletal involvement, the incidence of bone metastases from pulmonary carcinoma is much lower if the primary is occult (4%) than if it is known (30–50%).^{1,7} Following cases of pulmonary origin, bone metastases from undiagnosed renal cell carcinoma increased to 12%, more than those of prostate 10%, whereas in occult thyroid carcinomas are extremely rare (3%).⁸ Despite the significant improvement in diagnostic methods, including imaging, pathological testing, and molecular markers, management of CUP can be challenging because of the heterogeneity of this condition and its presentation. Approximately, 10% of patients present with symptoms secondary to metastasis, which can be diverse, ranging from lymphadenopathy to bone pain due to skeletal metastasis. Practically, all malignant neoplasms can metastasize in bone, since the skeleton is a common metastatic site for several visceral carcinomas. The majority of bone metastases originate from the breast, prostate, lungs, and kidneys. Usually, metastatic disease occurs late in the disease process, long after the primary disease has been identified. However, 3 to 4% of patients with metastatic carcinoma have an unknown primary site at the time of presentation. Bone metastases are mostly multiple and associated with severe bone pain as it is in our case.^{9,10}

To date, elective use of PET/CT is currently limited to patients with squamous-cell lymphadenopathy of the neck and solitary metastatic lesion. Apart from the above indications, the role of PET/CT remains unclear. Nevertheless, there are data from various studies, mainly retrospective, that the use of FDG PET/CT may be beneficial in extracervical metastases from an unknown primary as well. In a review of Moller et al,¹¹ the primary tumor was detected by means of FDGPET/CT in 39% of the patients with extracervical CUP

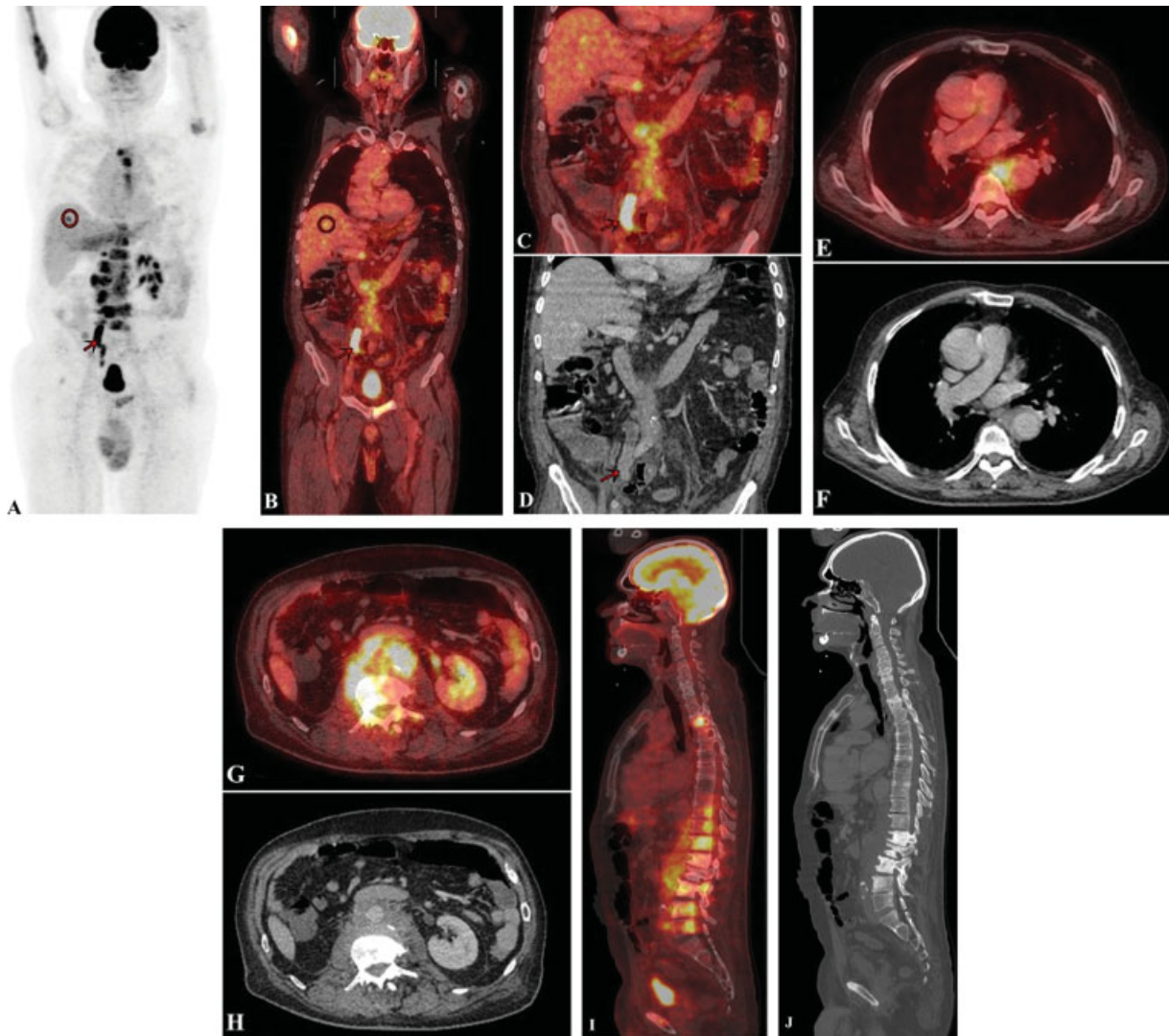


Fig. 1 Maximum intensity projection and ¹⁸F-fluoro-2-deoxy-D-glucose positron emission tomography/computed tomography (¹⁸F FDG PET/CT) images (A and B) show increased FDG uptake in mediastinal, retroperitoneal lymph nodes, right ureter (red arrow), multiple skeleton lesions, and suspicion for malignancy focus in the liver (red circle). Coronal FDG PET/CT image (C) revealed an intense FDG uptake in the right ureteral stump corresponding to a solid soft-tissue formation in the lumen on the contrast-enhanced computed tomography (CECT) component (D), compatible with primary tumor. Axial FDG PET/CT (E and G) slices demonstrate enlarged and hypermetabolic lymph nodes in mediastinal and retroperitoneal region, which presented as an ill-defined infiltrative lymphadenopathy on the CECT images (F and H). PET/CT sagittal image (I) of multiple FDG-avid lesions in axial the skeleton, corresponding to osteosclerotic bone metastasis on the CT (J).

site. The pooled estimates of the sensitivity, specificity, and accuracy of FDG PET/CT in the detection of the primary tumor site were 87, 88, and 88%, respectively.

Urothelial carcinoma, which is also known as TCC, is a malignant tumor that arises from the transitional epithelium. Urothelial carcinoma is the most common malignancy in the urinary system. It mostly invades the tissues and organs around the primary focus and rarely metastasizes to distant organs. Bone (~35%) is the most common distant metastatic organ in advanced urothelial carcinoma, and the vertebrae are the most common site (~40%) in all cases of bone metastasis,¹² whereas the reappearance of a primary malignant tumor of the ureteral stump after nephrectomy for a benign disease is extremely rare clinical situation. A primary tumor in the ureteric stump may be defined as one occurring in the residual ureter following nephrectomy or partial

nephroureterectomy, where there has been no tumor of renal parenchyma, pelvis, or excised upper ureter.¹³ The incidence of TCC developing de novo in these stumps approaches 10%, as most of the data are case based.^{6,14,15} In 1952, Loeff and Casella were the first to report a case of primary squamous cell carcinoma in the ureteric stump 14 years after nephrectomy for hydronephrosis and hydro-ureter.¹⁶ In another review of Mullen and Kovacs on 21 cases of ureteral stump carcinoma, the interval between nephrectomy and ureteral stump carcinoma was reported as 12 years. In total, 71% of the patients had TCC, 24% had squamous cell carcinoma, and 5% had adenocarcinoma.¹⁷ In patients with a prior diagnosis of a bladder tumor, urine reflux into the ureteral stump may be responsible for the ureteral stump tumor, possibly due to tumor implantation. However, in patients with no history of urothelial carcinoma, the etiology

of a ureteral stump tumor is unclear. There are several etiologic factors to be considered in the pathogenesis of genitourinary malignant tumors including chronic inflammation, leukoplakia, and carcinogenic substances. No matter the cause, it is essential to remember the ureteric stump remains a part of the urinary tract and is just as likely to become diseased or symptomatic.^{14,18} Hematuria is the major presenting symptom in most of the cases, in contrast to our case, where metastatically induced bone pain was the leading symptom. Diagnostic difficulty may arise due to the fact that the examiner's attention is drawn away from the side of the nephrectomy. Clinically, the remaining ureteral stump does not receive routine examination during follow-up. Retrograde urography, CT scan, and magnetic resonance are imaging that may provide diagnostic information.^{19,20} However, in our case, none of conventional techniques was able to detect the primary tumor. This could be explained by the fact that the identification of pathological lesions is highly dependent on abnormal contrast enhancement, which in some cases may be very faint or absent, as a result of which lesions may be missed. Another potential drawback is the large amounts of image data obtained in a single whole-body CT examination, which makes image interpretation complex, time-consuming, and subtle pathological findings may be overlooked. Therefore, sensitivity of CT for the detection of the unknown primary tumor may be compromised. In contrast to conventional CT and MRI, FDG PET offers high lesion-to-background contrast, making it a potentially more sensitive imaging modality.²¹

Our observations in this case also indicate that PET/CT could more accurately identify lymphogenous spread, especially when presented as infiltrative changes. Although, according to European Society for Medical Oncology (ESMO) guidelines,²² the systematic application of 18F-FDG PET/CT in the evaluation of occult tumors with extracervical metastases is limited, in this specific case, 18F-FDG PET/CT has been proven to be a valuable diagnostic tool due to its complex nature (accurate anatomic localization of altered metabolic tumor tissue) and correctly detected primary tumor and all malignant lesions compared with the staging whole-body CECT of the patient.

Conclusion

The clinical case presented by us is an extremely rare scenario of TCC of the ureteral stump, presenting as bone metastases from an unknown primary. The findings of our study clearly demonstrate that FDG PET/CT scan is a useful and noninvasive diagnostic tool in detecting an unidentified primary tumor site, as well as the exact tumor volume of metastatic lesions with high sensitivity. PET/CT may play a major role as an alternative imaging tool in diagnostic workup of patients with CUP, leading to complete staging and more adequate therapeutic approach.

Declaration of Patient Consent

The authors certify that they have obtained all appropriate patient consent forms. In the form, the patient(s) has/have

given his/her/their consent for his/her/their images and other clinical information to be reported in the journal. The patients understand that their names and initials will not be published and due efforts will be made to conceal their identity, but anonymity cannot be guaranteed.

Financial Support and Sponsorship

Nil.

Conflicts of Interest

There are no conflicts of interest.

References

- Piccioli A, Maccauro G, Spinelli MS, Biagini R, Rossi B. Bone metastases of unknown origin: epidemiology and principles of management. *J Orthop Traumatol* 2015;16(02):81–86
- Takagi T, Katagiri H, Kim Y, et al. Skeletal metastasis of unknown primary origin at the initial visit: a retrospective analysis of 286 cases. *PLoS One* 2015;10(06):e0129428
- Rouprêt M, Zigeuner R, Palou J, et al. European guidelines for the diagnosis and management of upper urinary tract urothelial cell carcinomas: 2011 update. *Eur Urol* 2011;59(04):584–594
- Vikram R, Sandler CM, Ng CS. Imaging and staging of transitional cell carcinoma: part 2, upper urinary tract. *AJR Am J Roentgenol* 2009;192(06):1488–1493
- Lam JS, Leppert JT, Figlin RA, Belldegrin AS. Surveillance following radical or partial nephrectomy for renal cell carcinoma. *Curr Urol Rep* 2005;6(01):7–18
- Satheesan B, Jayanand S, Kathiresan N. Ureteral stump transitional cell carcinoma after radical nephrectomy: a case report with review of literature. *Urol Ann* 2009;1:64
- Airoidi G. Cancer of unknown primary origin: utility and futility in clinical practice. *Ital J Med* 2012;6:315–326
- Vandecandelaere M, Flipo RM, Cortet B, Catanzariti L, Duquesnoy B, Delcambre B. Bone metastases revealing primary tumors. Comparison of two series separated by 30 years. *Joint Bone Spine* 2004;71(03):224–229
- García Carretero R, Romero Brugera M, Rebollo-Aparicio N, El Bouayadi Mohamed L. Primary bone metastasis as first manifestation of an unknown primary tumour. *BMJ Case Rep* 2015;2015:bcr2015211302
- Taylor MB, Bromham NR, Arnold SE. Carcinoma of unknown primary: key radiological issues from the recent National Institute for Health and Clinical Excellence guidelines. *Br J Radiol* 2012;85(1014):661–671
- Moller AK, Loft A, Berthelsen AK, et al. 18F-FDG PET/CT as a diagnostic tool in patients with extracervical carcinoma of unknown primary site: a literature review. *Oncologist* 2011;16(04):445–451
- Bu K, Shi Z, Lu Y, Zhao J, Li B. An occult urothelial carcinoma with wide multiorgan metastases and its genetic alteration profiling: case report and literature review. *Medicine (Baltimore)* 2019;98(16):e15245
- Wisheart JD. Primary tumour of the ureteric stump following nephrectomy. Presentation of a case and a review of the literature. *Br J Urol* 1968;40(03):344–349
- Malek RS, Moghaddam A, Furlow WL, Greene LF. Symptomatic ureteral stumps. *J Urol* 1971;106(04):521–528
- Park JY, Park J, Ku JH, Kim HH. Transitional cell carcinoma in a remnant ureter after retroperitoneoscopic simple nephrectomy for benign renal disease. *J Korean Med Sci* 2009;24(05):992–994
- Loef JA, Casella PA. Squamous cell carcinoma occurring in the stump of a chronically infected ureter many years after nephrectomy. *J Urol* 1952;67(02):159–163

- 17 Mullen JB, Kovacs K. Primary carcinoma of the ureteral stump: a case report and a review of the literature. *J Urol* 1980;123(01): 113–115
- 18 Tsai S-W, Lin C-M, Lin C-Y, Hsieh T-S. Urothelial carcinoma in a remnant ureter after a radical nephrectomy for renal cell carcinoma: a case report. *Urol Sci* 2013;24:65–68
- 19 Inui M, Yamashita M, Taketa S, Takenaka I, Kakehi Y. Transitional cell carcinoma of the ureteral stump eight years after nephrectomy for benign disease. *Int J Urol* 2002;9(09):515–516
- 20 Pollack HM, Banner MP, Popky GL. Radiologic evaluation of the ureteral stump. *Radiology* 1982;144(02):225–230
- 21 Kwee TC, Basu S, Cheng G, Alavi A. FDG PET/CT in carcinoma of unknown primary. *Eur J Nucl Med Mol Imaging* 2010;37(03): 635–644
- 22 Fizazi K, Greco FA, Pavlidis N, Daugaard G, Oien K, Pentheroudakis GESMO Guidelines Committee. Cancers of unknown primary site: ESMO Clinical Practice Guidelines for diagnosis, treatment and follow-up. *Ann Oncol* 2015;26(Suppl 5):v133–v138