

Smith-magenis syndrome: A rare case report

Rupam Sinha, Harshvardhan Jha, Debarati Deb, Mainak Datta

Department of Oral Medicine and Radiology, Haldia Institute of Dental Sciences and Research, Banbishnupur, Balughata Rd, West Bengal, India

ABSTRACT

Smith-Magenis syndrome is a rare genetic disorder involving multiple body systems, along with mental retardation and sleep disturbances. It is attributed to micro deletion at 17p11.2 chromosome region encoding for RAI1 gene. This article presents a case report of a 7-year-old patient having this rare syndrome along with his genetic analysis.

Keywords: 17p11.2 chromosome, genetic, mental retardation, RAI1 gene, sleep disturbances

Introduction

Smith-Magenis syndrome (SMS) is a complex genetic disorder involving various body systems and also cognitive defects, challenging behaviours, aggressiveness, impulsivity, attention seeking along with sleep defects.^[1] It is an extremely rare syndrome and is often misdiagnosed. Its severity varies from person to person. It is associated with interstitial micro deletion at 17p11.2 chromosome region that includes retinoic acid induced 1 gene (RAI1), which is seen in 90% cases of SMS or point mutation in RAI1 gene, which is seen in 10% cases of SMS.^[2] It is seen in generally 1 in 15,000–25,000 births and was first described in 1982 by Ann C.M. Smith and her colleagues.^[3] The diagnosis of SMS is based on clinical features, along with cognitive and behavioural changes and can be confirmed by detection of an interstitial micro deletion at 17p11.2 chromosome or by molecular genetic testing of RAI1.^[4] This kind of syndrome at times can be difficult to diagnose in normal clinical practice. A general practitioner however should identify

the various signs and symptoms of SMS and accordingly refer them to different experts for the treatment of the various signs and symptoms.

Case Report

A male patient 7 years of age reported to our department of Oral Medicine and Radiology with a chief complaint of pain in upper/lower right and left front and back teeth region.

Upon general examination, it was found that the patient had a broad-square face, short stature, midface hypoplasia, mandibular prognathism [Figures 1 and 2] and strabismus [Figure 3]. Upon communication with the patient it was found that the patient had speech delay, deep hoarse voice along with attention seeking behaviour. His parents also gave a history that communication between them and the child was poor even if they tried hard. The parents also gave history of seizures and sleep disturbance for which the patient was under medication. The developmental milestones were delayed. Upon intraoral examination it was found that multiple teeth were carious in both the upper and lower arch along with constricted maxilla [Figure 4].

We advised the patient to consult a psychiatrist and an ophthalmologist. Along with that an orthopantomogram and a lateral cephalogram was advised.

Address for correspondence: Dr. Debarati Deb,
Department of Oral Medicine and Radiology, Haldia Institute
of Dental Sciences and Research, Banbishnupur, Balughata Rd,
West Bengal, India.
E-mail: debarati1993@gmail.com

Received: 28-06-2021

Revised: 12-10-2021

Accepted: 20-10-2021

Published: 10-03-2022

Access this article online

Quick Response Code:



Website:
www.jfmpc.com

DOI:
10.4103/jfmpc.jfmpc_1279_21

This is an open access journal, and articles are distributed under the terms of the Creative Commons Attribution-NonCommercial-ShareAlike 4.0 License, which allows others to remix, tweak, and build upon the work non-commercially, as long as appropriate credit is given and the new creations are licensed under the identical terms.

For reprints contact: WKHLRPMedknow_reprints@wolterskluwer.com

How to cite this article: Sinha R, Jha H, Deb D, Datta M. Smith-magenis syndrome: A rare case report. J Family Med Prim Care 2022;11:1191-4.

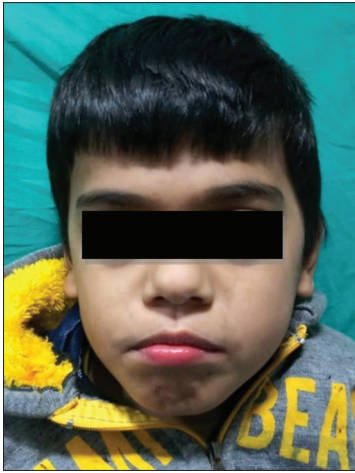

Figure 1: (Front Profile showing broad square face)

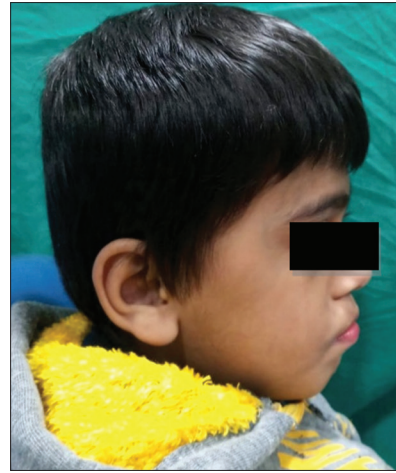

Figure 2: (Side Profile showing midface hypoplasia, mandibular prognathism)

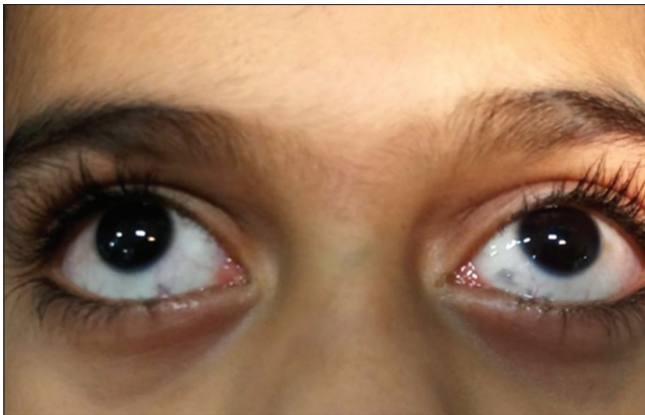

Figure 3: (Strabismus)

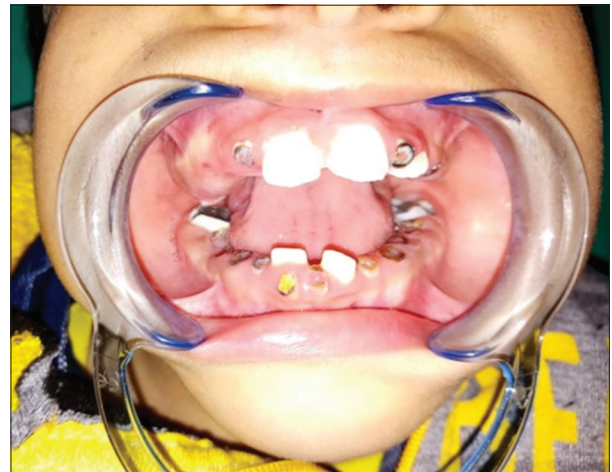

Figure 4: (Intraoral photograph showing multiple carious teeth)

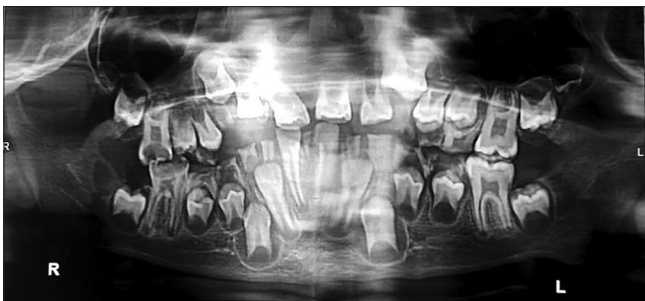

Figure 5: (Orthopantomogram showing Taurodontism in 16 and 26)

Investigations

Upon psychiatric examination it was reported that the patient had speech and motor delay. It was also reported that the developmental milestones were delayed. The communication, orientation and memory were reported to be poor. The I.Q. of the patient was reported to be 59. The final report was given as “Mild Mental Retardation With 50% Disability”.

The ophthalmic examination reported the patient to be having myopia and strabismus.

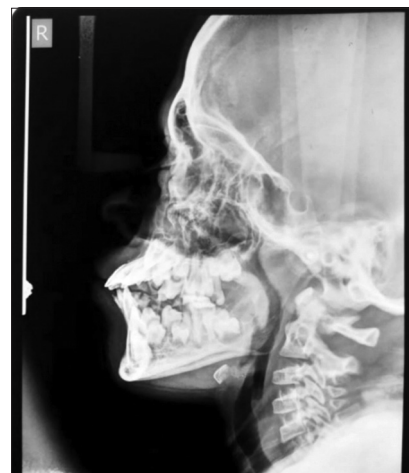

Figure 6: (Lateral cephalogram showing bimaxillary protrusion)

The orthopantomogram showed diffuse, non-homogeneous radiolucency involving pulp along with loss of crown structure in 81,82,83,84,85,71,72,73,74,75. The crown portion of 16

and 26 appeared enlarged and bulbous along with more apical placement of the furcation area. Also, the pulp chamber of 16 and 26 appeared enlarged. These features were suggestive of Taurodontism in 16 and 26 [Figure 5].

The lateral cephalogram along with orthodontic analysis showed bimaxillary protrusion and mid-face hypoplasia [Figure 6].

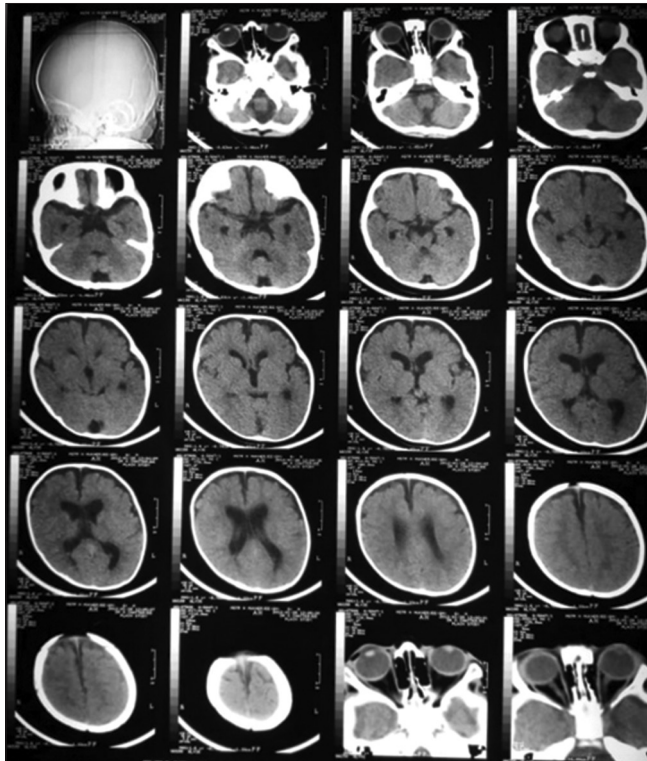


Figure 7: (CT scan of brain showing dilated supratentorial ventricular system with widened extra axial CSF spaces)

The CT scan of brain reported that there was mildly dilated supratentorial ventricular system with widened extra axial CSF spaces, which could be a sequel of atrophic changes secondary to any birth asphyxia/prior ischaemic events [Figure 7].

The MRI scan of brain reported mildly dilated ventricular system with enlarged cisterna magna or retrocerebellar arachnoid cyst. The pineal gland was enlarged and cystic [Figures 8a and b].

The cytogenomic microarray analysis showed a 2.67-Mb deletion involving chromosome 17 within 17p11.2, indicating monosomy for this region. The deletion includes the commonly deleted region associated with Smith-Magenis syndrome and contained 30 OMIM genes including RAI1, a critical gene within this region.

Based on all the clinical features, investigations and cytogenomic microarray analysis we gave a final diagnosis as ‘Smith-Magenis Syndrome’.

Restorative treatments were done in the carious teeth and patient was referred to the paediatrics department for further evaluation.

Discussion

SMS is a rare, multisystem genetic disorder with cognitive and behavioural dysfunctions and sleep disturbance. The clinical features of SMS is variable. In craniofacial/skeletal part it includes brachycephaly, midface hypoplasia, prognathism, tented upper lip, broad square face, synophrys, cleft lip/palate, short stature and scoliosis. In otolaryngologic portion it contains chronic ear infections, hearing loss, hoarse and deep voice.^[5]

The neurological symptoms include variable mental retardation, speech delay, motor delay, hypotonia, seizures by

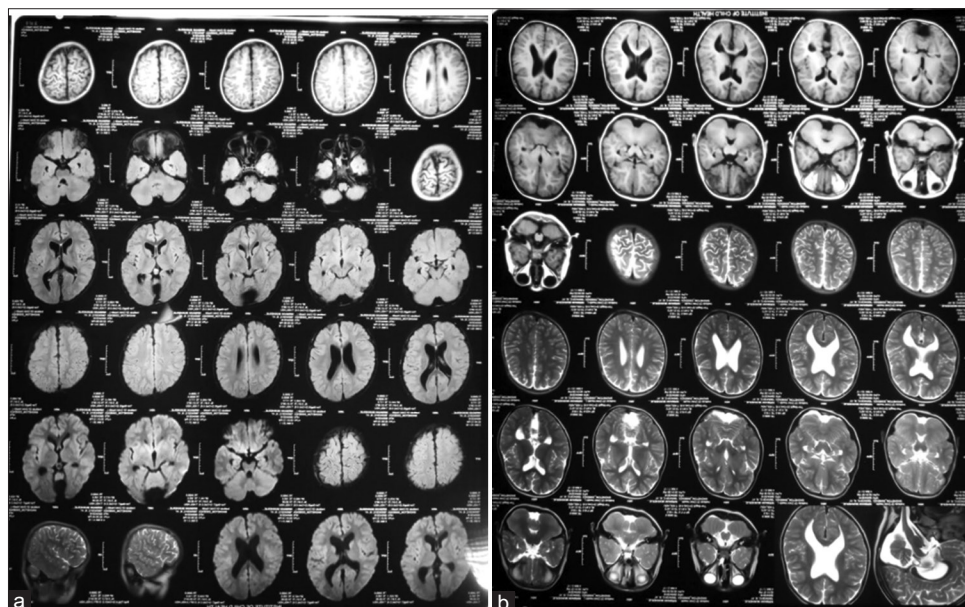


Figure 8: (a and b) (MRI scan of brain showing mildly dilated ventricular system with enlarged cisterna magna)

history, sleep disturbance, attention seeking, head banging, hand biting and so on. The ocular abnormalities included myopia and strabismus. Besides all these, the patient may have dental abnormalities, cardiovascular abnormality, renal abnormality and obesity.^[5]

Out of all these symptoms our patient had broad-square face, short stature, midface hypoplasia, mandibular prognathism, strabismus, deep hoarse voice, speech delay, history of seizures, sleep disturbance, mental retardation, attention seeking behaviour, brachydactyly and dental abnormalities.^[5] Most SMS patients have IQ ranging between 20 and 78 and it decreases as the child ages.^[6] In our patient the IQ was found to be 59 with mental retardation and 50% disability. Sleep disturbances have been reported in 75–100% of SMS cases, which include difficulty in falling asleep, diminished REM sleep, fragmented and short sleep cycles. The abnormal sleep patterns in SMS have been attributed to an inverted circadian rhythm of melatonin.^[7,8]

Diagnosis of SMS is done via its clinical characteristics and any kind of cytogenetic or molecular technique that shows microdeletion in region of 17p11.2 chromosome. Fluorescent *in situ* hybridization (FISH), multiplex ligation-dependent probe amplification (MLPA), real time quantitative PCR (qPCR) are some of the cytogenic and molecular techniques that are used in this regard.^[5,9]

Management of SMS is multifaceted. Primary focus should be on speech and language therapy; to control the aggressive behaviour, behaviour management techniques should be used.^[5] General physician should diagnose this kind of syndrome as early as possible so that symptomatic relief could be given to increase the quality of life. Psychotropic medications have been used to decrease hyperactivity and increase attention.^[7]

Trickett J *et al.*^[10] reported poor sleep quality in SMS and discussed the need to behavioural therapies like nap restriction and pharmacological approaches to improve the sleep quality.

For sleep disturbances treatment with Beta1 antagonist (Acebutolol 10 mg/kg/day) has shown good results.^[11]

Conclusions

Smith-Magenis is a very rare disorder and a clinician must know its clinical features in detail so that this entity isn't misdiagnosed. Even dental diagnosticians should be well aware of these syndromes as patients might come up with just dental issues and *in lieu* the syndrome comes up.

Declaration of patient consent

The authors certify to obtain all the appropriate consent forms from the patients for their images and other clinical information to be reported in the journal.

Financial support and sponsorship

Nil.

Conflicts of interest

There are no conflicts of interest.

References

- Vieira GH, Rodriguez JD, Carmona-Mora P, Cao L, Gamba BF, Carvalho DR, *et al.* Detection of classical 17p11.2 deletions, an atypical deletion and RAI1 alterations in patients with features suggestive of Smith-Magenis syndrome. *Eur J Hum Genet* 2012;20:148-54.
- Smith AC, McGavran L, Robinson J, Waldstein G, Macfarlane J, Zonona J, *et al.* Interstitial deletion of (17) (p11.2p11.2) in nine patients. *Am J Med Genet* 1986;24:393-414.
- Greenberg F, Guzzetta V, de Oca-Luna RM, Magenis RE, Smith AC, Richter SF, *et al.* Molecular analysis of the Smith-Magenis syndrome: A possible contiguous gene syndrome associated with del (17)(p11.2). *Am J Hum Genet* 1991;49:1207-18.
- Nijim Y, Adawi A, Bisharat B, Bowirrat A. First case report of Smith-Magenis syndrome (SMS) among the Arab community in Nazareth. *Medicine* 2016;95:e2362.
- Elsa SH, Girirajan S. Smith-Magenis syndrome. *Eur J Hum Genet* 2008;16:412-21.
- Greenberg F, Lewis RA, Potocki L, Glaze D, Parke J, Killian J, *et al.* Multi-disciplinary clinical study of Smith-Magenis Syndrome (deletion 17 p11.2). *Am J Med Genet* 1996;62:247-54.
- De Leersnyder H, De Blois MC, Claustrat B, Romana S, Albrecht U, Von Kleist-Retzow JC, *et al.* Inversion of the circadian rhythm of melatonin in the Smith-Magenis syndrome. *J Pediatr* 2001;139:111-16.
- Potocki L, Glaze D, Tan DX, Park SS, Kashork CD, Shaffer LG, *et al.* Circadian rhythm abnormalities of melatonin in Smith-Magenis syndrome. *J Med Genet* 2000;37:428-33.
- Vlangos CN, Wilson M, Blancato J, Smith AC, Elsa, SH. Diagnostic FISH probes for del (17)(p11.2p11.2) associated with Smith-Magenis syndrome should contain the RAI1 gene. *AM J Med Genet* 2005;132:278-82.
- Trickett J, Oliver C, Heald M, Denyer H, Surtees A, Clarkson E, *et al.* Sleep in children with Smith-Magenis syndrome: A case-control actigraphy study. *Sleepj* 2020;43:zs260.
- De Leersnyder H, De Blois MC, Vekemans M, Sidi D, Villain E, Kindermans C, *et al.* Beta1 adrenergic antagonists improve sleep and behavioural disturbances in a circadian disorder, Smith-Magenis syndrome. *J Med Genet* 2001;38:586-90.