



Case Report

Middle meningeal artery embolization for postoperative supratentorial chronic subdural hematoma occurring after posterior fossa neurosurgery

Hangeul Park, Hyun Joo Park, Hyun-Seung Kang, Eun Jung Lee

Department of Neurosurgery, Seoul National University Hospital, Seoul, Korea

J Cerebrovasc Endovasc Neurosurg.
2021 June;23(2):152-158

Received: 4 December 2020

Revised: 9 January 2021

Accepted: 9 January 2021

Correspondence to

Eun Jung Lee

Department of Neurosurgery, Seoul National University Hospital, 101, Daehak-ro, Jongno-gu, Seoul 03080, Korea

Tel +82-2-2072-1188

Fax +82-2-744-8459

E-mail eunjlee21@gmail.com

ORCID <http://orcid.org/0000-0003-1678-1967>

Chronic subdural hematoma (CSDH) after posterior fossa surgery is rare but may occur. A 70-year-old man with trigeminal neuralgia underwent microvascular decompression. The patient took several medications for trigeminal neuralgia and tremor for a long time. The patient tended to bleed easily and did not stop well, but the bleeding was thoroughly controlled intraoperatively. A month later, he presented with left side weakness, and brain computed tomography showed huge amount of CSDH in the right cerebral convex with midline shifting. Although CSDH was completely drained via burr hole trephination, the brain was not fully expanded, and the CSDH recurred a month later. CSDH was evacuated, but there was still considerable subdural space and remained small CSDH in another superficial subdural space. We considered that the patient was at high risk of recurrence of CSDH and performed middle meningeal artery (MMA) embolization. Afterward, he did not suffer a recurrence. Here, we reviewed the risk factors of CSDH recurrence and the usefulness of MMA embolization in the treatment of CSDH, and we recommend upfront MMA embolization as an effective adjuvant to treat CSDH in patients at a high risk of recurrence of CSDH.

Keywords Chronic subdural hematoma, Risk factor, Recurrence, Embolization, Middle meningeal artery

This is an Open Access article distributed under the terms of the Creative Commons Attribution Non-Commercial License (<http://creativecommons.org/licenses/by-nc/3.0/>) which permits unrestricted noncommercial use, distribution, and reproduction in any medium, provided the original work is properly cited.

INTRODUCTION

Chronic subdural hematoma (CSDH), a common disease in neurosurgery, is mostly due to head trauma. CSDH is also one of the postoperative complications. CSDH can infrequently occur after craniotomy. CSDH is usually caused by supratentorial surgery. The incidence of CSDH after craniotomy is approximately 1.1%.²⁾ One of the

causes is excessive cerebrospinal fluid (CSF) drainage during the procedure, as this can cause the bridging vein to stretch and rupture.¹⁰⁾¹¹⁾¹⁵⁾ Venous bleeding, in turn, can produce subdural hematomas. Another possible cause of a hematoma is compression of jugular veins because of intraoperative position.²⁰⁾ The compression of the jugular vein increases intracranial venous pressure and leads to subdural hemorrhage. Burr hole trephination is the treatment of choice for the management of CSDH. After burr hole trephination, the recurrence rate of CSDH is about 10%.¹⁷⁾ We introduce a patient who has undergone middle meningeal artery (MMA) embolization due to the recurrence of CSDH after microvascular decompression (MVD) for trigeminal neuralgia (TN). We want to discuss the risk factors of CSDH after infratentorial craniotomy and the efficacy of MMA embolization in patients at high risk of CSDH recurrence.

CASE DESCRIPTION

A 70-year-old man was diagnosed with right TN eight years ago. He took carbamazepine 300 mg three times a day and gabapentin 300 mg three times a day to relieve his facial pain. However, the treatment was not sufficient enough. He then underwent Gamma Knife radiosurgery (GKS) for TN five years ago. The problem was initially relieved after GKS, but TN relapsed four months later. Afterward, he underwent two times percutaneous nerve block and two times radiofrequency ablation. Meanwhile, he had developed essential tremor twenty years ago, and he took clonazepam 0.25 mg once a day and propranolol 60 mg twice a day. Also, he took aspirin for an unclear purpose. For persistent and medically intractable TN, the patients eventually underwent MVD. He stopped taking aspirin two weeks before surgery and did not take it again after surgery. In the supine position, his head was turned to the left less than 90 degrees, and the neck was flexed, with vertex being parallel to the floor. During skin incision and craniotomy, the bleeding tendency was detected, but not to the extent that it could not be controlled surgically. His preoperative clotting

profile was within the normal range. When the dura was opened, the usual amount of CSF was drained with the typical speed. Arachnoid dissection was performed around the trigeminal nerve and surrounding vessels in the usual manner. Due to the age-related atrophic brain, additional CSF drainage was not necessary to make working space. A superior cerebellar artery was adhered to the trigeminal nerve and compressed the nerve at the root entry zone and mid-cisternal segment. Large superior petrosal veins were crossing over the surgical approach field of view. During the dissection between the offending vessel and the trigeminal nerve, the superior petrosal vein was slightly stretched, resulting in venous bleeding. Bleeding was entirely controlled by compression and using hemostatic materials. The offending vessel was successfully transposed not to conflict with the trigeminal nerve, and Teflon was inserted between the nerve and the vessel. There was no unusual finding except a mild degree of pneumocephalus on immediate postoperative brain computed tomography (CT). The patient's pain alleviated immediately after surgery. He stopped taking carbamazepine and gabapentin. However, due to the recent aggravation of his essential tremor, he started taking topiramate 50 mg once a day in addition to propranolol and clonazepam. On the 4th day after surgery brain CT, an extra-axial fluid collection with CSF density with 7 mm thickness along the right cerebral convexity was observed. Still, there was no mass effect, and the patient was discharged (Fig. 1). A month later, he presented with worsening dizziness and headache. He tended to veer to the left and reported left-sided weakness without a history of head trauma. Brain CT showed CSDH in the right cerebral convexity. He underwent burr hole trephination to evacuate the CSDH. Although CSDH was completely drained, the brain was not fully re-expanded on 2nd day after the surgery brain CT, and there was still an excessive subdural space filled with CSF (Fig. 2). A month later, his subsequent CT scan showed a larger amount of CSDH mixed with acute stage hematoma in the right convexity. He underwent a repeated burr hole trephination, and a subdural catheter was inserted. A small amount of acute staged hematoma

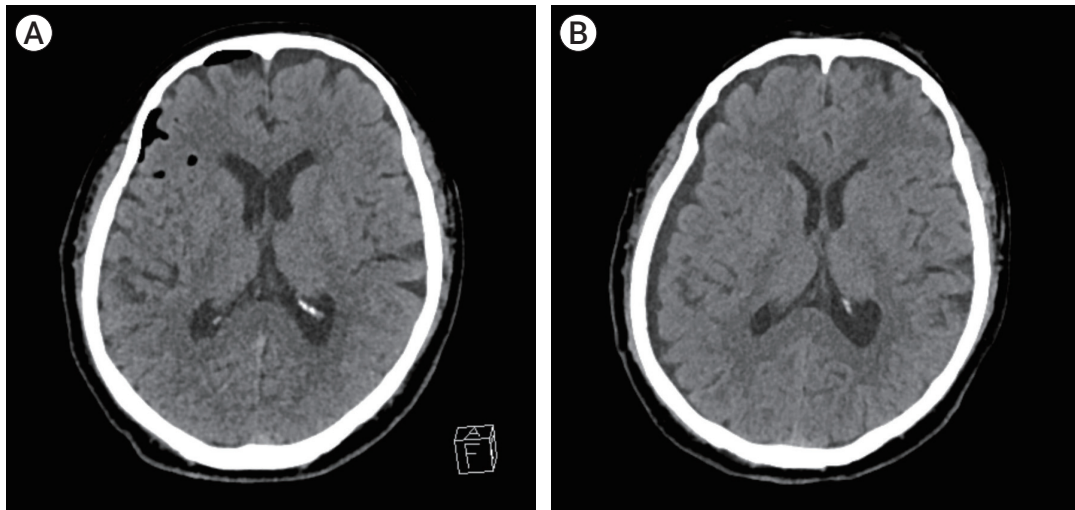


Fig. 1. (A) On immediate postoperative brain CT, there were not unusual postoperative findings except mild pneumocephalus. (B) The 4th days after surgery follow up brain CT showed an extra-axial fluid collection with CSF density with 7 mm thickness along the right cerebral convexity. CT, computed tomography; CSF, cerebrospinal fluid.

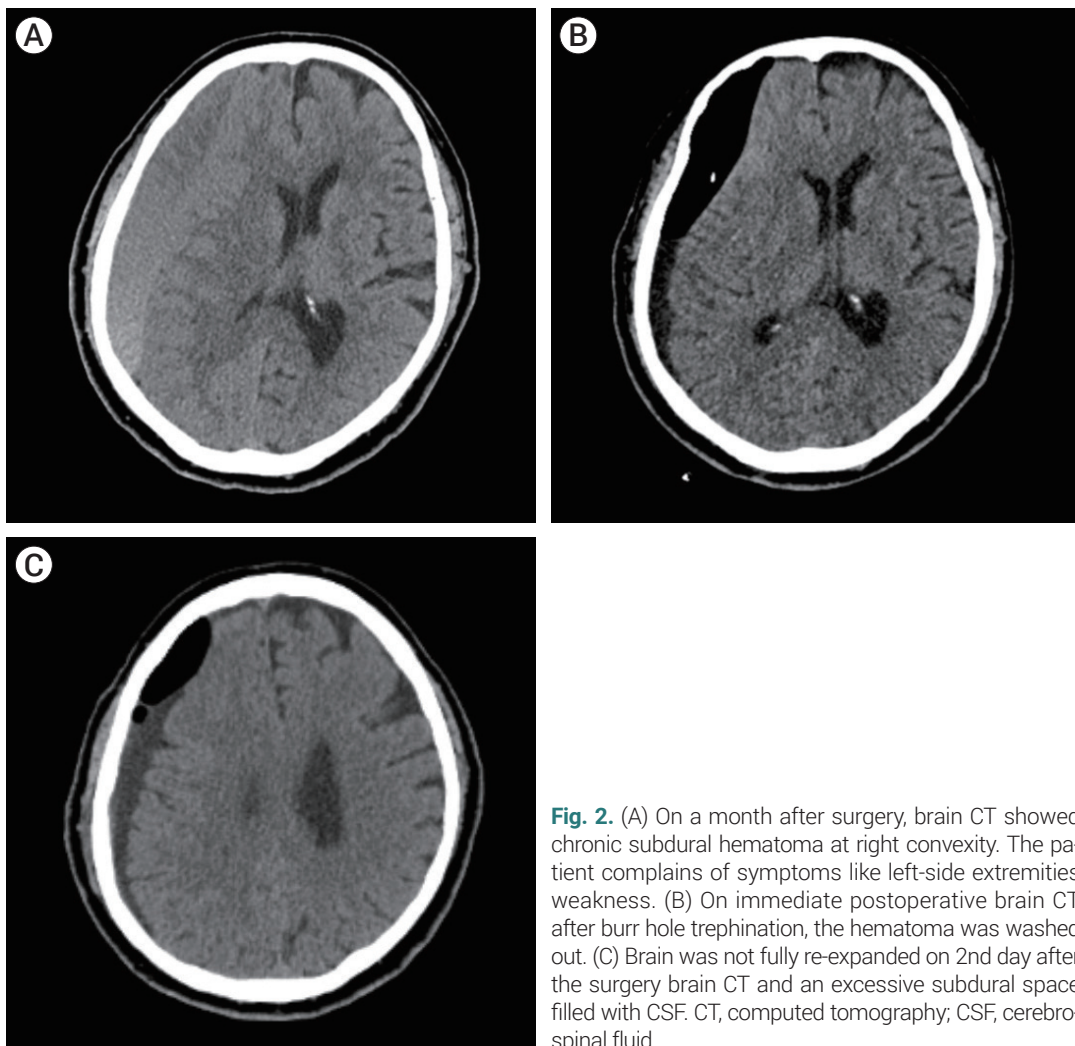


Fig. 2. (A) On a month after surgery, brain CT showed chronic subdural hematoma at right convexity. The patient complains of symptoms like left-side extremities weakness. (B) On immediate postoperative brain CT after burr hole trephination, the hematoma was washed out. (C) Brain was not fully re-expanded on 2nd day after the surgery brain CT and an excessive subdural space filled with CSF. CT, computed tomography; CSF, cerebrospinal fluid.

remained in the subdural space on the day after surgery brain CT. We considered that the patient was at high risk of CSDH recurrence due to age-related atrophic brain and bleeding tendency in the first intraoperative findings. Thus, we performed additional MMA embolization. There was still excessive subdural space filled with

subacute staged hemorrhage on CT scan a month later, but the subdural space extent did not increase. Brain CT 3 months after the second surgery showed complete CSDH resolution and full expansion of the brain parenchyma. After that, he did not suffer from a recurrence of CSDH (Fig. 3).

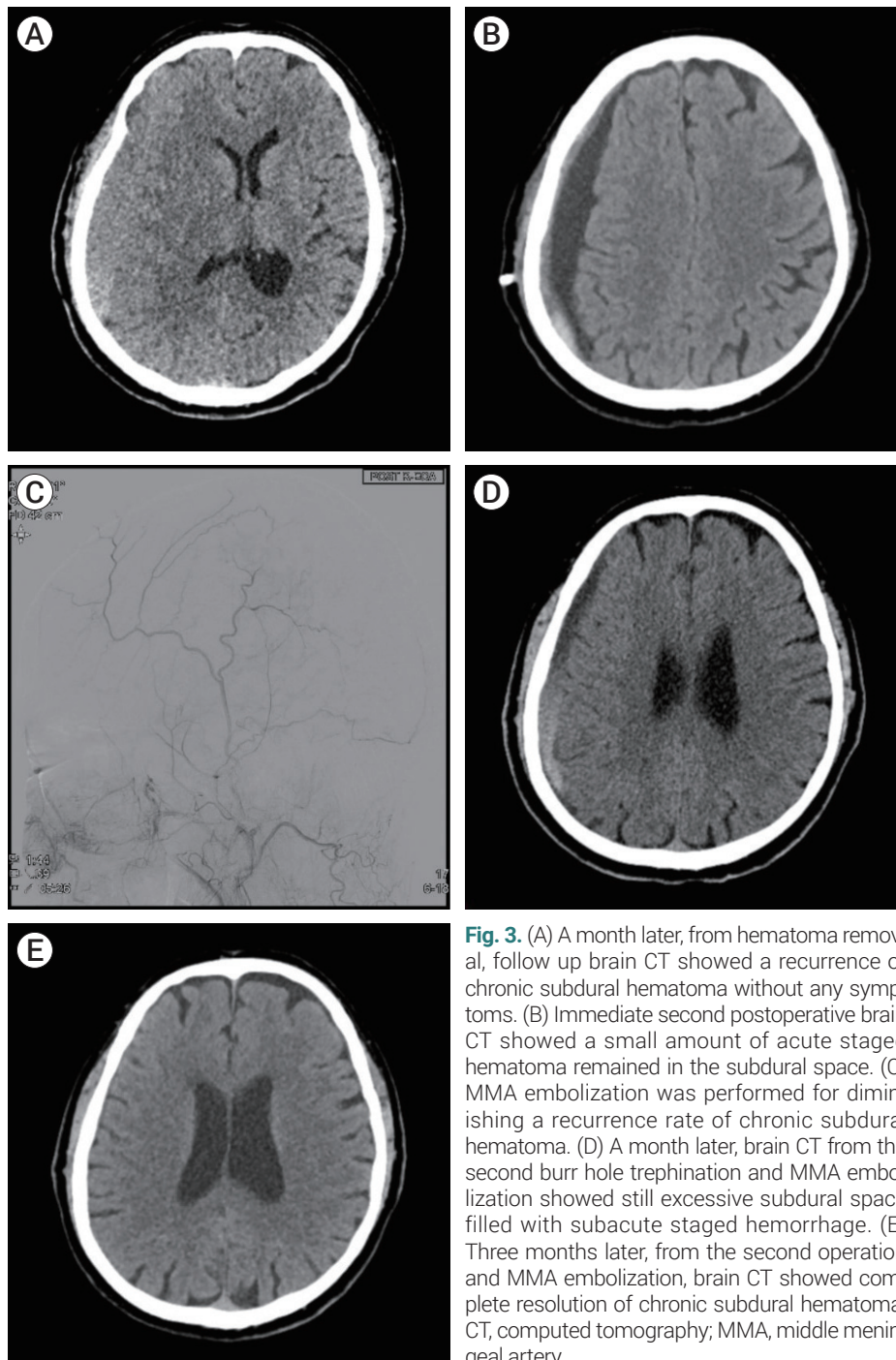


Fig. 3. (A) A month later, from hematoma removal, follow up brain CT showed a recurrence of chronic subdural hematoma without any symptoms. (B) Immediate second postoperative brain CT showed a small amount of acute staged hematoma remained in the subdural space. (C) MMA embolization was performed for diminishing a recurrence rate of chronic subdural hematoma. (D) A month later, brain CT from the second burr hole trephination and MMA embolization showed still excessive subdural space filled with subacute staged hemorrhage. (E) Three months later, from the second operation and MMA embolization, brain CT showed complete resolution of chronic subdural hematoma. CT, computed tomography; MMA, middle meningeal artery.

DISCUSSION

Causes of hemorrhage after MVD

Serious hemorrhagic complications after MVD for TN are rare.¹⁶⁾ There are some cases of supratentorial bleeding, all of them acute SDH.¹⁰⁾¹¹⁾¹⁵⁾ Excessive CSF drainage is considered to be a factor that damages the supratentorial bridging veins. Significantly, the age-related atrophic brain is vulnerable to CSF drainage.¹⁷⁾ CSF is normally drained passively, so the rate of CSF removal is more important than the amount of CSF drained.²⁾ In general, in MVD to treat hemifacial spasms, slightly lowering the patient's vertex will help locate the lesion by gravitational traction of the cerebellum. Vertex down position is an additional cause of stretching of the bridging vein. However, bleeding from bridging vein stretching cannot be applied to MVD for TN. During MVD for TN, the vertex of the patient is situated parallel to the floor. There is no way to predict the occurrence of supratentorial SDH during surgery. Yakufujiang et al.²³⁾ suggest that abnormal CSF accumulation in the cerebellomedullary cistern called 'the welling-up of CSF' is considered a sign of unexpected bleeding. The patient's neck was rotated and flexed in supine position to obtain the optimal surgical exposure in the retromastoid approach. This position causes compression of the contralateral jugular vein. Thus, venous pressure is increased, and hemodynamic stress in the brain, in turn, is increased.²⁰⁾ Increased venous pressure due to jugular vein compression could be another possible cause of SDH. However, in this patient, both the amount and rate of CSF drainage was as usual. He had surgery in the supine position with his head turned less than 90 degrees to the left. There were no unusual intraoperative findings except for superior petrosal vein bleeding during the surgery. The amount of bleeding was not extensive, and the bleeding was completely controlled. Although his preoperative coagulation profile was normal, he showed bleeding tendency during skin incision and craniotomy. Also, his brain showed age-related atrophic changes. The atrophic brain is vulnerable to bridging vein injury during the microsurgery because it is easily movable and poses the

bridging vein much more stretched with CSF drainage. Therefore, although CSF was drained at a normal rate and amount in this patient, the bridging vein's occult rupture might have occurred during the surgery, causing chronic SDH.³⁾

Medications related to bleeding tendency

Platelet aggregation is mediated by molecules such as adenosine diphosphate, thrombin, and thromboxane A2 (TXA2).¹²⁾ High levels of propranolol inhibit the thromboxane synthase that produces TXA2 in vitro. Thus, prolonged use of propranolol can inhibit platelet aggregation and cause a tendency to bleed.⁹⁾ In this case, the dosage was not enough to inhibit platelet aggregation, but we speculate that taking propranolol for a long time could have affected his tendency to bleed. Also, some studies reported that gabapentin has a dose-dependent inhibitory effect on platelet aggregation in vitro. Decreased platelet function is associated with inhibition of TXA2 formation and diminished intracellular calcium mobilization.¹⁸⁾ Baglo et al.³⁾ reported patients with mucosal bleeding while taking gabapentin. Laboratory tests had shown reduced platelet function. The patient, in this case, had been taking gabapentin for a long time for TN. Although he stopped medication after MVD, chronic suppression of platelet functions by gabapentin might have impacted the coagulation pathway and contributed to the development of CSDH.

MMA embolization for recurrent CSDH

MMA embolization is a very effective way to prevent recurrent CSDH.⁴⁾ In CSDH, the blood from the bridging vein mixes with the CSF and forms a hematoma. The hematoma is covered with a multi-layered membrane. In histopathology, angiogenesis occurs in the hematoma membranes. Also, inflammatory cells invade the hematoma membrane and secrete inflammatory mediators. Inflammatory cells and secreted materials facilitate neovascularization. Newly formed small blood vessels are fragile and rupture easily. Bleeding from the vessels makes hematoma and increases the size of the hematoma.⁴⁾⁶⁾ Between the outer membrane of the hematoma

and the dura mater, there are communicating vessels connected to the MMA. MMA embolization can help block the blood supply to the hematoma membrane and prevent further bleeding.⁷⁾ Surgical hematoma removal can help relieve the symptoms of CSDH. However, burr hole trephination does not solve the pathophysiology of the hematoma. To resolve the problem, surgery after MMA embolization is a useful strategy to relieve symptoms and prevent a recurrence of CSDH.⁵⁾ The recurrence rate of CSDH after burr hole trephination is approximately 10%,¹⁷⁾ but this rate is reduced to about 0-2.4% after MMA embolization.⁴⁾²²⁾ Old age, ischemic insults, anticoagulant therapy, and postoperative subdural air collection are known as risk factors for CSDH recurrence.¹⁾¹³⁾¹⁴⁾¹⁹⁾²¹⁾²⁴⁾ Also, it has been reported that laminar and separated typed CSDH had a higher recurrence rate than homogeneous and trabecular type because its fibrinolytic activity.⁸⁾ The hematoma in this patient was a separated type, and it might have contributed to the recurrence of CSDH along with poor re-expanding of the brain and subdural air collection after the first burr hole trephination. For patients with risk factors for CSDH recurrences such as the atrophic brain and increased bleeding tendency, an upfront MMA embolization may be a useful strategy to reduce recurrence rates and morbidity rates.

CONCLUSIONS

MMA embolization is an effective way to treat repetitive CSDH after craniotomy. For patients at high risk of CSDH recurrence due to brain atrophy and bleeding tendency, upfront MMA embolization would help reduce recurrence.

Disclosure

The authors report no conflict of interest concerning the materials or methods used in this study or the findings specified in this paper.

REFERENCES

1. Amagasaki K, Takusagawa Y, Kanehashi K, Abe S, Watanabe S, Shono N, et al. Supratentorial acute subdural haematoma during microvascular decompression surgery: report of three cases. *J Surg Case Rep*. 2017 Feb;2017(2):rjx004.
2. Anfossi G, Trovati M, Mularoni E, Massucco P, Calcamuggi G, Emanuelli G. Influence of propranolol on platelet aggregation and thromboxane B2 production from platelet-rich plasma and whole blood. *Prostaglandins Leukot Essent Fatty Acids*. 1989 Apr;36(1):1-7.
3. Baglo T, Pouplard C, Valentin JB, Guery EA, Gruel Y, Wayne C. Acquired platelet defect associated with gabapentin treatment: a case-report. *Platelets*. 2020 Aug;1-4.
4. Ban SP, Hwang G, Byoun HS, Kim T, Lee SU, Bang JS, et al. Middle meningeal artery embolization for chronic subdural hematoma. *Radiology*. 2018 Mar;286(3):992-9.
5. Chon KH, Lee JM, Koh EJ, Choi HY. Independent predictors for recurrence of chronic subdural hematoma. *Acta Neurochir (Wien)*. 2012 Sep;154(9):1541-8.
6. Fukuhara T, Gotoh M, Asari S, Ohmoto T, Akioka T. The relationship between brain surface elastance and brain reexpansion after evacuation of chronic subdural hematoma. *Surg Neurol*. 1996 Jun;45(6):570-4.
7. Haldrup M, Ketharanathan B, Debrabant B, Schwartz OS, Mikkelsen R, Fugleholm K, et al. Embolization of the middle meningeal artery in patients with chronic subdural hematoma-a systematic review and meta-analysis. *Acta Neurochir (Wien)*. 2020 Apr;162(4):777-84.
8. Hanakita J, Kondo A. Serious complications of microvascular decompression operations for trigeminal neuralgia and hemifacial spasm. *Neurosurgery*. 1988 Feb;22(2):348-52.
9. Hashimoto T, Ohashi T, Watanabe D, Koyama S, Namatame H, Izawa H, et al. Usefulness of embolization of the middle meningeal artery for refractory chronic subdural hematomas. *Surg Neurol Int*. 2013 Aug;4:104
10. Jackson SP. The growing complexity of platelet aggregation. *Blood*. 2007 Jun;109(12):5087-95.
11. Jung YG, Jung NY, Kim E. Independent predictors for recurrence of chronic subdural hematoma. *J Korean Neurosurg Soc*. 2015 Apr;57(4):266-70.
12. Kasuya H, Kuroi Y, Yokosako S, Koseki H, Tani S. Intraoperative and postoperative bleeding in microvascular decompression for trigeminal neuralgia. *World Neurosurg*. 2018 Oct;118:e123-8.
13. Ko BS, Lee JK, Seo BR, Moon SJ, Kim JH, Kim SH. Clinical

- analysis of risk factors related to recurrent chronic subdural hematoma. *J Korean Neurosurg Soc.* 2008 Jan;43(1):11-5.
14. Lee MH, Jee TK, Lee JA, Park K. Postoperative complications of microvascular decompression for hemifacial spasm: lessons from experience of 2040 cases. *Neurosurg Rev.* 2016 Jan;39(1):151-8; discussion 158.
 15. Li N, Zhao W, Pu C, Shen J. Delayed hemorrhage following microvascular decompression. Three case reports. *Neurol Med Chir (Tokyo).* 2007 Apr;47(4):186-8.
 16. Mori K, Maeda M. Surgical treatment of chronic subdural hematoma in 500 consecutive cases: clinical characteristics, surgical outcome, complications, and recurrence rate. *Neurol Med Chir (Tokyo).* 2001 Aug;41(8):371-81.
 17. Nagahori T, Nishijima M, Takaku A. Histological study of the outer membrane of chronic subdural hematoma: possible mechanism for expansion of hematoma cavity. *No Shinkei Geka.* 1993 Aug;21(8):697-701.
 18. Nakaguchi H, Tanishima T, Yoshimasu N. Factors in the natural history of chronic subdural hematomas that influence their postoperative recurrence. *J Neurosurg.* 2001 Aug;95(2):256-62.
 19. Nakaguchi H, Tanishima T, Yoshimasu N. Relationship between drainage catheter location and postoperative recurrence of chronic subdural hematoma after burr-hole irrigation and closed-system drainage. *J Neurosurg.* 2000 Nov;93(5):791-5.
 20. Schwarz F, Loos F, Dunisch P, Sakr Y, Safatli DA, Kalff R, et al. Risk factors for reoperation after initial burr hole trephination in chronic subdural hematomas. *Clin Neurol Neurosurg.* 2015 Nov;138:66-71.
 21. Takahashi Y, Ohkura A, Sugita Y, Sugita S, Miyagi J, Shigemori M. Postoperative chronic subdural hematoma following craniotomy--four case reports. *Neurol Med Chir (Tokyo).* 1995 Feb;35(2):78-81.
 22. Tanaka T, Kaimori M. Histological study of vascular structure between the dura mater and the outer membrane in chronic subdural hematoma in an adult. *No Shinkei Geka.* 1999 May;27(5):431-6.
 23. Yakufujian M, Higuchi Y, Wakita S, Horiguchi, Ikegami S, Iwadate Y. Welling-up of cerebrospinal fluid is a sign of remote supratentorial hemorrhage during microvascular decompression: a case report. *Egypt J Neurosurg.* 2020 Apr;35(11):1-4.
 24. Yang AI, Balsler DS, Mikheev A, Offen S, Huang JH, Babb J, et al. Cerebral atrophy is associated with development of chronic subdural haematoma. *Brain Inj.* 2012;26(13-14):1731-6.