



Since January 2020 Elsevier has created a COVID-19 resource centre with free information in English and Mandarin on the novel coronavirus COVID-19. The COVID-19 resource centre is hosted on Elsevier Connect, the company's public news and information website.

Elsevier hereby grants permission to make all its COVID-19-related research that is available on the COVID-19 resource centre - including this research content - immediately available in PubMed Central and other publicly funded repositories, such as the WHO COVID database with rights for unrestricted research re-use and analyses in any form or by any means with acknowledgement of the original source. These permissions are granted for free by Elsevier for as long as the COVID-19 resource centre remains active.

Reversible cerebral vasoconstriction syndrome and dissection in the setting of COVID-19 infection

Katarina Dakay, DO,* Gurmeen Kaur, MD,* Edwin Gulko, MD,†
Justin Santarelli, MD,* Christian Bowers, MD,‡ Stephan A Mayer, MD,§
Chirag D Gandhi, MD,* and Fawaz Al-Mufti, MD*

The current COVID-19 pandemic has recently brought to attention the myriad of neuro-logic sequelae associated with Coronavirus infection including the predilection for stroke, particularly in young patients. Reversible cerebral vasoconstriction syndrome (RCVS) is a well-described clinical syndrome leading to vasoconstriction in the intracranial vessels, and has been associated with convexity subarachnoid hemorrhage and occasionally cervical artery dissection. It is usually reported in the context of a trigger such as medications, recreational drugs, or the postpartum state; however, it has not been described in COVID-19 infection. We report a case of both cervical vertebral artery dissection as well as convexity subarachnoid hemorrhage due to RCVS, in a patient with COVID-19 infection and no other triggers.

Keywords: Reversible cerebral vasoconstriction syndrome—Coronavirus,—COVID-19—Convexity subarachnoid hemorrhage—Vertebral artery dissection
© 2020 Elsevier Inc. All rights reserved.

Introduction

Recent reports reflect emerging evidence for the neurotropism of the novel SARS-CoV-2 virus; patients have been presenting with neurological symptoms with unusual clustering frequency and age-predilection including hypercoagulability leading to ischemic

stroke, hemorrhagic leukoencephalopathy, and Guillain-Barre syndrome.¹

Reversible cerebral vasoconstriction syndrome (RCVS) is a clinical syndrome characterized by thunderclap headache and alternating intracranial vascular vasoconstriction and vasodilation on vessel imaging; ischemic stroke, convexity subarachnoid hemorrhage (cSAH), and intraparenchymal hemorrhage can also occur.² RCVS is usually triggered by medications, post-partum state, or sexual activity³ but has not been reported with COVID-19. Herein we describe RCVS and extracranial dissection with concomitant SARS-CoV-2 infection.

Case Report

A female nurse in her thirties with migraines presented with a few weeks of severe cough, and three days of severe thunderclap headache different than her usual migraines. Nasopharyngeal swab was positive for SARS-CoV-2 on RT-PCR assay. Non-contrast CT brain demonstrated bilateral high frontal cSAH (Fig 1A). She had no typical triggers for RCVS on review of medications and

From the *Department of Neurosurgery, New York Medical College, 100 Woods Rd, Valhalla, NY 10595, United States; †Department of Radiology, Division of Neuroradiology, New York Medical College, Valhalla, NY, United States; ‡Department of Neurosurgery, University of New Mexico, Albuquerque, New Mexico, United States; and §Department of Neurology, Henry Ford Hospital, Detroit, Michigan.

Received May 11, 2020; revision received May 27, 2020; accepted May 28, 2020.

Work performed at Westchester Medical Center at New York Medical College, Valhalla, New York; Department of Neurosurgery

Grant support: None

Address correspondence to Fawaz Al-Mufti, MD, Department of Neurosurgery, New York Medical College 100 Woods Rd, Valhalla, NY 10595. E-mail: fawaz.al-mufti@wmchealth.org.

1052-3057/\$ - see front matter

© 2020 Elsevier Inc. All rights reserved.

<https://doi.org/10.1016/j.jstrokecerebrovasdis.2020.105011>

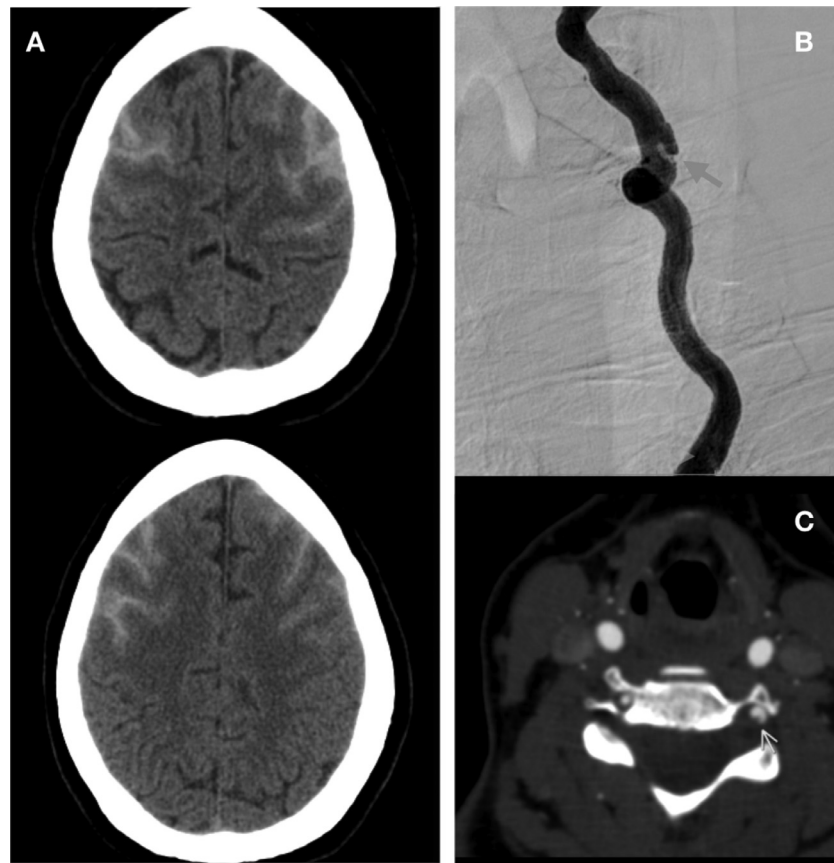


Fig. 1. CT brain on admission demonstrates bilateral convexity subarachnoid hemorrhage (A); diagnostic cerebral angiogram on admission demonstrates a left vertebral artery dissection (B), also seen on CT angiogram (C).

social history. Coagulation parameters were normal, hCG was negative, and neurologic exam was nonfocal. Diagnostic cerebral angiogram (DSA) on admission revealed a left V2 segment vertebral artery dissection and no other abnormalities (Fig 1B) which was also seen on CT angiogram (Fig 1C). She was transferred to the

COVID19 Intensive care unit and started on verapamil, levetiracetam, aspirin, and analgesics. DSA seven days after admission demonstrated bilateral mild to moderate anterior circulation vasospasm suggestive of RCVS (Figs. 2,3). She was discharged home with verapamil and follow-up CT angiogram.

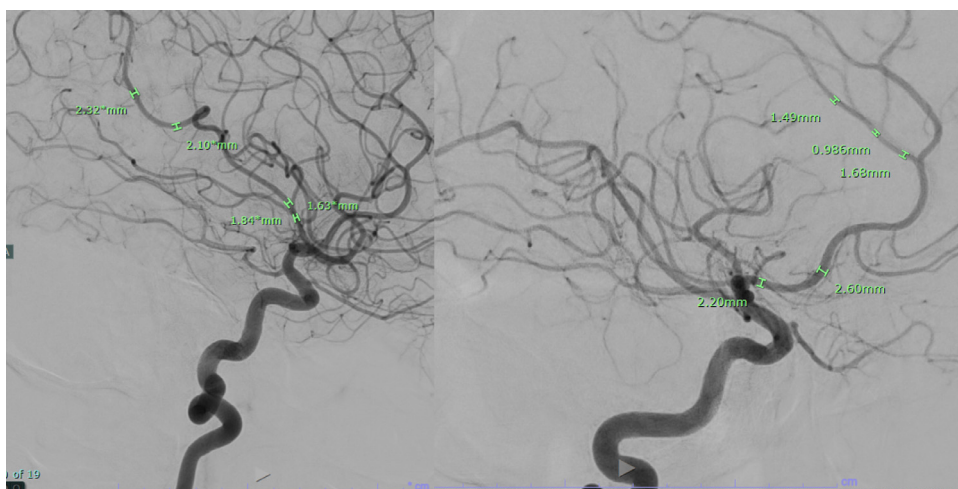


Fig. 2. Diagnostic cerebral angiogram at one week demonstrates bilateral diffuse vasoconstriction in the anterior circulation, as measured on angiographic images.

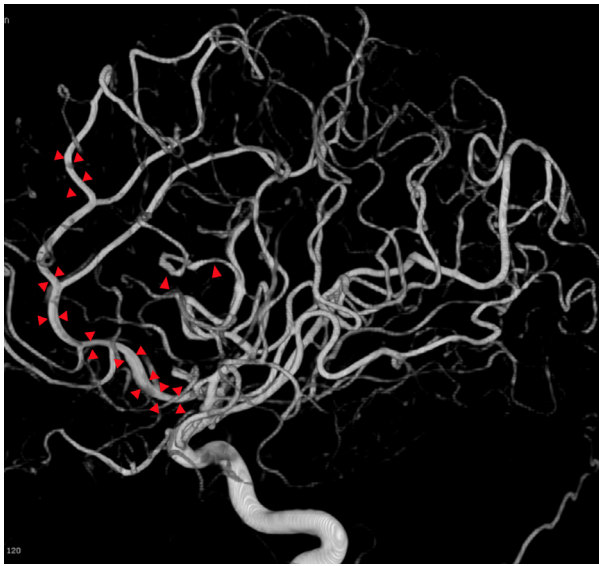


Fig. 3. 3-dimensional rotational imaging shows left anterior cerebral artery and middle cerebral artery vasospasm in the M3 segment.

Conclusion

RCVS is a common cause of cSAH in young women but is generally not associated with viral infection. In our patient, dissection was present on initial DSA, with multifocal vasoconstriction seen only on repeat DSA. In this case, she had been coughing for a week prior to the presentation, which likely precipitated the dissection, leading to subsequent RCVS and cSAH. Extracranial dissection associated with RCVS is uncommon but reported; dissection may lead to vasoactive substance release precipitating RCVS.⁴ cSAH in RCVS is likely due to dynamic vessel wall changes, with vasoconstriction followed by vasodilation leading to reperfusion injury and hemorrhage.² However, SARS-CoV-2 also may induce vasoconstriction; spikes in blood pressure may lead to loss of cerebral autoregulation, which is the proposed mechanism of RCVS.⁵ In particular, SARS-CoV-2 downregulates the ACE2 receptor, which functions to reduce sympathetic tone, increases vasodilation, and exerts antihypertensive effects. SARS-CoV-2 leads to downregulation of ACE2, which can cause overactivation of the classic renin-angiotensin axis and lead to vasoconstriction.⁶

Limitations of our case include the lack of follow-up imaging at this time, as the patient presented early in her course and had vasoconstriction on last imaging, as well as the unclear relationship between SARS-CoV-2 infection, dissection, and RCVS. However, the patient's RCVS2 score⁷ was 10, with a score of >5 having a high

specificity and sensitivity (99% and 90% respectively) for diagnosing RCVS. Overall, this single case report only suggests a possible association between RCVS and SARS-CoV-2 infection, and more cases with epidemiological data are needed to validate a causal relationship. This case also suggests the need to consider potential neurological symptoms of SARS-CoV-2 infection.

Consent

The patient provided written informed consent to the publication of manuscript.

Identifying Data

The patient provided written informed consent to the publication of this case report.

Conflict of Interest

All authors have no affiliations with or involvement in any organization or entity with any financial interest or non-financial interest in the subject matter or materials discussed in this manuscript.

References

1. Mao L, Jin H, Wang M, Hu Y, Chen S, He Q, et al. Neurologic manifestations of hospitalized patients with coronavirus disease 2019 in Wuhan, China. *JAMA Neurol* 2020. <https://doi.org/10.1001/jamaneurol.2020.1127>.
2. Topcuoglu MA, Singhal AB. Hemorrhagic reversible cerebral vasoconstriction syndrome: features and mechanisms. *Stroke* 2016;47:1742-1747.
3. Ducros A. Reversible cerebral vasoconstriction syndrome [Internet]. *Lancet Neurol* 2012;11:906-917. [https://doi.org/10.1016/s1474-4422\(12\)70135-7](https://doi.org/10.1016/s1474-4422(12)70135-7).
4. Mawet J, Boukobza M, Franc J, Sarov M, Arnold M, Bousser M-G, et al. Reversible cerebral vasoconstriction syndrome and cervical artery dissection in 20 patients. *Neurology* 2013;81:821-824.
5. Sharifi-Razavi A, Karimi N, Rouhani N. COVID-19 and intracerebral haemorrhage: causative or coincidental? *New Microbes New Infections* 2020;35:100669. <https://doi.org/10.1016/j.nmni.2020.100669>.
6. Divani AA, Andalib S, Di Napoli M, Lattanzi S, Shazam Hussain M, Biller J, et al. Coronavirus disease 2019 and stroke: clinical manifestations and pathophysiological insights [Internet]. *JStroke Cerebrovascular Diseases* 2020;29:104941. <https://doi.org/10.1016/j.jstrokecerebrovasdis.2020.104941>.
7. Rocha EA, Topcuoglu MA, Silva GS, Singhal AB. RCVS score and diagnostic approach for reversible cerebral vasoconstriction syndrome. *Neurology* 2019;92:e639-e647.