

The grade of preoperative subscapularis muscle atrophy as a prognostic factor for postoperative retears: A double-center retrospective series

Emmanouil Fandridis,¹

Michael-Alexander Malahias,¹

Athena Plagou,² Antonio Orgiani,³

Luca Flaviis,⁴ Alessandro Castagna³

¹Hand-Upper Limb and Microsurgery Department, Hospital KAT, Athens, Greece; ²Private Radiological Institution, Athens, Greece; ³Humanitas Clinical Institute, Milan, Italy; ⁴Private Radiological Office De Flaviis, Milan, Italy

Abstract

The aim of the study was to investigate whether subscapularis muscle atrophy is a negative prognostic factor leading to increased risk of retears in patients treated with an arthroscopic subscapularis tendon repair. We hypothesized that fatty infiltration of the subscapularis muscle deteriorates the clinical and sonographic outcome of the arthroscopic repair and inhibits reparability of the ruptured tendons. A double-center, multinational, retrospective, blind (in the follow-up) clinical study regarding 32 patients who underwent an arthroscopic subscapularis repair was conducted. Patients were divided into two groups according to the preoperative fatty infiltration grade of subscapularis muscle (group A: grade<II, group B: grade II or higher). Reparability was not influenced by the grade of preoperative fatty infiltration of subscapularis muscle. The preoperative MRI scans showed significantly higher grades of fatty infiltration (group B) in the subscapularis muscle of patients with clinical evidence of retear after the arthroscopic repair. Low grades of preoperative subscapularis muscle atrophy are significantly correlated with low clinical and sonographic retear's rate after subscapularis arthroscopic repair, while high grades were a clear negative prognostic factor for the clinical outcome of the aforementioned patients.

Introduction

The subscapularis muscle is the most

powerful muscle of the rotator cuff and the main internal rotator of the shoulder. The insertion of the subscapularis tendon is partly tendinous (upper 60%) and partly muscular (lower 40%).^{1,2} In common with the other rotator cuff muscles it plays an important role in maintaining glenohumeral joint stability through force couples. Stability is the result of a balance of forces between the anterior and posterior cuff muscles. This, so-called "transverse force couple", explains why the integrity of the subscapularis and infraspinatus tendons is crucial to shoulder function and stability.³⁻⁵ Subscapularis tendon tears can be isolated or combined with large supraspinatus and/or infraspinatus tendon tears. Repair of subscapularis tendon tears is essential for restoring normal glenohumeral biomechanics.⁶⁻¹⁰ It has been suggested by many researchers that an important factor leading to poor functional outcome after rotator cuff repairs is fatty infiltration.¹¹⁻¹⁴ Preoperative muscle atrophy of the supraspinatus or fatty infiltration of the infraspinatus are negative predictive factors of healing after rotator cuff arthroscopic repair.¹⁵ According to Lee *et al.*, fatty degeneration of the supraspinatus is an independent risk factor for a rotator cuff retear.¹⁶ On the other hand, the influence of subscapularis fatty infiltration as a preoperative prognostic factor on the postoperative healing of arthroscopic subscapularis repair remains controversial. Kim *et al.* concluded that reparability of rotator cuff tears is associated with fatty infiltration of the supraspinatus and infraspinatus but not with fatty infiltration of the subscapularis or teres minor.¹⁷

Till now, there was a relative lack of clinical trials reporting the influence of fatty infiltration of subscapularis muscle on the retear rate after arthroscopic subscapularis repair. Our aim was to investigate whether subscapularis muscle atrophy is a negative prognostic factor leading to increased risk of retears in patients treated with an arthroscopic subscapularis tendon repair. We hypothesized that fatty infiltration of the subscapularis muscle deteriorates the clinical and sonographic outcome of the arthroscopic repair and inhibits reparability of the ruptured tendons.

Materials and Methods

A double-center, multinational, retrospective (prospectively collected data), blind (in the follow-up) clinical trial including 32 older than 40 years old patients (mean age: 64.4 years, 19 male: 13 female, 27 right: 5 left arms), with MRI-confirmed

Correspondence: Michael-Alexander Malahias, Hand-Upper Limb and Microsurgery Department, Hospital KAT, Athanasiou Diakou 11, Agia Paraskevi, 15342 Athens, Greece.
Tel.: +30.6972631960.
E-mail: alexandermalahias@yahoo.gr

Key words: Fatty infiltration, subscapularis muscle atrophy, preoperative prognostic factor, subscapularis arthroscopic repair, MRI subscapularis.

Contributions: EF conception and the design of this study, performed some of the operations described in this paper. MAM design of the study, review of the literature and writing the manuscript. AP performed part of the ultrasound examinations, participated in the data collection and the manuscript preparation. AO acquisition and interpretation of the data. LF performed part of the ultrasound examinations and critically revised the manuscript. AC carried out some of the operations which were described in this paper and he participated in critically revising of the manuscript for important intellectual content.

Conflict of interest: the authors declare no potential conflict of interest.

Funding: none.

Received for publication: 17 October 2018.

Accepted for publication: 2 May 2019.

This work is licensed under a Creative Commons Attribution NonCommercial 4.0 License (CC BY-NC 4.0).

©Copyright E. Fandridis *et al.*, 2019

Licensee PAGEPress, Italy

Orthopedic Reviews 2019;11:7909

doi:10.4081/or.2019.7909

symptomatic subscapularis tear was conducted. All patients involved in this case-control study had undergone an arthroscopic subscapularis repair regardless of the size of the tear by one of two senior shoulder surgeons (EF, AC) with adequate experience on shoulder arthroscopy. These patients were examined and treated in two orthopedic academic centers with special interest in upper limb surgery from November 2012 until December 2013. The follow-up for each patient should be at least 12 months. All procedures performed were in accordance with the ethical standards of the institutional and/or national research committee and with the 1964 Helsinki declaration and its later amendments or comparable ethical standards.

We excluded from our retrospective analysis patients who were <40 years old,

those who were re-operated on the same shoulder in the past, individuals who did not undergo an arthroscopic treatment of the subscapularis tear or had a short follow-up less than 12 months, those who did not have a preoperative MRI confirmation of the subscapularis tear, patients suffering from systematic or autoimmune diseases, cancer, psychiatric diseases and uncontrolled hormonal diseases.

Preoperative subscapularis tendon tears had been evaluated with shoulder MRI in all cases. The MRI protocol included T1 axial and coronal oblique images and T2 fat suppression axial, sagittal oblique and coronal oblique images. MRI reported the type and extent of subscapularis tendon tears, as well as the extent of subscapularis muscle atrophy graded according to the Fuchs classification system.¹⁸ Patients were retrospectively divided into two groups according to the preoperative fatty infiltration grade of subscapularis muscle (16 patients of group A: grade <II, 16 patients of group B: grade II or higher).¹⁹

Regarding the surgical technique, arthroscopic subscapularis repair was performed with the patient in lateral position and arm traction in all cases. Arthroscopy allowed complete visualization of the glenohumeral joint with the 30° scope and shoulder maneuvers such as internal rotation of the arm and anterior to posterior translation. In all cases tenotomy or tenodesis of the long head of the biceps was performed, due to tendon instability, pulley lesion or tendon degeneration.

Release of the subscapularis tendon was carried out meticulously and its footprint at the lesser tuberosity was prepared by cautious decortication. In cases where the subscapularis tendon was retracted, medialization of the footprint was planned. The tendon elasticity was assessed in order to restore normal tension. One or two anchors with two or three sutures were placed. Arthroscopic instrumentation such as suture passer was used to repair the subscapularis tendon through the anchor sutures.

Tenodesis of the long head of the biceps was performed, when necessary, with one of the remaining anchor sutures. The subscapularis repair was assessed with the arthroscopic probe in various degrees of arm rotation. Arthroscopy of the subacromial space, bursectomy and acromioplasty were performed in most of the cases. Supraspinatus or supra-infraspinatus repair was also performed in antero-superior or massive cuff tears. A similar rehabilitation program of initial protection in a splint and gradual mobilization of the repaired shoulder was utilized to all our patients.

All patients were postoperatively evalu-

ated and documented with the use of ultrasound by two radiologists (AP and FL) who were unaware of the preoperative MRI assessment. The clinical evaluation at the final point of the follow-up was performed by two physicians, other than the treating surgeons, who were unaware of the preoperative MRI grading. The clinical assessment was done using four different clinical tests (internal rotation lag sign, the Napoleon test, the bear-hug and lift-off test). Patients documented as clinically suspicious for subscapularis retear were those who had a minimum of one positive clinical test. The rate of failure was calculated by the number of operated patients per group who had documented clinical or sonographic subscapularis retear after 12 months follow-up. The intraoperative reparability of the subscapularis tear was investigated as secondary outcome.

Statistical analysis was performed using paired t-test on SPSS ver. 10.0. A P-value <0.05 was considered significant.

Results

Preoperative MRI revealed the presence and extent of subscapularis muscle atrophy. In 13 out of 32 patients no muscle atrophy of the subscapularis was found. The remaining patients presented with grades I to III atrophy as shown in Table 1. No partial

thickness subscapularis tendon tears were identified in the study group. The vast majority of the patients were classified as Fox & Romeo type II, while seven were type III and two type IV.

Nineteen subscapularis tendon tears were associated with traumatic events, while the remaining thirteen tears were presumed due to degenerative tendon disease. In all cases the arthroscopic repair was considered successful based on the intraoperative evaluation and the surgeon's report. As a result, reparability was not influenced by the grade of preoperative fatty infiltration of subscapularis muscle.

The fibrillar echostructure of the successfully repaired tendons was sonographically documented to be similar to the normal echostructure of the contralateral subscapularis tendons (Figures 1 and 2). Tendon thickness compared to the contralateral side was the same in 15 patients

Table 1. Subscapularis muscle atrophy of the patients in the study according to the MRI Fuchs classification system.

Grade	Number of patients
Grade 0	13 patients
Grade I	3 patients
Grade II	9 patients
Grade III	7 patients
Grade IV	0 patients

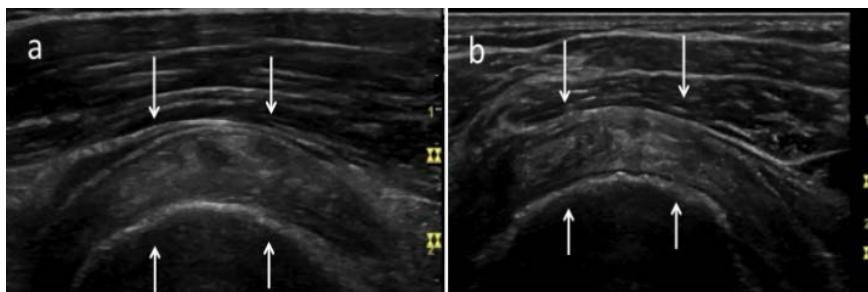


Figure 1. A 52-year old female with traumatic, Romeo type II right subscapularis tendon tear. Transverse scans of (a) normal left subscapularis tendon (b) repaired, intact right subscapularis tendon arrows: subscapularis tendon.

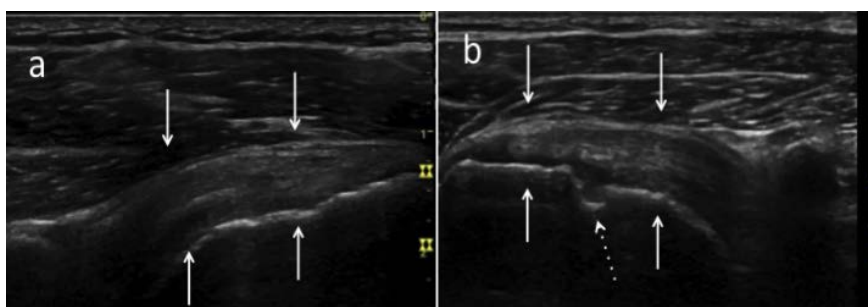

Figure 2. Same patient. Sagittal views of (a) normal left subscapularis tendon (b) repaired, intact right subscapularis tendon arrows: subscapularis tendon, dashed arrow: hole drilled by the surgeons.

and with a difference less than 1 mm in 9 patients. Brightly echogenic suture material was identified within the tendon substance of 13 patients at the initial examination (Figure 3). This absorbable suture material was not visualized in any of the cases at the final endpoint examination. The holes drilled by the surgeons on the lesser tubercle, as well as the suture anchors, were visualized at ultrasound in the majority of shoulders; 26 out of 37 cases (Figure 2).

Twenty-five patients were sonographically found with an intact subscapularis tendon six months after the repair and remained so at the time of the second ultrasound examination (12 months postoperatively). Seven patients were found with a sonographic complete disruption of the subscapularis tendon after 6 months follow-up.

The subscapularis specific clinical tests were assessed as a whole and were positive for retear when one or more of these tests were found positive. At the final endpoint of the follow-up, all group B patients had at least one postoperative positive clinical test indicative for subscapularis retear. On the contrary, all patients with low levels of preoperative atrophy (group A) had excellent outcomes based both on ultrasound and clinical assessment (clinical tests as a composite) (Table 2).

Discussion

The most important finding of our study was that the grade of preoperative subscapularis muscle atrophy can safely predict the postoperative clinical and sonographic outcomes after arthroscopic subscapularis repair. Despite several results have investigated this correlation in tendons of the rotator cuff like supraspinatus or infraspinatus, there is only limited and conflicting evidence regarding subscapularis.

Clinical trials especially focusing on subscapularis arthroscopic repair comprise a very small minority of the published literature regarding rotator cuff arthroscopic repair, yet subscapularis tears cause significant pain and dysfunction for patients.²⁰ The importance of the integrity of subscapularis tendon on shoulder biomechanics, as well as the effects of anterosuperior cuff tears on glenohumeral translation, have been reported in several studies.^{6,8,9} Orthopaedic surgeons are especially interested in the postoperative integrity of the subscapularis tendon, not only in order to restore subscapularis muscle function and pain relief, but also for assuring glenohumeral joint stability. Several researchers have supported that fatty degeneration of the rotator cuff might

be a contraindication to rotator cuff repair, because muscle-tendon units with fatty degeneration do not have the ability to heal.^{14,19} On the contrary, there are only very few clinical data in relation to subscapularis fatty infiltration as an isolated prognostic factor. In a retrospective clinical series of 21 patients, Bartl *et al.* reported that atrophy of the subscapularis muscle was present in about one-fourth of the patients and in all patients with a positive postoperative belly-press test.²¹ The authors focused on the postoperative grade of fatty atrophy and not on the preoperative grading as a predictive factor of the therapeutic result.²¹ According to Nové-Josserand *et al.*, the subjective and functional outcomes were not influenced by the postoperative fatty infiltration of the subscapularis muscle.²²

Regarding our study, higher grades of preoperative MRI subscapularis fat atrophy were documented in those patients who had at least one positive clinical test indicating subscapularis retear during their follow-up.

So, all patients who had been graded as stage II or more were found clinically suspicious for retear. On the contrary, patients who had minor or no preoperative subscapularis muscle atrophy (grade I or 0) had no clinical or sonographic signs of retear at their follow-up. These results confirmed our initial hypothesis and proved that the theory of fatty infiltration as preoperative prognostic factor works also in the case of subscapularis tears. So, the preoperative MRI status of the subscapularis muscle should be always taken into consideration by the treating physician who should individualize the treatment's and rehabilitation's protocol in order to achieve optimal results.

This study was not without limitations. First of all, the number of patients was rather small and no randomized control group was used. The follow-up was relatively short, while the design of the study was retrospective. On the other hand, this was a double-center, multinational study, while the data were prospectively collected.

Table 2. Relation between the severity of the preoperative MRI fatty atrophy with the postoperative incidence of clinical retear and sonographic retear.

Muscle atrophy	N. patients	Postoperative clinical retear	Postoperative sonographic retear
Grade 0	13 patients	No one (0/13)	No one (0/13)
Grade I	3 patients	No one (0/3)	No one (0/3)
Grade II	9 patients	9/9 (100%)	3/9 (33%)
Grade III	7 patients	7/7 (100%)	4/7 (57.1%)
Grade IV	0 patients	-	-

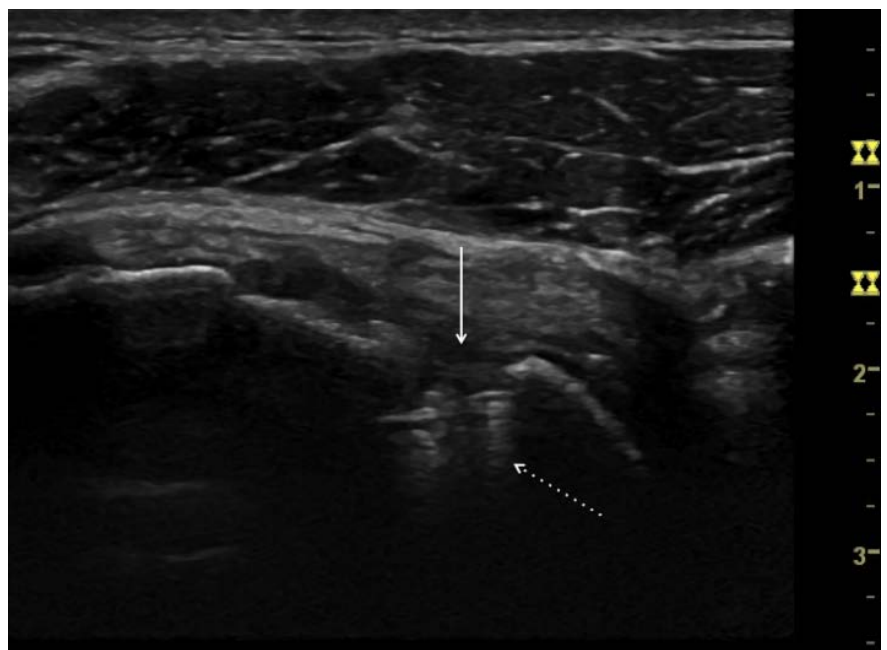


Figure 3. Ultrasound examination 12 months after the repair (transverse scan). The hole drilled on the lesser tubercle (arrow) and the anchor (dashed arrow) is demonstrated.

We divided our sample into two groups in order to make statistical comparisons between the different grades of fatty infiltration and assess it as a preoperative prognostic factor. In addition, the postoperative assessment was carried out by investigators who were unaware of the preoperative MRI values.

Conclusions

Low grades of preoperative subscapularis muscle atrophy are significantly correlated with low clinical and sonographic retear's rate after subscapularis arthroscopic repair, while high grades were a negative prognostic factor for the clinical outcome of these patients.

References

- Halder A, Zobitz ME, Schultz E, An KN. Structural properties of the subscapularis tendon. *J Orthop Res* 2000;18:829-3.
- Arai R, Sugaya H, Mochizuki T, et al. Subscapularis tendon tear: an anatomic and clinical investigation. *Arthroscopy* 2008;24:997-1004.
- Longo UG, Berton A, Papapietro N, et al. Biomechanics of the rotator cuff: European perspective. *Med Sport Sci* 2012;57:10-7.
- Lee SB, Kim KJ, O'Driscoll SW, et al. Dynamic glenohumeral stability provided by the rotator cuff muscles in the mid-range and end-range of motion. A study in cadavera. *J Bone Joint Surg Am* 2000;82:849-57.
- Halder AM, Zhao KD, Odriscoll SW, et al. Dynamic contributions to superior shoulder stability. *J Orthop Res* 2001; 19:206-12.
- Steenbrink F, de Groot JH, Veeger HE, et al. Glenohumeral stability in simulated rotator cuff tears. *J Biomech* 2009;42:1740-5.
- Su WR, Budoff JE, Luo ZP. The effect of anterosuperior rotator cuff tears on glenohumeral translation. *Arthroscopy* 2009;25:282-9.
- Hsu HC, Luo ZP, Cofield RH, An KN. Influence of rotator cuff tearing on glenohumeral stability. *J Shoulder Elbow Surg* 1997;6:413-22.
- Thompson WO, Debski RE, Boardman ND 3rd, et al. A biomechanical analysis of rotator cuff deficiency in a cadaveric model. *Am J Sports Med* 1996;24:286-92.
- Parsons IM, Apreleva M, Fu FH, Woo SL. The effect of rotator cuff tears on reaction forces at the glenohumeral joint. *J Orthop Res* 2002;20:439-46.
- Oh JH, Kim SH, Ji HM, et al. Prognostic factors affecting anatomic outcome of rotator cuff repair and correlation with functional outcome. *Arthroscopy* 2009;25:30-9.
- Oh JH, Kim SH, Kang JY, et al. Effect of age on functional and structural outcome after rotator cuff repair. *Am J Sports Med* 2010;38:672-8.
- Burkhart SS, Barth JR, Richards DP, et al. Arthroscopic repair of massive rotator cuff tears with stage 3 and 4 fatty degeneration. *Arthroscopy* 2007;23:347-54.
- Gladstone JN, Bishop JY, Lo IK, Flatow EL. Fatty infiltration and atrophy of the rotator cuff do not improve after rotator cuff repair and correlate with poor functional outcome. *Am J Sports Med* 2007;35:719-28.
- Jeong HY, Kim HJ, Jeon YS, Rhee YG. Factors Predictive of Healing in Large Rotator Cuff Tears: Is It Possible to Predict Retear Preoperatively? *Am J Sports Med* 2018;363546518762386.
- Lee YS, Jeong JY, Park CD, et al. Evaluation of the Risk Factors for a Rotator Cuff Retear After Repair Surgery. *Am J Sports Med* 2017;45:1755-1761.
- Kim JY, Park JS, Rhee YG. Can Preoperative Magnetic Resonance Imaging Predict the Reparability of Massive Rotator Cuff Tears? *Am J Sports Med* 2017;45:1654-63.
- Fuchs B, Weishaupt D, Zanetti M, et al. Fatty degeneration of the muscles of the rotator cuff: assessment by computed tomography versus magnetic resonance imaging. *J Shoulder Elbow Surg* 1999;8:599-605.
- Goutallier D, Postel JM, Gleyze P, et al. Influence of cuff muscle fatty degeneration on anatomic and functional outcomes after simple suture of full-thickness tears. *J Shoulder Elbow Surg* 2003;12:550-4.
- Mall NA, Chahal J, Heard WM, et al. Outcomes of arthroscopic and open surgical repair of isolated subscapularis tendon tears. *Arthroscopy* 2012;8:1306-14.
- Bartl C, Salzmann GM, Seppel G, et al. Subscapularis function and structural integrity after arthroscopic repair of isolated subscapularis tears. *Am J Sports Med* 2011;39:1255-62
- Nové-Josserand L, Hardy MB, Leandro Nunes Ogassawara R, et al. Clinical and structural results of arthroscopic repair of isolated subscapularis tear. *J Bone Joint Surg Am* 2012;94:e125.