

Retropupillary iris-claw intraocular lens implantation in aphakic patients

C V Sumitha, Vijay Pai, Mithun Thulasidas¹

Purpose: To evaluate the outcomes of implantation of an iris-claw intraocular lens (IC-IOL) in retropupillary position in aphakic patients. **Methods:** We conducted a prospective interventional study, including 36 aphakic eyes with inadequate capsular support. The postoperative examination included best-corrected visual acuity (BCVA), intraocular pressure (IOP) measurement, central corneal thickness (CCT), and anterior segment examination with emphasis on the anterior chamber reaction and shape of pupil. Follow-up was done for 3 months. **Results:** Thirty-six eyes of 34 patients, including 22 right eyes and 14 left eyes were included. Indications for surgery were complicated cataract surgery in 38.9% ($n = 14$), aphakia in 27.8% ($n = 10$), pseudophakic bullous keratopathy in 16.7% ($n = 6$), dislocated posterior chamber IOL (PCIOL) in 11.1% ($n = 4$), IC drop in 2.8% ($n = 1$), and subluxated PCIOL in 2.8% ($n = 1$). Postoperatively, the visual acuity improved by at least two lines in 32 (88.9%) and worsened in four (11.1%) eyes at the end of three months. Mean postoperative IOP at the end of the third month was 12.42 mmHg (standard deviation [SD] 2.57; range 11.55–13.29 mmHg). The mean postoperative CCT at the end of the third month was 542.42 microns (SD 13.77; range 537.76–547.07 microns). Sixteen eyes (44.4%) had horizontally oval pupil, eleven eyes (30.6%) had round pupil, and nine eyes (25%) had irregular pupil. Twenty-three eyes (63.9%) presented with significant anterior chamber reaction and seven eyes (19.4%) had corneal stromal edema on postoperative day 1. **Conclusion:** Our study demonstrated that retropupillary IC-IOL implantation in eyes without adequate capsular support is an effective and safe procedure with a good visual outcome and fewer complications.

Key words: Aphakia, cataract, Iris-claw IOL, retropupillary

The management of aphakia because of complicated cataract surgery is challenging for a cataract surgeon. The loss of the posterior capsule and/or ciliary zonules results in inadequate support for the implantation of a standard posterior chamber intraocular lens (PCIOL).^[1]

Secondary IOL implantation in a case of loss of capsular support includes angle supported anterior chamber IOLs (ACIOL), scleral supported (different surgical techniques), and iris-claw (IC) anterior chamber and retropupillary IOLs.

Sizing is the major drawback of anterior chamber angle-supported IOLs. An appropriate diameter of the lens relative to the diameter of the anterior chamber is needed to maintain the lens in position and prevent complications. As the availability of different diameters is limited, complications related to incorrect sizing are common. Short lens results in rotation and/or dislocation, increasing the risk of corneal endothelial decompensation and damage to the angle of anterior chamber. The excess pressure on the iris root caused by a large IOL increases the damage to the angle of anterior chamber and can result in peripheral anterior synechiae formation, increased intraocular pressure (IOP), and glaucoma. Other major complications include dyscoria and decentered pupils, chronic uveitis, and cystoid macular edema. On the

other hand, implantation of angle-supported IOLs is easier, with lesser surgical time.^[2-6]

The scleral fixation of PCIOL implantation has the main advantages like the more physiological location in the eye as an optical system, nearer to the plane of the crystalline lens, and the increased distance from the cornea, which decreases the risk of corneal endothelial decompensation.^[7,8] However, serious complications are related to scleral fixation, such as retinal detachment, choroidal hemorrhage, and endophthalmitis related to transscleral sutures.^[9-13] In cases where sufficient capsular support is observed intraoperatively, a PCIOL can be implanted in the ciliary sulcus, without the need of scleral sutures.^[14]

Prof. Jan Worst developed the IC-IOL attached to the anterior iris in 1972.^[15] He introduced a technique to correct the aphakia in the absence of capsular support and without compromising the angle of anterior chamber. However, a major complication associated with it is damage to the corneal endothelium,^[16] mainly in patients with narrow anterior chambers and in corneal transplantation. Brasse and Neuhann^[17] modified this technique by clipping the lens to the

Department of Ophthalmology, K.S Hegde Charitable Hospital, Deralakatte, Mangalore, Karnataka, ¹Centre for Sight Eye Institute, Plot No. 9, Sector 9, Dwarka, New Delhi, India

Correspondence to: Dr. C V Sumitha, Department of Ophthalmology, K.S Hegde Charitable Hospital, Deralakatte, Mangalore - 575 018, Karnataka, India. E-mail: sumithacv@gmail.com

Received: 03-Jun-2019

Revision: 17-Sep-2019

Accepted: 22-Oct-2019

Published: 16-Mar-2020

Access this article online

Website:

www.ijo.in

DOI:

10.4103/ijo.IJO_1043_19

Quick Response Code:



This is an open access journal, and articles are distributed under the terms of the Creative Commons Attribution-NonCommercial-ShareAlike 4.0 License, which allows others to remix, tweak, and build upon the work non-commercially, as long as appropriate credit is given and the new creations are licensed under the identical terms.

For reprints contact: reprints@medknow.com

Cite this article as: Sumitha CV, Pai V, Thulasidas M. Retropupillary iris-claw intraocular lens implantation in aphakic patients. Indian J Ophthalmol 2020;68:597-602.

posterior iris, thereby protecting the endothelial layer of cornea, with the A-constant altered accordingly to 117.0. Secondary implantations of retropupillary IC-IOL have been the preferred procedure in cases where iris support is feasible.^[18] As IC-IOL is attached to the midperiphery of the iris, complications related to the size of IOL and damage to the angle of anterior chamber and the root of iris are avoided. The unique enclavation system allows centration of the IOL on the pupillary axis, which is important in eyes with decentered pupils. Also, IC-IOLs do not interfere with iris physiological vascularization or cause distortion of pupil.^[19]

The IC lens implantation can be combined with penetrating keratoplasty, as the surgery would take lesser time with IC-IOL.^[20] The IC-IOL used for correction of aphakia is made of rigid polymethylmethacrylate (PMMA). Its implantation needs a 5.4-mm corneal or scleral incision. A foldable IC-IOL, with a smaller corneal incision, would reduce surgery time and would help in reducing postoperative complications.^[21]

The purpose of this study was to evaluate the outcomes of retropupillary implantation of IC-IOL in patients with inadequate capsular support.

Methods

A prospective interventional study was conducted at our hospital for a period of 2 years (October 2016–October 2018), including 36 aphakic eyes with inadequate capsular support. The criteria of inclusion in the study were aphakic patients secondary to previous cataract surgery, complicated cataract surgery/intraoperative posterior capsule rupture, zonular dialysis, bullous keratopathy with loss of capsular support, and dislocated/subluxated IOL. The exclusion criteria included gross iris abnormalities like aniridia or iris new vessels, glaucoma, and uveitis. The ethical committee approval was obtained before beginning the study and informed consent was obtained from each patient according to the tenets of the Declaration of Helsinki.

A detailed history, both ocular and medical, was elicited from all patients. General examination, including the physical condition of the patient and basic vitals, was also recorded and documented. Preoperatively, all patients had undergone complete ophthalmologic evaluation, including uncorrected visual acuity (UCVA), subjective refraction, best-corrected visual acuity (BCVA), slit-lamp examination, keratometry, applanation A-scan biometry (A constant used for IOL power calculation is 117.0 and SRK/T formula was used), central corneal thickness (CCT) using pachymetry, intraocular pressure (IOP) measurement using schiottz tonometer, retinal evaluation using 90 diopter and indirect ophthalmoscopy, and a B-scan in cases where fundus could not be visualized. The same surgeon performed all surgeries. Single piece PMMA IC-IOL with an optic diameter of 5.5 mm, overall diameter of 8.5 mm, modified convex–concave version with the postoperative vaulted design was used.

Surgical technique

Under general/local anesthesia, superior or temporal, 5.5 mm sclero-corneal/clear corneal incision/enlargement of previously done tunnel in secondary cases was done. Two paracenteses were made at 9 and 3 o'clock positions

from the main section. Intracameral pilocarpine was used whenever required. Anterior vitrectomy was done whenever required. IC-IOL was introduced into the anterior chamber through main section. A small amount of viscoelastic (2% hydroxypropylmethylcellulose) was injected on the peripheral iris. Holding the optic with a lens forceps, one haptic was tilted down and pushed under the iris with gentle manipulation. A sinsky hook was passed through the same side port. The haptic was tilted up to produce an indent on the iris. The iris was enclaved into the haptic claw with gentle push with the sinsky hook. A similar maneuver was done through the other side port after switching the hands. Viscoelastic was aspirated with simcoe cannula/I and A aspiration cannula, anterior chamber was formed with balanced salt solution and conjunctiva repositioned. Gatifloxacin 0.3% and prednisolone acetate 1% drops were prescribed after surgery and slowly tapered over time.

Combined penetrating keratoplasty

Under general/local anesthesia, corneal trephination was done. Cohesive viscoelastic material was injected into the anterior chamber. IOL was removed and synechiolysis of the angle was done if needed. The IC-IOL was then inserted with the open sky technique. Intracameral pilocarpine was used whenever required. The IOL claw was enclaved into the iris. Peripheral iridectomy was performed in all cases. The corneal donor tissue was then sutured to the host bed using interrupted sutures and viscoelastic material was removed. Gatifloxacin 0.3% and prednisolone acetate 1% drops were prescribed after surgery and slowly tapered over time. Systemic immunosuppressive agents were not used.

Postoperative examination on day 1 included BCVA, IOP measurement using schiottz tonometer, CCT using pachymetry, anterior segment examination with emphasis on AC reaction (>grade 2 cells and flare) and shape of the pupil. Follow-up was done after a week, then at a month, and at 3 months also.

Statistical analysis was performed on the Statistical Package for Social Sciences (SPSS) version 17.0 for Windows. Descriptive statistics, such as frequency and percentage for qualitative data and mean with standard deviation (SD) for quantitative data, were used. The Friedman test, repeated measures analysis of variance (ANOVA), and Wilcoxon signed-rank test were used for analyzing the data. A probability value (*P*-value) of <0.05 was considered as statistically significant.

Results

Thirty-six eyes of 34 patients (17 males and 17 females) were included. Twenty-two (61.1%) were right eyes and 14 (38.9%) were left eyes. The mean age was 59.92 years with a SD of 12.31, ranging from 13 to 74 years. The majority (79%) of the patients were in the age group of 50 to 70 years. Indications for retropupillary implantation of IC-IOL were complicated cataract surgery in 38.9% (*n* = 14), aphakia in 27.8% (*n* = 10), pseudophakic bullous keratopathy with ACIOL and loss of capsular support in 16.7% (*n* = 6), dislocated PCIOL in 11.1% (*n* = 4), IC drop in 2.8% (*n* = 1), and subluxated PCIOL in 2.8% (*n* = 1) [Fig. 1]. IC-IOL was implanted in the same sitting in all complicated cataract surgeries (*n* = 14) with extensive posterior capsule rupture. Other cases (*n* = 22) were referred to our center for secondary IOL implantation.

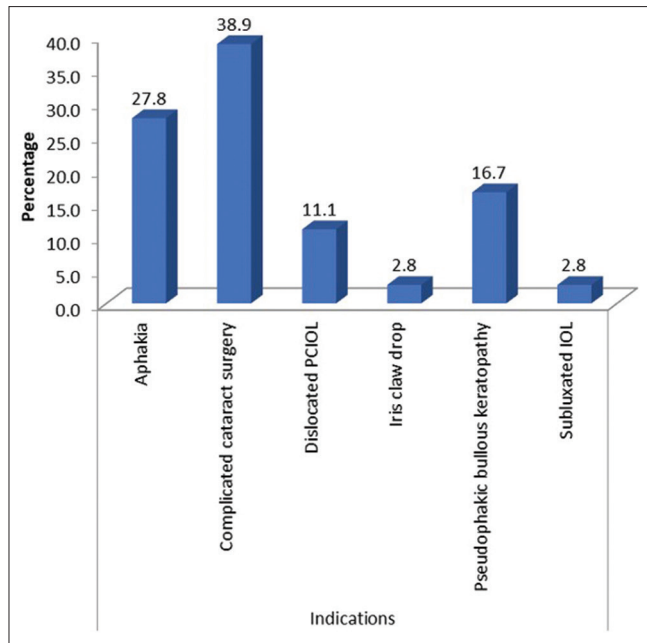


Figure 1: Indications for retropupillary iris-claw intraocular lens implantation

Preoperatively, 19 eyes (52.8%) presented with BCVA of logarithm of minimum angle of resolution (logMAR) >1, 14 eyes (38.9%) had BCVA of logMAR 1.0–0.6 and 3 eyes (8.3%) had BCVA of logMAR ≤/ = 0.48. Three months postoperatively, four eyes (11.1%) had BCVA of logMAR >1.0, 3 eyes (8.3%) had BCVA of logMAR 1.0–0.6 and 29 eyes (80.6%) had BCVA of logMAR ≤/ = 0.48 ($P < 0.05$) [Fig. 2]. Of 36 eyes, the visual acuity improved by at least two lines (Snellen chart) in 32 (88.9%) and worsened in four (11.1%).

Mean preoperative IOP was 12.79 mm Hg (SD 3.17; range 11.72–13.86 mmHg). Mean postoperative IOP on day 1 was 14.28 mmHg (SD 4.07; range 12.90–15.65 mmHg). Mean postoperative IOP at the end of the third month was 12.42 mmHg (SD 2.57; range 11.55–13.29 mmHg) [Fig. 3]. Mean preoperative CCT was 556.08 microns (SD 42.43; range 541.73–570.44 microns). Mean postoperative CCT on day 1 was 547.31 microns (SD 16.89; range 541.59–553.02 microns). Mean postoperative CCT at the end of the third month was 542.42 microns (SD 13.77; range 537.76–547.07 microns) [Fig. 4].

Postoperatively, 16 eyes (44.4%) had horizontally oval pupil, 11 eyes (30.6%) had a round pupil [Fig. 5], and 9 eyes (25%) had irregular pupil. Twenty-three eyes (63.9%) presented with significant anterior chamber reaction (>= grade 2 cells and flare) and seven eyes (19.4%) had corneal stromal edema on postoperative day 1.

Discussion

Secondary IOL implantation in the absence of adequate posterior capsular support is challenging for cataract surgeons. It can also be combined with other surgical techniques such as penetrating keratoplasty, as in our study. Surgical correction of aphakia can be performed using ACIOL, scleral fixated IOL (SFIOL), glued IOLs, and IC-IOLs.^[22]

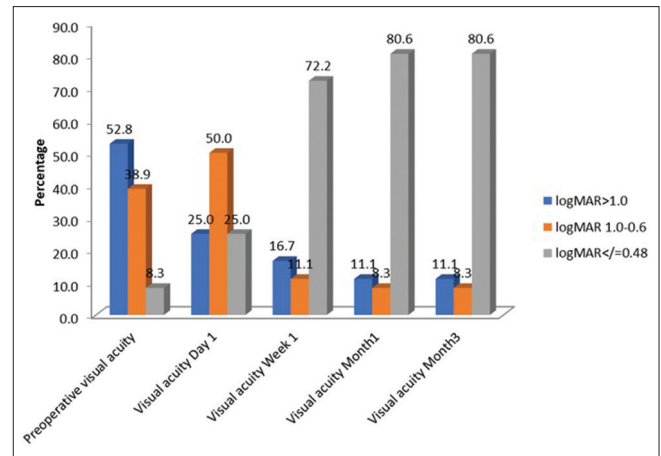


Figure 2: Preoperative and postoperative best-corrected visual acuity, Friedman test $P = 0.0001$, highly significant; Wilcoxon signed-rank test: $P = 0.000$, highly significant when preop was compared with postop (at the end of 3 months)

The modern ACIOLs with flexible haptics, though technically easier to place and easily available, can lead to significant complications including angle trauma with hyphema, clefts, secondary glaucoma, uveitis, and corneal endothelial decompensation from progressive endothelial trauma.^[22-24] In cases of corneal transplantation where corneal endothelium is already compromised, there is a risk of graft rejection. In a study conducted by Marques *et al.*, the main indication for IOL exchange was ACIOL related inflammation.^[25] Another technique is suturing the haptics of a three-piece IOL to the peripheral posterior iris.^[26]

Scleral fixation of IOL is usually performed with different suture methods^[27] and tissue adhesive.^[28] This technique has a long-term risk of IOL dislocation from breakage of the polypropylene suture^[29] and includes manipulation of the vitreous base with a greater tendency for retinal tears, retinal detachment, and hemorrhage.^[30] SFIOLs had more complications, both intraoperatively and postoperatively according to a study by Belluci *et al.*^[9] A study of glued IOLs by Kumar DA *et al.* observed complications like IOL decentration, haptic extrusion, pigment dispersion, cystoid macular edema.^[31]

In 1980s, the concept of IC-IOLs being implanted anterior to the iris was popularized by Prof. Jan Worst.^[15] from Holland and Dr. Daljeet Singh from India.^[32] The anterior position of the IOL has the advantage of technically straightforward insertion and enclavation but puts the corneal endothelium at risk.^[16] The posterior chamber placement as introduced by Brasse and Neuhann,^[17] protects the endothelium from the IOL. Iris tissue thickness should be adequate for enclavation and a blunt instrument like a Sinsky hook is useful to reduce perforation of iris. The IC-IOL is contraindicated in ocular trauma cases with extensive loss of iris tissue or widely dilated pupil. The posterior placement of IC-IOLs has the advantage of a simpler procedure, positioning near the nodal point without the use of extra sutures or glue.^[33] Various studies have advocated the use of IC-IOL in aphakic patients with inadequate capsular support.^[1,19-21,34]

All our patients completed the 3 months follow-up period. In our study, male female ratio was 1:1 and right

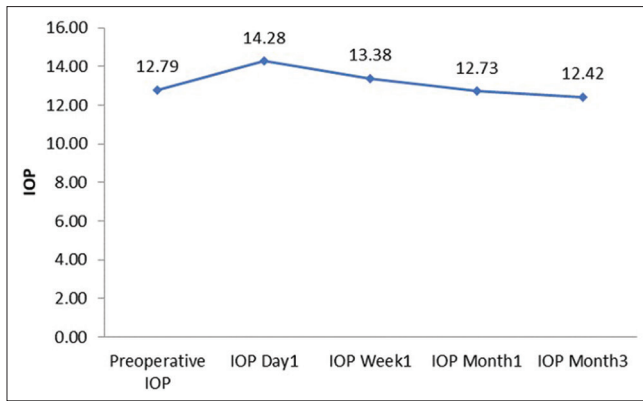


Figure 3: Preoperative and postoperative mean intraocular pressure, repeated measures analysis of variance, Wilcoxon signed-rank test: $P > 0.05$, no statistically significant differences when preop was compared with postop (at the end of 3 months)

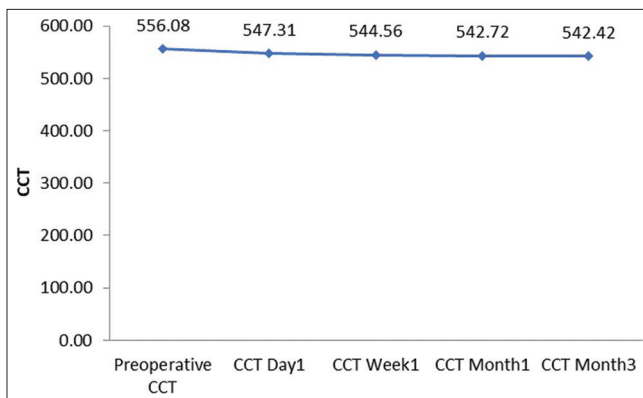


Figure 4: Preoperative and postoperative mean central corneal thickness, repeated measures analysis of variance, Wilcoxon signed-rank test: $P > 0.05$, no statistically significant differences when preop was compared with postop (at the end of 3 months)

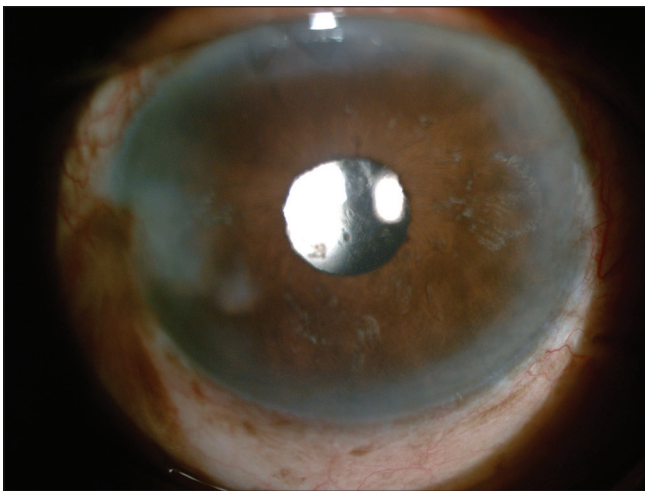


Figure 5: Round pupil after iris-claw intraocular lens implantation

eye was involved in 61.1% of the cases. The mean age was 59.92 ± 12.31 years (range: 13–74 years). Major of the indications for retropupillary IC-IOL implantation were found to be complicated cataract surgery (38.9%) and aphakia (27.8%),

which was in accordance with the studies done by Sezer Helvacı *et al.*^[35] and Maurice Schallenberg *et al.*^[34]

In our series, 88.9% of the eyes had improved BCVA postoperatively which is comparable to a study by DeSilva *et al.* (88.7%)^[36] and higher as compared to a study by Labeille *et al.* (68.8%).^[37] Preoperatively, 3 eyes (8.3%) had BCVA of logMAR ≤ 0.48 . Three months postoperatively, 29 eyes (80.6%) had BCVA of logMAR ≤ 0.48 . Of 36 eyes, the visual acuity improved by at least two lines (Snellen chart) in 32 (88.9%) and worsened in four (11.1%). Deterioration of vision was attributed to corneal graft astigmatism in two eyes, neovascular age-related macular degeneration (AMD) in one eye and cystoid macular edema (CME) in one eye. A patient who developed neovascular AMD had been given multiple anti-VEGF injections in the past, but there was no evidence of activity or subretinal fluid prior to surgery on macular optical coherence tomography and fluorescein angiography. The release of inflammatory mediators after surgical manipulation could be the etiology for both neovascular AMD and CME. Vitreo-retina specialist's opinion was taken for both cases, and they were treated with injection ranibizumab 0.5 mg (0.05 mL of 10 mg/mL solution) and posterior subtenon triamcinolone 20 mg/0.5 mL, respectively. All patients with deterioration of vision were on regular follow-ups.

Improvement of visual acuity was noted in four of six eyes, which underwent combined procedure (penetrating keratoplasty) which is in accordance with the study done by Rufer *et al.*^[20] However, combined surgery limited the refractive results with the unpredictable mire changes, which are likely postoperatively.^[1] In our study, grafts did not show any sign of rejection. No increased risk for the graft could be observed in retropupillary IC-IOL implantation; hence, this approach is recommendable in cases requiring combined keratoplasty.^[20]

Mean preoperative IOP was 12.79 ± 3.17 mmHg (range: 11.72–13.86 mmHg) and mean postoperative IOP on day 1 was 14.28 ± 4.07 mmHg (range: 12.90–15.65 mmHg). One patient who underwent combined keratoplasty had raised IOP on day 1, which was managed conservatively with oral acetazolamide. Similar to our study, raised IOP was found in 1 patient by Schallenberg *et al.*^[34] In another study done by Nana Madhukar Jare *et al.*,^[38] 3 out of 108 eyes had raised IOP in the first week postoperatively which were managed with Nd:YAG peripheral iridectomy. An increase in IOP in our case could be due to retained viscoelastic material. As there is some evidence, that pupillary block cannot happen in eyes with retropupillary IC-IOL implantation,^[39] iridectomy was not considered mandatory in our study series. Mean postoperative IOP at the end of the third month was 12.42 ± 2.57 mmHg (range: 11.55–13.29 mmHg) and no statistically significant IOP changes were noted when compared with preoperative values.

Mean preoperative CCT was 556.08 ± 42.43 microns (range: 541.73–570.44 microns). Mean postoperative CCT at the end of the third month was 542.42 ± 13.77 microns (range: 537.76–547.07 microns) and no statistically significant changes were noted when compared with preoperative CCT.

In our study, 16 eyes (44.4%) had horizontally oval pupil followed by 11 eyes (30.6%) with a round pupil and 9 eyes (25%) with irregular pupil postoperatively. No cases required any intervention for pupillary distortion. Twenty-three

eyes (63.9%) presented with significant anterior chamber reaction and seven eyes (19.4%) had corneal stromal edema on postoperative day 1, which improved with subsequent follow-ups. No other added medications were needed other than topical antibiotic-steroids. In their study, Forlini *et al.*^[40] did not see chronic anterior chamber inflammation in any case which is similar to our study.

One case had a history of IC drop into the vitreous cavity, which was believed to be due to inadequate iris enclavation due to faulty claws. Spontaneous disenclavation of one or both IC haptics with or without dislocation of IOL had been reported before.^[40] Long-term observations are needed to assess the stability of anchoring after implantation of IC-IOL. The incidence of CME ($n = 1$) was less in our study compared to the studies done by Nana Madhukar Jare *et al.*,^[38] DeSilva *et al.*^[36] and studies on other types of secondary IOLs.^[3,19] None of our patients had retinal detachment, hyphema or hypotony.

The limitation of this study was its relatively small sample size and short follow-up. Studies with larger sample size and longer follow-up are needed to demonstrate the superiority of IC-IOLs and probable long-term complications.

Conclusion

Our study demonstrates that retropupillary IC-IOL implantation in aphakic eyes without adequate capsular support is a safe, predictable and effective procedure with a good visual outcome and less intraoperative and postoperative complications.

Financial support and sponsorship

Nil.

Conflicts of interest

There are no conflicts of interest.

References

- Hsing Y, Lee G. Retropupillary iris claw intraocular lens for aphakia. *Clin Exp Ophthalmol* 2012;40:849-54.
- Weene LE. Flexible open-loop anterior chamber intraocular lens implants. *Ophthalmology* 1993;100:1636-9.
- Ellerton CR, Rattigan SM, Chapman FM, Chitkara DK, Smerdon DL. Secondary implantation of open-loop, flexible, anterior chamber intraocular lenses. *J Cataract Refract Surg* 1996;22:951-4.
- Biro Z. Results and complications of secondary intraocular lens implantation. *J Cataract Refract Surg* 1993;19:64-7.
- Hykin PG, Gardner ID, Corbett MC, Cheng H. Primary or secondary anterior chamber lens implantation after extracapsular cataract surgery and vitreous loss. *Eye* 1991;5:694-8.
- Drolsum L, Haaskjold E. Secondary implantation of flexible open loop anterior chamber IOLs. *Acta Ophthalmol (Copenh)* 1993;71:482-6.
- Stark WJ, Gottsch JD, Goodman DF, Goodman GL, Prutzer K. Posterior chamber intraocular lens implantation in the absence of capsular support. *Arch Ophthalmol* 1989;107:1078-83.
- Brunette I, Stulting RD, Rinne JR, Waring JO 3rd, Gemmil M. Penetrating keratoplasty with anterior or posterior chamber intraocular lens implantation. *Arch Ophthalmol* 1994;112:1311-9.
- Bellucci R, Pucci V, Morselli S, Bonomi L. Secondary implantation of angle-supported anterior chamber and scleral-fixated posterior chamber intraocular lenses. *J Cataract Refract Surg* 1996;22:247-52.
- Malta JB, Banitt M, Musch DC, Sugar A, Mian SI, Soong HK. Long-term outcome of combined penetrating keratoplasty with scleral-sutured posterior chamber intraocular lens implantation. *Cornea* 2009;28:741-6.
- Mannarino AP, Hannush SB. A new technique for transscleral fixation of a posterior chamber intraocular lens in the absence of capsular support during penetrating keratoplasty. *Refract Corneal Surg* 1990;6:353-6.
- McCluskey P, Harrisberg B. Long-term results using scleral fixated posterior chamber intraocular lenses. *J Cataract Refract Surg* 1994;20:34-9.
- Chang JH, Lee JH. Long-term results of implantation of posterior chamber intraocular lens by suture fixation. *Korean J Ophthalmol* 1991;5:42-6.
- Güell JL, Verdaguer P, Elies D, Gris O, Manero F, Morral M. Secondary iris claw anterior chamber lens implantation in patients with aphakia without capsular support. *Br J Ophthalmol* 2014;98:658-63.
- Worst JG. Iris claw lens. *J Am Intraocul Implant Soc* 1980;6:166-7.
- Menezo JL, Cisneros AL, Rodriguez-Salvador V. Endothelial study of iris-claw phakic lens: Four year follow-up. *J Cataract Refract Surg* 1998;24:1039-49.
- Brasse K, Neuhann TH. Posterior chamber Verisyse lens implantation to correct aphakia without capsular support. *Video J Cataract Refract Surg* 2004;20.
- Bellamy JP, Queguiner F, Salamé N, Montard M. Secondary intraocular lens implantation: Methods and complications. *J Fr Ophthalmol* 2000;23:73-80.
- Menezo JL, Martinez MC, Cisneros AL. Iris-fixated Worst claw versus sulcus-fixated posterior chamber lenses in the absence of capsular support. *J Cataract Refract Surg* 1996;22:1476-84.
- Rufer F, Saeger M, Nolle B. Implantation of retropupillary iris claw lenses with and without combined penetrating keratoplasty. *Graefes Arch Clin Exp Ophthalmol* 2009;247:457-62.
- Faria M, Pinto Ferreira N, Gama I, Medeiros Pinto J, Canastro M, Monteiro Grillo M. Retropupillary positioning of foldable iris-claw intraocular lens for correction of aphakia with no capsular support. *Int Med Case Rep J* 2016;9:337-40.
- Evereklioglu C, Er H, Bekir NA, Borazan M, Zorlu F. Compassion of secondary implantation of flexible open-loop anterior chamber and scleral-fixated posterior chamber intraocular lenses. *J Cataract Refract Surg* 2003;29:301-8.
- Downing JE. Ten-year follow up comparing anterior and posterior chamber intraocular lens implants. *Ophthalmic Surg* 1992;23:308-15.
- Hara T, Hara T. Ten-year results of anterior chamber fixation of the posterior chamber intraocular lens. *Arch Ophthalmol* 2004;122:1112-6.
- Marques FF, Marques DM, Osher RH, Freitas LL. Longitudinal study of intraocular lens exchange. *J Cataract Refract Surg* 2007;33:254-7.
- Condon GP. Simplified small-incision peripheral iris fixation of an AcrySof intraocular lens in the absence of capsule support. *J Cataract Refract Surg* 2003;29:1663-7.
- Por YM, Lavin MJ. Techniques of intraocular lens suspension in the absence of capsular/zonular support. *Surv Ophthalmol* 2005;50:429-62.
- Agarwal A, Kumar DA, Jacob S, Baid C, Agarwal A, Srinivasan S. Fibrin glue-assisted sutureless posterior chamber intraocular lens implantation in eyes with deficient posterior capsules. *J Cataract Refract Surg* 2008;34:1433-8.
- Price MO, Price FW Jr, Werner L, Berlie C, Mamalis N. Late dislocation of sclera-sutured posterior chamber intraocular lenses. *J Cataract Refract Surg* 2005;31:1320-6.

30. Versace P. Retropupillary implantation of the iris claw lens for aphakia. *Tech Ophthalmol* 2007;5:50-5.
31. Kumar DA, Agarwal A, Packiyalakshmi S, Jacob S, Agarwal A. Complications and visual outcomes after glued foldable intraocular lens implantation in eyes with inadequate capsules. *J Cataract Refract Surg* 2013;39:1211-8.
32. Singh D. Iris claw lens- Six years' experience. *Indian J Ophthalmol* 1986;34:181-2.
33. Hazar L, Kara N, Bozkurt E, Ozgurhan EB, Demirok A. Intraocular lens implantation procedures in aphakic eyes with insufficient capsular support associated with previous cataract surgery. *J Refract Surg* 2013;29:685-91.
34. Schallenberg M, Dekowski D, Hahn A, Laube T, Steuhl K, Meller D. Aphakia correction with retropupillary fixated iris-claw lens (Artisan) – long-term results. *Clinical Ophthalmology* 2014;8:137-41.
35. Helvacı S, Demirduzen S, Oksuz H. Iris-claw intraocular lens implantation: Anterior chamber versus retropupillary implantation. *Indian J Ophthalmol* 2016;64:45-9.
36. De Silva SR, Arun K, Anandan M, Glover N, Patel CK, Rosen P. Iris-claw intraocular lenses to correct aphakia in the absence of capsule support. *J Cataract Refract Surg* 2011;37:1667-72.
37. Labielle E, Burillon C, Cornut PL. Pars plana vitrectomy combined with iris-claw intraocular lens implantation for lens nucleus and intraocular lens dislocation. *J Cataract Refract Surg* 2014;40:1488-97.
38. Jare NM, Kesari AG, Gadkari SS, Deshpande MD. The posterior iris-claw lens outcome study: 6 month follow-up. *Indian J Ophthalmol* 2016;64:878-83.
39. Brandner M, Thaler-Saliba S, Plainer S, Vidic B, El-Shabrawi Y, Ardjomand N. Retropupillary Fixation of Iris-Claw Intraocular Lens for Aphakic Eyes in Children. *PLoS One* 2015;10:e0126614.
40. Forlini M, Soliman W, Bratu A, Rossini P, Cavallini GM, Forlini C. Long-term follow-up of retropupillary iris-claw intraocular lens implantation: A retrospective analysis. *BMC Ophthalmol* 2015;15:143.