



Intravascular Placement of Metallic Coils as Lung Tumor Markers for CyberKnife Stereotactic Radiation Therapy

Kutlay Karaman, MD¹, A. Murat Dokdok, MD¹, Oktay Karadeniz, MD¹, Cemile Ceylan, MSc², Kayhan Engin, MD²

Departments of ¹Radiology and ²Radiation Oncology, Anadolu Medical Center, Kocaeli 41400, Turkey

Objective: To present our experience with placing endovascular coils in pulmonary arteries used as a fiducial marker for CyberKnife therapy and to describe the technical details and complications of the procedure.

Materials and Methods: Between June 2005 and September 2013, 163 patients with primary or secondary lung malignancies, referred for fiducial placement for stereotactic radiosurgery, were retrospectively reviewed. Fourteen patients (9 men, 5 women; mean age, 70 years) with a history of pneumonectomy (n = 3), lobectomy (n = 3) or with severe cardiopulmonary co-morbidity (n = 8) underwent coil (fiducial marker) placement. Pushable or detachable platinum micro coils (n = 49) 2–3 mm in size were inserted through coaxial microcatheters into a small distal pulmonary artery in the vicinity of the tumor under biplane angiography/fluoroscopy guidance.

Results: Forty nine coils with a median number of 3 coils per tumor were placed with a mean tumor-coil distance of 2.7 cm. Forty three (87.7%) of 49 coils were successfully used as fiducial markers. Two coils could not be used due to a larger tumor-coil distance (> 50 mm). Four coils were in an acceptable position but their non-coiling shape precluded tumor tracking for CyberKnife treatment. No major complications needing further medication other than nominal therapy, hospitalization more than one night or permanent adverse sequale were observed.

Conclusion: Endovascular placement of coil as a fiducial marker is safe and feasible during CyberKnife therapy, and might be an option for the patients in which percutaneous transthoracic fiducial placement might be risky.

Index terms: *Fiducial marker; Lung neoplasm; CyberKnife*

INTRODUCTION

Stereotactic radiation therapy was primarily developed for brain neoplasms (1, 2). This therapy applies a high dose of radiation in a defined target volume. Surrounding healthy

tissue is not irradiated. This technique has been modified to treat other body tumors (3-6). The CyberKnife (Accuray, Sunnyvale, CA, USA) system is a recently developed, frameless stereotactic radiosurgery system that tracks tumors in real-time and allows patient movements during the treatment. This system utilizes internal fiducial markers around the target tumor for this purpose.

Stereotactic radiation therapy is also a treatment option for unresectable lung malignancy due to its ability to deliver high doses of conformal radiation to a small target area (3-5). To precisely target the lung tumors, interventional radiologists are often asked to place markers within the lungs. The standard technique is direct percutaneous transthoracic fiducial placement. The main complications of this method are comprised pneumothorax,

Received January 8, 2014; accepted after revision February 4, 2015.

Corresponding author: Kutlay Karaman, MD, Department of Radiology, Anadolu Medical Center, Anadolu Cad. No:1, Gebze, Kocaeli 41400, Turkey.

- Tel: +90 262 6785020 • Fax: +90 262 6540567
- E-mail: kutlaykaraman@yahoo.com

This is an Open Access article distributed under the terms of the Creative Commons Attribution Non-Commercial License (<http://creativecommons.org/licenses/by-nc/3.0>) which permits unrestricted non-commercial use, distribution, and reproduction in any medium, provided the original work is properly cited.

migration of fiducial markers and hemorrhage. High rates of pneumothorax (22–67%) with percutaneous transthoracic method have been reported in the literature and might be regarded as an unacceptable risk for some patients with severe cardiopulmonary comorbidity (7, 8). Endovascular placement of a coil as a fiducial marker is a feasible technique in interventional radiology practice and may be a valuable method for such cases. However, only one study has yet been published (7).

The aim of this study was to present our experience with endovascular coil placement for CyberKnife therapy and to describe the technical details and complications of this procedure.

MATERIALS AND METHODS

Patient Demographics

Between June 2005 and September 2013, 163 patients (age range, 35–87 years) with primary or secondary lung malignancies were referred for fiducial placement and subsequent CyberKnife radiosurgery. In 14 patients (9 men, 5 women; mean age, 70 years), direct percutaneous

transthoracic fiducial placement was deemed too risky because of a history of pneumonectomy (n = 3), lobectomy (n = 3) or severe cardiopulmonary co-morbidity (n = 8). Indications for radiosurgery were unresectable non-small cell lung carcinoma (n = 11) or metastatic adenocarcinoma (n = 3) in the lungs. The lesions were located in the right upper lobe (n = 4), right lower lobe (n = 2), left upper lobe (n = 5), left lower lobe (n = 3), and mediastinum (n = 1). The largest lesion measured 36 x 41 mm and the smallest lesion was 13 x 10 mm according to World Health Organization criteria (product of largest diameter and greatest perpendicular diameter). The details of these groups are described in Table 1.

Endovascular Coil Placement

Each case was discussed with a radiation oncologist and other responsible primary physicians, and two different interventional radiologists. Medical records were reviewed for previous lung surgery, previous radiation therapy, patient performance status and routine laboratory tests. The benefits and risks of the procedure were fully explained and written informed consent was obtained from each patient.

Table 1. Demographics of 14 Patients with Endovascular Coil Placement

Patient No.	Age	Sex	Tumor Type	Lesion Size (mm)	Previous Lung Surgery	Lesion Localization	Number and Diameter of Coils	Tumor-Coil Distance (Mean)
1	83	M	NSCLC	27 x 20	-	Left upper lobe	3 coils-2 mm	2.2 cm
2	66	M	Metastatic adeno Ca.	19 x 10	Right pneumonectomy	Left upper lobe	2 coils-3 mm/ 1 coil-2 mm	3.2 cm
3	65	F	NSCLC	20 x 22	Right upper lobectomy	Left upper lobe	1 coil-3 mm/ 2 coils-2 mm	1.6 cm
4	79	F	NSCLC	24 x 22	-	Right upper lobe	3 coils-2 mm	2.4 cm
5	72	M	Metastatic adeno Ca.	18 x 20, 22 x 24	-	Left upper lobe, Right lower lobe	3 coils-2 mm/ 2 coils-3 mm	2.2 cm/ 2.6 cm
6	71	M	NSCLC	12 x 20	-	Right upper lobe	4 coils-2 mm	3.1 cm
7	59	M	NSCLC	15 x 18	Right pneumonectomy	Left upper lobe	3 coils-2 mm	2.1 cm
8	64	M	NSCLC	36 x 41	Right upper lobectomy	Left lower lobe	3 coils-2 mm/ 2 coils-3 mm	2.7 cm
9	72	F	Metastatic adeno Ca.	13 x 10	-	Right lower lobe	3 coils-2 mm	3.8 cm
10	60	M	NSCLC	18 x 20	Left upper lobectomy	Left paramediastinal	3 coils-2 mm	3.2 cm
11	67	M	NSCLC	22 x 24	-	Right upper lobe	3 coils-2 mm	3.4 cm
12	74	F	NSCLC	30 x 36	-	Left lower lobe	3 coils-2 mm/ 1 coil-3 mm	2.8 cm
13	77	M	NSCLC	25 x 28	Left pneumonectomy	Right upper lobe	3 coils-2 mm	3.2 cm
14	73	F	NSCLC	22 x 27	-	Left lower lobe	2 coils-2 mm/ 2 coils-3 mm	2.6 cm

adeno Ca. = adenocarcinoma, F = female, M = male, NSCLC = non-small cell lung carcinoma

The procedures were performed by interventional radiologists in the biplane angiography suite as a standard pulmonary angiography, which requires percutaneous venous catheterization, intracardiac catheter manipulation and catheterization of the pulmonary artery. A pigtail-type catheter was advanced through the right heart using deflection maneuvers to reach the right or the left pulmonary artery where it was exchanged with a standard

5-Fr diagnostic catheter. A coaxial 2.7-Fr microcatheter (Progreat, Terumo, Tokyo, Japan) was positioned into a distal small pulmonary artery in the vicinity of the lesion, under biplane fluoroscopy guidance. For other lesions not clearly visible on fluoroscopy, previous chest computed tomography (CT) was used to locate the tumor by fluoroscopy in relation to structures like the heart and main vessels. A selective angiogram was done to check the distal vessel size and to confirm the position of the microcatheter, as the maximal distance between coil and tumor should be no more than 50 mm according to the CyberKnife manual. As a final step, a 0.018" 2-mm or 3-mm pushable (Azur, Terumo, Tokyo, Japan) or detachable (Axium, EV3, Irvine, CA, USA and Microplex, Microvention, Columbia, USA) platinum coil was inserted (Fig. 1). In one patient (#5), endovascular coil placement for bilateral lung lesions was done during the same session (Fig. 2A). The patients were discharged on the same day, after a 2-hour post-procedural observation.

Six to nine days after the procedure, noncontrast-enhanced CT was performed for CyberKnife planning before starting radiosurgery. The position and shape of the coils were checked by two interventional radiologists who performed the procedure. Coil-tumor distance, location and coil shape were evaluated on multiplanar CT images (Fig. 2B). Three coils non-collinear in orthogonal planes, with a minimum intercoil distance > 2 cm, maximum coil to tumor distance < 50 mm and a good coiling shape were regarded as successful for this procedure. The numbers, size and

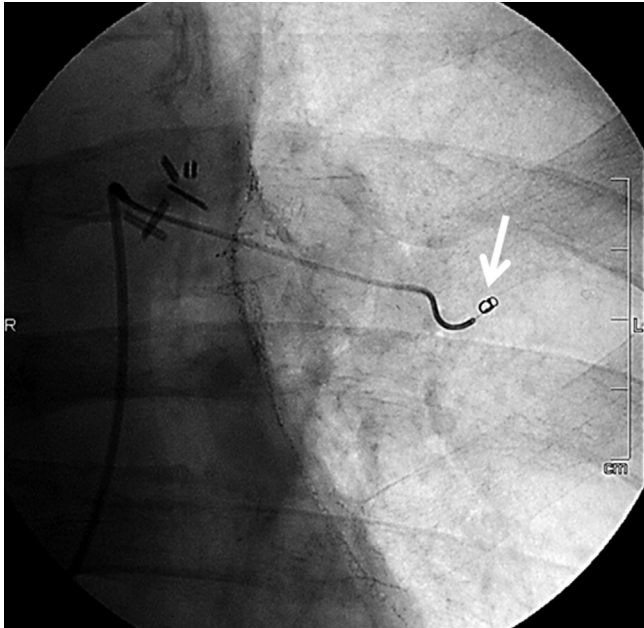


Fig. 1. 60-year-old male with non-small cell lung carcinoma (patient No. 10). Digital fluoroscopic image shows microcatheter placed in smaller pulmonary artery. Coil being pushed out of catheter is indicated by arrow.

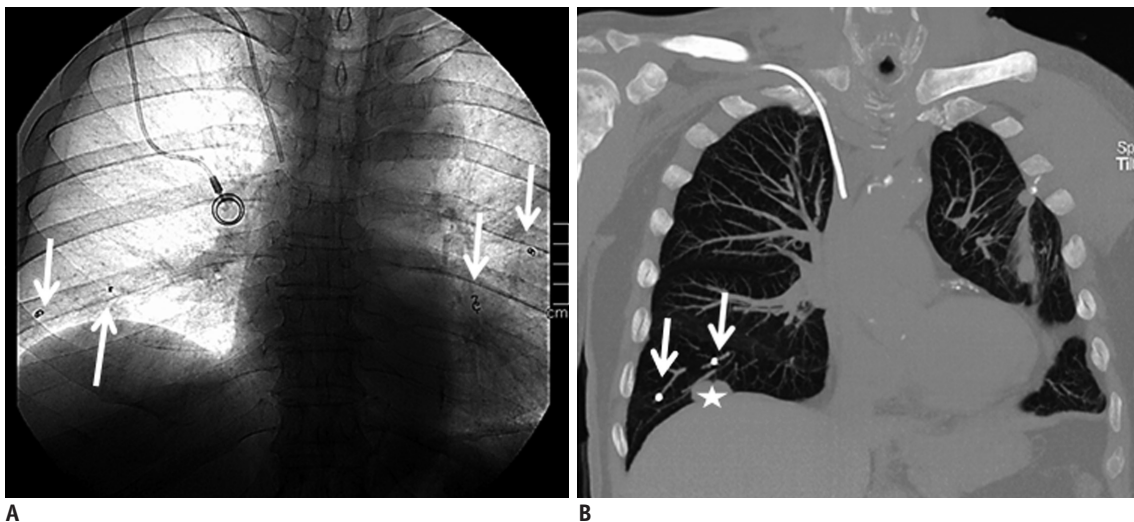


Fig. 2. 72-year-old male with metastatic adenocarcinoma (patient No. 5). **A.** Digital fluoroscopic image shows endovascular coils (arrows) which were placed into both lungs in single procedure. Tumors in both lungs were treated with CyberKnife. **B.** Coronal maximum intensity projection CT image shows two endovascular coils (arrows) in right lung, which were adequately placed in vicinity of tumor (star).

Intravascular Placement of Metallic Coils

tumor-to-coil distance are presented in Table 1.

Late complications of hemorrhage, infarction and infection were also evaluated on CT, along with the clinical status of patients during and after endovascular coil placement to monitor early complications like arrhythmia and vascular complications.

RESULTS

Forty nine metallic micro coils with a median number of 3 coils per tumor were placed with a mean distance of 2.7 cm tumor-to-coil. The planning CT determined that 43 of 49 coils (87.7%) were adequately placed, which were subsequently used as fiducial markers. Two coils could not be used because of larger tumor-coil distance (> 50 mm). Four coils were in acceptable positions, while their non-coiling shapes precluded tumor tracking for the CyberKnife system (Fig. 3). All 14 patients underwent CyberKnife therapy using two or three successfully placed coils, without requiring a repeat endovascular procedure. No long-lasting arrhythmia or vascular complications were noted during catheterization. None of the patients experienced clinical signs of pulmonary complications such as dyspnea, fever and pleuritic pain after endovascular coil placement in early and late phases, as confirmed by CT. No major complications needing further medication other than nominal therapy, overnight hospitalization or permanent adverse sequelae were observed.

DISCUSSION

Surgery remains the standard of care for early-stage lung cancer and certain pulmonary metastases (9). In the case of inoperable patients, radiotherapy might be an option. To account for tumor motion in stereotactic radiation therapy planning and treatment delivery, several methods may be used. These include respiratory gating, body frame and real-time tumor tracking. The CyberKnife system utilizes real-time tumor tracking and may require the use of radio-opaque markers implanted near or inside the tumor.

Different methods of marker placement that have been described include percutaneous transthoracic fiducial placement, endovascular coil placement, fiducial placement with bronchoscopy technique and percutaneous extrathoracic fiducial placement (7, 10-12).

With the standard percutaneous transthoracic puncture, gold seeds or platinum fiducials are placed into the

lung. Different size of needles (18 to 25 gauge) from different vendors may be used under guidance of different imaging modalities (ultrasonography, fluoroscopy, CT). Embolization coils may also be implanted by a transthoracic puncture technique. Interestingly, it has been reported that percutaneously implanted platinum endovascular embolization coils are much better seen than standard gold markers, and are successfully tracked by the CyberKnife system (13). However, the percutaneous transthoracic method resulted in a high rate of pneumothorax (22–67%) with tube drainage for the pneumothorax sometimes required. Another common complication is parenchymal hemorrhage, which is usually self-limiting (7, 8). CyberKnife treatment is often performed in elderly patients or patients with co-morbidities like chronic lung disease and previous lung surgery in whom the risk of pneumothorax and parenchymal hemorrhage should be taken seriously. In such patients, endovascular placement of coil as a fiducial marker is a valuable option to avoid these events. We chose the endovascular technique in 14 patients who had symptoms and test results indicating decreased lung reserve due to a previous lung surgery or a chronic lung disease. As in our series, Erasmus Medical Center investigators also found no pneumothorax or parenchymal hemorrhage associated with endovascular delivery of 87 embolization coils in 23

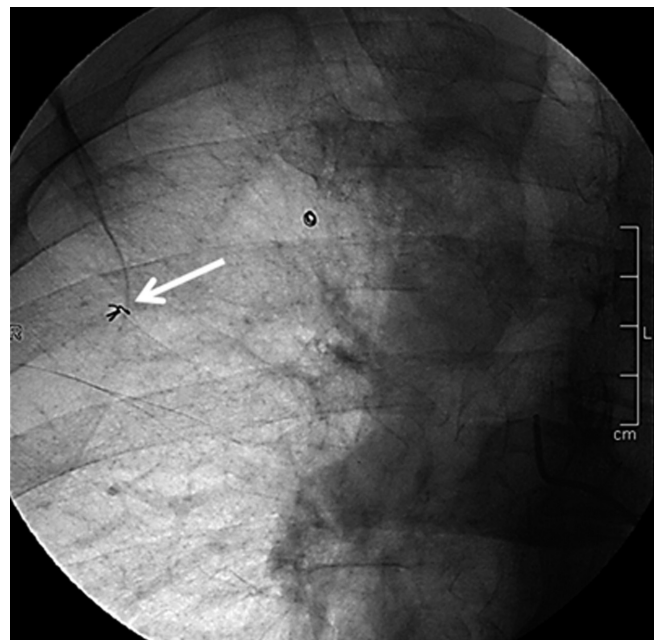


Fig. 3. 71-year-old male with metastatic non-small cell lung carcinoma (patient No. 6). Digital fluoroscopic image shows endovascular coil, which has been deployed in non-coiling shape (arrow). Coils in such shape cannot be used for tumor tracking in CyberKnife radiosurgery.

patients (7).

Endovascular fiducial marker placement allowed successful CyberKnife therapy in all 14 patients (100%) in our study, similar to reports about percutaneous fiducial placement in lung tumors. However, in the percutaneous technique, migration of fiducials in the parenchyma and into the thoracic space is a common problem. This may be evident during the procedure or even in the late phase, necessitating reimplantation (8). During the endovascular procedures, we did not encounter migration of coils, but uncoiling occurred in four patients. Adequacy of coil placement could be determined during the catheterization procedure, which was subsequently confirmed by planning CT.

There are other fiducial implantation techniques, but they might be technically inappropriate for undesired locations and small lung lesions. For example, a small peripheral tumor may be challenging during bronchoscopy, even when using the electromagnetic navigation guidance to reach the tumor (12). Percutaneous placement of fiducial markers into the thoracic wall is another option. However, as in the case of a small central tumor, larger distance and physiological movements precluded tumor tracking for the CyberKnife system. In our experience, the endovascular method is more precise and accurate compared to the other methods of fiducial marker placement, at least in a select group of patients. We believe that the advantage of this technique might be even greater when cone-beam CT is used.

The potential complications of the endovascular procedure in the pulmonary vasculature include vascular injury, thrombosis and pulmonary infarction. Transient pleural pain, hemoptysis and clinically silent small pulmonary infarction have been reported after embolization of pulmonary arteriovenous malformations with different embolic materials as particles, glue and coils (14). The lungs are infrequently infarcted due to dual supply with many anastomoses. The pulmonary and bronchial circulations have two types of connections. The first is an end-to-end anastomosis of 72–325 μm arteries on middle sized bronchi called Sperrarterien. The second type of bronchopulmonary anastomosis is end-to-end or end-to-side, at the precapillary level with a vessel diameter of 24–48 μm (15). The bronchial circulation responds to decreased pulmonary arterial ischemia with dilatation, hypertrophy, and focal proliferation across these meshlike anastomotic channels. In our series, the coils used, unlike liquid embolic material or small particles, probably occluded the vessels mechanically at the proximal sites without inducing

widespread thrombosis, which kept these anastomoses open. We did not encounter a patient with a clinical or CT sign of pulmonary infarction. These findings are consistent with other data in the literature (7).

The most common technical problem in our cases was uncoiling and elongation of the coils. We used the smallest coils available on the market. Still we sometimes barely accomplished good coiling shape, given that the smaller diameter in distal vessels close to the lesion could preclude coiling. This problem was more evident with pushable coils, which have no control mechanism to maintain a good coiling shape. Moreover, unlike detachable coils, pushable coils could not be drawn back after insertion as all 4 uncoiled coils in our study. In addition, coils with different chemical properties may have different shape memories and even straining of the coils during manipulations might cause uncoiling.

We did not detect any migration of intravascular coils during follow-up CT scans, probably because they were fixed after placement into a small blood vessel. This seems to be better with hydrocoils which expand after contact with blood. In prior studies, platinum microcoils had enough radio-opacity for the CyberKnife system (7, 13).

In conclusion, endovascular coil placement in distal pulmonary arteries is safe and feasible for CyberKnife radiosurgery. This method might be an option for patients with poor pulmonary condition, in which percutaneous fiducial placement is not safe.

REFERENCES

1. Adler JR Jr, Chang SD, Murphy MJ, Doty J, Geis P, Hancock SL. The Cyberknife: a frameless robotic system for radiosurgery. *Stereotact Funct Neurosurg* 1997;69(1-4 Pt 2):124-128
2. Chang SD, Murphy M, Geis P, Martin DP, Hancock SL, Doty JR, et al. Clinical experience with image-guided robotic radiosurgery (the Cyberknife) in the treatment of brain and spinal cord tumors. *Neurol Med Chir (Tokyo)* 1998;38:780-783
3. Uematsu M, Shioda A, Tahara K, Fukui T, Yamamoto F, Tsumatori G, et al. Focal, high dose, and fractionated modified stereotactic radiation therapy for lung carcinoma patients: a preliminary experience. *Cancer* 1998;82:1062-1070
4. Whyte RI, Crownover R, Murphy MJ, Martin DP, Rice TW, DeCamp MM Jr, et al. Stereotactic radiosurgery for lung tumors: preliminary report of a phase I trial. *Ann Thorac Surg* 2003;75:1097-1101
5. Wulf J, Haedinger U, Oppitz U, Thiele W, Mueller G, Flentje M. Stereotactic radiotherapy for primary lung cancer and

- pulmonary metastases: a noninvasive treatment approach in medically inoperable patients. *Int J Radiat Oncol Biol Phys* 2004;60:186-196
6. Timmerman RD, Kavanagh BD, Cho LC, Papiez L, Xing L. Stereotactic body radiation therapy in multiple organ sites. *J Clin Oncol* 2007;25:947-952
 7. Prévost JB, Nuyttens JJ, Hoogeman MS, Pöll JJ, van Dijk LC, Pattynama PM. Endovascular coils as lung tumour markers in real-time tumour tracking stereotactic radiotherapy: preliminary results. *Eur Radiol* 2008;18:1569-1576
 8. Bhagat N, Fidelman N, Durack JC, Collins J, Gordon RL, LaBerge JM, et al. Complications associated with the percutaneous insertion of fiducial markers in the thorax. *Cardiovasc Intervent Radiol* 2010;33:1186-1191
 9. Ginsberg RJ, Rubinstein LV. Randomized trial of lobectomy versus limited resection for T1 N0 non-small cell lung cancer. Lung Cancer Study Group. *Ann Thorac Surg* 1995;60:615-622; discussion 622-623
 10. Imura M, Yamazaki K, Shirato H, Onimaru R, Fujino M, Shimizu S, et al. Insertion and fixation of fiducial markers for setup and tracking of lung tumors in radiotherapy. *Int J Radiat Oncol Biol Phys* 2005;63:1442-1447
 11. Shirato H, Harada T, Harabayashi T, Hida K, Endo H, Kitamura K, et al. Feasibility of insertion/implantation of 2.0-mm-diameter gold internal fiducial markers for precise setup and real-time tumor tracking in radiotherapy. *Int J Radiat Oncol Biol Phys* 2003;56:240-247
 12. Schroeder C, Hejal R, Linden PA. Coil spring fiducial markers placed safely using navigation bronchoscopy in inoperable patients allows accurate delivery of CyberKnife stereotactic radiosurgery. *J Thorac Cardiovasc Surg* 2010;140:1137-1142
 13. Hong JC, Yu Y, Rao AK, Dieterich S, Maxim PG, Le QT, et al. High retention and safety of percutaneously implanted endovascular embolization coils as fiducial markers for image-guided stereotactic ablative radiotherapy of pulmonary tumors. *Int J Radiat Oncol Biol Phys* 2011;81:85-90
 14. Mager JJ, Overtom TT, Blauw H, Lammers JW, Westermann CJ. Embolotherapy of pulmonary arteriovenous malformations: long-term results in 112 patients. *J Vasc Interv Radiol* 2004;15:451-456
 15. Pump KK. Distribution of bronchial arteries in the human lung. *Chest* 1972;62:447-451