



# Lipoprotein Glomerulopathy in a Hispanic Female: A Case Report and Literature Review

Canadian Journal of Kidney Health and Disease  
Volume 6: 1–7  
© The Author(s) 2019  
Article reuse guidelines:  
sagepub.com/journals-permissions  
DOI: 10.1177/2054358119859576  
journals.sagepub.com/home/cjk

Nasma K. Majeed<sup>1</sup> , Jeanette McLaughlin<sup>2</sup>, and Miguel Gonzalez<sup>3</sup>

## Abstract

**Rationale:** Lipoprotein glomerulopathy (LPG) is a rare renal disorder that features glomerular capillary lipoprotein thrombi, proteinuria, and progressive renal failure. Although most reported cases describe involvement in Asian patients, occurrence in Caucasian and other ethnicities has also been reported.

**Presenting concern:** A 28-year-old Hispanic female with a past medical history of hypertension, high cholesterol, gastritis, and a strong family history of renal disease presented with abdominal pain. On admission, her blood pressure was elevated. A computed tomography scan was unremarkable. Her laboratory studies showed proteinuria, high creatinine level, and an abnormal lipid profile.

**Diagnosis:** The kidney biopsy showed glomerular capillary lipoprotein thrombi that stained positively for Oil-Red-O, confirming the lipid nature of the material consistent with LPG.

**Intervention:** After stabilizing her blood pressure, the patient was started on fenofibrate to treat her high cholesterol and improve her renal function.

**Outcome:** Her lipid profile and renal function were initially improved. However, after one year of treatment, her renal function started to decline and the patient was referred to a transplant center for further management.

**Novel finding:** To the best of our knowledge, this the first reported incidence of LPG in a Hispanic female.

## Abrégé

**Justification:** La glomérulopathie lipoprotéique (GLP) est une pathologie rénale rare caractérisée par des thrombus au niveau des capillaires glomérulaires, une protéinurie et une insuffisance rénale progressive. Bien que la plupart des cas rapportés concernent des patients d'origine asiatique, quelques cas ont été observés chez des patients caucasiens ou d'origines ethniques autres.

**Présentation du cas:** Une patiente de 28 ans d'origine hispanique a consulté à l'urgence pour un tableau de douleurs abdominales. Elle présentait des antécédents d'hypertension, d'hypercholestérolémie et de gastrite, en plus d'importants antécédents familiaux de néphropathies. À son admission, sa pression artérielle était élevée. La tomодensitométrie était normale. Les résultats de laboratoire indiquaient une protéinurie, un taux élevé de créatinine et un profil lipidique anormal.

**Diagnostic:** La biopsie rénale a montré des thrombus lipoprotéiques au niveau des capillaires glomérulaires. Leur nature lipidique, cohérente avec une GLP, a été confirmée par la coloration Oil-Red-O.

**Intervention:** Après stabilisation de la pression artérielle, un traitement au fénofibrate a été initié pour abaisser le taux de cholestérol et améliorer la fonction rénale.

**Résultats:** Le profil lipidique et la fonction rénale de la patiente se sont améliorés initialement. Cependant, après un an de traitement, la fonction rénale a commencé à décliner et la patiente a été aiguillée vers un centre de transplantation pour prise en charge.

**Conclusion:** À notre connaissance, ce cas constitue la première incidence d'une GLP chez une femme d'origine hispanique.

## Keywords

lipoprotein glomerulopathy, apoE gene, abnormal lipid profile

Received February 1, 2019. Accepted for publication April 16, 2019.



## What was known before

The majority of reported cases of lipoprotein glomerulopathy (LPG) are from Asian countries, Japan and China, with only approximately 13 cases in the non-Asian population.

## What this adds

We are reporting a case of LPG in the non-Asian population. Although LPG is more common in patients of Asian ethnicity and males, we report the first known case of LPG in a Hispanic female that has not been described before.

## Introduction

Lipoprotein glomerulopathy (LPG) is a unique renal disease. Most described patients have been Japanese or Chinese, but the disease has also been described in patients of other ethnicities.<sup>1</sup> Male patients are more commonly affected than female patients, and the disease can be seen in childhood. The clinical onset of the disease is usually marked by proteinuria with an abnormal lipid profile. Approximately 50% of patients slowly progress to renal failure,<sup>2</sup> and the lesion may recur in the renal allograft. Microscopically, the glomeruli in LPG are enlarged, with lipoprotein thrombi in distended capillaries. The thrombi stain positively for Oil-Red-O and Sudan stains. Immunofluorescence examination findings are usually non-specific, and the thrombi show a concentric laminated pattern by electron microscopy. Novel missense mutations and deletion in apoE gene are thought to be pathogenetic in LPG. We report a case of a 28-year-old Hispanic female with LPG. To the best of our knowledge, this is the first case report of LPG in a Hispanic female in the English literature.

## Case Report

The patient is a 28-year-old Hispanic female with a past medical history of hypertension, high serum cholesterol, and gastritis who presented to the emergency room for the evaluation of abdominal pain of 2 days duration. Six months prior, she had similar pain. An upper gastrointestinal (GI) endoscopy at that time showed peptic ulcer disease and no other mucosal lesions. The patient had a strong family history of renal disease and 2 of her siblings required a renal transplant, but she did not know what kidney pathology they had. Her medications included Lisinopril oral 10 mg tablet daily and Pantoprazole oral 40 mg daily. On presentation at the

emergency room (ER), her height and weight were 157 cm and 61 kg, respectively, and her blood pressure was 206/121 mm Hg. On physical examination, the patient had epigastric tenderness. The rest of her physical examination was unremarkable. Radiology was ordered to exclude any anatomical abnormality. A computed tomography scan showed neither atrophy nor enlargement of the kidneys. She then followed up as an outpatient with a nephrologist shortly after her ER visit. Her laboratory work up during that visit revealed the following: nephrotic range proteinuria (9.2 g protein on 24-hour urine collection; reference range, 0-2.5 g/d), hypoalbuminemia (300 µmol/L; reference range, 421-662 µmol/L), hypoproteinemia (50 g/L; reference range, 60-80 g/L), elevated serum creatinine (148.5 µmol/L; reference range, 44-80 µmol/L), high chloride (110 mmol/L; reference range, 98-106 mmol/L), and low hemoglobin (100 g/L; reference range, 120-160 g/L). The lipid profile showed an increased total cholesterol level (8.3 mmol/L; reference range, <5.2 mmol/L), elevated triglycerides (3.7 mmol/L; reference range, <1.70 mmol/L), elevated low-density lipoprotein fraction (5.9 mmol/L; reference range, <2.6 mmol/L), and decreased high-density lipoprotein fraction (1.1 mmol/L; reference range, ≥1.55 mmol/L). After treating her blood pressure, the patient underwent a US-guided renal biopsy.

## Pathologic Findings

The biopsy consisted of renal cortical parenchyma containing 9 glomeruli. Three glomeruli were globally sclerosed. The remaining glomeruli showed mesangial expansion and segmental hypercellularity, focal thickening and duplication of the capillary wall, and capillary thrombi of eosinophilic, weakly Periodic acid -Schiff (PAS)-positive and Jones silver negative material that appeared bluish gray on trichrome stains and stained positively with the Oil-Red-O histochemical stain for lipids. Focal glomerular foamy histiocytes were also noted. Tuft necrosis and crescents were not seen. There was moderate tubular atrophy and interstitial fibrosis estimated at 35% of the parenchyma, with accompanying non-specific interstitial inflammation. The tubules were focally dilated and exhibited reactive and hyperplastic epithelial changes. Rare intraluminal cells with foamy cytoplasm were noted. The extraglomerular blood vessels revealed moderate arteriosclerosis. Immunofluorescence examination revealed either non-specific or negative staining of the specimen for all of the antibodies, including albumin which showed 1-2+ normal pseudolinear staining of the glomerular and tubular

<sup>1</sup>Department of Pathology, The University of Illinois at Chicago, USA

<sup>2</sup>Department of Nephrology, Advocate Christ Medical Center, Chicago, IL, USA

<sup>3</sup>Department of Pathology, Advocate Lutheran General Hospital, Park Ridge, IL, USA

### Corresponding Author:

Nasma K. Majeed, Department of Pathology, The University of Illinois at Chicago, 840 S Wood St, Chicago, IL 60612, USA.

Email: [nasma.k.majeed@gmail.com](mailto:nasma.k.majeed@gmail.com)

basement membranes with 4+ staining of tubular reabsorption droplets. An Oil-Red-O histochemical stain was also performed and revealed staining of the glomerular capillary thrombi, confirming the lipid nature of the material. Ultrastructural examination of thin sections demonstrated expanded mesangial regions with paramesangial densities, some compatible with insudates and others with a texture suggesting lipid. The capillaries contained intraluminal thrombi containing small lipid droplets admixed with granular material. The capillary wall showed foci of mesangial cell interposition and basement membrane duplication. The podocytes displayed diffuse attenuation of the foot processes. Foam cells were present. Immune deposits were not identified (Figure 1). Genetic testing was not performed in our patient; however, one of the patient's siblings with renal failure was tested positive for apoE gene mutation in another institution.

## Follow-Up

After the diagnosis of LPG, the patient was started on fenofibrate (Tricor). She tolerated her medication very well and her lipid profile improved: total cholesterol 4.3 mmol/L (reference range, <5.2 mmol/L), triglycerides 1.6 mmol/L (reference range, <1.70 mmol/L), and low-density lipoprotein fraction 1.7 mmol/L (reference range, <2.6 mmol/L). She initially complained of myalgia, but creatine phosphokinase (CPK) level was normal at 75 U/L (reference range, 22-198 U/L) and symptoms improved. However, after 1 year of treatment, her renal function started to decline. Her creatinine level increased to 291  $\mu$ mol/L (reference range, 44-80  $\mu$ mol/L) and the patient was referred to a transplant center for further management. She did not follow-up for transplant evaluation and her creatinine continued to increase, despite angiotensin receptor blocker (ARB) use and blood pressure control. Recently, she became pregnant, with a creatinine of 353  $\mu$ mol/L (reference range, 44-80  $\mu$ mol/L). She was started on dialysis and she is now dialyzing 6 days a week, in her second trimester.

## Discussion

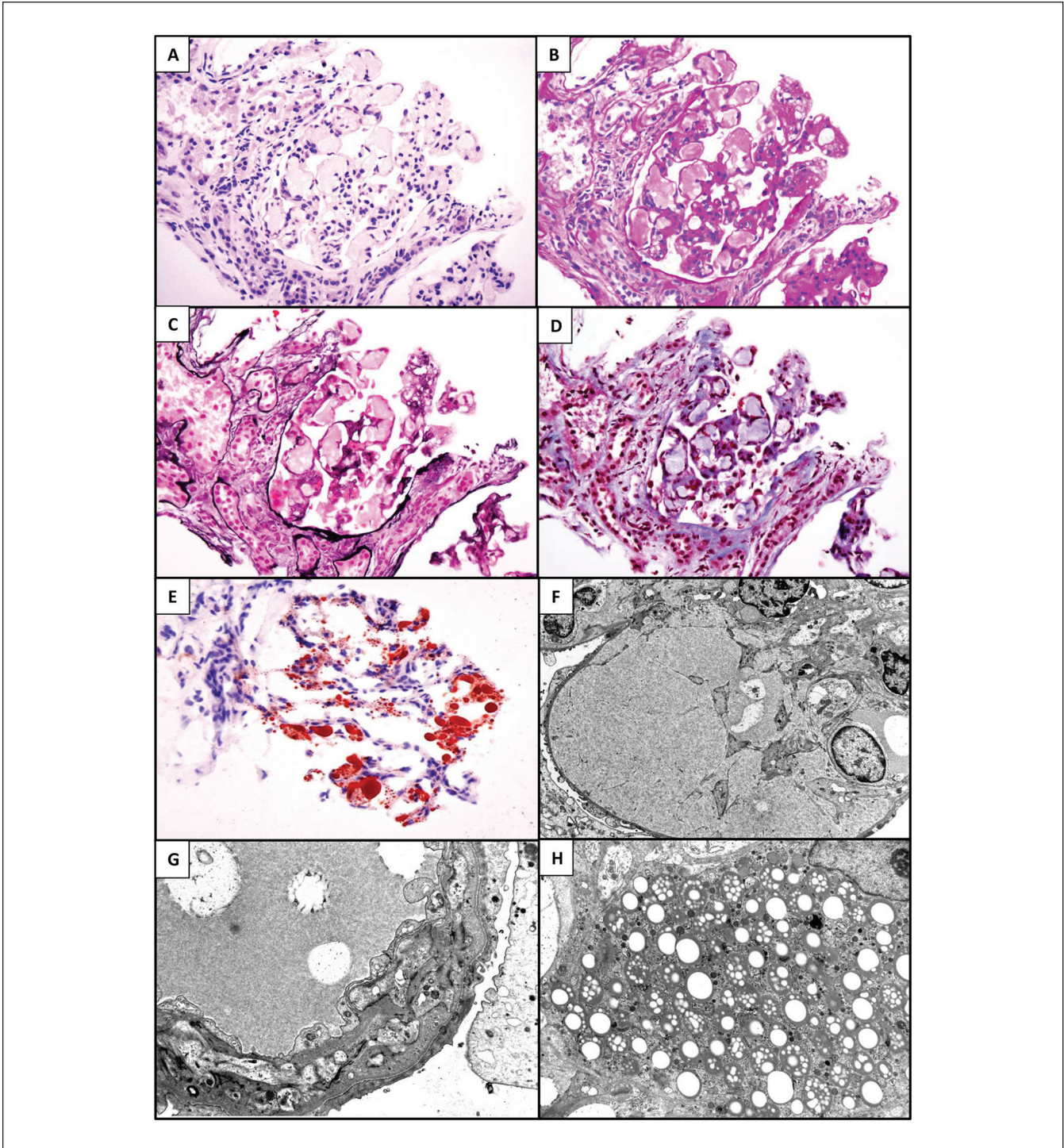
Lipoprotein glomerulopathy is a rare disease that was initially described in the review of renal lipidosis by Faraggiana and Churg.<sup>3</sup> The first reported case of LPG by Saito et al was in a Japanese patient in 1989.<sup>4</sup> Since then, more than 150 cases have been reported in the literature. Most of the cases come from Asian countries, Japan and China, with approximately 13 cases in the non-Asian population (Table 1). Most of the patients are from Europe or of European ancestry,<sup>1,5-11</sup> 1 patient is American of Asian ancestry,<sup>12</sup> and 2 patients from South America are Brazilian<sup>13</sup> and Mexican.<sup>14</sup> There were more male patients than female patients, the age of the patients ranged from 16 to 61 years old, and 7 of the patients have distinct genetic mutations.

The familial involvement and recurrence of the disease in the transplanted kidney show a genetic component related to the pathogenesis of LPG, with most of the patients with LPG found to have mutations in the apoE gene. The apoE gene is located at the long (q) arm of chromosome 19 at position 13.32. It plays an essential role in the synthesis of a protein called apolipoprotein E. This protein combines with lipid to form molecules called lipoproteins. Lipoproteins are responsible for packaging cholesterol and maintaining normal levels in the serum. At least 3 different alleles of the apoE gene have been identified. The 3 major alleles are e2, e3, and e4. The e3 allele is most common and found in more than half of the general population. More than 15 different mutations in apoE gene have been reported to date. The most common mutations are Kyoto and Sendai; cases of more than 1 mutation have been reported as well.<sup>15</sup> Although there is increased evidence of genetic factors involved in the pathogenesis of LPG, 1 case study in Chinese patients with LPG showed an absence of apoE gene mutations in those patients.<sup>16</sup> Moreover, the presence of asymptomatic carriers of apoE variants suggests that other factors may also play a role in the pathogenesis of the disease and that the exact mechanism remains to be defined.

In our case, the patient has 2 siblings with advanced renal disease; one of them has biopsy-documented LPG and a demonstrated mutation confirming LPG as a disease that is transmitted in an autosomal dominant fashion with incomplete penetrance.<sup>14</sup>

The clinical presentation of LPG ranges from asymptomatic proteinuria on routine screening examination to end-stage renal disease. Most of the patients have proteinuria (average 4.8 g/d) and an abnormal lipid and lipoprotein profile (increased very low-density lipoprotein [VLDL], intermediate density lipoprotein [IDL], and apoE concentrations).<sup>17</sup> Other systemic symptoms like edema, hypertension, atherosclerosis, decreased albumin levels, and xanthoma have been reported as well. In our case, the patient had mild edema but no evidence of cutaneous or ocular xanthoma. There are no specific recommendations for when to perform a kidney biopsy in a patient with only hypertriglyceridemia without proteinuria. However, severe proteinuria and other features of nephrotic syndrome are definitely indications to perform kidney biopsy as those patients have an increased risk of thrombotic disease and progressive renal injury.

The diagnosis of LPG depends on the clinical features and renal biopsy. On light microscopy, the patient will have distended glomerular capillaries with thrombi of eosinophilic, weakly PAS-positive and Jones silver negative material that appears bluish gray on trichrome stains and stains positively with the Oil-Red-O histochemical stain for lipids. Mesangiolytic as well as capillary wall duplication may occur. There may be segmental or global sclerosis of the glomeruli. Tubulointerstitial changes are proportionate to and follow glomerulosclerosis.<sup>12</sup> There are no specific vascular lesions. Immunofluorescence examination for immunoglobulins and complements is usually negative or non-specific



**Figure 1.** (A) The glomerulus with distended capillaries containing lipoprotein thrombi (Hematoxylin & Eosin stain; original magnification:  $\times 300$ ). (B) The glomerulus with distended capillaries containing lipoprotein thrombi (Periodic Acid-Schiff stain; original magnification:  $\times 300$ ). (C) The glomerulus with distended capillaries containing lipoprotein thrombi (Silver Jones stain; original magnification:  $\times 300$ ). (D) The glomerulus with distended capillaries containing lipoprotein thrombi (Masson's trichrome stain; original magnification:  $\times 300$ ). (E) The glomerulus with distended capillaries containing lipoprotein thrombi (Oil-Red-O stain; original magnification:  $\times 300$ ). (F) Glomerular capillary lumen filled with concentric laminated pattern thrombus (Electron microscopy; original magnification:  $\times 2000$ ). (G) The capillary wall is thickened, with mesangial interposition and duplication of the glomerular basement membrane (Electron microscopy; original magnification:  $\times 5000$ ). (H) Prominent foam cell (Electron microscopy; original magnification:  $\times 3500$ ).

**Table 1.** Cases of LPG in Non-Asian Patients Reported in the Literature.

| Reported cases | Author (year)                   | Age       | Sex    | Ethnicity                        | Presentation                            | Genetic testing                     | Proteinuria | Creatinine             | Triglyceride    | Apolipoprotein |
|----------------|---------------------------------|-----------|--------|----------------------------------|---|-------------------------------------|-------------|------------------------|-----------------|----------------|
| 1 case         | Meyrier et al <sup>1</sup>      | 42        | Male   | White European                   | Proteinuria                             | Not performed                       | NR          | NR                     | NR              | NR             |
| 1 case         | Mourad et al <sup>5</sup>       | 16        | Female | French                           | Proteinuria                             | Not performed                       | 10 g/d      | 140 µmol/L             | 3.6 mmol/L      | 160 mg/L       |
| 1 case         | Sam et al <sup>14</sup>         | 31        | Male   | Mexican                          | Proteinuria and acute kidney injury     | ApoE Chicago                        | 9.7 g/d     | 168 µmol/L             | 2.7 mmol/L      | NR             |
| 2 cases        | Rovin et al <sup>6</sup>        | NR        | Male   | Americans from European ancestry | Proteinuria and edema                   | ApoE Kyoto                          | NR          | NR                     | NR              | NR             |
| 1 case         | Sethi <sup>12</sup>             | 61        | Female | American from Asian ancestry     | Hypertension and hypercholesterolemia   | Not performed                       | 3.2 g/d     | 114.9 µmol/L           | 0.9 mmol/L      | NR             |
| 1 case         | Bomback et al <sup>7</sup>      | 36        | Male   | European American                | Proteinuria                             | ApoE Las Vegas                      | 12 g/d      | 114.9 µmol/L           | 2.4 mmol/L      | NR             |
| 1 case         | Boumendjel et al <sup>8</sup>   | 31        | Male   | White                            | Proteinuria and hypertension            | ApoE alleles of the wild-type E3/E3 | 9.8 g/d     | 203.3 µmol/L           | 2.5 mmol/L      | NR             |
| 2 cases        | Pasquariello et al <sup>9</sup> | 45 and 41 | Male   | Italian                          | Proteinuria and increased creatinine    | ApoE3 with apoE3/3 phenotype        | 3.7 g/d     | 132.6 and 110.5 µmol/L | 2.3, 2.2 mmol/L | 80 mg/L        |
| 1 case         | Magistroni et al <sup>10</sup>  | 51        | Male   | Italian                          | Proteinuria and type III hyperlipidemia | ApoEMODENA                          | 5 g/d       | 82.2 µmol/L            | 3.8 mmol/L      | NR             |
| 1 case         | Pégas et al <sup>13</sup>       | 11        | Male   | Brazilian                        | Steroid-resistant nephrotic syndrome    | Not performed                       | 10.7 g/d    | 61.8 µmol/L            | 7.1 mmol/L      | NR             |
| 1 case         | Sipovskii et al <sup>11</sup>   | 47        | NR     | Russian                          | Unknown                                 | Unknown                             | 12.4 g/d    | 134 µmol/L             | NR              | NR             |

Note. LPG = lipoprotein glomerulopathy; NR = not reported.

but positive for apoB and apoE. Immunofluorescence is helpful in excluding other types of glomerulopathy like immunoglobulin A (IgA) or membranous nephropathy which may mimic LPG on clinical grounds and light microscopy.<sup>18</sup> Electron microscope examination reveals foam cells with lipid droplets or concentric lamellar bodies of various sizes mainly localized in the glomerular capillaries. Glomerular basement membrane duplication as well as mesangial interposition and variable mesangial hypercellularity may also be observed. The extent of attenuation of the podocyte foot processes correlates with the degree of proteinuria. The capillary luminal deposits may be confused with fibrin thrombi or amyloid deposits by light microscopy; however, fibrin thrombi appear fuchsinophilic on the trichrome stain and stain positively with antibody to fibrinogen on immunofluorescence while amyloid deposits are Congo-red positive and show a fibrillary appearance on electron microscopy.

Currently, there is no known effective and/or specific treatment for LPG. Some case reports suggested that using lipid-lowering therapy including fenofibrate may decrease the serum lipid levels, proteinuria, and serum creatinine concentrations, and cause complete resolution of lipoprotein thrombi in serial renal biopsies; a recommended target goal for serum triglyceride level is less than 100 mg/dL.<sup>19</sup> In our case, the patient diagnosed with hypertension and high cholesterol around 1 year before her presentation, which she controlled with diet and Lisinopril. After the diagnosis of LPG, she started on fenofibrate, which improved the serum lipid profile but did not help to improve the patient's renal function.

In general, for patients with LPG and high blood pressure, it is recommended to use agents like angiotensin-converting enzyme inhibitors or angiotensin II receptor blockers to control the blood pressure and slow progression of the renal disease. Other treatments like steroids and immunosuppressant drugs have not been shown to be effective in those patients.<sup>13</sup> So far, 5 cases of LPG who had undergone kidney transplantation have been reported in the literature: 4 of them had a recurrence of the disease in the allograft and only 1 case had no clinical evidence of disease on follow-up.<sup>20</sup>

## Conclusion

We present a case of LPG in a Hispanic female. Although this disease is more predominant in the Asian population and males, it should always be considered in any patient who presents with an abnormal lipid profile and proteinuria, and a kidney biopsy should be recommended to confirm the diagnosis.

## Ethics Approval and Consent to Participate

Formal research ethics approval was not sought for this case report.

## Consent for Publication

Informed consent was obtained for publication.

## Availability of Data and Materials

All data generated are included in this article.


## Declaration of Conflicting Interests

The author(s) declared no potential conflicts of interest with respect to the research, authorship, and/or publication of this article.

## Funding

The author(s) received no financial support for the research, authorship, and/or publication of this article.

## ORCID iD

Nasma K. Majeed  <https://orcid.org/0000-0002-8780-2537>

## References

- Meyrier A, Dairou F, Callard P, Mougenot B. Lipoprotein glomerulopathy: first case in a white European. *Nephrol Dial Transplant*. 1995;10(4):546-549.
- Saito T, Ishigaki Y, Oikawa S, Yamamoto TT. Etiological significance of apolipoprotein E mutations in lipoprotein glomerulopathy. *Trends Cardiovasc Med*. 2002;12(2):67-70.
- Faraggiana T, Churg J. Renal lipidoses: a review. *Hum Pathol*. 1987;18(7):661-679.
- Saito T, Sato H, Kudo KI, et al. Lipoprotein glomerulopathy: glomerular lipoprotein thrombi in a patient with hyperlipoproteinemia. *Am J Kidney Dis*. 1989;13(2):148-153.
- Mourad G, Djamali A, Turc-Baron C, Cristol JP. Lipoprotein glomerulopathy: a new cause of nephrotic syndrome after renal transplantation. *Nephrol Dial Transplant*. 1998;13(5):1292-1294.
- Rovin BH, Roncone D, McKinley A, Nadasdy T, Korbet SM, Schwartz MM. APOE Kyoto mutation in European Americans with lipoprotein glomerulopathy. *N Engl J Med*. 2007;357(24):2522-2524.
- Bomback AS, Song H, D'Agati VD, et al. A new apolipoprotein E mutation, apoE Las Vegas, in a European-American with lipoprotein glomerulopathy. *Nephrol Dial Transplant*. 2010;25(10):3442-3446.
- Boumendjel R, Papari M, Gonzalez M. A rare case of lipoprotein glomerulopathy in a white man: an emerging entity in Asia, rare in the white population. *Arch Pathol Lab Med*. 2010;134(2):279-282.
- Pasquariello A, Pasquariello G, Innocenti M, et al. Lipoprotein glomerulopathy: first report of 2 not consanguineous Italian men from the same town. *J Nephrol*. 2011;24(3):381-385.
- Magistrini R, Bertolotti M, Furci L, et al. Lipoprotein glomerulopathy associated with a mutation in apolipoprotein E. *Clin Med Insights Case Rep*. 2013;6:189-196.
- Sipovskii VG, Klemina IK, Zverkov RV, Dobronravov VA, Smirnov AV. A case of diagnosing lipoprotein glomerulopathy in Russia. *Arkh Patol*. 2016;78(6):52-57.
- Sethi S. The Case|Renal failure with intracapillary thrombi. *Kidney Int*. 2008;73(9):1097-1098.
- Pêgas KL, Rohde R, Garcia CD, et al. Lipoprotein glomerulopathy: a case report of a rare disease in a Brazilian child. *J Bras Nefrol*. 2014;36(1):93-95.

14. Sam R, Wu H, Yue L, et al. Lipoprotein glomerulopathy: a new apolipoprotein E mutation with enhanced glomerular binding. *Am J Kidney Dis.* 2006;47(3):539-548.
15. Saito T, Matsunaga A. Lipoprotein glomerulopathy may provide a key to unlock the puzzles of renal lipidosis. *Kidney Int.* 2014;85(2):243-245.
16. Chen S, Liu ZH, Zheng JM, Zhang X, Li LS. A complete genomic analysis of the apolipoprotein E gene in Chinese patients with lipoprotein glomerulopathy. *J Nephrol.* 2007;20:568-575.
17. Oikawa S, Suzuki N, Sakuma E, et al. Abnormal lipoprotein and apolipoprotein pattern in lipoprotein glomerulopathy. *Am J Kidney Dis.* 1991;18(5):553-558.
18. Fukunaga M, Nagahama K, Aoki M, et al. Membranous nephropathy-like apolipoprotein E deposition disease with apolipoprotein E Toyonaka (Ser197Cys) and a homozygous apolipoprotein E2/2. *Case Rep Nephrol Dial.* 2018;8(1):45-55.
19. Matsunaga A, Furuyama M, Hashimoto T, Toyoda K, Ogino D, Hayasaka K. Improvement of nephrotic syndrome by intensive lipid-lowering therapy in a patient with lipoprotein glomerulopathy. *Clin Exp Nephrol.* 2009;13(6):659-662.
20. Cheung CY, Chan AO, Chan GP, Iu HY, Shek CC, Chau KF. Long-term outcome of kidney transplantation in a patient with coexisting lipoprotein glomerulopathy and fibrillary glomerulonephritis. *Clin Kidney J.* 2014;7(4):396-398.