

Prevalence of Thymic Parathyroids in Primary Hyperparathyroidism During Radioguided Parathyroidectomy

Sophie Dream¹, Brenessa Lindeman and Herbert Chen¹

Department of Surgery, The University of Alabama at Birmingham, Birmingham, AL, USA.

Clinical Medicine Insights:
Endocrinology and Diabetes
Volume 12: 1–4
© The Author(s) 2019
Article reuse guidelines:
sagepub.com/journals-permissions
DOI: 10.1177/1179551419869917



ABSTRACT

BACKGROUND: Radioguided surgery has been an effective tool for identifying hyperfunctioning parathyroid glands during routine parathyroidectomy for hyperparathyroidism. The purpose of this study was to examine the role of radioguided surgery for the identification of intrathymic parathyroid glands.

MATERIAL AND METHODS: Between March 2001 and February 2018, 2291 patients underwent parathyroidectomy by 1 surgeon for primary hyperparathyroidism. Of these patients, 158 (7%) were identified to have an ectopic intrathymic parathyroid gland. All patients underwent radioguided parathyroidectomy. Ex vivo radionuclide counts were used to confirm parathyroid excision with specimen radioactivity of >20% of the background level.

RESULTS: The mean age was 56 ± 1 years with 74% of the patients being female. Preoperatively, 122 patients underwent sestamibi scan, which correctly identified the affected gland 61% of the time. Mean background radionuclide count was 208 ± 7 , mean ex vivo radionuclide count was 127 ± 9 , with ex vivo counts of removed glands >20% in all patients. All ectopic parathyroid glands were successfully identified using gamma probe. Ex vivo counts found to be significantly higher in patients with adenomas. Patients with parathyroid adenomas also were older in age and had higher preoperative calcium levels. While 10% of patients with primary hyperparathyroidism have hyperplasia, 42% of patients with thymic parathyroids had hyperplasia.

CONCLUSIONS: Radioguided parathyroidectomy is useful in detecting ectopic parathyroid glands in the thymus. Patients with hyperplasia disproportionately have clinically significant thymic parathyroid glands.

KEYWORDS: hyperparathyroidism, radioguided surgery, parathyroidectomy, ectopic parathyroid, hyperplasia

RECEIVED: July 23, 2019. **ACCEPTED:** July 25, 2019.

TYPE: Original Article

FUNDING: The author(s) received no financial support for the research, authorship, and/or publication of this article.

DECLARATION OF CONFLICTING INTEREST: The author(s) declared no potential conflicts of interest with respect to the research, authorship, and/or publication of this article.

CORRESPONDING AUTHOR: Herbert Chen, The University of Alabama at Birmingham, 1808 7th Avenue, Boshell Building, Birmingham, AL 35233, USA. Email: hchen@uabmc.edu

Introduction

Primary hyperparathyroidism affects approximately 1% of the population.¹ Management is surgical excision of the hyperfunctioning gland(s), with 80% of cases attributable to a single adenoma and cure achieved in >95% of cases.² This cure rate is dependent on surgeon experience, as hospitals performing low-volume parathyroid surgery have a significantly higher failure rate of parathyroidectomy for glands in the normal anatomic location when compared with high-volume centers (89% vs 13%, $P < .0001$).³

Persistent hyperparathyroidism after parathyroidectomy may be due to a hyperfunctioning gland in an ectopic location, about 16% to 31% cases, which may result in operative failure.⁴⁻⁷ Sixty-two percent of ectopic parathyroid glands are identified to be an inferior gland. They are most commonly found within the thymus (30%), anterosuperior mediastinum (22%), and thyrothymic ligament (17%).⁷ However, cadaveric studies have demonstrated that the lower parathyroid is identified within the thymus up to 41% of the time.⁸

Radioguided surgery has been an effective tool for identifying hyperfunctioning parathyroid glands, including both adenomas and hyperplastic glands during routine parathyroidectomy

for hyperparathyroidism.⁹ The purpose of this study was to examine the role of radioguided surgery for the identification of intrathymic adenomatous and hyperplastic parathyroid glands.

Materials and Methods

A retrospective review of patients who underwent parathyroidectomy between March 2001 and February 2018 was performed from a prospectively collected database. There were 2291 patients who underwent parathyroidectomy by 1 surgeon for primary hyperparathyroidism. Of these patients, 158 (7%) were identified to have an ectopic intrathymic parathyroid gland and comprise the study population of interest. Demographics, imaging, and intraoperative radioguided probe data were evaluated.

All patients underwent radioguided parathyroidectomy with preoperative injection of 10 mCi of technetium-99m (^{99m}Tc) sestamibi. A collimated gamma probe (Neoprobe Gamma Detection System, Devicor Medical Products, Inc., part of Leica Biosystems, Cincinnati, OH) was placed over the thyroid isthmus to obtain a background count. Parathyroid exploration was performed. When an enlarged parathyroid gland was encountered, it was excised and placed on top of the



gamma probe, directed away from the patient, to obtain ex vivo radionuclide counts. The cause of primary hyperparathyroidism was determined by the surgeon, a single enlarged and hyperfunctioning parathyroid gland was determined to be an adenoma. Patients with 2 enlarged and hyperfunctioning parathyroid glands were considered to have a double adenoma; in these patients both affected glands were excised. If all parathyroid glands were affected, patients were classified as having hyperplastic disease; these patients underwent subtotal parathyroidectomy. In all cases, excised parathyroid glands were confirmed to be hyperfunctioning with ex vivo radionuclide counts greater than 20% of the background level and intraoperative parathyroid hormone (ioPTH) monitoring was used following the Miami and the Wisconsin criteria.^{10,11}

Cervical thymectomy was performed in cases with missing lower parathyroid glands or when ioPTH levels did not drop appropriately after excision of affected parathyroid glands in eutopic locations. Excised thymic tissue was scanned with the gamma probe, again directed away from the patient, to confirm the excision of an ectopic parathyroid (Figure 1). Ex vivo radionuclide counts were used to confirm parathyroid excision with specimen radioactivity of >20% of the background level. Curative excision was confirmed with the normalization of postoperative PTH and calcium levels at 6 months.

SPSS Statistics software (version 25, IBM corp) was used to perform statistical analysis. Data are reported as mean \pm standard error of the mean (SEM). Comparison among groups was performed using 1-way analysis of variance (ANOVA). A *P* value of <.05 was considered statistically significant. This study was approved by the University of Alabama at Birmingham Institutional Review Board (IRB-160921006); informed consent was waived in this study.

Results

Patient and outcomes

The mean age was 56 ± 1 years with 74% of the patients being female (range: 9-83 years). Mean preoperative calcium was 10.7 ± 0.1 mg/dL (reference range: 8.4-10.4 mg/dL) and the mean preoperative PTH was 112 ± 6 pg/mL (reference range: 12-88 pg/mL). Twenty-seven patients (17%) had previously undergone a neck exploration. Preoperatively, 122 patients underwent sestamibi scan with the scan correctly identifying the affected gland 61% of the time. All patients (100%) were cured of their hyperparathyroidism after radioguided parathyroid surgery with a mean postoperative calcium of 9.3 ± 0.1 mg/dL and mean postoperative PTH of 46 ± 3 pg/mL at 2 weeks postoperatively. The mean postoperative calcium and mean postoperative PTH were 9.4 ± 0.1 mg/dL and 46 ± 3 pg/mL, respectively, at 6 months postoperatively.

Patients were stratified based on whether their hyperparathyroidism was due to a single adenoma, double adenoma, or hyperplasia. Sixty-eight patients had a single adenoma, 24 had

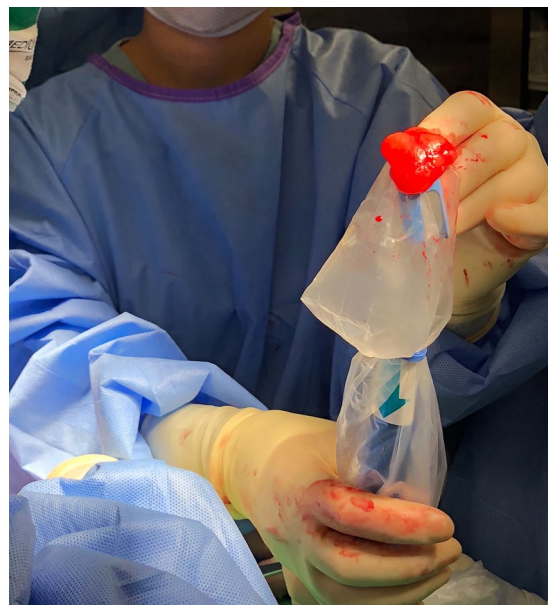

Figure 1. Measurement of ex vivo radionuclide counts.

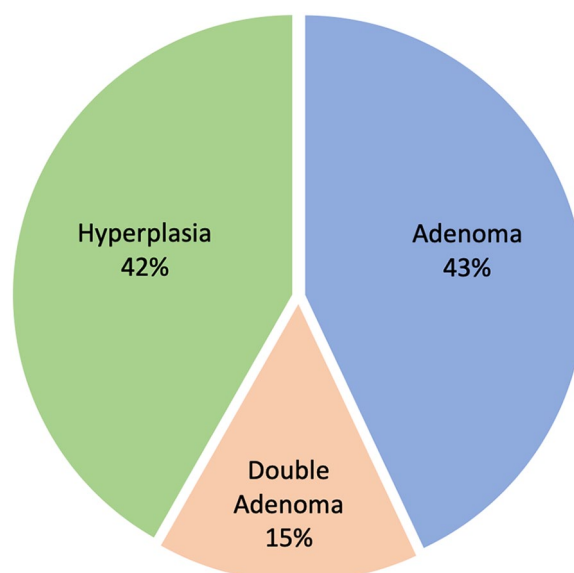


Figure 2. The cause of hyperparathyroidism in this study population.

double adenoma, and 66 had hyperplasia. While 10% of patients with primary hyperparathyroidism generally have hyperplasia, 42% of patients with thymic parathyroids had hyperplasia (Figure 2).¹

Comparison was performed across the 3 groups (Table 1). Patients with parathyroid adenomas were on average older than patients with double adenomas and hyperplasia (61 ± 2 vs 58.3 ± 3 and 51 ± 2 years, *P* = .001). There was no difference in gender composition of the groups (75% vs 79% vs 71%, *P* = .732). Preoperative calcium was significantly higher in patients with adenoma (11.0 ± 0.1 vs 10.6 ± 0.2 and 10.5 ± 0.1 mg/dL, *P* = .001). There was no difference in the mean preoperative PTH (121 ± 9 vs 108 ± 15 and 103 ± 7 pg/mL, *P* = .294).

Table 1. Comparison of demographic and laboratory data.

	ADENOMA	DOUBLE ADENOMA	HYPERPLASIA	P VALUE
N	68	24	66	
Gender (%female)	75%	79%	71%	.732
Age (years)	61 ± 2	58 ± 3	51 ± 2	.001
Preoperative Ca (mg/dL)	11.0 ± 0.1	10.6 ± 0.2	10.5 ± 0.1	.001
Preoperative PTH (pg/mL)	121 ± 9	108 ± 15	103 ± 7	.294
Postoperative Ca (mg/dL)	9.42 ± 0.1	9.34 ± 0.1	9.24 ± 0.1	.017
Postoperative Ca (mg/dL) at 6 months	9.44 ± 0.1	9.46 ± 0.1	9.36 ± 0.1	.732
Postoperative PTH (pg/mL)	50 ± 5	47 ± 9	41 ± 5	.481
Postoperative PTH (pg/mL) at 6 months	47 ± 3	35 ± 4	51 ± 6	.151

Abbreviation: PTH, parathyroid hormone.

Table 2. Radioguided excision data.

	ADENOMA	DOUBLE ADENOMA	HYPERPLASIA	P VALUE
Mean background counts	210 ± 11	192 ± 13	212 ± 12	.615
Mean ex vivo counts	162 ± 16	105 ± 20	100 ± 10	.003
Mean ex vivo counts (% background)	78 ± 6%	65 ± 18%	51% ± 5%	.017

Radioguided data

Mean background radionuclide count was 208 ± 7 , mean ex vivo radionuclide count was 127 ± 9 , with ex vivo counts of removed glands $>20\%$ of background in all patients. All ectopic parathyroid glands were successfully identified using gamma probe after excision. Ex vivo counts were found to be significantly higher in patients with adenomas (162 ± 16 vs 105 ± 20 and 100 ± 10 , $P = .003$; Table 2).

Discussion

The role of radioguidance to aid in the identification of ectopic intrathyroidic parathyroid glands has not been well defined. This study serves to evaluate the utility of radioguided surgery for ectopic parathyroid glands within the thymus. Of the patients studied who underwent radioguided parathyroidectomy for primary hyperparathyroidism, 158 had an ectopic intrathyroidic parathyroid gland which was identified intraoperatively using a gamma probe, precluding the need for frozen section.

Within this series, there was an increased proportion of patients with hyperplasia (42%) compared with all patients who had primary hyperparathyroidism. Considering that parathyroid hyperplasia affects all parathyroid glands, this likely does not represent an increased percentage of ectopic parathyroid glands in the thymus, but a high rate of detection of ectopic glands due to their clinical significance in this patient

population. In patients with parathyroid adenomas, especially with affected upper glands, the detection of a normal, ectopic intrathyroidic parathyroid gland would likely be less common. It is notable that the determination of adenomatous versus hyperplastic disease in this series was made by the surgeon intraoperatively. Given that not all patients underwent 4-gland exploration, the proportion of patients with hyperplastic disease may not be accurate. In addition, the confirmation of a parathyroid adenoma with pathology was not possible in this retrospective series as pathology reporting at our institution did not specify adenomatous versus hyperplastic disease.

Radioguided surgery has been established as a useful adjunct to intraoperative localization of parathyroid tissue in parathyroidectomy. Murphy and Norman¹² demonstrated that parathyroid adenomas have radionuclide ex vivo counts $>20\%$ of the background, obviating the need to confirm that the excised tissue is hyperfunctioning parathyroid tissue on frozen section. Past studies have shown the use of intraoperative sestamibi for detecting parathyroid glands to be equally effective in both adenomatous and hyperplastic glands.⁹ In addition, minimally invasive radioguided parathyroidectomy has been shown to decrease operative time and allows for the omission of frozen section, decreasing cost without compromising outcomes or patient safety.^{13,14}

In a case series of 840 patients, cervical thymectomy occurred 18% of the time with confirmation of parathyroid

gland on pathology 97% of the time; 3% of patients had persistent disease.¹⁵ The use of intraoperative radioguidance can help confirm the presence of hyperfunctioning parathyroid tissue within the excised thymic tissue during the operation. With the addition of ioPTH monitoring to confirm the excision of all affected parathyroid glands, 1 study was able to demonstrate cure of all the patients who underwent parathyroidectomy with the use of preoperative sestamibi scan or gamma probe guidance.¹⁶ We similarly demonstrated a 100% cure rate in this series with the addition of ioPTH to confirm excision of all hyperfunctioning parathyroid tissue. Notably, while most of the patients in this series underwent preoperative sestamibi scan, the causative parathyroid gland(s) were only identified in 61% of cases prior to surgery.

Sullivan et al described the use of preoperative parathyroid scan in combination with intraoperative ^{99m}Tc sestamibi with gamma probe guidance to focus dissection. They demonstrated 94% accuracy in predicting the location of a parathyroid adenoma using this technique.¹⁷ There have been multiple reports of successful intraoperative localization of intrathymic and intrathoracic ectopic parathyroid glands.¹⁸⁻²¹ One such case describes the in vivo identification of an intrathymic adenoma with radionuclide counts 2.5 times greater than the background levels.²²

To date, the use of radioguidance in mediastinal ectopic parathyroid glands has been questioned due to the high cardiac uptake of ^{99m}Tc sestamibi, which limits the use of in vivo measurement of radioactivity to localize hyperfunctioning parathyroid tissue.²³ However, we have found it to be useful in confirming the excision of an ectopic parathyroid gland within the thymus in the setting of cervical thymectomy for a missing inferior gland.

Conclusions

Radioguided parathyroidectomy is useful in detecting ectopic parathyroid glands in the thymus. Patients with hyperplasia disproportionately have clinically significant thymic parathyroid glands.

Author Contributions

SD contributed to study design, statistical analysis, and manuscript preparation. HC contributed to study design, database preparation, and manuscript revision. BL contributed to database preparation and manuscript revision.

ORCID iDs

Sophie Dream  <https://orcid.org/0000-0002-9738-0796>

Herbert Chen  <https://orcid.org/0000-0003-3031-4521>

REFERENCES

- Mallick R, Chen H. Diagnosis and management of hyperparathyroidism. *Adv Surg*. 2018;52:137-153.
- Chen H, Sokoll LJ, Udelsman R. Outpatient minimally invasive parathyroidectomy: a combination of sestamibi-SPECT localization, cervical block anesthesia, and intraoperative parathyroid hormone assay. *Surgery*. 1999;126:1016-1021; discussion 1021-1022.
- Chen H, Wang TS, Yen TW, et al. Operative failures after parathyroidectomy for hyperparathyroidism: the influence of surgical volume. *Ann Surg*. 2010;252:691-695.
- Weber CJ, Sewell CW, McGarity WC. Persistent and recurrent sporadic primary hyperparathyroidism: histopathology, complications, and results of reoperation. *Surgery*. 1994;116:991-998.
- Karakas E, Müller HH, Schlosshauer T, Rothmund M, Bartsch DK. Reoperations for primary hyperparathyroidism—improvement of outcome over two decades. *Langenbecks Arch Surg*. 2013;398:99-106.
- Richards ML, Thompson GB, Farley DR, Grant CS. Reoperative parathyroidectomy in 228 patients during the era of minimal-access surgery and intraoperative parathyroid hormone monitoring. *Am J Surg*. 2008;196:937-942; discussion 942-943.
- Phitayakorn R, McHenry CR. Incidence and location of ectopic abnormal parathyroid glands. *Am J Surg*. 2006;191:418-423.
- Wang C-A. The anatomic basis of parathyroid surgery. *Ann Surg*. 1973;183:271-275.
- Chen H, Mack E, Starling JR. Radioguided parathyroidectomy is equally effective for both adenomatous and hyperplastic glands. *Ann Surg*. 2003;238:332-337; discussion 337-338.
- Irvin GL III, Prudhomme DL, Deriso GT, Sfakianakis G, Chandarlapaty SK. A new approach to parathyroidectomy. *Ann Surg*. 1994;219:574-581.
- Cook MR, Pitt SC, Schaefer S, Sippel R, Chen H. A rising ioPTH level immediately after parathyroid resection: are additional hyperfunctioning glands always present? an application of the Wisconsin Criteria. *Ann Surg*. 2010;251:1127-1130.
- Murphy C, Norman J. The 20% rule: a simple, instantaneous radioactivity measurement defines cure and allows elimination of frozen sections and hormone assays during parathyroidectomy. *Surgery*. 1999;126:1023-1028; discussion 1028-1029.
- Goldstein RE, Blevins L, Delbecke D, Martin WH. Effect of minimally invasive radioguided parathyroidectomy on efficacy, length of stay, and costs in the management of primary hyperparathyroidism. *Ann Surg*. 2000;231:732-742.
- Hutchinson JR, Yandell DW, Bumpous JM, Fleming MM, Flynn MB. Three-year financial analysis of minimally invasive radio-guided parathyroidectomy. *Am Surg*. 2004;70:1112-1115.
- Stalberg P, Grodski S, Sidhu S, Sywak M, Delbridge L. Cervical thymectomy for intrathymic parathyroid adenomas during minimally invasive parathyroidectomy. *Surgery*. 2007;141:626-629.
- Dackiw AP, Sussman JJ, Fritsche HA Jr, et al. Relative contributions of technetium Tc 99m sestamibi scintigraphy, intraoperative gamma probe detection, and the rapid parathyroid hormone assay to the surgical management of hyperparathyroidism. *Arch Surg*. 2000;135:550-555; discussion 555-557.
- Sullivan DP, Scharf SC, Komisar A. Intraoperative gamma probe localization of parathyroid adenomas. *Laryngoscope*. 2001;111:912-917.
- Onoda N, Ishikawa T, Yamada N, et al. Radioisotope-navigated video-assisted thoracoscopic operation for ectopic mediastinal parathyroid. *Surgery*. 2002;132:17-19.
- Onoda N, Ishikawa T, Nishiyama N, Kawabe J, Takashima T, Hirakawa K. Focused approach to ectopic mediastinal parathyroid surgery assisted by radio-guided navigation. *Surg Today*. 2014;44:533-539.
- Shah-Patel LR, Ghesani M, Connery C, Moore E. Gamma probe detection of ectopic parathyroid adenoma. *Radiol Case Rep*. 2008;3:161.
- O'Herrin JK, Weigel T, Wilson M, Chen H. Radioguided parathyroidectomy via VATS combined with intraoperative parathyroid hormone testing: the surgical approach of choice for patients with mediastinal parathyroid adenomas? *J Bone Miner Res*. 2002;17:1368-1371.
- Daliakopoulos SI, Chatzoulis G, Lampridis S, et al. Gamma probe-assisted excision of an ectopic parathyroid adenoma located within the thymus: case report and review of the literature. *J Cardiothorac Surg*. 2014;9:62.
- Schwarzlmuller T, Brauckhoff K, Lovas K, Biermann M, Brauckhoff M. High cardiac background activity limits ^{99m}Tc-MIBI radioguided surgery in aortopulmonary window parathyroid adenomas. *BMC Surg*. 2014;14:22.