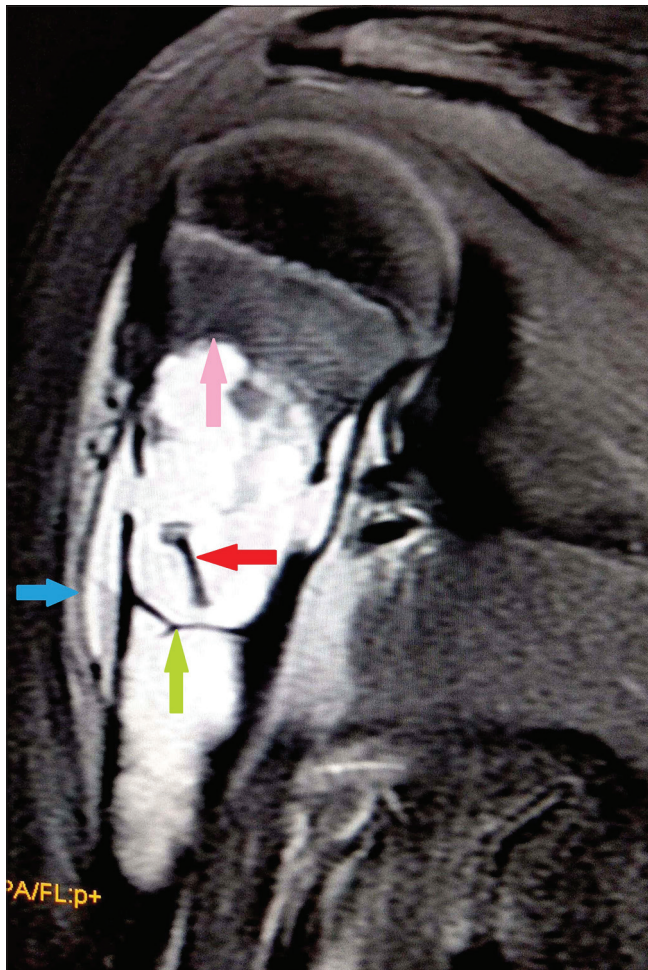


# Explanation of radiological signs and fracture indices in a unicameral bone cyst

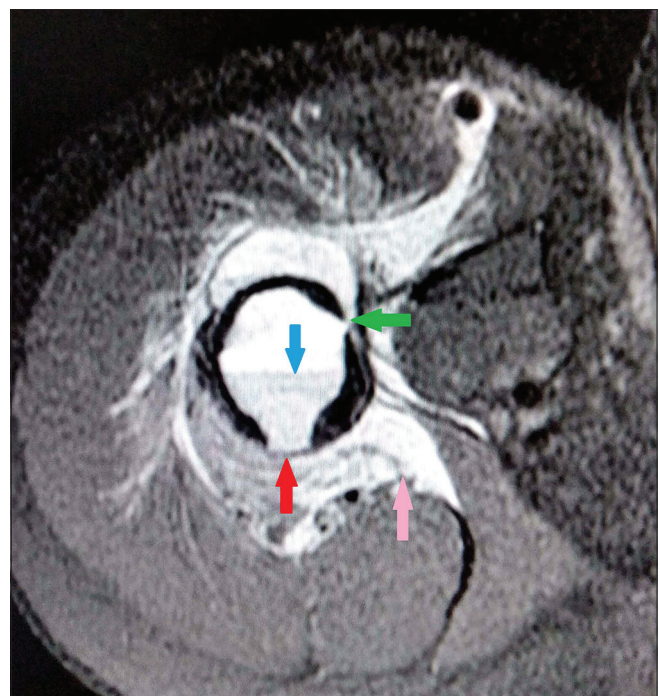Dear Sir,

A 12-year-old boy had a history of fall and sustained pathological fracture of proximal humerus. He was further referred for MR imaging that showed a cystic lesion along the long axis of the humerus in the proximal meta-diaphyseal region with no extension across the



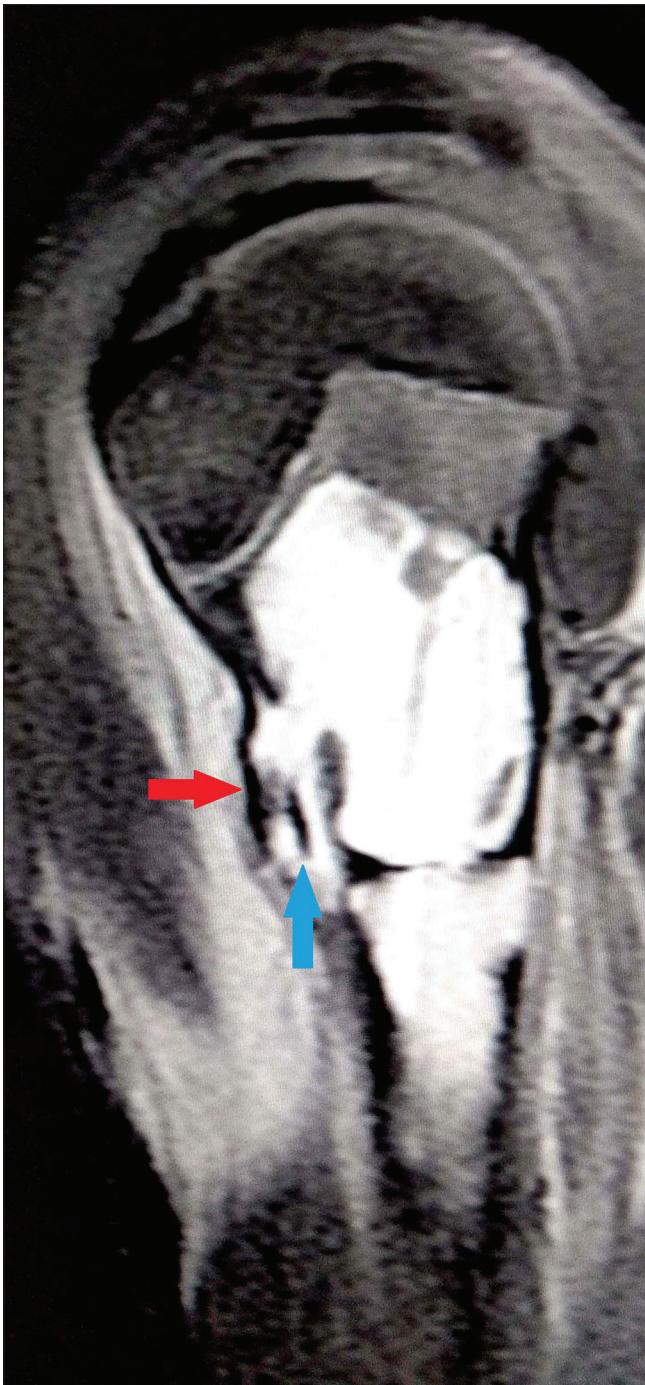
**Figure 1:** Coronal MERGE (gradient) MR image of the shoulder joint demonstrating radiological signs in a unicameral bony cyst involving the proximal humerus in a 12-year-old boy. Note the meta-diaphyseal location of the cyst with no extension across the epiphyseal plate. Linear hypointense focus is seen in the dependent position indicating "Fallen fragment sign" (red arrow). Endosteal scalloping (pink arrow) and internal septation (green arrow) is being demonstrated. Note the periosteal elevation with collection demonstrating blood-fluid level (blue arrow)

epiphyseal plate. Lesion appeared heterogeneously hyperintense on T2-weighted images with dependent blooming on GRE images indicating blood-fluid levels. Few internal septa with multiple cortical breaks were demonstrated in the proximal aspect of the lesion with periosteal elevation and collection. Linear T2-weighted hypointense foci are seen within the lesion indicating fallen fracture fragments [Figures 1-3]. Unicameral bone cyst is described as a solitary, lytic metaphyseal lesion, which does not cross the epiphyseal plate.<sup>[1]</sup> The lesion has well defined margins with narrow transition zone with the long axis of the lesion parallel to the long axis of bone and is known to migrate towards diaphysis during growth of child. It commonly occurs below 20 years of age and is commonly located in proximal humerus and femur in skeletally immature individuals and lacks malignant potential.<sup>[2]</sup> Radiological signs described in unicameral bone cyst are fallen fragment,<sup>[3]</sup> trapped door<sup>[4]</sup> and rising bubble signs.<sup>[5]</sup>



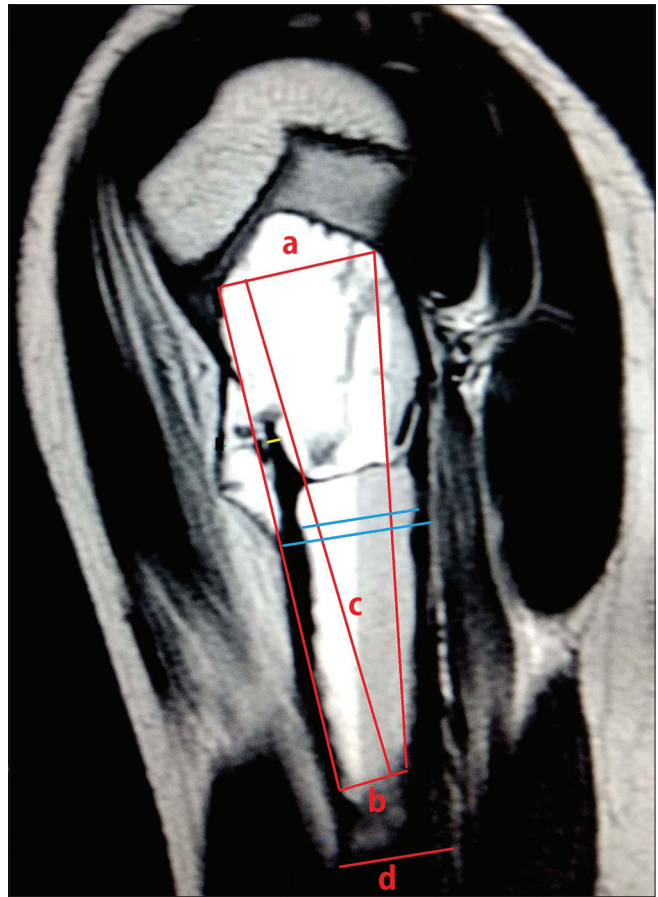
**Figure 2:** Axial MERGE (gradient) MR image of the unicameral bony cyst demonstrating cortical thinning (red arrow) and cortical break (green arrow). Note the blood-fluid level within the cyst (blue arrow) and fluid collection/hematoma in the surrounding soft tissues (pink arrow)





**Figure 3:** Sagittal T2-weighted MR image of the unicameral bone cyst in the proximal humerus demonstrating a periosteal hinge that keeps the fractured bone fragment from falling dependently into the cyst indicating "Trapped door sign" (blue arrow). Note the elevated and thinned out periosteum (red arrow)

Fallen fragment sign results from a pathologic fracture of the cyst wall, with displacement of the fragment into the dependent portion of the cyst [Figure 1]. Trapped door sign is a variant of the fallen fragment sign described in literature in which a periosteal hinge keeps the fragment



**Figure 4:** Sagittal T2-weighted MR image demonstrating the various indices predicting the risk of pathological fracture in a unicameral bone cyst. Calculation of "Bone cyst index (BCI)" first described by Kaelin and MacEwan<sup>[6]</sup> is demonstrated (in Red).  $BCI = [(a + b)/2 \times c]/d^2$ , which is obtained by dividing cyst area by the diameter of diaphysis squared. Calculation of "Bone cyst diameter (BCD)" first described by Ahn and Park<sup>[7]</sup> is demonstrated (in blue). BCD is expressed as the percentage of bone occupied by the cyst in transverse plane and bone cyst diameter >85% is a significant predictor of fracture. Note the thinned out cortex demonstrated (in yellow) with a minimal cortical thickness (MCT) less than 2 mm predicting a high risk of pathological fracture

from falling dependently and allows it to change position with the patient [Figure 3]. The trapped door is seen due to hydrostatic pressure of the fluid contained within the cyst. After sustaining a pathological fracture, presence of a gas bubble at the most non-dependent portion of the lytic bone lesion implies the lesion is hollow. On MRI, fluid level may be noted with cortical thinning, periosteal hematoma, septations, and pathological fracture [Figures 1-3]. The periphery of the lesion and septa within may show enhancement on administration of contrast. Unicameral bone cysts appear to be geographic lucent lesions on radiography with a central location, cortical thinning, and gentle expansion. The bone cyst index described by Kaelin and MacEwan<sup>[6]</sup> can be used as an easy method to assess the mechanical resistance of the cyst wall. The bone cyst index

is calculated by dividing the cyst area by the diameter of the diaphysis squared [Figure 4]. Kaelin and MacEwan found that unicameral bone cyst with a bone cyst index of more than 4 for the humerus and more than 3.5 for the femur were at high risk for fracture. Ahn and Park<sup>[7]</sup> reported a second predictor for fracture is the bone cyst diameter and is expressed as the percentage of bone occupied by the cyst in the transverse plane. Unicameral bone cyst is considered to be at a high risk for fracture when the bone cyst diameter reaches more than 85% in both the anteroposterior and lateral images [Figure 4]. A third predictor is the minimal cortical thickness with a value less than 2 mm predicting a high risk of fracture [Figure 4].<sup>[6]</sup> Differential diagnoses for unicameral bone cyst include aneurysmal bone cyst, eosinophilic granuloma, enchondroma, fibrous dysplasia, and intraosseous ganglia. MRI helps in differentiating unicameral bone cyst from aneurysmal bone cyst.

#### Declaration of patient consent

The authors certify that they have obtained all appropriate patient consent forms. In the form the patient(s) has/have given his/her/their consent for his/her/their images and other clinical information to be reported in the journal. The patients understand that their names and initials will not be published and due efforts will be made to conceal their identity, but anonymity cannot be guaranteed.

#### Financial support and sponsorship

Nil.

#### Conflicts of interest

There are no conflicts of interest.

**Reddy Ravikanth, Kanagasabai Kamalasekar**

Department of Radiology, Holy Family Hospital,  
Thodupuzha, Kerala, India.  
E-mail: ravikanthreddy06@gmail.com

## References

1. Mascard E, Gomez-Brouchet A, Lambot K. Bone cysts: Unicameral and aneurysmal bone cyst. *OrthopTraumatol Surg Res*2015;101 (1 Suppl):S119-27.
2. Kadhim M, Thacker M, Kadhim A, Holmes L. Treatment of unicameral bone cyst: Systematic review and meta analysis. *J Child Orthop*2014;8:171-91.
3. Killeen KL. The fallen fragment sign. *Radiology*1998;207:261-2.
4. Komiya S, Inoue A. Development of a solitary bone cyst-a report of a case suggesting its pathogenesis. *ArchOrthop Trauma Surg*2000;120:455-7.
5. Jordanov MI. The "rising bubble" sign: A new aid in the diagnosis of unicameral bone cysts. *Skeletal Radiol*2009;38:597-600.
6. Kaelin AJ, MacEwan GD. Unicameral bone cysts. Natural history and the risk of fracture. *Int Orthop* 1989;13:275-82.
7. Ahn JI, Park JS. Pathological fractures secondary to unicameral bone cysts. *Int Orthop* 1994;18:20-2.

This is an open access journal, and articles are distributed under the terms of the Creative Commons Attribution-NonCommercial-ShareAlike 4.0 License, which allows others to remix, tweak, and build upon the work non-commercially, as long as appropriate credit is given and the new creations are licensed under the identical terms.

Access this article online	
<b>Quick Response Code:</b>	<b>Website:</b> www.ijri.org
	<b>DOI:</b> 10.4103/ijri.IJRI_443_18

**Cite this article as:** Ravikanth R, Kamalasekar K. Explanation of radiological signs and fracture indices in a unicameral bone cyst. *Indian J Radiol Imaging* 2019;29:104-6.

© 2019 Indian Journal of Radiology and Imaging | Published by Wolters Kluwer - Medknow