

# Right Dominance in the Incidence of External Auditory Canal Squamous Cell Carcinoma in the Japanese Population: Does Handedness Affect Carcinogenesis?

Atsunobu Tsunoda, MD; Takuro Sumi, MD; Omi Terasaki, MD; Seiji Kishimoto, MD

**Objectives/Hypothesis:** To investigate the relationship between handedness and the incidence of squamous cell carcinoma in the external auditory canal (EACSCC).

**Materials and Methods:** Sixty-eight cases of EACSCC were enrolled in this study, and their affected side was checked. Handedness and ear-picking habits were also investigated in 34 EACSCC cases. Handedness was judged based on self-categorization, and the relationship between handedness and the affected side was investigated.

**Results:** Fifty-two cases occurred on the right side, and 16 cases occurred on the left side of patients with EACSCC. The incidence of laterality in EACSCC showed a statistically significant right dominance. Concerning handedness, 29 cases were right-handed, 4 cases were left-handed, and 1 case was ambidextrous. Twenty-seven out of the 29 right-handed cases and 1 ambidextrous case suffered from carcinoma on the right side, whereas 3 left-handed cases suffered from carcinoma on the left side. That is, most of the cases suffered from EACSCC on the same side as their handedness, and this tendency showed a statistically significant difference. Most of the patients with EACSCC experienced itching and habitual ear-picking in the affected side.

**Conclusion:** Mechanical stimulations to the EAC, such as ear picking, may plausibly cause EACSCC. In Japan, ear picking, also called “mimikaki,” is a popular habit and an established unique culture. Because ear picking requires delicate handling and manipulation, this tends to occur on the same side as the handedness in the Japanese population. This is the first report about the relationship between handedness and carcinogenesis.

**Key Words:** Carcinogenesis, ear-picking, eczema, handedness, temporal bone tumors.

**Level of Evidence:** N/A.

## INTRODUCTION

Malignant disorders in the ear and temporal bone are rare, and their treatment is still a formidable challenge for clinicians. Among these disorders, carcinoma in the external auditory canal (EAC) occurs most frequently; however, this tumor mimics inflammation and eczema. Delayed diagnosis frequently occurs, so advanced cases are commonly encountered. For such advanced disease, treatment is a daunting task for clinicians.<sup>1–8</sup>

We have treated patients with this rare but formidable disease and found one curious occurrence, that is, squamous cell carcinoma in the EAC (EACSCC) tends to occur on the right side, at least among the Japanese

population. To clarify this curiosity, we investigated patients' ear-picking habits and their handedness.

In this paper, we reported the relationship between handedness and the occurrence and possible carcinogenesis of this disease. This study is the first report about the relationship between carcinogenesis and handedness.

## MATERIALS AND METHODS

From 2001 to 2015, we encountered 94 Japanese patients with histologically proven temporal bone malignancy. These patients underwent careful ear examination of both sides and imaging studies. Eighty-four malignancies occurred in the EAC, and the other 10 malignancies occurred in the middle ear. EACSCC is the most common pathology ( $n=68$ ) followed by adenoid cystic carcinoma in the EAC ( $n=11$ ). No patients suffering from bilateral disease were encountered in this study.

In 2011, we investigated the handedness of these patients. Patients' self-impression of their handedness was judged from the viewpoint of skillfulness.<sup>9,10</sup> Because left-handed cases tend to have suffered from reformation of their handedness on the right, we asked about the experience of such reformation. We also asked the patients about itching in the EAC and their ear-picking habit. A device for ear picking was also checked. We obtained written informed consent from the patients. This study was approved by the Review Committee (Tokyo Medical and Dental University No. 1066). Statistical analysis was performed using JMP® 8 (SAS Institute, Inc., Cary, NC, USA). The incidence was analyzed using Fisher's exact test.

## RESULTS

Patients' data are listed in Table 1. Sixty-four malignancies occurred on the right side, and the other

This is an open access article under the terms of the Creative Commons Attribution-NonCommercial-NoDerivs License, which permits use and distribution in any medium, provided the original work is properly cited, the use is non-commercial and no modifications or adaptations are made.

From the Department of Otolaryngology (A.T.), Juntendo University Nerima Hospital, Tokyo, Japan; Department of Head and Neck Surgery (T.S.), Tokyo Medical and Dental University, Tokyo, Japan; Kurita Hospital (O.T.), Kamogawa, Japan; and the Department of Otolaryngology (S.K.), Kameda Medical Center, Kamogawa, Japan

Editor's Note: This Manuscript was accepted for publication 3 November 2016.

Financial Disclosure: None

Conflict of Interest: Nothing to declare

Send correspondence to: Dr. Atsunobu Tsunoda, MD, Department of Otolaryngology, Juntendo University Nerima Hospital, Nerimaku Takandai 3-1-10, Tokyo 177-8521, Japan. E-mail: atsunoda@mac.com

DOI: 10.1002/liv.2.43

TABLE 1.  
Pathologies in this study (right/left)

	EAC	Middle ear	Total
SCC	68 (52/16)	8 (2/6)	76
ACC	11 (4/7)	0	11
BCC	1 (1/0)	0	1
VC	1 (1/0)	0	1
Carcinoid	1 (1/0)	1 (0/1)	2
RMS	1 (1/0)	0	1
OS	0	1 (1/0)	1
HCC/meta	1 (1/0)	0	1
Total	84 (61/23)	10 (3/7)	94

30 malignancies occurred on the left side. Fifty-two cases of EACSCC occurred on the right side, and 16 cases occurred on the left. That is, tumors occurred dominantly on the right side (test of proportion:  $P = 0.000013$ ).

Handedness was determined in 34 EACSCC cases. Two patients experienced reformation of their left-handedness on the right, and these two patients had their disease on the left side. No patients experienced the same on the left. Regarding patients' self-categorization of handedness, that is, which hand is more easily and skillfully operated, 29 patients answered "right hand," and 4 patients answered "left hand." One patient with the disease on the right could use both hands equally.

Right-handed patients tended to suffer from their tumors on the right EAC, whereas left-handed patients tended to suffer on the left EAC (Table 2). Except for an ambidextrous patient with EACSCC on the right, the affected side of this carcinoma was related to their handedness, and this tendency showed statistical significance ( $p=0.0070$ , Fisher's test).

All patients complained of ear itching to different degrees and habitually cleaned their ear canal at different frequencies. Three patients cleaned their ear canal multiple times a day. One of them used one package of 200 swabs monthly. Seven patients cleaned every day, and 2 patients cleaned every other day. One patient cleaned twice a month. Other patients could not accurately answer as to the exact frequency of ear picking. Sixteen patients answered "frequently," and 2 patients answered "sometimes." Three patients could not recall the frequency.

Twenty-one out of 34 patients reported laterality of ear-picking. Six patients answered that they picked both sides equally. Four out of six patients were right-

TABLE 2.  
Comparison of incidence between the side of EACSCC and handedness

	Right-handed	Left-handed	Ambidextrous	Total
Right Ca	27	1	1	29
Left Ca	2	3	0	5
Total	29	4	1	34

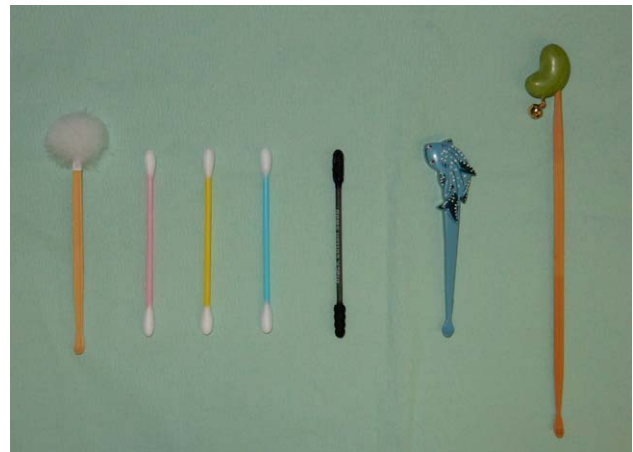


Fig. 1. Various types of mimikaki are sold in Japan for daily use and as souvenirs. The example on the left is a popular one with a small shovel-like ear cleaner. A fluffy piece of cotton is on the opposite end as a finishing touch. A cotton swab is also a popular device for ear picking as well as ear cleaning. The black one is a sticky type covered with glue. Various types of swabs are also sold.

handed, suffering from three right carcinomas and one left carcinoma. The other two were left-handed, suffering on the left. Fifteen patients mainly picked the right canal. Fourteen out of 15 patients were right-handed, and one was ambidextrous. These 15 patients showed carcinoma on the right side. The most popular devices for picking were bamboo sticks and cotton swabs. Few patients exclusively used a metal bar or a matchstick. These 34 patients showed eczema in the ear canal of the unaffected ear.

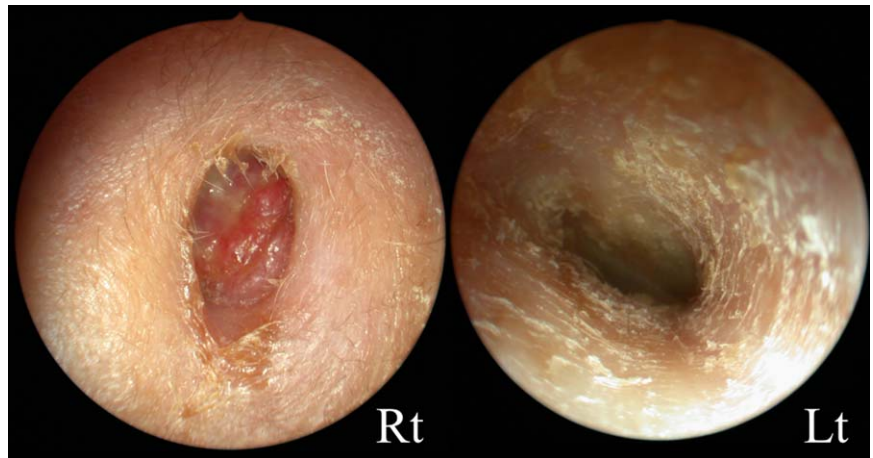
## DISCUSSION

Various factors may play a role in carcinogenesis, such as smoking, alcohol, viruses, *Helicobacter pylori*, irradiation, and ultraviolet radiation. To investigate such environmental factors, it is of great importance not only to recognize tumor pathology but also to prevent tumorigenesis. Concerning ear carcinoma, SCC in the middle ear tends to occur in patients with chronic otitis media and/or open mastoid surgery.<sup>11,12</sup> EACSCC also arose after radiotherapy for nasopharyngeal carcinoma.<sup>13,14</sup>

Concerning incidence, the dominance of the right side was also reported. Bacciu et al. reported 26 temporal bone carcinomas (57.8%) on the right side and 19 (42.2%) on the left side.<sup>15</sup> Shiga et al. reported that 9 patients had EACSCC on the right side, and 5 had EACSCC on the left side.<sup>16</sup> On the contrary, Gidley et al. reported left dominance (55%) and concluded that SCC in the temporal bone was more commonly found on the left ear of middle-aged to elderly men.<sup>8</sup> As mentioned above, we found right dominance in the incidence of primary EACSCC. To investigate this dominance, we started to check the handedness of the patients.

Although patients with cerumen impaction consult clinicians, ear picking is usually performed personally. Ear picking takes a special position in Japan. An ear pick and its device are named "mimikaki" (*mimi* = ear,

Fig. 2. A case of a 70-year-old female with EACSCC on the right side. She felt an ear itch, and picked her ear daily for at least 7 years. At first, she used a bamboo stick mimikaki then saw a slight bit of blood on the stick, so she changed to using a cotton swab. She felt an ear itch on both ears, and eczema was observed in her left ear. She is right-handed, and she mainly picked her right ear, as it was easier to pick.



*kaki* = picking) in Japanese, which means picking or scratching the EAC. Many mimikaki products, that is, devices for ear picking, are produced and commonly used in the country (Figure 1). Such devices were first produced more than 1,000 years ago in Japan.<sup>17</sup> They are used to remove earwax and also to ease the itchy feeling. We noticed that patients with EACSCC have ear-picking habits and tended to have eczema in the unaffected side (Figure 2). The EAC is sensitive, and ear picking needs delicate manipulation and is much easier on the side of the dominant hand.

Actually, the laterality of ear picking is related to the effected side in the present study. Another speculation from this data can be postulated: carcinoma produces an abnormal feeling, like itching, on the same side. Therefore, the patient with right carcinoma mainly picks the EAC on the right. However, if so, the right dominance in the incidence of EACSCC cannot be explained. We speculate that eczema or other factors might come first for the patient and give rise to ear picking.

Therefore, we speculated that excessive ear-picking and its mechanical stimulation might influence the right dominance in EACSCC. Although itching may occur on both sides of the ear, the ear-picking habit tends to occur with a patient's dominant hand, as delicate manipulation is required during ear picking.

As shown in the present study, right-handedness is dominant in humans.<sup>9,10</sup> Handedness is influenced by many factors, and the measurement of handedness is performed in various ways.<sup>9,10</sup> In this study, we judged handedness from self-impression.<sup>9,10</sup> Self-categorization of handedness accurately indicates with which hand a person is more skillful and makes it easier to manipulate the device to do delicate maneuvers such as mimikaki.<sup>9,17</sup>

The mimikaki habit is not common outside of Japan and few other Asian countries. Laterality in EACSCC occurrence has never been reported, and it may relate to the mimikaki habit in other populations. It is still unclear why this habit is common and even an established culture in Japan. The characteristics of cerumen are different in humans, and nearly 75% of the Japanese population has dry cerumen.<sup>18,19</sup> Such characteristics and the moist Japanese climate may relate to the habits and cultures of mimikaki.

We have never encountered a case with bilateral EACSCC, although such cases have been reported.<sup>20,21</sup> Multiple factors in carcinogenesis exist for EACSCC. However, an ear pick may be one of the influential causes of EACSCC in the Japanese population from the present data. Excessive ear-picking becomes a mechanical stimulation to the EAC and may cause SCC in the same way that dentures or pipes may cause tongue and lip cancers. This fact is worthy of consideration for the prevention of this disease, as habitual ear-pickers commonly exist among populations complaining of ear itch. The risk of ear-picking may play an important role in the early diagnosis and prevention of EACSCC.

## CONCLUSION

This is the first report about the relationship between handedness and carcinogenesis. Because of its rarity, the number of cases is not large enough, and further investigation is needed. However, this report may shed light on not only carcinogenesis but also the prevention of EACSCC. More information about the risk of excessive ear-picking is important for clinicians, and more so for citizens, for the early diagnosis and prevention of this rare but formidable disease.

## BIBLIOGRAPHY

1. Homer JJ, Lesser T, Moffat D, et al. Management of lateral skull base cancer: United Kingdom National Multidisciplinary Guidelines. *J Laryngol Otol* 2016;130(Suppl. S2):S119–S124.
2. Moffat DA, Wagstaff SA, Hardy DG. The outcome of radical surgery and postoperative radiotherapy for squamous carcinoma of the temporal bone. *Laryngoscope* 2005;115:341–347.
3. Nakagawa T, Kumamoto Y, Natori Y, et al. Squamous cell carcinoma of the external auditory canal and middle ear: an operation combined with preoperative chemoradiotherapy and a free surgical margin. *Otol Neurotol* 2006;27:242–248.
4. Yin M, Ishikawa K, Honda K, et al. Analysis of 95 cases of squamous cell carcinoma of the external and middle ear. *Auris Nasus Larynx* 2006;33:251–257.
5. Gidley PW, Thompson CR, Roberts DB, DeMonte F, Hanna EY. The oncology of otology. *Laryngoscope* 2012;122:393–400.
6. Moffat DA, Chiossone-Kerdel JA, Da Cruz M. Squamous cell carcinoma. In: Jackler RK, Driscoll CLW, eds. *Tumors of the Ear and Temporal Bone*. Philadelphia: Lippincott Williams & Wilkins; 2000: 67–83.
7. Madsen AR, Gundgaard MG, Hoff CM, et al. Cancer of the external auditory canal and middle ear in Denmark from 1992 to 2001. *Head Neck* 2008;30:1332–1338.

8. Gidley PW, Roberts DB, Sturgis EM. Squamous cell carcinoma of the temporal bone. *Laryngoscope* 2010;120:1144–1151.
9. Chapman LJ, Chapman JP. The measurement of handedness. *Brain Cognit* 1987;6:175–183.
10. Vuoksima E, Koskenvuo M, Rose RJ, Kaprio J. Origins of handedness: a nationwide study of 30 161 adults. *Neuropsychologia* 2009;47:1294–1301.
11. Wackym PA, Friedman I. Unusual tumors of the middle ear and mastoid. In: Jackler RK, Driscoll CLW, eds. *Tumors of the Ear and Temporal Bone*. Philadelphia: Lippincott Williams & Wilkins; 2000: 128–145.
12. Paaske PB, Witten J, Schwer S, et al. Results in treatment of carcinoma of the external auditory canal and middle ear. *Cancer* 1987;59:156–160.
13. Wang J, Xie B, Dai C. Clinical characteristics and management of external auditory canal squamous cell carcinoma in post-irradiated nasopharyngeal carcinoma patients. *Otol Neurotol* 2015;36:1081–1088.
14. Lambert EM, Garden AS, DeMonte F, Roberts DB, Gidley PW. Radiation-associated malignancies of the ear canal and temporal bone. *Laryngoscope* 2015;125:1198–1204.
15. Bacciu A, Clemente IA, Piccirillo E, Ferrari S, Sanna M. Guidelines for treating temporal bone carcinoma based on long-term outcomes. *Otol Neurotol* 2013;34:898–907.
16. Shiga K, Ogawa T, Maki A, Amano M, Kobayashi T. Concomitant chemoradiotherapy as a standard treatment for squamous cell carcinoma of the temporal bone. *Skull Base* 2011;21:153–158.
17. Ueno R. Mimikaki ga shitai (I want to do an earpick). In *Japanese Jive*, Tokyo, Japan; 2004.
18. Matsunaga E. The dimorphism in human normal cerumen. *Ann Hum Genet* 1962;25:273–286.
19. Nakano M, Miwa N, Hirano A, Yoshiura K, Niikawa N. A strong association of axillary osmidrosis with the wet earwax type determined by genotyping of the ABCC11 gene. *BMC Genet* 2009;10:42.
20. Wolfe SG, Lai SY, Bigelow DC. Bilateral squamous cell carcinoma of the external auditory canals. *Laryngoscope* 2002;112:1003–1005.
21. Elsürer C, Senkal HA, Zayyan E, et al. Bilateral external auditory canal squamous cell carcinoma: a case report. *Eur Arch Otorhinolaryngol* 2007;264:941–945.