

Ileocecal junction perforation caused by a sewing needle in incarcerated inguinal hernia

An unusual case report

Shiqi Liu, MD^a, Qifeng Li, PhD^b, Yumei Li, PhD^c, Yi Lv, MD^{d,*}, Jianhua Niu, MM^e, Quan Xu, MM^a, Jingru Zhao, MM^a, Yajun Chen, MD^f, Dayong Wang, MD^d, Ruimiao Bai, MM^g

Abstract

Introduction: This case study is concerning the meticulous observation of the moving process and track of 2 ingested needles using interval x-ray radiography, trying to localize the foreign bodies and reduce unnecessary exploration of digestive tract.

Case presentation: An unusual case of a 1-year, 9-month-old female baby, with incarcerated hernia perforation caused by sewing needles with sharp ends, was reported herein. The patient had swallowed 2 sewing needles. One needle was excreted uneventfully after 8 days. On the contrary, the other needle stabbed the ileocecal junction wall into the right side of inguinal hernia sac after 9 days, and the patient received successful operation management. Interval x-ray confirmed that 1 needle-like foreign body moving down in 8 days until excretion along with feces. However, the other pierced into the incarcerated hernia. Preoperative x-ray radiography successfully monitored the moving process and tract of the sewing needles. Considering the penetrating-migrating nature of the foreign bodies, once the sharp-pointed objects were located, they should be removed as the mortality and risk of related complications may be increased.

Conclusion: Interval x-ray radiography represents a meticulous preoperative monitoring method of the moving process and tract of needle-like foreign bodies. Interval x-ray with real-time images accurately detecting the moving foreign bodies could be help to reduce the unnecessary exploration of digestive tract and subsequently prevent possible complications. Based on the basic findings from the interval x-ray, treatment choices of endoscopic removal and surgical intervention may be attempted.

Keywords: foreign body, incarcerated hernia, needle migration, x-ray radiography

1. Introduction

Foreign body ingestion is commonly seen among pediatric population, and the vast majority of ingested foreign bodies pass through the gastrointestinal tract uneventfully. Nonoperative interventions would be necessary in 10% to 20% of patients,

Editor: N/A.

SL and QL contributed equally to this study.

The authors have no funding and conflicts of interest to disclose.

^a Department of Pediatric Surgery, Northwest Women's and Children's Hospital, Xi'an, Shaanxi Province, ^b Xinjiang Institute of Pediatrics, People's Hospital of Xinjiang Uygur Autonomous Region, Urumqi, Xinjiang, P.R. China, ^c The Interdisciplinary Centre for Security, Reliability and Trust (Sn T), University of Luxembourg, Luxembourg, Luxembourg, ^d Department of Hepatobiliary Surgery, The First Affiliated Hospital, Xi'an Jiaotong University, Xi'an, Shanxi Province, ^e Third Department of General Surgery, The First Affiliated Hospital, School of Medicine, Shihezi University, Shihezi, Xinjiang, ^f Department of Basic Surgery, Beijing Children's Hospital, Capital Medical University, Beijing, ^g Department of Neonatal Intensive Care Unit, Northwest Women's and Children's Hospital, Xi'an, Shaanxi Province, P.R. China.

* Correspondence: Yi Lv, Department of Hepatobiliary Surgery, The First Affiliated Hospital, Xi'an Jiaotong University, No. 277, West Road, Yanta District, Xi'an, Shaanxi Province 710061, P.R. China (e-mail: liushiqi23@foxmail.com).

Copyright © 2018 the Author(s). Published by Wolters Kluwer Health, Inc. This is an open access article distributed under the terms of the Creative Commons Attribution-Non Commercial-No Derivatives License 4.0 (CCBY-NC-ND), where it is permissible to download and share the work provided it is properly cited. The work cannot be changed in any way or used commercially without permission from the journal.

Medicine (2018) 97:22(e10787)

Received: 20 December 2017 / Accepted: 17 April 2018

<http://dx.doi.org/10.1097/MD.0000000000010787>

whereas 1% with the obstruction, penetration, abscess, and/or perforation need surgical treatments.^[1–3] Perforation is mainly caused by thin, pointed objects, such as needles,^[4] toothpick,^[5] lollipop stick,^[6] fish bones,^[7] and magnetic foreign bodies.^[8] Meanwhile, foreign body ingestion in children is one of the most challenging clinical scenarios pediatric gastroenterologists face.^[9] Radiologic localization of the foreign bodies is mandatory when surgical intervention is considered. In this study, we reported the unique case of a female baby with an incarcerated hernia fistula caused by a sewing needle, which had been ingested for more than 8 days. Diagnosis and treatment were discussed with literature review.

2. Case report

Prior written and informed consent were obtained from the patient's family and the study was approved by the ethics review board of the First Affiliated Hospital, Xi'an Jiaotong University.

A 1-year, 9-month-old female child was admitted to the emergency department in our hospital for sewing needle ingestion (for more than 15 hours, without bellyache). At admission, the baseline clinical observation was stable, which was listed as follows: blood pressure (BP), 102/66 mm Hg; heart rate, 100 bpm; body temperature, 36.5°C; SpO₂, 100% on air; and respiratory rate, 26 breaths/min. Physical examination indicated that the abdomen was soft, without tenderness. Abdomen x-ray confirmed the presence of 2 resembled sewing needles as foreign bodies (3.5 cm in length) on the T12 (the stomach) and L2 levels (the proximal jejunum) (Fig. 1A and B). Interval abdomen x-ray demonstrated these 2 foreign bodies, which was slowly moving to

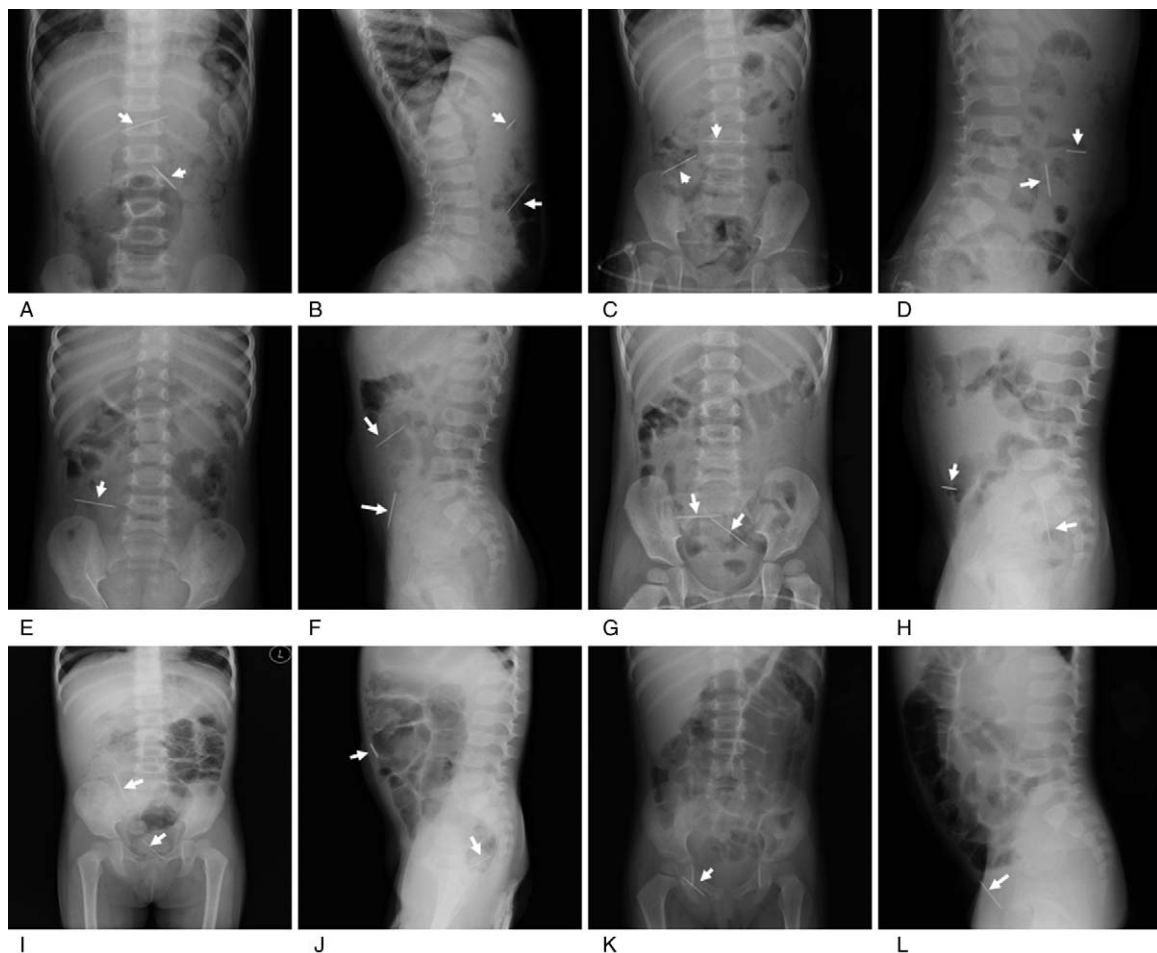


Figure 1. X-ray examination of 2 needle-like foreign bodies located in the abdomen. A,B, At 15 hours after swallowing the needles, positive (A) and side (B) x-ray showed 2 needle-like foreign bodies located at the vertebral T12 and L2 levels in the small intestine (white arrow). C,D, At 24 hours after admission, x-ray showed that the 2 needle-like foreign bodies were located at the T3 and L4–5 levels. E,F, On the 3rd days after admission, 1 needle-like foreign body was located in the vertebral right abdomen (L4–5 levels), whereas the other one was on the right side of abdomen. G,H, On the 6th days, 1 needle-like foreign body was located in the pelvis, whereas the other was near the sacrum. I,J, On the 7th day, x-ray suggested the abdominal intestinal pneumatosis, with a foreign body in the pelvic right front part (I). Lateral x-ray found 1 needle-like foreign body outside of the gut and the other in front of the coccyx (J). K, On the 8th day, x-ray showed that only 1 needle-like foreign body was positioned in the right groin area bowel hernia, and part of the foreign body was located in front of right pelvic cavity. L, On the 9th day, x-ray 1 needle-like foreign body was still positioned in the right groin area bowel hernia, and part of the foreign body was located in the hernial sac. All the x-ray confirmed that there was no free gas in the abdominal cavity.

the digestive tract distal. However, pneumoperitoneum was not observed (Fig. 1C–J). On the 8th day, one of the needle was defecated according to the abdominal radiation film (Fig. 1K), which was found in the feces. The patient did not report any clinical manifestations, such as abdominal pain, nausea, vomiting, hematochezia, or fever. In the morning on the 9th day, the body temperature was 36.5°C, and the x-ray examination found that the other needle was located outside of the gut (however, pneumoperitoneum was still not seen). The following abdominal ultrasonography confirmed that the needle perforated the intestinal wall, and was positioned in the right inguinal hernia sac (Fig. 1L). The needle was extracted by surgery uneventfully. For the exploratory surgery, transverse striation incision through the right lower abdomen was performed. Hernial sac wall edema and thickening was observed, as well as the ileocecal junction with a needle-induced perforation hole and the sewing needle incarcerated in the right inguinal hernia sac. No hematoma was present. The remote hernia sac was explored, and the end of the sewing needle was identified beneath the bottom of the hernial sac. The 3.5-cm needle shaft was held with a clamp to prevent

dislodgement and fracture (Fig. 2). The patient had an uneventful recovery, and discharged within 2 days after surgery. During the hospitalization, the female patient did not report significant

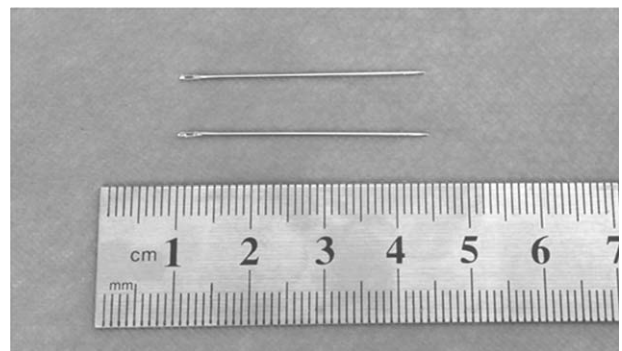


Figure 2. Two 3.5-cm sewing needles ingested during hospitalization. One needle was discharged and found in the patient's feces, whereas the other was obtained in the incarcerated inguinal hernia sac through exploratory surgery.

medical history nor took any medicine, until 1 needle pierced into the bowel wall due to the right incarcerated inguinal hernia. Laboratory examination showed the white blood cell count of $10.46 \times 10^9/L$ (with 33.7% neutrophils), hemoglobin of 116 g/L, and platelet count of $343 \times 10^9/L$. The results of the liver and renal function tests, as well as the electrolyte contents, were all within the normal limits.

From the first day of hospitalization, normal feeding was provided. The patient was discharged from the hospital on the 10th day. After discharge, the patient remained asymptomatic and grew up healthily, during the subsequent 4-year follow-up period.

3. Discussion

Foreign body ingestion is commonly seen in infants and children, especially for the age between 6 months and 3 years.^[10] Nearly 80% to 90% of the cases of ingested foreign bodies might be naturally discharged from the body without any complication.^[1,3] In general, objects wider than 2 cm could not pass through the pylorus and tend to be lodged in the stomach, whereas objects longer than 5 cm tend to be held in the duodenal sweep.^[2,11] In the 1-year, 9-month-old female baby reported herein, two 3.5-cm sewing needles passed through the duodenal sweep uneventfully.

As the sharp foreign bodies passed the duodenum, clinical radiologic monitoring had been undertaken and surgery had been indicated in case of complications, such as peritonitis, intra-abdominal abscess, digestive fistula, and hemorrhage. For the surgeons attempting to manage the needle migration, the main hazards include those inherent difficulties in seeking a small sharp object and the potential morbidity due to puncture or laceration of vessels,^[12] pancreas and spleen,^[13] and/or intrahepatic tissue.^[14]

Perforation of the small intestine caused by a foreign body in incarcerated hernia had been rarely seen.^[15] In this case, the interval x-ray indicated the moving process of these 2 sewing needles in the alimentary tract, and 1 needle perforated the intestinal wall and stayed in right inguinal hernia sac, which was a rare case.

X-ray associated with abdominal ultrasonography is extremely useful to accurately detect the radiopaque foreign bodies and the related complications. Herein, the moving ingested needles were tracked and localized using x-ray before serious complications occurred, followed by timely surgery. It is great helpful to accurately detect the radiopaque foreign bodies. Based on the basic findings of x-ray, treatment choices of endoscopic removal and surgical intervention may be attempted. Computed tomography scan is a modality method to preoperatively locate the foreign bodies, both radiopaque and radiolucent.^[16] Surgical team had been contacted to ascertain that the emergency surgery could be carried out immediately when bowel perforation was detected or abdominal pain aggravated. Intraoperative C-arm fluoroscopy is a feasible, cost-effective modality with real-time images, which could accurately detect multiple radiopaque objects disseminated throughout the digestive tract.^[17] Sharp-pointed objects can stay in human bodies for a long time period without symptoms. For this female patient, the sewing needles stayed in the body and 1 needle was discharged from the digestive tract within 8 days. It has been reported that a patient could swallow a sewing needle and suffer from no apparent symptoms, from 2 years^[18] to more than 17 years,^[19] before several episodes of recurrent abdominal pain occur.

Because the foreign body may cause the digestive tract perforation, peritonitis, and other severe complications, early surgical intervention may avoid the intra-abdominal resection and these complications. Herein, we suggest that this operation should be performed by an experienced team, which is able to deal with potential vascular or digestive system complications. In addition, it is recommended that sharp-pointed objects like needles should be removed even if the patient is asymptomatic, as the mortality and risk of perforations could increase, which might eventually lead to peritonitis, abscess,^[7] obstruction, fistulae, hemorrhage, and even death.^[13,20] In this study, the patient presented with the needle punching incarcerated intestinal and positioned in the hernia sac. Therefore, surgical intervention was the best option. There, of course, are several limitations about this study, such as the limited case size (only one case reported herein) and the lacking of the clinical treatment experience. Therefore, further in-depth studies are still needed in the future.

Meticulous preoperative monitoring of the moving process and tract of ingested needles should be mandatory for the application of x-ray examination. It is extremely useful to accurately detect these radiopaque foreign bodies. Based on the basic findings on the interval x-ray, treatment choices of endoscopic removal and/or surgical intervention may be attempted. Considering the penetrating-migrating nature of the foreign bodies, the interval x-ray not only presents a feasible, cost-effective, and quick modality to accurately detect multiple radiopaque objects disseminated throughout the digestive tract, it could also reduce the unnecessary exploration of digestive tract, subsequently preventing possible complications.

Acknowledgments

The authors are grateful to Dr. Dawei Hou, and for the technical support from the Department of Medical Radiology Center, and the Northwest Women's and Children's Hospital.

Author contributions

Conceptualization: Yi Lv.
Data curation: Jianhua Niu.
Formal analysis: Quan Xu.
Funding acquisition: Yi Lv.
Investigation: Yumei Li.
Methodology: Yajun Chen.
Project administration: Yi Lv.
Resources: Jingru Zhao.
Supervision: Qifeng Li, Dayong Wang, Ruimiao Bai.
Writing – original draft: Shiqi Liu.

References

- [1] Hsieh CH, Wang YC, Chen RJ, et al. Comparison of the clinical presentations of ingested foreign bodies requiring operative and nonoperative management. *Int Surg* 2005;90:99–102.
- [2] Anderson KL, Dean AJ. Foreign bodies in the gastrointestinal tract and anorectal emergencies. *Emerg Med Clin North Am* 2011;29:369–400.
- [3] Ginsberg GG. Management of ingested foreign objects and food bolus impactions. *Gastrointest Endosc* 1995;41:33–8.
- [4] Pratt CL, Reineke EL, Drobotz KJ. Sewing needle foreign body ingestion in dogs and cats: 65 cases (2000–2012). *J Am Vet Med Assoc* 2014;245:302–8.
- [5] Zouros E, Oikonomou D, Theoharis G, et al. Perforation of the cecum by a toothpick: report of a case and review of the literature. *J Emerg Med* 2014;47:e133–7.
- [6] Cho EA, Lee du H, Hong HJ, et al. An unusual case of duodenal perforation caused by a lollipop stick: a case report. *Clin Endosc* 2014;47:188–91.

- [7] Masoodi I, Alsayari K, Al Mohaimeed K, et al. Fish bone migration: an unusual cause of liver abscess. *BMJ Case Rep* 2012;2012:pii: bcr0920114838.
- [8] Alfonzo MJ, Baum CR. Magnetic foreign body ingestions. *Pediatr Emerg Care* 2016;32:698–702.
- [9] Kramer RE, Lerner DG, Lin T, et al. Management of ingested foreign bodies in children: a clinical report of the NASPGHAN Endoscopy Committee. *J Pediatr Gastroenterol Nutr* 2015;60:562–74.
- [10] Liu S, Li J, Lv Y. Gastrointestinal damage caused by swallowing multiple magnets. *Front Med* 2012;6:280–7.
- [11] Chang JJ, Yen CL. Endoscopic retrieval of multiple fragmented gastric bamboo chopsticks by using a flexible overtube. *World J Gastroenterol* 2004;10:769–70.
- [12] Ho AS, Morzaria S, Damrose EJ. Management of intraoral needle migration into the posterior cervical space. *Auris Nasus Larynx* 2011; 38:747–9.
- [13] Toyonaga T, Shinohara M, Miyatake E, et al. Penetration of the duodenum by an ingested needle with migration to the pancreas: report of a case. *Surg Today* 2001;31:68–71.
- [14] Dominguez S, Wildhaber BE, Spadola L, et al. Laparoscopic extraction of an intrahepatic foreign body after transduodenal migration in a child. *J Pediatr Surg* 2009;44:e17–20.
- [15] Uriupin AV, Brezhnev VP. Perforation of the small intestine by a foreign body in incarcerated hernia of the spigelian line [in Russian]. *Khirurgiia (Mosk)* 1991;128.
- [16] Takada M, Kashiwagi R, Sakane M, et al. 3D-CT diagnosis for ingested foreign bodies. *Am J Emerg Med* 2000;18:192–3.
- [17] Nasri B, Yuu K, Tada M. A case report of successful removal of multiples sewing needles in the gastrointestinal tract and pancreas using intraoperative C-arm fluoroscopy. *Int J Surg Case Rep* 2016;24:166–71.
- [18] Bulbuloglu E, Yuksel M, Kantarceken B, et al. Laparoscopic removal of a swallowed sewing needle that migrated into the greater omentum without clinical evidence. *J Laparoendosc Adv Surg Tech A* 2005; 15:66–9.
- [19] Noushif M, Sivaprasad S, Prashanth A. Abdominal foreign body: late presentation as a rectus sheath abscess. *Singapore Med J* 2011;52:e94–5.
- [20] Goh BK, Yong WS, Yeo AW. Pancreatic and hepatic abscess secondary to fish bone perforation of the duodenum. *Dig Dis Sci* 2005;50:1103–6.