

Comparison of extracranial artery stenosis and cerebral blood flow, assessed by quantitative magnetic resonance, using digital subtraction angiography as the reference standard

Jingjing Cai, MD^{a,b}, Dan Wu, MD^c, Yongqian Mo, MD^b, Anxin Wang, MD^d, Shiyu Hu, MD^b, Lijie Ren, MD^{a,b,*}

Abstract

Extracranial arteriosclerosis usually indicates a high risk of ischemic stroke. In the past, a clinical decision following diagnosis was dependent on the percentage of vessel stenosis determined by an invasive technique. We aimed to develop a quantitative magnetic resonance (QMR) technique to evaluate artery structure and cerebral hemodynamics noninvasively.

QMR and digital subtraction angiography (DSA) were performed in 67 patients with suspected cerebral vascular disease at our hospital. Accuracy, sensitivity, positive predictive values (PPVs), negative predictive values (NPVs), and Pearson correlation coefficient of QMR were calculated and compared for the detection and measurement of vascular stenoses using DSA as a gold standard. For patients with unilateral artery stenosis, quantitative cerebral blood flow (CBF) was measured by QMR in ipsilateral and contralateral hemispheres.

Among 67 subjects (male 54, female 12), 201 stenoses were detected by QMR and DSA. QMR measuring the degree of stenosis and lesion length was in good correlation with the results obtained by DSA ($r^2 = 0.845, 0.721$, respectively). As for artery stenosis, PPV and NPV of QMR were 89.55% and 95.71%, respectively. As for severe stenosis, sensitivity and specificity of QMR were 82.3% and 86.0% with DSA as a reference. For subjects with unilateral carotid stenosis, CBF in basal ganglia decreased significantly ($P < 0.001$) compared with the contralateral one in symptomatic and asymptomatic groups. For subjects with moderate stenosis (50–79%), CBF of temporal and basal ganglia was decreased compared with the contralateral ganglia. However, CBF in subjects with severe stenosis or occlusion in the basal ganglia was mildly elevated compared with the contralateral ganglia ($P < 0.001$).

In our study, a good correlation was found between QMR and DSA when measuring artery stenosis and CBF. QMR may become an important method for measuring artery stenosis and cerebral hemodynamics in the future.

Abbreviations: CBF = cerebral blood flow, CVR = cerebrovascular reserve, CE-MRA = contrast-enhanced magnetic resonance angiography, DSA = digital subtraction angiography, DSC = dynamic susceptibility contrast, DWI = diffusion-weighted imaging, FLAIR = fluid-attenuated inversion recovery, Gd-DTPA = gadolinium diethylenetriamine pentaacetic acid, MRA = magnetic resonance angiography, MRI = magnetic resonance imaging, NASCET = North American Symptomatic Carotid Endarterectomy Trial, NPV = negative predictive values, PPV = positive predictive values, QMR = quantitative magnetic resonance.

Keywords: carotid stenosis, cerebral blood flow, digital subtraction angiography, quantitative magnetic resonance

Editor: Zhonghua Sun.

Funding/support: This work was supported in part by Science and technology innovation program of Shenzhen Science and Technology Commission (JCYJ20151030151431727), Shenzhen-based research project (JCYJ20140414170821262), Guangdong Province Science and Technology Project (2013B021800102), and Shenzhen Knowledge Innovation Program (20130322131035).

The authors declare no conflict of interest in this study.

Supplemental Digital Content is available for this article.

^a Department of Neurology, The Affiliated College Shenzhen Second People's Hospital, Anhui Medical University, Hefei, Anhui province, ^b Department of Neurology, The First Affiliated Hospital of Shenzhen University, ^c Shenzhen Institutes of Advanced Technology, Chinese Academy of Sciences, Shenzhen, Guangdong Province,

^d Department of Neurology, Beijing Tiantan Hospital, Capital Medical University, Beijing, China.

* Correspondence: Lijie Ren, First Affiliated Hospital of Shenzhen University, Guangdong, China, 538000 (e-mail: 13631605966@126.com).

Copyright © 2016 the Author(s). Published by Wolters Kluwer Health, Inc. All rights reserved.

This is an open access article distributed under the terms of the Creative Commons Attribution-Non Commercial-No Derivatives License 4.0 (CCBY-NC-ND), where it is permissible to download and share the work provided it is properly cited. The work cannot be changed in any way or used commercially without permission from the journal.

Medicine (2016) 95:46(e5370)

Received: 11 August 2016 / Received in final form: 8 October 2016 / Accepted: 11 October 2016

<http://dx.doi.org/10.1097/MD.0000000000005370>

1. Introduction

Arteriosclerosis, and particularly extracranial atherosclerosis, is a major cause of ischemic cerebrovascular disease.^[1–3] Measurements of stenosis and evaluation of cerebral blood flow (CBF) are critical for the management of patients with atherosclerosis. Digital subtraction angiography (DSA) remains the gold standard for detection of artery stenosis and hemodynamic changes.^[4–7] However, DSA is an invasive, semi-quantitative, and time-consuming procedure with potential catheter-related complications.^[8,9]

Magnetic resonance imaging (MRI), an important noninvasive technique, is the preferred examination method in diagnosis of cerebral vascular diseases. Previous studies showed that magnetic resonance angiography (MRA) may over- or underestimate carotid artery stenosis compared with DSA.^[10,11] More recently, it has been reported that quantitative contrast-enhanced MRA (CE-MRA) improved the diagnostic accuracy match with DSA and that it could therefore represent an alternative imaging modality.^[12] For this reason, CE-MRA has been widely performed in clinical settings. Furthermore, as an important parameter of cerebrovascular reserve (CVR), CBF can be estimated by perfusion-weighted imaging (PWI) MRI.^[13] CBF has recently become one of powerful diagnostic tools for the assessment of artery stenosis in humans.^[14–16] A connection with stroke risk and prognosis has been demonstrated.^[17,18] Previous study has suggested that combining low-dose CE-MRA and dynamic susceptibility contrast (DSC) perfusion imaging is feasible in the evaluation without the need for additional contrast.^[19]

In this paper, we developed a concept of quantitative magnetic resonance (QMR) image platform for combining angiography and phase-contrast imaging sequences to provide anatomic visualization and blood flow measurements inside arteries, which can be used for the assessment of luminal stenosis and blood flow changes.^[20–22] In our platform, these quantitative measures of CBF^[23] and the degree of artery stenosis^[12] can be generated conveniently using a high-spatial resolution MRI.

The goal of this study was to compare the diagnostic accuracy of QMR with DSA as a gold standard. For patients with unilateral common carotid or internal carotid artery stenosis, CBF of different brain lobes was measured bilaterally to examine changes in the amount of stenosis and to explore the relationship between the symptoms and CBF in different lobes.

2. Methods

This study was a retrospective analysis conducted between January 2014 and April 2016. Sixty-seven patients suspected of having carotid atherosclerotic disease were consecutively enrolled in the study in the first affiliated hospital of Shenzhen University. All patients underwent QMR and DSA sequentially within 2 weeks; QMR imaging included CE-MRA and DSC perfusion imaging. Figure 1 describes criteria for patients' selection. The examinations were approved by the local medical ethics committee (see graph, Supplemental Content, which demonstrates the agreement of medical ethics committee, <http://links.lww.com/MD/B422>), and informed consent was obtained from each patient.

DSA was performed when QMR or carotid ultrasound would detect a severe carotid artery stenosis to determine whether the patients should undergo surgery. Exclusion criteria included patients with allergic reaction to contrast medium, severe renal insufficiency (glomerular filtration rates $30 \text{ mL/min/1.73 m}^2$), and other reasons for which QMR or DSA examination would not be well-tolerated by the patients.

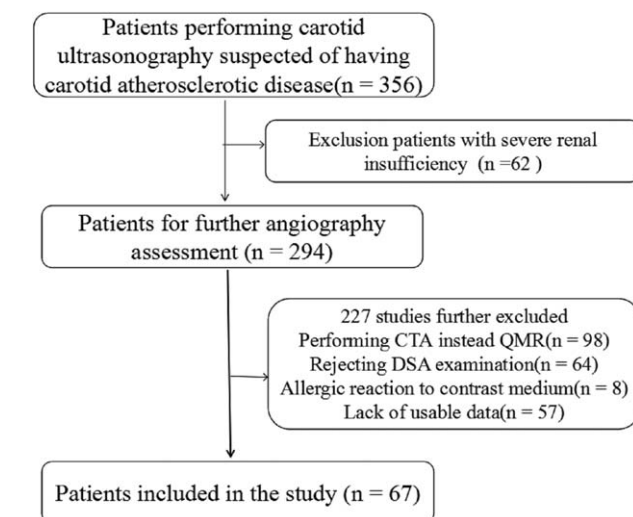


Figure 1. The flow diagram illustrating the selection of patients for the study.

Stenoses were quantified by 2 researchers in a comparable cross-sectional plane on QMR and DSA images. The degree of stenosis was graded according to the North American Symptomatic Carotid Endarterectomy Trial (NASCET) criteria^[24]: I (1–29%), mild stenosis; II (30–49%) and III (50–69%), moderate stenosis; IV (70–99%), severe stenosis; and V (100%), occlusion.

3. Image acquisition

3.1. Quantitative MRA and cerebral blood flow

All examinations were performed on a 1.5-T MR clinical system (Sonata; Siemens, Erlangen, Germany) using head-and-neck coil. All patients underwent routine MR stroke protocol, which included diffusion-weighted imaging (DWI), fluid-attenuated inversion recovery (FLAIR) sequences, PWI, CE-MRA, and DSC perfusion imaging. Contrast injection was performed in 2 phases, without the need for additional contrast. Parameters for the PWI sequence were as follows: repetition time 1410 ms, echo time 30 ms, flip angle 60°, and slice thickness 5 mm; resolution matrix 128×128 . Parameters for the CE-MRA sequence were as follows: repetition time 3.27 ms, echo time 1.18 ms, flip angle 25°, and slice thickness 1.0 mm; resolution matrix 256×192 . Gadolinium diethylenetriamine pentaacetic acid (Gd-DTPA) was used as contrast agent at a dose of 0.1 mmol/kg body weight, administered at a rate of 5 mL/s and flushed with 20 mL of saline for the CE-MRA acquisition. A modified 2-phase contrast injection scheme was used to perform CE-MRA and DSC perfusion imaging, without the need for additional contrast.

DSA imaging was performed within 14 days of the MR examination via femoral artery catheterization by using the digital subtraction technique (Axiom Artis dTA; Siemens, Germany). After inserting a catheter into the artery, 3000 to 5000 U of heparin was injected to prevent blood clotting. Iodinate was used as contrast media in our study. Images were obtained in anteroposterior, lateral, and 2 oblique projections for each catheterization.

3.2. Image evaluation

Two experienced radiologists independently rated all stenoses according to the NASCET criteria for MRA and DSA.

Table 1
Basic information of subjects.

Age, y	65 ± 8 (range 44–79)
Sex (%)	
Male	54 (80.6%)
Female	12 (19.4%)
Risk factors (%)	
Hypertension	45 (67.2%)
Hyperlipidemia	17 (25.4%)
Diabetes	21 (31.3%)
Ever smoker	11 (16.4%)
Hyperhomocysteinemia	14 (20.9%)
Ischemic heart disease	5 (7.5%)
Previous cerebral infraction	12 (17.9%)
Underlying diseases (%)	
Active cancer	4 (6.0%)
	Total: 67

Afterwards, 3 researchers (Jingjing Cai, Dan Wu, and Yongqian Mo) revised their ratings and decided on the grades of stenosis using a consensus approach. The researcher of the index tests and reference standard were blinded to the results of QMR and DSA and patients' basic information. Per-patient and per-vessel stenosis were the maximal stenoses identified in all segments or in all segments within a vessel vicinity, respectively.

3.3. Statistical analyses

Data were analyzed using the software Statistical Package for the Social Sciences (SPSS, version 12.0, Inc., Chicago, IL, USA). Grading of luminal narrowing was compared with DSA as a gold standard. Correlation between QMR and DSA for the assessment of vascular stenosis was calculated using Pearson correlation

coefficient. Histograms are used to describe CBF in different lobes for different degrees of stenosis, with or without symptoms. The difference of CBF between the side affected by stenosis and contralateral side was calculated by subtraction ($\Delta\text{CBF} = \text{lesion side} - \text{healthy side}$). $P < 0.05$ was considered statistically significant.

4. Results

Sixty-seven patients (male 54, female 12) from the first affiliated hospital of Shenzhen University were enrolled from January 2014 and April 2016, and 201 stenoses were detected by QMR and DSA. No motion artifacts affected QMR image quality. The mean age of subjects was 65 ± 8 years ranging from 44 to 79 years. No QMR- and DSA-related adverse events were recorded. Factors associated with artery atherosclerosis were listed in Table 1: 67.2% of the patients had hypertension and 31.3% had diabetes. Table 2 summarizes the grade of stenosis measured with QMR and DSA. Thirty-three regions of carotid artery were false-positive, and 21 parts were false-negative. Negative predictive values (NPVs) were of 95.71% and positive predictive values (PPVs) were of 89.55%. Overall, false positive rate of QMR was higher than false negative rate. Overestimation occurred in 14 arteries with QMR in which 10 were moderate stenosis (30–69%). In 4 cases of congenital vertebral artery slim, QMR reported moderate to severe stenosis.

Table 3 lists the stenosis section and degree in stenosis of the artery verified by DSA. Left-side stenosis occurrence rate was slightly higher than the right (55.4% vs 44.6%). In the carotid artery system, internal carotid artery stenosis accounted for 44.1%, which was significantly higher than in other regions. For the measured carotid stenosis degree, scatter plots were drawn to reflect the correlation between QMR and DSA after removing the

Table 2
Comparison of the degree of stenosis with QMR and DSA.

Stenosis degree on QMR	Stenosis degree on DSA					
	Normal	1–29%	30–49%	50–69%	70–99%	100%
Normal	469	3	5	6	7	0
1–29%	12	7	1	0	0	0
30–49%	9	4	6	3	1	0
50–69%	9	0	8	19	6	0
70–99%	3	0	1	11	55	3
100%	0	0	0	0	0	17

DSA = digital subtraction angiography, QMR = quantitative magnetic resonance.

Table 3
Stenosis section and degree on DSA.

Section	Stenosis degree on DSA					Total
	1–29%	30–49%	50–69%	70–99%	100%	
Left CCA	0	2	6	8	1	17
Left ICA	2	5	6	21	5	39
Left ECA	0	1	1	2	0	4
Left VA	5	1	4	8	1	19
Left SA	1	2	5	4	2	14
Right CCA	0	3	2	4	0	9
Right ICA	1	4	10	15	5	35
Right ECA	0	1	0	1	1	3
Right VA	5	4	4	6	5	24
Right SA	0	0	1	3	0	4
Total	14	23	39	72	20	168

CCA = common carotid artery, ECA = external carotid artery, ICA = internal carotid artery

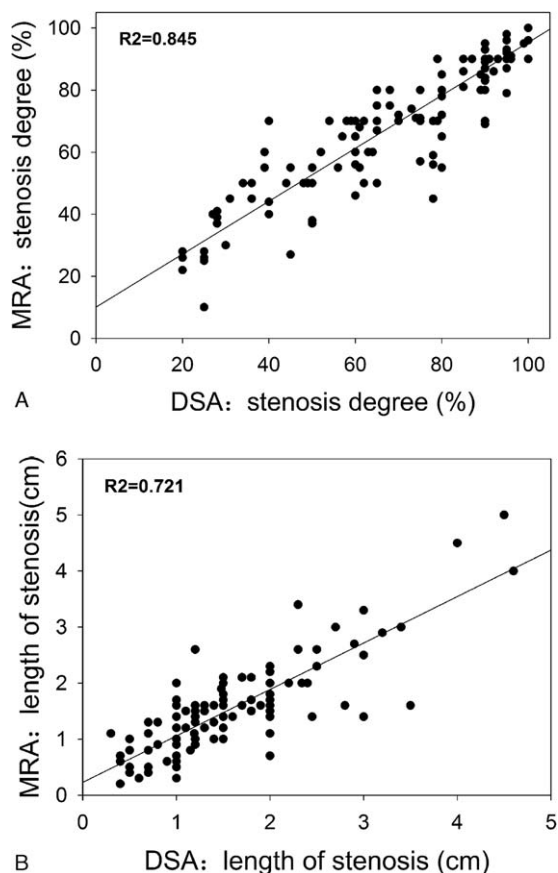


Figure 2. Linear regression of CE-MRA and DSA for the stenosis measurement.

false positive and negative results. As shown in Fig. 2A, good correlation was observed between QMR and DSA ($r^2=0.845$). Figure 2B shows good correlation between QMR and DSA in the length of stenosis, as $r^2=0.721$. Sensitivity and specificity of QMR for detecting severe stenosis was 82.3% and 86.0% with DSA as a 100% reference.

The study included 37 patients with unilateral common carotid artery or internal carotid artery stenosis, regardless of the vertebral artery lesions. For these 37 patients, we conducted further analysis of CBF using QMR. In symptomatic group, CBF in frontal, parietal, temporal, and basal ganglia were reduced (Fig. 3). Besides, parietal lobes show the most obvious decrease in 4 brain areas and the lowest reduction in the basal ganglia. As compared with asymptomatic group, there was a significant decrease in CBF in temporal and basal ganglia in the symptomatic group.

To investigate the correlation between the degree of stenosis and Δ CBF, all subjects were divided into 4 groups: Group 1, 1% to 49%, Group 2, 50% to 69%, Group 3, 70% to 99%, and Group 4, 100% (Fig. 4). Group 1 included only 2 subjects, and bar charts show that Δ CBF were quite different among brain lobes. For patients with moderate stenosis (50–79%), CBF of ipsilateral frontal lobe was higher than in the contralateral one. However, CBF of parietal, temporal lobes, and basal ganglia was decreased in the ipsilateral side, especially in the basal ganglia. In Group 3 and Group 4, CBF in the ipsilateral hemisphere was reduced in the frontal lobe, parietal lobe, and temporal lobe, while mildly elevated in the basal ganglia.

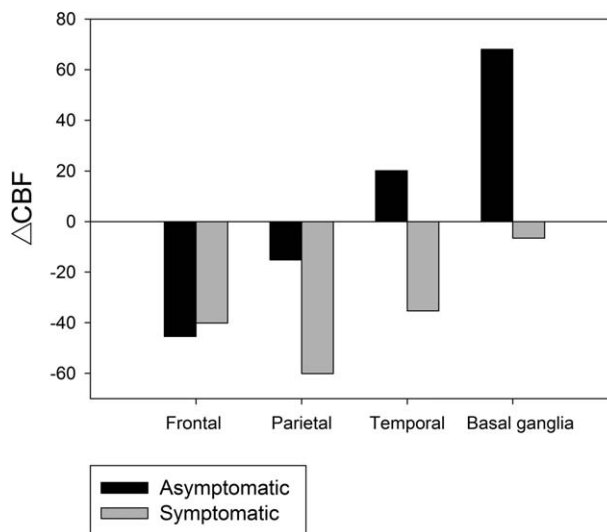


Figure 3. Comparison of Δ CBF between symptomatic and asymptomatic groups.

5. Discussion

Accurate evaluation of artery stenosis and CBF is essential for guiding clinical treatment. This study suggests that QMR is as accurate and consistent as DSA in measuring artery stenosis. The study presents 3 main findings. First, QMR had a strongest correlation with DSA in the degree and length of stenosis ($r^2=0.845, 0.721$, respectively). Sensitivity and specificity of QMR for detecting severe stenosis was 82.3% and 86.0% with reference to DSA. Second, patients with symptoms had significantly decreased CBF in temporal and basal ganglia. Third, CBF of patients with moderate stenosis (50–79%) in parietal, temporal lobes, and basal ganglia were decreased, while in patients with severe stenosis or occlusion, CBF was mildly elevated in the basal ganglia.

Although DSA is still considered as the gold standard for the evaluation of artery stenosis, there are some limitations to this

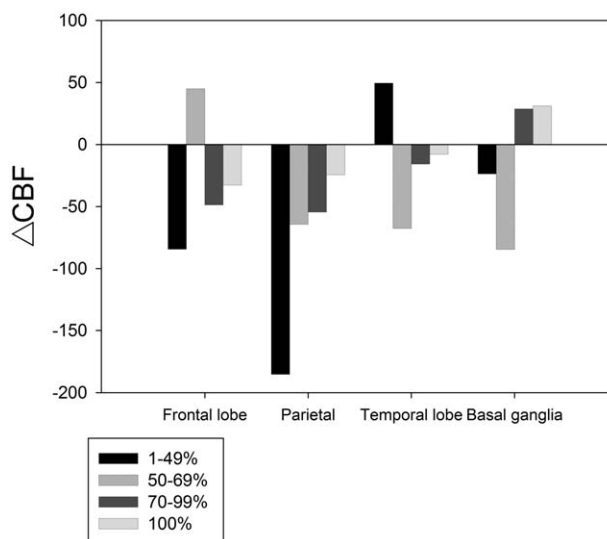


Figure 4. Comparison of Δ CBF between different grades of stenosis.

methodology such as invasiveness that are not easily accepted by patients. Noninvasive imaging techniques such as computed tomography (CT) and MRI have gradually replaced DSA for the diagnosis of carotid artery stenosis. Previously, use of CE-MRA was limited and performed in routine stroke protocols because of its relatively lower spatial resolution and the need for an extra contrast dose. In the last few years, CE-MRA has become required simultaneously to the contrast used for DSC perfusion imaging.^[19] With the introduction of new magnetic resonance technology, the speed and spatial resolution of CE-MRA have significantly improved.^[25,26]

In our study, we found that CE-MRA and DSA have a similar efficiency in detecting artery stenosis. Besides, our study confirmed that combining CE-MRA and PWI is feasible and presents no need for additional contrast. Related studies have shown that, compared with other measurements used to measure artery stenosis such as DSA, CT angiography, and ultrasound, QMR angiography provides noninvasive and accurate measurement of all extracranial vessels without exposure to radiotracers.^[27,28]

CBF can be measured by a number of imaging techniques, including CT perfusion imaging and PWI. Different imaging techniques have their own advantages and disadvantages.^[29] MRI has been widely used in measuring CBF, and commonly used applications of this technique comprise PWI, blood oxygen level dependent imaging, and phase-contrast MR angiography. MRI is a nonradioactive detection technique capable of detecting acute ischemic lesions and providing morphological and hemodynamic information.^[30] Because of this, an increasing number of medical doctors prefer it to QMR when examining patients with extracranial artery stenosis. PWI is an important MRI for detecting cerebral hemodynamics changes, and it has been widely used in clinical practice. In our study, CBF was measured by PWI in different lobes of the brain.

Previous studies indicated that CVR may be a more accurate predictor of stroke than degree of internal carotid artery or middle cerebral artery stenosis.^[31,32] Liu and Zhou^[32] found that the impairment of CVR rather than severe stenosis was associated with a higher risk of stroke, as the odds ratio in the first case was 1.70. Moreover, a link between impaired CBF and prognosis of ischemic stroke has been shown.^[17] The results of a previous study demonstrated that embolism formation is positively correlated to the stability of the plaque rather than to the degree of stenosis.^[33] Consequently, identification of patients with a high risk of stroke and with poor CBF may be useful to guide the treatment decision making.

In our study, the difference value of CBF in bilateral lobes showed nonlinear correlation with the degree of stenosis. We found that patients with severe artery stenosis can maintain CBF at a certain level. Two potential mechanisms may be involved in regulating CBF. On the one hand, as the formation of artery stenosis is a chronic process, the patients with severe stenosis have plenty of time to establish collateral circulation in the case their body is in good condition. On the other hand, adjustment of CBF in different lobes is a dynamic process, so that our body preferentially retains the flow in the regions that are important to preserving vital functions. The results of our study show that CBF of frontal and parietal lobes in patients with severe stenosis decreases significantly.

Our study has several limitations. First, the sample size was relatively small. Further study including a larger sample on patients with different degrees of artery stenosis is therefore needed. Second, although all images were performed on a 1.5-T MR clinical system, more advanced equipment has been used in other studies. Therefore, it is possible that the diagnostic accuracy of QMR

will be higher using more advanced scanners. Finally, DSA is considered when moderate to severe vascular disease is diagnosed or when selection of interventional surgery is being considered. The subjects included in our study had relatively severe lesions, which rendered us unable to assess mild stenosis accurately.

6. Conclusions

This study showed good correlation between QMR and DSA in measuring artery stenosis and CBF. Patients with symptoms had a significantly decreased CBF in temporal and basal ganglia. CBF of patients with moderate stenosis in parietal, temporal, and basal ganglia was also decreased, while in patients with severe stenosis or occlusion, CBF was mildly elevated in the basal ganglia. QMR may represent an important method for measuring artery stenosis and cerebral hemodynamics in the future.

References

- Inzitari D, Eliasziw M, Gates P, et al. The causes and risk of stroke in patients with asymptomatic internal-carotid-artery stenosis. North American Symptomatic Carotid Endarterectomy Trial Collaborators. *N Engl J Med* 2000;342:1693–700.
- Barnett HJ, Gunton RW, Eliasziw M, et al. Causes and severity of ischemic stroke in patients with internal carotid artery stenosis. *JAMA* 2000;283:1429–36.
- Chaturvedi S, Bruno A, Feasby T, et al. Carotid endarterectomy: an evidence-based review: report of the Therapeutics and Technology Assessment Subcommittee of the American Academy of Neurology. *Neurology* 2005;65:794–801.
- Sheth SA, Liebeskind DS. Imaging evaluation of collaterals in the brain: physiology and clinical translation. *Curr Radiol Rep* 2014;2:29.
- North American Symptomatic Carotid Endarterectomy Trial CBeneficial effect of carotid endarterectomy in symptomatic patients with high-grade carotid stenosis. *N Engl J Med* 1991;325:445–53.
- Executive Committee for the Asymptomatic Carotid Atherosclerosis Study Endarterectomy for asymptomatic carotid artery stenosis. *JAMA* 1995;273:1421–8.
- Hobson RW 2nd, Weiss DG, Fields WS, et al. Efficacy of carotid endarterectomy for asymptomatic carotid stenosis. The Veterans Affairs Cooperative Study Group. *N Engl J Med* 1993;328:221–7.
- Dawkins AA, Evans AL, Wattam J, et al. Complications of cerebral angiography: a prospective analysis of 2,924 consecutive procedures. *Neuroradiology* 2007;49:753–9.
- Willinsky RA, Taylor SM, TerBrugge K, et al. Neurologic complications of cerebral angiography: prospective analysis of 2,899 procedures and review of the literature. *Radiology* 2003;227:522–8.
- Fellner C, Lang W, Janka R, et al. Magnetic resonance angiography of the carotid arteries using three different techniques: accuracy compared with intraarterial x-ray angiography and endarterectomy specimens. *J Magn Reson Imaging* 2005;21:424–31.
- Clevert DA, Johnson T, Michael H, et al. High-grade stenoses of the internal carotid artery: comparison of high-resolution contrast enhanced 3D MRA, duplex sonography and power Doppler imaging. *Eur J Radiol* 2006;60:379–86.
- Attenberger UI, Haneder S, Morelli JN, et al. Peripheral arterial occlusive disease: evaluation of a high spatial and temporal resolution 3-T MR protocol with a low total dose of gadolinium versus conventional angiography. *Radiology* 2010;257:879–87.
- Warach S, Chien D, Li W, et al. Fast magnetic resonance diffusion-weighted imaging of acute human stroke. *Neurology* 1992;42:1717–23.
- Muller M, van der Graaf Y, Visseren FL, et al. Hypertension and longitudinal changes in cerebral blood flow: the SMART-MR study. *Ann Neurol* 2012;71:825–33.
- Jennings JR, Heim AF, Kuan DC, et al. Use of total cerebral blood flow as an imaging biomarker of known cardiovascular risks. *Stroke* 2013;44:2480–5.
- Pase MP, Grima NA, Stough CK, et al. Cardiovascular disease risk and cerebral blood flow velocity. *Stroke* 2012;43:2803–5.
- Park SA, Park HL, Kim D, et al. The prediction of gross motor outcome using cerebrovascular reserve measured by acetazolamide-challenged SPECT. *NeuroRehabilitation* 2012;30:359–67.

- [18] Yonas H, Smith HA, Durham SR, et al. Increased stroke risk predicted by compromised cerebral blood flow reactivity. *J Neurosurg* 1993;79:483–9.
- [19] Nael K, Meshksar A, Ellingson B, et al. Combined low-dose contrast-enhanced MR angiography and perfusion for acute ischemic stroke at 3T: a more efficient stroke protocol. *AJNR Am J Neuroradiol* 2014;35:1078–84.
- [20] Anzidei M, Napoli A, Geiger D, et al. Preliminary experience with MRA in evaluating the degree of carotid stenosis and plaque morphology using high-resolution sequences after gadofosveset trisodium (Vasovist) administration: comparison with CTA and DSA. *La Radiol Med* 2010;115:634–47.
- [21] Bahr-Hosseini M, Shakur SF, Amin-Hanjani S, et al. Angiographic correlates of cerebral hemodynamic changes with Diamox challenge assessed by quantitative magnetic resonance angiography. *Stroke* 2016;47:1658–60.
- [22] Amin-Hanjani S, Du X, Zhao M, et al. Use of quantitative magnetic resonance angiography to stratify stroke risk in symptomatic verte-brobasilar disease. *Stroke* 2005;36:1140–5.
- [23] Zhao M, Amin-Hanjani S, Ruland S, et al. Regional cerebral blood flow using quantitative MR angiography. *AJNR Am J Neuroradiol* 2007;28:1470–3.
- [24] North American Symptomatic Carotid Endarterectomy Trial Methods, patient characteristics, and progress. *Stroke* 1991;22:711–20.
- [25] Phan T, Huston J 3rd, Bernstein MA, et al. Contrast-enhanced magnetic resonance angiography of the cervical vessels: experience with 422 patients. *Stroke* 2001;32:2282–6.
- [26] Tomasian A, Salamon N, Lohan DG, et al. Supraaortic arteries: contrast material dose reduction at 3.0-T high-spatial-resolution MR angiography: feasibility study. *Radiology* 2008;249:980–90.
- [27] Friese S, Klose U, Kastrup A, et al. [Enhanced MR-angiography (CE-MRA) of the supraaortic arteries: dose reduction with a contrast agent of high relaxivity (Gd-BOPTA)]. *RoFo* 2003;175:1363–7.
- [28] Anzalone N, Scomazzoni F, Castellano R, et al. Carotid artery stenosis: intraindividual correlations of 3D time-of-flight MR angiography, contrast-enhanced MR angiography, conventional DSA, and rotational angiography for detection and grading. *Radiology* 2005;236:204–13.
- [29] Latchaw RE, Yonas H, Hunter GJ, et al. Guidelines and recommendations for perfusion imaging in cerebral ischemia: a scientific statement for healthcare professionals by the writing group on perfusion imaging, from the Council on Cardiovascular Radiology of the American Heart Association. *Stroke* 2003;34:1084–104.
- [30] MacDonald ME, Frayne R. Cerebrovascular MRI: a review of state-of-the-art approaches, methods and techniques. *NMR Biomed* 2015;28:767–91.
- [31] Gupta A, Chazen JL, Hartman M, et al. Cerebrovascular reserve and stroke risk in patients with carotid stenosis or occlusion: a systematic review and meta-analysis. *Stroke* 2012;43:2884–91.
- [32] Liu M, Zhou L. Cerebrovascular reserve may be a more accurate predictor of stroke than degree of ICA or MCA stenosis. *Med Sci Monit* 2014;20:2082–7.
- [33] Freilinger TM, Schindler A, Schmidt C, et al. Prevalence of nonstenosing, complicated atherosclerotic plaques in cryptogenic stroke. *JACC Cardiovasc Imaging* 2012;5:397–405.