



Case report

Non-convulsive seizure clustering misdiagnosed as vertebrobasilar insufficiency

Yu-Shiue Chen^{a,1}, Tsang-Shan Chen^{b,1}, Chin-Wei Huang^{a,*}^a Department of Neurology, National Cheng Kung University Hospital, College of Medicine, National Cheng Kung University, Tainan, Taiwan^b Department of Neurology, Tainan Sin-Lau Hospital, Tainan, Taiwan

ARTICLE INFO

Keywords:

Neurology
 Neuroscience nervous system
 Internal medicine
 Clinical research
 Nonconvulsive seizure
 Vertebrobasilar insufficiency
 Seizure

ABSTRACT

Diagnosing non-convulsive seizures (NCSs) is a great challenge for most clinicians due to a wide spectrum of clinical presentations. The complexity of the disease course usually results in a delayed diagnosis or misdiagnosis so that timely and appropriate treatment is not given. Herein, we report a case with NCSs misdiagnosed as vertebrobasilar insufficiency (VBI), in which the patient suffered from episodes of prominent dizziness, vertigo, becoming transfixed, and worsening response within a day. Brain magnetic resonance image findings were unremarkable, however electroencephalography (EEG) showed rhythmic epileptiform discharges that appeared to originate from the right frontal area with ipsilateral hemispheric involvement. We prescribed intravenous valproate and the seizures ceased. Few studies have reported a patient with NCS misdiagnosed with VBI, a very different entity. It is thus important that clinicians should be aware of the trivial symptoms of NCSs, and to consider implementing early EEG studies and anti-epileptic drug therapy.

1. Introduction

Making a clinical diagnosis of non-convulsive seizures (NCSs) is challenging, mostly because of the lack of prominent physical signs and symptoms [1, 2]. It is a serious but treatable condition in which early detection is the key to preserve viable neurons during seizure activity [3]. The clinical presentation of NCSs varies, and the clues may be in plain sight. Non-convulsive status epilepticus (NCSE) is one of the associated causes of death among all disease in acute conditions. Devastating consequences occur if the condition remains untreated. Without immediate treatment, NCSs may evolve into NCSE which ultimately lead to death [4]. A retrospective study showed 27% mortality rate from NCSE in acute medical group, which was significantly higher than that of the epilepsy and cryptogenic group [5]. The necessity of timely diagnosis and continuous electroencephalography (EEG) monitoring improves the clinical practice. Herein, we report an unusual case of NCSs misdiagnosed as vertebrobasilar insufficiency (VBI).

2. Case report

A 67-year-old male with a past medical history of hypertension and coronary artery disease presented at our emergency department (ED)

with episodes of prominent dizziness, vertigo, intermittent left arm shaking, and bouts of dull response that occurred while playing Mah-Jong with his friends. He had a high blood pressure of 200/110 mmHg at triage, when episodic transfixed status was also noted. The duration of each episode was about 5 min. During the attacks, he was unable to think but he was partially aware of what was happening. There was no accompanying extraocular movement deviation, trismus, or incontinence. He was diagnosed with VBI at the ED. He had no prior history of seizures.

The basic laboratory data at the ED were within normal limits, and a neurological examination was unremarkable except for the presence of a dull response during the events. There were no focal brainstem signs, left-right disorientation, dyslexia, dysgraphia, or finger agnosia. *Brain magnetic resonance imaging* (MRI) revealed non-specific white matter changes with no signal alterations in the posterior circulation or brainstem. Intravenous hydration and anti-platelet therapy were administered.

Beside video-electroencephalography (EEG) recording was then arranged because the attacks recurred more than 10 times a day even with hydration and anti-platelet therapy. Seizures could not be excluded. The EEG showed rhythmic epileptiform discharges originating from the right frontal area with ipsilateral hemispheric spreading and relatively limited homologous contralateral involvement (Figure 1).

* Corresponding author.

E-mail address: huangcw@mail.ncku.edu.tw (C.-W. Huang).¹ Yu-Shiue Chen and Tsang-Shan Chen contributed equally to this work.

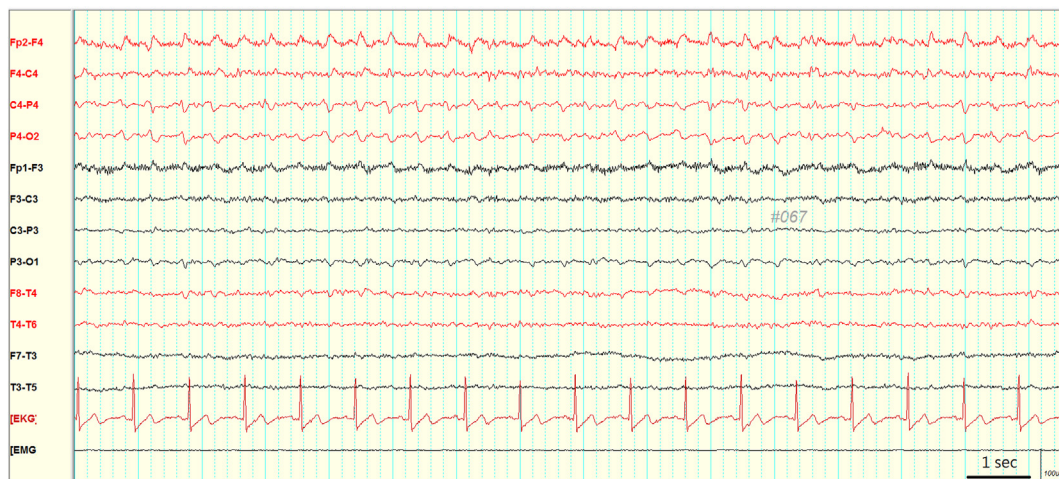


Figure 1. Right hemispheric rhythmic activities, maximally frontal area, appeared in a quasi-periodic fashion at intervals of about one second, during which the patient presented significant dizziness, vertigo and dull response.

Under the diagnosis of NCSs he was given intravenous valproate, and the frequency of seizures markedly decreased. He was eventually seizure-free and discharged under oral valproate treatment. No further episodes of seizures occurred during 24 months of follow-up.

The patient was informed about the writing of the case report without sharing patient identification information. We have obtained informed consent from this patient.

3. Discussion

It is uncommon to encounter a patient with NCSs presenting as VBI. The clinical symptoms of VBI include dizziness, vertigo, headache, visual disturbance (such as diplopia), dysarthria, dysphagia, ataxia, gait imbalance, and drop attack [6, 7]. The most common symptoms are dizziness, vertigo and visual disturbance. Due to its transient nature, negative findings in neurological examinations do not necessarily exclude other dangerous etiologies, such as NCSs in our case.

This patient was reported to have initial intermittent left arm shaking. Although it was not persistently observed by the clinician, it is relatively unusual for VBI, and indeed possible to be related to a partial seizure. Furthermore, the attacks attributed to seizures were typically more often than VBI. It is thus important to specifically raise the suspicion of a partial seizure during the first approach during history taking in this patient at the ED.

Patients with VBI may present with low blood pressure, and blood pressure usually rises during a seizure. It may be another clue for suspicion of an etiology other than VBI, along with the other atypical manifestations. Meanwhile, in this patient, the higher blood pressure at ED also mandates a good evaluation of medical adherence and baseline blood pressure status.

Making a differential diagnosis of NCSs is challenging due to the lack of obvious physical symptoms. NCSs, or NCSE, typically presents with subtle motor signs, changes in consciousness, psycho-behavioral changes, speech disorders, catatonia or autonomic dysfunction [8, 9]. The diagnosis demands confirmation from continuous EEG monitoring [10], in addition to brain MRI and diffusion weighted imaging (DWI), which is considered the most reliable sequence for early detection of cerebral infarct [11], to exclude acute vascular insults, as demonstrated in our case. Whether more advanced imaging such as arterial spin labeling can identify the area of hypoperfusion during NCS and be helpful in early diagnosis of NCS is worth further study [12]. It has also been reported that reversible changes in perfusion imaging and DWI in a

patient with NCS [13]. The integration of these advanced modalities is important in early diagnosis of NCS.

The epileptiform discharges of the right frontal lobe could result in convulsion of the left limbs, probably involving the motor area. The EEG findings and the clinical presentation in our case were essentially compatible. Of note, our patient had initial prominent dizziness and vertigo. Partial seizures can present as vestibular symptoms or so-called epileptic vertigo and dizziness (EVD). Penfield and Kristiansen reported that epileptic discharges in the superior temporal gyrus and temporo-parietal cortex were associated with vertigo [14], and later studies have suggested that the temporal lobe [15, 16], temporo parieto-occipital junction [17], parietal lobe [18], frontal lobe [19], and precuneus [20] may also be involved. Epileptiform discharges originating from the right hemisphere, mainly frontal area were noted in our case, which is uncommon in epilepsy presenting with vestibular symptoms. A recent systematic review showed that almost 80% of seizure activity in patients with EVD occurred in the temporal lobe, with 12% in the parietal lobe and 3% in the frontal lobe [21]. The lateralization in our case is in keeping with the hypothesis that the right hemisphere is usually related to EVD, as the right side plays a major role in visuospatial orientation [22]. Moreover, the spread of epileptiform discharges in our case may have altered the widespread vestibular multisensory cortical network so that vestibular symptoms occurred [23] while the patient remained aware.

EEG is extremely useful in the setting of impaired consciousness, confusional state or cognitive disorders and the only available tool able to validate the diagnosis of NCS [24]. It is irreplaceable in the diagnosis and management of certain pathologies involving the cerebral cortex. However, Patient-specific algorithms can further improve sensitivity and specificity but need parameter adjustments and training for individual patients. Furthermore, the limitation of scalp-EEG at the current stage cannot replace continuous supervision of patients and complete visual review of the acquired data by specially trained personnel [25].

In conclusion, clinicians should always suspect NCSs whenever a patient has the sudden onset of central nervous system symptoms with no identifiable etiology, especially those with an episodic and repetitive nature and unremarkable MRI findings.

Declarations

Author contribution statement

All authors listed have significantly contributed to the investigation, development and writing of this article.

Funding statement

This work was supported by Ministry of Science and Technology, Taiwan (107-2314-B-006-018-, 107-2320-B-006-019-, 108-2320-B-006-023-, 109-2314-B-006 -034 -MY3) and National Cheng Kung University Hospital (20180254, 20190160).

Declaration of interests statement

The authors declare no conflict of interest.

Additional information

No additional information is available for this paper.

References

- [1] T. Lawson, S. Yeager, Status epilepticus in adults: a review of diagnosis and treatment, *Crit. Care Nurse* 36 (2016) 62–73.
- [2] Y.R. Aldana, B. Hunyadi, E.J.M. Reyes, et al., Nonconvulsive epileptic seizure detection in scalp EEG using multiway data analysis, *IEEE J. Biomed. Health Inform.* 23 (2018) 660–671.
- [3] S. Zehtabchi, K. Yadav, D. Nishijima, et al., 297 utility of a brief EEG training module on improving emergency physicians' ability to identify nonconvulsive seizure, *Ann. Emerg. Med.* 70 (2017) S117.
- [4] R. Maganti, P. Gerber, C. Drees, et al., Nonconvulsive status epilepticus, *Epilepsy Behav.* 12 (2008) 572–586.
- [5] B.F. Shneker, N.B. Fountain, Assessment of acute morbidity and mortality in nonconvulsive status epilepticus, *Neurology* 61 (2003) 1066–1073.
- [6] A.C.L. Neto, R. Bittar, G.S. Gattas, et al., Pathophysiology and diagnosis of vertebrobasilar insufficiency: a review of the literature, *Int. Arch. Otorhinolaryngol.* 21 (2017) 302–307.
- [7] S.I. Savitz, L.R. Caplan, Vertebrobasilar disease, *N. Engl. J. Med.* 352 (2015) 2618–2626.
- [8] H. Meierkord, M. Holtkamp, Non-convulsive status epilepticus in adults: clinical forms and treatment, *Lancet Neurol.* 6 (2017) 329–339.
- [9] A.M. Husain, G.J. Horn, M.P. Jacobson, Non-convulsive status epilepticus: usefulness of clinical features in selecting patients for urgent EEG, *J. Neurol. Neurosurg. Psychiatry* 74 (2003) 189–191.
- [10] A.M. Husain, Treatment of recurrent electrographic nonconvulsive seizures (TRENDS) study, *Epilepsia* 54 (2013) 84–88.
- [11] A.A. Abdelrasoul, N.A. Elsebaie, O.A. Gamaleldin, et al., Imaging of brain infarctions: beyond the usual territories, *J. Comput. Assist. Tomogr.* 43 (2019) 443–451.
- [12] A.A.K. Abdel Razek, M. Talaat, L. El-Serougy, et al., Clinical applications of arterial spin labeling in brain tumors, *J. Comput. Assist. Tomogr.* 43 (2019) 525–532.
- [13] S. Flacke, U. Wüllner, E. Keller, et al., Reversible changes in echo planar perfusion- and diffusion-weighted MRI in status epilepticus, *Neuroradiology* 42 (2000) 92–95.
- [14] W. Penfield, K. Kristiansen, *Epileptic Seizure Patterns*, Springfield, Illinois, 1951.
- [15] M. Dieterich, T. Brandt, Functional brain imaging of peripheral and central vestibular disorders, *Brain* 131 (2008) 2538–2552.
- [16] S. Hegemann, S. Fitzek, C. Fitzek, et al., Cortical vestibular representation in the superior temporal gyrus, *J. Vestib. Res.* 14 (2004) 33–35.
- [17] C. Barba, G. Barbati, L. Minotti, et al., Ictal clinical and scalp-EEG finding differentiating temporal lobe epilepsies from temporal 'plus' epilepsies, *Brain* 130 (2007) 1957–1967.
- [18] F. Bartolomei, M. Gavaret, R. Hewett, et al., Neural networks underlying parietal lobe seizures: a quantified Study from intracerebral recordings, *Epilepsy Res.* 93 (2011) 164–176.
- [19] S.A. Hamed, A.M. Tohamy, A.M. Oseilly, Vestibular function in adults with epilepsy of unknown etiology, *Otol. Neurotol.* 38 (2017) 1217–1224.
- [20] Y. Yang, H. Wang, W. Zhou, et al., Electroclinical characteristics of seizures arising from the precuneus based on stereoelectroencephalography (SEEG), *BMC Neurol.* 18 (2018) 110.
- [21] A.A. Taruntzer, S. Lee, K.A. Robinson, et al., Clinical and electrographic findings in epileptic vertigo and dizziness, *Neurology* 84 (2015) 1595–1604.
- [22] R. Hewett, M. Guye, M. Gavaret, et al., Benign temporo-parieto-occipital junction epilepsy with vestibular disturbance: an underrecognized form of epilepsy? *Epilepsy Behav.* 21 (2011) 412–416.
- [23] C. Lopez, O. Blanke, The thalamocortical vestibular System in animals and humans, *Brain Res. Rev.* 67 (2011) 119–146.
- [24] S.D. Rosenberg, B. Périn, V. Michel, et al., EEG in adults in the laboratory or at the patient's bedside, *Neurophysiol. Clin.* 45 (2015) 19–37.
- [25] C. Baumgartner, J.P. Koren, Seizure detection using scalp-EEG, *Epilepsia* 59 (2018) s14–22.