

## Penetration of Bromelain in Serum and Rhinosinusal Mucosa in Patients Undergoing Endoscopic Sinus Surgery

Sir,

The objective of our research was to find the concentration of bromelain in rhinosinusal mucosa of patients with chronic rhinosinusitis (Group A) and of individuals without nasal or paranasal diseases (Group B). Forty patients (twenty patients and twenty controls) were enrolled in the study. Bromelain 500 mg tablet twice daily was administered for 30 days. We ranked the presence of bromelain in turbinate and ethmoid mucosae by immunohistochemistry, and the concentration of bromelain in serum was measured by Western blot analysis. Bromelain taken by mouth has an excellent distribution from blood to rhinosinusal mucosa of both groups.

Bromelain is extracted from the fruit or stem of pineapples (*Ananas comosus*). It is a mixture of several compounds, including large amount of proteolytic enzymes. Many reports show that bromelain could be useful in the treatment of several disorders characterized by chronic inflammation or autoimmune diseases.<sup>[1]</sup> Due to its powerful anti-inflammatory and analgesic characteristics, it is useful in the treatment of patients with osteoarthritis and rheumatoid arthritis.<sup>[2]</sup> Recently, *in vitro* experiments demonstrated the capacity to modulate the immune system too.

It was observed that bromelain does more than masking the primary immune response by reducing allergic sensitization; it also modulates T-cells, macrophages, and natural killer cell activities, increasing the interleukin (IL)-1  $\beta$ , IL-6, and tumor necrosis factor- $\alpha$  secretion by mononuclear cells.<sup>[3]</sup> The objective of the current study was to analyze the quantity of bromelain in rhinosinusal mucosa of patients with chronic rhinosinusitis (CRS) (Group A) and individuals without nasal and paranasal pathology (Group B).

Twenty patients (13 males, 7 females; age range: 22–77 years) with CRS diagnosed according to the “International Consensus Statement on Allergy and Rhinology”<sup>[4]</sup> and EPOS criteria<sup>[5]</sup> were enrolled as Group A while twenty patients (9 males, 11 females; age range: 26–64 years) without rhinosinusal problems were enrolled as Group B.

CRS in adults is defined as sinonasal inflammation persisting for >12 weeks. CRS in adults is characterized by nasal obstruction/congestion/blockage, anterior or posterior nasal mucopurulent, facial pain/pressure/fullness, and decreased/loss of sense of smell. Symptoms must be accompanied by objective findings including positive nasal endoscopy (purulence, edema) or positive imaging findings such as inflammation or mucosal changes within the sinuses. Hence, paranasal sinuses were studied with a computed tomography scan. The severity

of sinus mucosal inflammation was scored, according to Lund–Mackay staging system,<sup>[6]</sup> as 0 (sinus complete lucency), 1 (partial lucency), or 2 (complete opacity). All patients of Group A belonged to Lund–Mackay score grade 2.

The work was done in collaboration with ENT Department of Carol Davila University of Bucharest. Bromelain 500 mg tablet twice daily was administered by mouth for 30 days.

The study was performed in accordance with the good clinical practice guidelines and requirements of the Declaration of Helsinki and was approved by the Bucharest Local Health Unit Ethics Committee. Patients entered the study after signing a written informed consent.

The exclusion criteria were<sup>[7]</sup> (a) administration of other systemic/intranasal antibiotics and/or corticosteroids, (b) evidence of infections during all the trials, (c) hypersensitivity (known or suspected) to any of the constituents of medication, (d) pregnancy or lactation, (e) known hepatic or renal insufficiency, and (f) any other concomitant drug treatment.

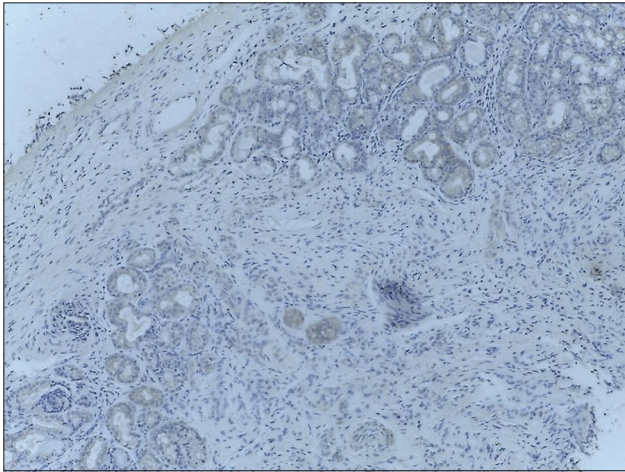
A sample of mucosa from ethmoid and middle turbinate mucosa was taken during functional endoscopic sinus surgery, while for Group B, the samples were taken during transnasal pituitary surgery or skull base surgery. For immunohistochemistry analysis, we used the procedure which was considered the most valid and reliable.<sup>[4]</sup> Samples were washed for 30 s in 0.9% sodium chloride solution to minimize blood contamination and then were paraffinized. Paraffin sections were deparaffinized, rehydrated, and rinsed in phosphate-buffered saline at pH 7.4. Retrieval with cooking in specific buffer was raised in a microwave oven (Samsung) at 800 W for 5 min and 440 W for 10 min. The immunohistochemistry method was an indirect bivalent technique performed with a polymer-based detection system (Max Polymer Detection System–Leica Ref: RE 7280-k) according to the manufacturer’s instructions. All specimens were counterstained with Meyer’s hematoxylin, examined, and photographed with a Nikon E  $\times 200$  microscope. The cases were tested by immunohistochemistry using monoclonal antibodies against bromelain (Agrisera AB/AS09 552). The dilution used was 1:2000, cooked overnight at 60°C, H<sub>2</sub>O<sub>2</sub> 3%.

We graded the quantity of bromelain in turbinate and ethmoid mucosa as 0, 1, 2, 3, and 4 based on reaction: grade 0 for absence of reaction, Grade 1 for positive reaction in glandular epithelium <25%, Grade 2 for positive reaction in cytoplasm from glands and covering epithelium 25%–50% [Figure 1], Grade 3 for positive reaction in cytoplasm from glands

**Table 1: Bromelain grades in controls and patients**

	Controls (Group B)			Patients (Group A)		
	Serum	Turbinate	Ethmoid	Serum	Turbinate	Ethmoid
Mean (SEM)	2.6 (0.22)	1.45 (0.20)	1.4 (0.21)	1.5 (0.21)	0.9 (0.18)	0.85 (0.17)
Median	3.0	1.5*	1.5*	1.5*	1.0	1.0

\* $P < 0.05$  compared to control serum. SEM=Standard error of mean



**Figure 1:** Immunohistochemistry Grade 2 positivity

and covering epithelium 50%–75%, and Grade 4 for positive reaction in cytoplasm from glands and covering epithelium >75%. A blood sample was collected, and the presence of bromelain in blood was determined using the Western blotting method. We graded the presence of bromelain in serum as 0 (no bromelain), and 1, 2, 3, and 4 based on the quantity of bromelain present in the serum. Optical density (OD) values of the migration gel <60,000 were graded 1, the OD values between 60,000 and 80,000 were graded 2, the OD values between 80,000 and 90,000 were graded 3, and the OD values >90,000 were graded 4.

The quantity of bromelain present in the mucus and serum is summarized in Table 1. The bromelain quantities in serum of Group A (patients) and Group B (controls) are significantly different. However, there is no difference in the quantities present in the mucus of both the groups. The mucus levels in controls are significantly different when compared to serum levels, but a similar difference is not observed in controls. It appears that the distribution of bromelain in mucus of patients and controls is no different though the serum levels in both the groups differ significantly. The diffusion capacity of bromelain as evidenced by the above results and the immunohistochemistry results [Figure 1] indicates that the drug could be exploited for use as an anti-inflammatory agent in nasal and sinusal pathologies.

### Financial support and sponsorship

Nil.

### Conflicts of interest

There are no conflicts of interest.

**Desiderio Passali, Luisa Maria Bellussi, Codrut Sarafoleanu<sup>1</sup>, Michele Loglisci, Claudiu Manea<sup>1</sup>, Cristina Iosif<sup>2</sup>, Francesco Maria Passali<sup>3</sup>**

Department of ENT, Università degli Studi di Siena, Siena, <sup>3</sup>Department of ENT, Università "Tor Vergata" di Roma, Roma, Italy, <sup>1</sup>Department of ENT, Carol Davila University of Medicine and Pharmacy, București, <sup>2</sup>CESITO Centre, "Sfanta Maria" Hospital, Bucharest, Romania, Balkans

**Address for correspondence:** Desiderio Passali, Department of ENT, Università degli Studi di Siena, Viale Bracci 16, 53100 Siena, Italy. E-mail: d.passali@virgilio.it

### REFERENCES

1. Mojcik CF, Shevach EM. Adhesion molecules: A rheumatologic perspective. *Arthritis Rheum* 1997;40:991-1004.
2. Cohen A, Goldman J. Bromelains therapy in rheumatoid arthritis. *Pa Med J* 1964;67:27-30.
3. Barth H, Guseo A, Klein R. *In vitro* study on the immunological effect of bromelain and trypsin on mononuclear cells from humans. *Eur J Med Res* 2005;10:325-31.
4. Orlandi RR, Kingdom TT, Hwang PH, Smith TL, Alt JA, Baroody FM, *et al.* International consensus statement on allergy and rhinology: Rhinosinusitis. *Int Forum Allergy Rhinol* 2016;6 Suppl 1:S22-209.
5. Fokkens WJ, Lund VJ, Mullol J, Bachert C, Alobid I, Baroody F, *et al.* European position paper on rhinosinusitis and nasal polyps 2012. *Rhinology* 2012;Mar; Suppl 23:3, 1-298.
6. Lund VJ, Mackay IS. Staging in rhinosinusitis. *Rhinology* 1993;31:183-4.
7. De Benedetto M, Passali D, Tomacelli G, Ruggieri A, Rosignoli MT, Piccolo R, *et al.* Penetration of prulifloxacin into sinus mucosa of patients undergoing paranasal sinus elective endoscopic surgery. *J Chemother* 2012;24:26-31.

This is an open access article distributed under the terms of the Creative Commons Attribution-NonCommercial-ShareAlike 3.0 License, which allows others to remix, tweak, and build upon the work non-commercially, as long as the author is credited and the new creations are licensed under the identical terms.

#### Access this article online

##### Quick Response Code:



##### Website:

www.jpharmacol.com

##### DOI:

10.4103/jpp.JPP\_169\_16

**How to cite this article:** Passali D, Bellussi LM, Sarafoleanu C, Loglisci M, Manea C, Iosif C, *et al.* Penetration of bromelain in serum and rhinosinusal mucosa in patients undergoing endoscopic sinus surgery. *J Pharmacol Pharmacother* 2017;8:128-9.

**Received:** 10-11-2016 **Revised:** 07-02-2017 **Accepted:** 14-03-2017

© 2017 Journal of Pharmacology and Pharmacotherapeutics | Published by Wolters Kluwer - Medknow