Case Reports in Gastroenterology

Case Rep Gastroenterol 2023;17:339–345
DOI: 10.1159/000534201
Received: April 6, 2023
Accepted: September 7, 2023
Published online: November 17, 2023

Case Report

Endoscopic Treatment of Colo-Colonic Intussusception in a Patient with Peutz-Jeghers Syndrome

Takeshi Fujima[a] Daisuke Saito[a] Hidenori Shibuta[a] Ryota Ogihara[a] Hiromu Morikubo[a] Ryo Ozaki[a] Sotaro Tokunaga[a] Shintaro Minowa[a] Tatsuya Mitsui[a] Miki Miura[a] Mari Hayashida[a] Yoshiko Watanabe[b] Jun Miyoshi[a] Minoru Matsuura[a] Junji Shibahara[c] Etsuji Ukiyama[b] Tadakazu Hisamatsu[a]

[a]Department of Gastroenterology and Hepatology, Kyorin University School of Medicine, Tokyo, Japan; [b]Department of Pediatric Surgery, Kyorin University School of Medicine, Tokyo, Japan; [c]Department of Pathology, Kyorin University School of Medicine, Tokyo, Japan

Keywords
Colo-colonic intussusception · Colonoscopy · Polypectomy · Peutz-Jeghers syndrome

Abstract
A 19-year-old man with a history of Peutz-Jeghers syndrome (PJS) and two previous partial small bowel resections because of intussusception presented with lower abdominal pain. Computed tomography (CT) showed concentric multilayer and cord-like structures in the transverse colon. Colo-colonic intussusception was suspected and he was hospitalized. After two therapeutic enemas were unsuccessful, a colonoscopy was performed. The intussusception was reduced and a 40-mm transverse colon polyp with a thick stalk was resected. After the procedure, his abdominal pain was relieved and he was discharged on the sixth hospital day. This case and several previous reports suggest that PJS polyps with tumor diameter exceeding 30 mm and location in the transverse or sigmoid colon can cause intussusception. Endoscopic treatment should be considered for these lesions.

Correspondence to:
Daisuke Saito, straw@zb3.so-net.ne.jp

Karger

Introduction

Peutz-Jeghers syndrome (PJS) is a disorder characterized by hamartomatous polyps of the entire gastrointestinal tract excluding the esophagus and pigmentation of the skin and mucous membranes, mainly of the lips, oral cavity, and fingertips [1]. It is an autosomal dominant disorder caused by germline pathogenic variant in the STK11/LKB1 gene on the short arm of chromosome 19 [2]. Approximately 17–50% of PJS cases are sporadic and occur in patients with no family history of the disease. Hamartomatous polyps in PJS are most common in the small intestine but also occur in the stomach, colon, and extraintestinal sites including the renal pelvis, bronchus, gall bladder, nasal passages, urinary bladder, and ureters. Polyps in the gastrointestinal tract can cause intussusception, which may require repeated laparotomy and bowel resection. Most PJS-related cases of intussusception occur in the small intestine; colo-colonic cases are rare [1–4]. All patients in previous case reports of colo-colonic intussusception in PJS underwent surgery as treatment. Polypectomy as treatment has not been reported. Here, we report successful endoscopic reduction and polypectomy for treatment of a colo-colonic intussusception in a patient with PJS. The CARE Checklist has been completed by the authors for this case report, attached as supplementary material (for all online suppl. material, see https://doi.org/10.1159/000534201).

Case Report

A 19-year-old man with PJS diagnosed at age 9 years presented with lower abdominal pain. No family members had the syndrome. At 9 and 14 years of age, he underwent partial resection of the small bowel for intussusception. Since then, he has been followed regularly with capsule and balloon endoscopy. A colonoscopy performed at 15 years of age showed three 20-mm polyps in the sigmoid colon that were resected, but a colonoscopy had not been performed since then. On physical examination, the abdomen was distended. He complained of tenderness on palpation from the left side of the umbilicus to the left lower abdomen. No pigmentation of the lips, mouth, or fingertips was observed. Blood testing showed an elevated white blood cell count (11,700/μL) but was otherwise unremarkable. Computed tomography (CT) showed concentric multilayer and cord-like structures in the transverse colon (Fig. 1). Based on these findings, he was diagnosed with colonic intussusception and hospitalized. Colonic polyps related to PJS were suspected as the cause. A therapeutic enema was performed using 200 mL diatrizoate meglumine and diatrizoate sodium solution in 2,000 mL of water (Fig. 2). Although this temporarily improved his pain, it worsened on the second hospital day. CT showed intussusception recurrence and another therapeutic enema was performed, which failed to relieve the pain. Therefore, colonoscopy was performed to resect the colonic polyps causing the intussusception on the following day. During the colonoscopy, invagination of the head of the polyp was found in the transverse colon (Fig. 3a). After releasing the invagination, a polyp over 40 mm in size with a thick stalk was visualized (Fig. 3b). The stalk was ligated with a detachable snare, and polypectomy was performed (Fig. 3c, d). After the procedure, the patient's abdominal pain disappeared. Improvement in intussusception was confirmed as abdominal symptoms disappeared, but post-treatment CT scan was not performed. He was discharged on the sixth hospital day. Histopathological examination of the polyp revealed hyperplasia of the mucosal epithelium and dendritic growth of smooth muscle fiber bundles from the mucosal muscle plate, which are features of PJS polyps (Fig. 4a, 3b). One-year follow-up colonoscopy and capsule endoscopy are planned.

Case Rep Gastroenterol 2023;17:339–345
DOI: 10.1159/000534201

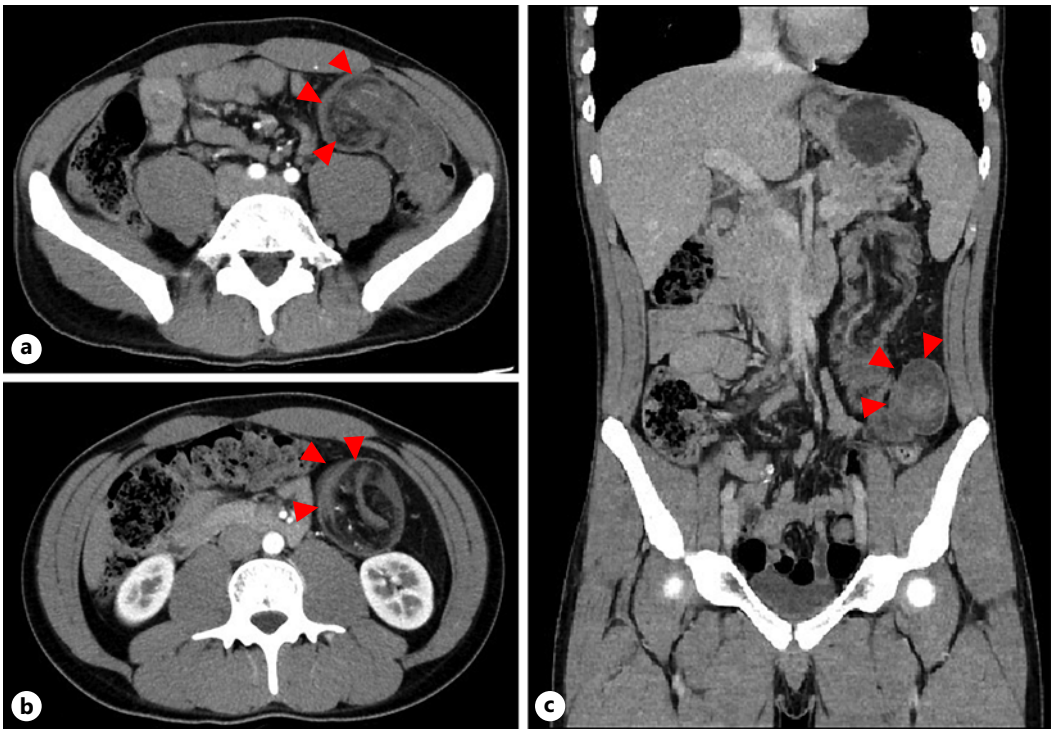

Fig. 1. Axial (**a**, **b**) and coronal (**c**) CT images at presentation. A concentric multilayer and cord-like structures were visualized in the transverse colon (red arrows).

Discussion

In patients with PJS, polyps frequently occur in the gastrointestinal tract excluding the esophagus, usually in the small intestine [1, 2]. In PJS, most intussusceptions develop before age 30, and most intussusception cases occur in the small intestine. In our patient, partial small bowel resection was performed at ages 9 and 14. Appropriate gastrointestinal surveillance is important to avoid surgery. Larger polyps are associated with higher risk of intussusception. Accordingly, the guidelines of the Japanese Society of Endoscopy and the European Society of Gastrointestinal Endoscopy strongly recommend polypectomy for small intestinal lesions larger than 15 mm [3, 4]. For specific surveillance, capsule endoscopy is recommended at the age of 8 years or earlier if symptoms are present, and surveillance every 1–3 years if polyps are found [1, 2]. In our case, the patient's informed consent was not obtained, so appropriate follow-up according to the guidelines could not be performed. As a result, he developed intussusception.

Although neoplastic and benign colorectal lesions such as colorectal cancer, malignant lymphoma, gastrointestinal stromal tumor, lipoma, and diverticulum have been reported to cause intussusception [3], colorectal intussusception caused by PJS polyps is rare. Table 1 summarizes the published reports of colo-colonic intussusception in patients with PJS, including our patient [5–9]. The most common sites of occurrence were the transverse colon and sigmoid colon. Tumor diameter was more than 30 mm in many cases. All previously reported cases were treated with surgery. The GeneReviews stated that prophylactic polypectomy of large polyps should be performed to decrease the sequelae of large polyps including bleeding, anemia, obstruction, and intussusception, and also to reduce the risk for cancer by the malignant transformation of PJS-type polyps [1]. Japanese guidelines also contain the same recommendations as GeneReviews [10]. Prophylactic polypectomy should

Case Rep Gastroenterol 2023;17:339–345
DOI: 10.1159/000534201

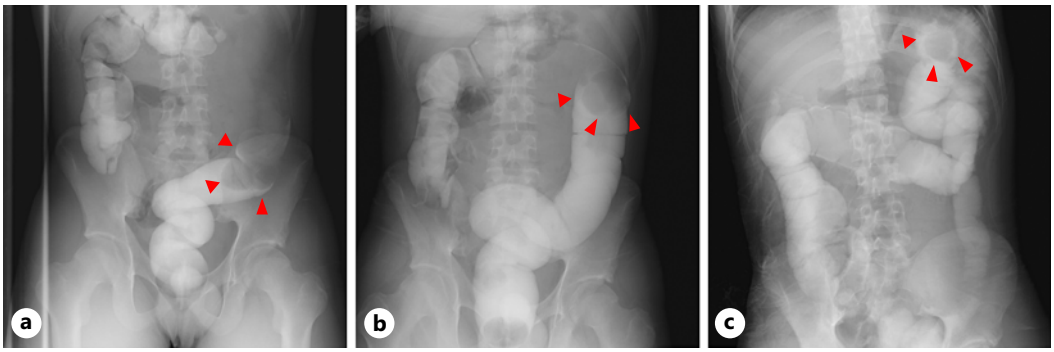

Fig. 2. Plain radiography images. **a** Before the therapeutic enema, a defect was found in the left colon (red arrows). **b**, **c** After the enema, the defect moved to the oral side (red arrows).

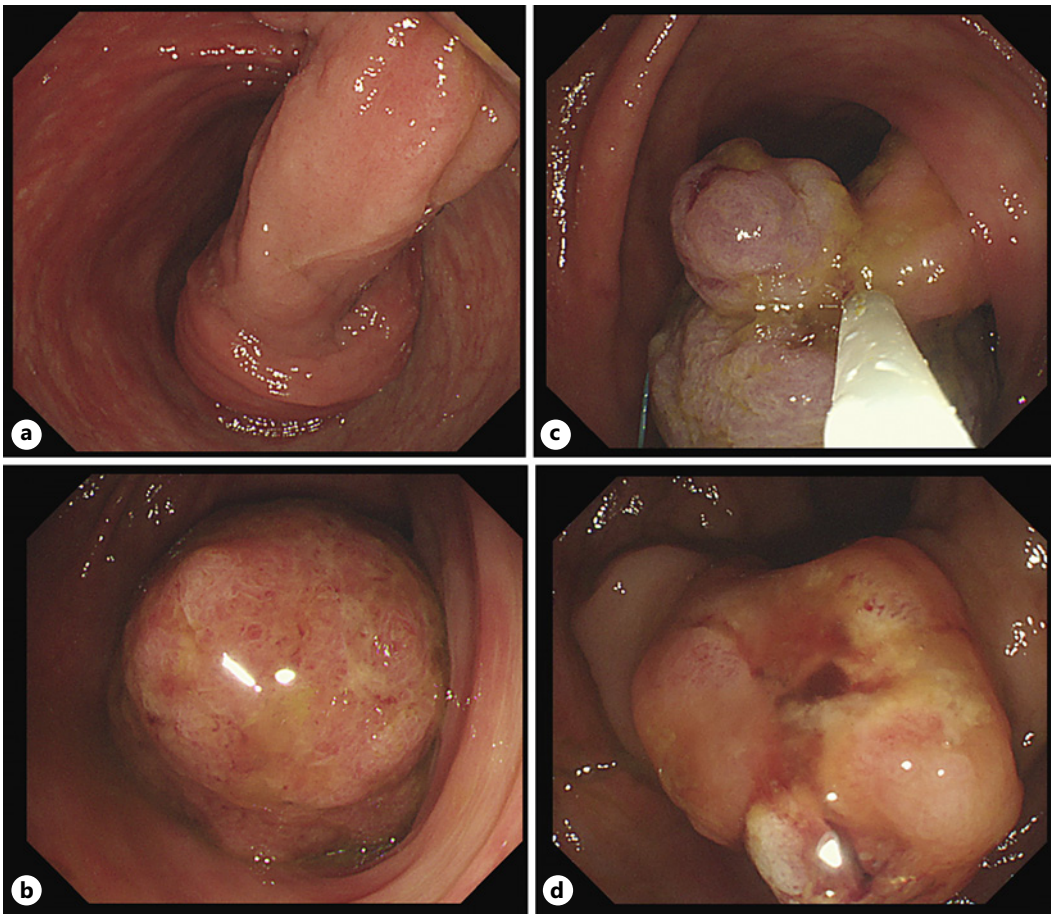

Fig. 3. A colonoscopic image shows invagination of the head of the polyp in the transverse colon (**a**). After releasing the invagination, a polyp over 40 mm in size with a thick stalk was visualized (**b**). The base of the stalk was ligated with a detachable snare, and polypectomy was performed after confirming the color change of the tumor surface (**c**, **d**).

Case Rep Gastroenterol 2023;17:339–345
DOI: 10.1159/000534201

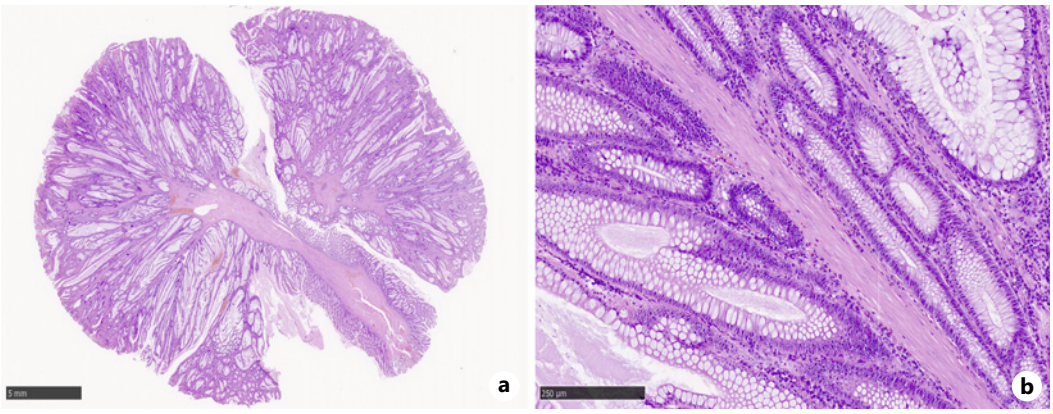

Fig. 4. a, **b** Histopathological images of the polyp demonstrate hyperplasia of the mucosal epithelium and dendritic growth of smooth muscle fiber bundles from the mucosal muscle plate.

Table 1. Case reports of colo-colonic intussusception in patients with PJS, including our patient

	Author	Year	Age	Sex	Site	Tumor size	Treatment
1	A J McAllister et al. [5]	1977	17 years	Female	Transverse colon	55 mm	Surgery
2	J Howel et al. [6]	1981	4 months	Male	Sigmoid colon	Unknown	Surgery
3	Jaremko J L et al. [7]	2005	19 years	Male	Spleen flextion	Unknown	Surgery
4	Hasegawa S et al. [8]	2006	47 years	Female	Sigmoid colon	30 mm	Surgery
5	Jamil S et al. [9]	2018	18 years	Male	Spleen flexion	Unknown	Surgery
6	Our case	2022	19 years	Male	Transverse colon	40 mm	Polypectomy

also be considered for colonic lesion according to this guideline, and if appropriate follow-up was performed in our case, we believe that the onset of intussusception could have been prevented. In addition, our case and the previous reports suggest that polyps with tumor diameter exceeding 30 mm and location in the transverse colon or sigmoid colon have a high risk of causing intussusception, as these segments of the colon are highly mobile. Appropriate polypectomy of colorectal polyps in patients with PJS may prevent intussusception and avoid future surgery.

In GeneReviews, regarding intussusception, it states, "Intussusception should be treated in a standard manner." Endoscopic treatment is less invasive than surgery, so if endoscopic treatment can be selected as a treatment for intussusception, it would be desirable. In our case, we were able to avoid surgery by performing endoscopic treatment for a large polyp exceeding 40 mm. However, whether or not it is possible to choose endoscopic treatment for intussusception is largely dependent on hospital size and endoscopist's experience, and so on. This may be one of the big problems in PJS treatment.

Although it is rare, colo-colonic intussusception may occur in patients with PJS. Colonic lesions should be evaluated when performing gastrointestinal surveillance. When lesions are encountered, endoscopic treatment should be considered to prevent intussusception. In particular, the risk of colo-colonic intussusception is high for transverse or sigmoid colon polyps larger than 30 mm, and early endoscopic treatment is desirable.

Acknowledgment

The authors thank Edanz (https://jp.edanz.com/ac) for editing a draft of this manuscript.

Statement of Ethics

The patient's treatment was conducted in accordance with the Declaration of Helsinki and the ethical principles of Kyorin University School of Medicine. Written informed consent was obtained from the patient and their parent for publication of the details of their medical case and any accompanying images. Kyorin University School of Medicine Ethics Committee requires no ethical approval for case reports. This retrospective review of patient data did not require ethical approval in accordance with local/national guidelines.

Conflict of Interest Statement

The authors have no conflicts of interest to declare.

Funding Sources

No funding was received in relation to this study.

Author Contributions

Guarantor of the article: D.S. Conception of the work and drafting of the manuscript: T.F., D.S., J.M., M.Ma., and T.H. Acquisition of data: H.S., R.Og., H.M., R.Oz., S.T., S.M., T.M., M.Mi., M.H., Y.W., J.S., and E.W.

Data Availability Statement

All data generated or analyzed during this report are included in this article. Further inquiries can be directed to the corresponding author.

References

1 McGarrity TJ, Amos CI, Baker MJ. Peutz-jeghers syndrome. In: Adam MP, Everman DB, Mirzaa GM, et al, editors. GeneReviews® [internet]. Seattle (WA): University of Washington, Seattle; 2001. p. 1993–2023. [Updated 2021 Sep 2].
2 van Lier MG, Mathus-Vliegen EM, Wagner A, van Leerdam ME, Kuipers EJ. High cumulative risk of intussusception in patients with peutz-jeghers syndrome: time to update surveillance guidelines? Am J Gastroenterol. 2011;106(5):940–5.
3 van Leerdam ME, Roos VH, van Hooft JE, Dekker E, Jover R, Kaminski MF, et al. Endoscopic management of polyposis syndromes: European society of gastrointestinal endoscopy (ESGE) guideline. Endoscopy. 2019; 51(9):877–95.
4 Matsui T, Oryu M, Kobara H, Komatsu A, Chiyo T, Kobayashi N, et al. A case of adult intussusception in the transverse colon with an advanced ileal Peutz-Jeghers type polyp associated with cancer. J Jpn Soc Gastroenterol. 2021;118(10):959–66.

5 MacAllister AJ, Richards KF. Peutz-Jeghers syndrome: experience with twenty patients in five generations. Am J Surg. 1977;134(6):712–20.
6 Howell J, Pringle K, Kirschner B, Burrington JD. Peutz-Jeghers polyps causing colocolic intussusception in infancy. J Pediatr Surg. 1981;16(1):82–4.
7 Jaremko JL, rawat B. Colo-colonic intussusception caused by a solitary Peutz-Jeghers polyp. Br J Radiol. 2005; 78(935):1047–9.
8 Hasegawa S, Sekka T, Soeda J, Ishizu K, Ito E, Morita S, et al. Laparoscopic treatment of intestinal intussusception in Peutz-Jeghers syndrome: case report and review of literature. Tokai J Exp Clin Med. 2006;31(4): 1 50–3.
9 Shah J, Sunkara T, Xiao P, Gaduputi V, Reddy M, Razia S. Peutz-jeghers syndrome presenting as colonic intussusception: a rare entity. Gastroenterol Res. 2018;11(2):150–3.
10 Yamamoto H, Sakamoto H, Kumagai H, Abe T, Ishiguro S, Uchida K, et al. Clinical guidelines for diagnosis and management of peutz-jeghers syndrome in children and adults. Digestion. 2023;104(5):335–47. Online ahead of print.