

# Acute Spontaneous Spinal Subdural Hematoma: A Case Report

## Authors' Contribution:

Study Design A  
Data Collection B  
Statistical Analysis C  
Data Interpretation D  
Manuscript Preparation E  
Literature Search F  
Funds Collection G

BDE 1 **M. Yassin Mitwalli**  
BDEFG 1,2 **Amr Elmoheen**  
EF 1,2 **Khalid Bashir**

1 Emergency Department, Hamad Medical Corporation, Doha, Qatar  
2 College of Medicine, Qatar University, Doha, Qatar

**Corresponding Author:** Amr Elmoheen, e-mail: [aelmoheen@hamad.qa](mailto:aelmoheen@hamad.qa)  
**Conflict of interest:** None declared

**Patient:** Male, 25-year-old  
**Final Diagnosis:** Acute spontaneous spinal subdural hematoma  
**Symptoms:** Weakness  
**Medication:** —  
**Clinical Procedure:** —  
**Specialty:** Critical Care Medicine • Neurology • Neurosurgery • Radiology

**Objective:** Rare disease

**Background:** Spontaneous spinal subdural hematoma is a rare condition that can lead to devastating neurologic deficits, usually caused by coagulation abnormalities, trauma, underlying neoplasm, or arteriovenous malformation. The patient presents with local and/or radicular pain, followed by loss of sensory, motor, bladder, and bowel function.

**Case Report:** A 25-year-old patient presented with left-sided weakness preceded by nontraumatic upper back pain. He denied any past medical illness and being on any regular medications. He had decreased strength in the left lower limb, left upper limb, and right lower limb, with intact strength in the right upper limb. The patient exhibited decreased sensation of pain and touch on the right side of the lower limb, bilateral loss of proprioception, and intact reflexes and anal tone. He had weakness on the left side of the body and contralateral decreased sensation of pain and touch on the right side. These symptoms were suggestive of Brown-Séquard syndrome, while the bilateral loss of proprioception suggested posterior cord syndrome. Magnetic resonance imaging showed an acute spinal subdural canal hematoma producing cord compression. The patient had an urgent laminectomy and hematoma evacuation. Afterward, his neurological function improved.

**Conclusions:** Spontaneous spinal subdural hematoma can occur without any known pathology or remarkable trauma. It can compress the spinal cord and produce cerebral stroke-like symptoms. Hence, spinal hematoma should be ruled out in any patient presenting with a neurological deficit.

**MeSH Keywords:** Brown-Sequard Syndrome • Hematoma, Subdural, Spinal • Spinal Cord Compression

**Full-text PDF:** <https://www.amjcaserep.com/abstract/index/idArt/922416>

 1027  —  3  11



## Background

Spontaneous spinal subdural hematoma is a rare condition that is considered a neurosurgical emergency because it can lead to devastating neurologic deficits, usually caused by coagulation abnormalities, trauma, underlying neoplasm, or arteriovenous malformation. The patient presents with local and/or radicular pain, followed by a loss of sensory, motor, bladder, and bowel function according to the affected side and level of the spinal cord. The source of bleeding is usually venous, and symptoms can progress over days. Time to intervention is crucial, especially in neurologically unstable patients [1]. Laminectomy and evacuation of the blood are vital to relieve the compression and avoid permanent loss of neurologic function. Stable neurologic deficits have a good prognosis and can be managed conservatively. This case report discusses such a case to help improve the outcome of this emergency condition.

## Case Report

A 25-year-old Bangladeshi man presented with left-sided weakness of 7-h duration that was preceded by nontraumatic upper back pain for 2 days. The pain had increased in intensity on the day of presentation. He went to his general practitioner, who gave him a diclofenac injection for pain. The patient started to develop left-sided weakness afterward.

He denied any past medical illness and being on any regular medications. The patient was a nonsmoker, did not consume alcohol, and had no previous similar attacks. The patient had stable vital signs and was fully conscious and afebrile at presentation.

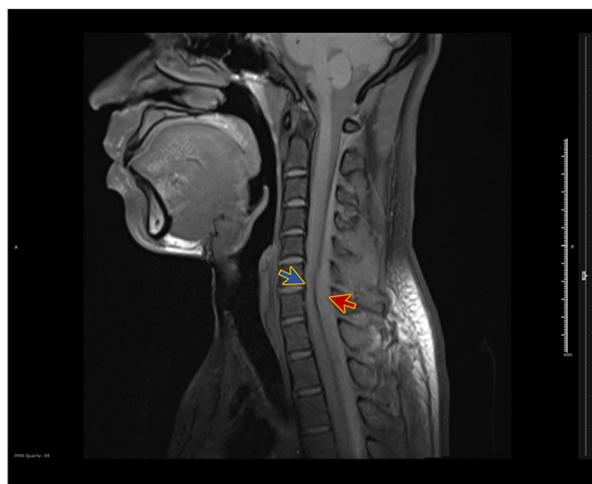His physical examination revealed decreased strength in the left lower limb (2/5), left upper limb (3/5), and right lower limb (4/5), with intact strength in the right upper limb. He had a decreased sensation of pain and touch on the right side of the lower limb, bilateral loss of proprioception, and intact reflexes and anal tone.

## Investigations

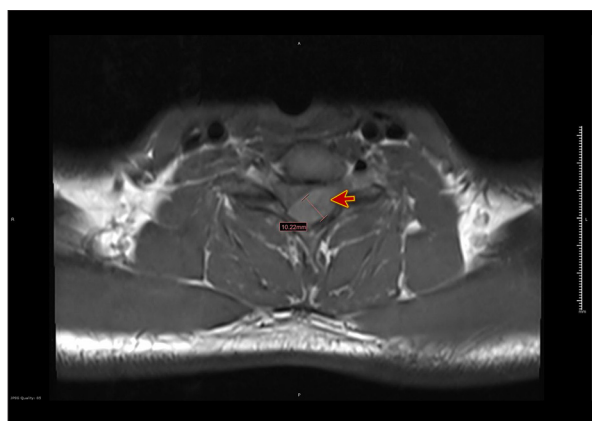
Initial blood workup, including a complete blood count and coagulation profile, yielded normal results.

Magnetic resonance imaging (MRI) showed findings suggestive of acute spinal subdural canal hematoma leading to cord compression, which was the most severe at the C6–C7 level, with cord signal changes (Figure 1).

A left-side posterolateral intraspinal extramedullary lesion was observed outside the thecal sac. It was appeared to be



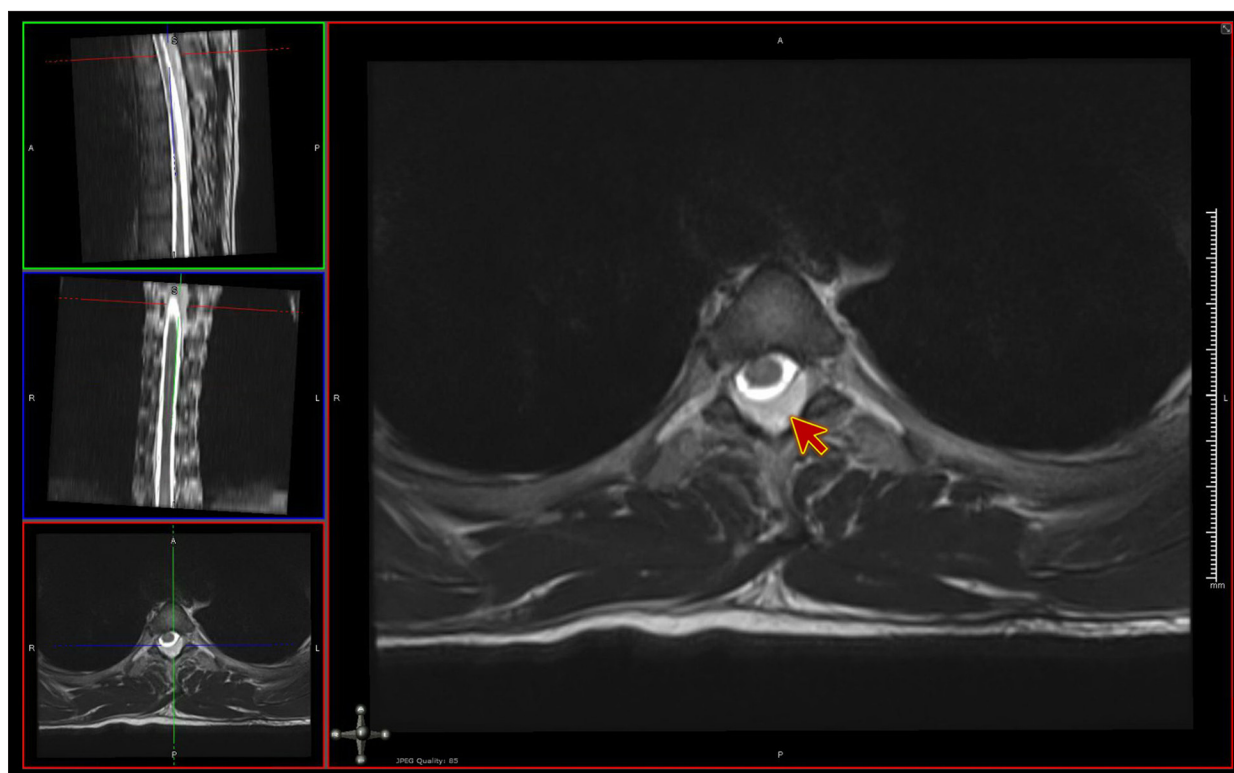
**Figure 1.** Magnetic resonance imaging with contrast, sagittal view whole spine. The figure shows acute spinal subdural canal hematoma (red arrow), producing cord compression (blue arrow) at the C6–C7 level.



**Figure 2.** Magnetic resonance imaging with contrast, transverse view whole spine. The figure shows severe cord compression, with a left-side posterolateral intraspinal extramedullary lesion outside the thecal sac (red arrow).

subdural, along the left lateral aspect of the spinal canal extending from C2–C3 to T7 level and very thin below the T3 level. The most significant part of this contiguous lesion was in the mid to lower cervical spine, where it measured approximately 1 cm in maximum thickness. Cord compression was the most severe C6/C7 (Figure 2), with displacement and compression of the cord toward the right ventral lateral aspect. The lesion, as such, was not enhanced with contrast, and there was enhancement surrounding it. Gradient-echo sequence showed hypodensities within the lesion, suggestive of blood products (Figure 3).

Spinal angiography was done using aseptic techniques and general anesthesia. After the right groin puncture, both vertebral



**Figure 3.** Magnetic resonance imaging with contrast, transverse view whole spine. The figure shows the gradient-echo sequence and hypodensities within the lesion, suggestive of blood products (red arrow).

arteries, both subclavian arteries, and the thoracic segmental arteries from T5 to T12 bilaterally, were catheterized. The study did not show any significant vascular abnormality.

### Differential diagnosis

The patient had weakness on the left side of the body and contralateral decreased sensation of pain and touch. These manifestations suggested Brown-Séquard syndrome. He also had a bilateral loss of proprioception, which mimicked the signs of posterior cord syndrome.

The diagnosis of acute spinal subdural canal hematoma and cord compression was accomplished by MRI.

### Treatment

The patient was referred to a neurosurgeon, who did an urgent C6–C7 laminectomy and hematoma evacuation to relieve pressure over the spinal cord. The surgery was smooth, and the patient did not experience any complications. The post-surgical plan involved getting the patient out of bed, sensory facilitation, balance training, and progressive gait training.

### Outcome, and follow-up

The patient later showed improvement in neurological function. The postoperative assessment showed that left elbow flexion and extension were grade 4, and the rest of the myotomes were grade 5. The patient had decreased sensations in C5/C6 dermatomes, but the rest of the neurological examination was normal.

On review, it was decided that the patient needs more occupational therapy sessions for upper limb strengthening exercises and physiotherapy sessions for safe ambulation, along with outpatient neuro occupational therapy referrals for upper limb muscle strengthening.

### Discussion

A spinal injury can cause sensory and motor deficits, and the presentation depends on the involved part of the spinal cord. Various mechanisms of spinal cord involvement may include trauma, abscess formation, tumor, or compression by a hematoma [2].

Regardless of its cause, bleeding around the spinal cord can produce spinal cord compression, which can present with

various symptoms depending on the site and the area involved. Sensory, motor, and autonomic functions of the spinal cord can be affected [3], and the diagnosis is made accordingly to the patterns of presentation [4].

Subdural spinal hematoma can have various causes, including arteriovenous malformation, use of anticoagulation medications, and trauma [5]. In some cases, it can spontaneously occur in the absence of any pathology [6–8], as happened in this case.

Spinal subarachnoid or subdural hemorrhage can present with neurological signs similar to Brown-Séquard syndrome, and it can be caused by trauma [9], oral anticoagulant use [10], or thrombocytopenia [11].

Our case presented with weakness on the left side of the body and contralateral decreased sensation of pain and touch. These manifestations suggested Brown-Séquard syndrome. The patient also had bilateral loss of proprioception, which mimicked signs of posterior cord syndrome. The patient had no coagulopathy, and he was not receiving any anticoagulant medications. He denied exposure to trauma, falls, or any procedures. MRI showed acute spinal subdural canal hematoma and cord compression.

We reached this challenging diagnosis of spontaneous spinal subdural hematoma by keeping in mind that the patient had neurological symptoms in the absence of precipitating factors such as trauma, coagulopathy, or anticoagulant use.

## Conclusions

Spinal hematoma can be spontaneous without any known pathology or trauma. It can compress the spinal cord and produce cerebral stroke-like symptoms. Therefore, spinal hematoma should be ruled out in any patient presenting with a neurological deficit. Emergency intervention is required to prevent permanent damage arising from spontaneous spinal subdural hematoma.

## Department and Institution where work was done

Emergency Department, Hamad Medical Corporation, Doha, Qatar.

## Conflict of interest

None.

## References:

1. Wang B, Liu W, Zeng X: Idiopathic cervical spinal subdural haematoma: A case report and literature review. *J Int Med Res*, 2019; 47(3): 1365–72
2. Donnally CJ III, Hanna A, Odom CK: Cervical myelopathy.. In: StatPearls [Internet]. Treasure Island (FL): StatPearls Publishing; Available from: <https://www.ncbi.nlm.nih.gov/books/NBK482312/>
3. Tamburrelli FC, Meluzio MC, Masci G et al: Etiopathogenesis of traumatic spinal epidural hematoma. *Neurospine*, 2018; 15(1): 101–7
4. Mariano R, Flanagan EP, Weinshenker BG, Palace J: A practical approach to the diagnosis of spinal cord lesions. *Pract Neurol*, 2018; 18: 187–200
5. De Beer MH, Eysink Smeets MM, Koppen H: Spontaneous spinal subdural hematoma. *Neurologist*, 2017; 22(1): 34–39
6. Matsumoto H, Miki T, Miyaji Y et al: Spontaneous spinal epidural hematoma with hemiparesis mimicking acute cerebral infarction: Two case reports. *J Spinal Cord Med*, 2012; 35(4): 262–66
7. Motamedi M, Baratloo A, Majidi A et al: Spontaneous spinal epidural hematoma; A case report. *Emerg (Tehran)*, 2014; 2(4): 183–85
8. Kyriakides AE, Lalam RK, El Masry WS: Acute spontaneous spinal subdural hematoma presenting as paraplegia: A rare case. *Spine (Phila Pa 1976)*, 2007; 32(21): E619–22
9. Rascón-Ramírez F, Avecillas-Chasín JM, Trondin A, Arredondo MJ: Brown-Séquard syndrome and cervical post-traumatic subarachnoid hematoma. *Neurocirugia (Astur)*, 2018; 29(4): 209–12
10. Wolfe AR, Farouqi RM, Visvikis GA et al: Spinal subarachnoid and subdural hematoma presenting as a Brown-Séquard-like myelopathy following minor trauma in a patient on dabigatran etexilate. *Radiol Case Rep*, 2017; 12(2): 257–60
11. Lee JH, Park KS, Lee DS, Park MS: Spontaneous spinal subdural hematoma causing Brown-Séquard syndrome with thrombocytopenic myelodysplastic syndrome. *Korean J Spine*, 2015; 12(3): 213–16