

The “correct shake” for “handshake” in glued intrascleral fixation of intraocular lens

Priya Narang, Amar Agarwal¹

We hereby describe the correct method to perform a “handshake technique” and easy transfer of haptics from one hand to another for glued intrascleral fixation of an intraocular lens (glued IOL). The procedure was implemented in 57 cases that necessitated the application of performing a glued IOL procedure and it resulted in an appropriate and easy externalization of haptic in all the cases. The surgeons’ positioning with reference to the scleral flap is an essential component and the surgeon should always be positioned perpendicular to the plane of scleral flaps and the plane of haptic maneuver. The surgeons who intend to perform glued IOL should adopt this technical point.

Key words: Glued intraocular lens, handshake technique, haptic externalization, vertical glued intraocular lens

Proper positioning of the surgeon and the patient’s eye is essential, and the goal in selecting and adjusting a particular surgical position is to maintain the ease of surgery while allowing proper and adequate access to the surgical site. Handshake technique^[1] forms an essential part of glued intrascleral fixation of intraocular lens (glued IOL)^[2,3] that

allows the transfer of haptics from one forceps to another for smooth haptic externalization. The essentials of the technique are required to be understood and deciphered correctly. The surgeon often struggles during haptic externalization if not positioned correctly in relation to the plane of scleral flaps and the plane of haptic manipulation. This prompted the authors to put forward this article to highlight and solve the issue.

Preoperatively, the corneal diameter is always measured so as to assess the amount of haptic that will be externalized. Adequate haptic externalization is essential as it allows sufficient amount of haptic to be tucked into the intrascleral pockets, thereby allowing a stable IOL fixation.^[2,4] In eyes with normal white-to-white (WTW) diameter, the surgeon can make a horizontal flap at 3’o clock and 9’o clock positions with the surgeon seated superiorly. In this scenario, the plane of surgical intervention that is haptic externalization is occurring perpendicular to the surgeon’s position and is appropriate for surgery [Fig. 1a]. However, in large eyes with greater WTW diameter when the surgeon performs a vertical glued IOL,^[5] i.e., the flaps are positioned at 12’o clock and 6’o clock positions, the surgeon needs to sit temporally if the surgeon is placed at 12’o clock position initially. The plane of scleral flaps and the plane of performing a handshake should be nearly perpendicular to the surgeon’s position, and it should not be aligned in the same direction [Fig. 1b].

Materials and Methods

The procedure conformed to the Declaration of Helsinki. Informed consent was taken from the patients and an Institutional Review Board’s approval was obtained. During phacoemulsification following a posterior capsule rupture [Fig. 2a], the corneal incision was sutured and the supplemental anesthesia was administered as necessary. Corneal diameter was measured with a Vernier caliper, and as the vertical corneal diameter is less, two scleral flaps were made a 12’o clock and 6’o clock positions. Infusion was

Videos Available on: www.ijo.in	
Access this article online	
Quick Response Code:	Website: www.ijo.in
	DOI: 10.4103/0301-4738.195613

Narang Eye Care and Laser Centre, Ahmedabad, Gujarat, ¹Dr. Agarwal’s Eye Hospital and Research Centre, Chennai, Tamil Nadu, India

Correspondence to: Prof. Amar Agarwal, Dr. Agarwal’s Eye Hospital and Eye Research Centre, 19, Cathedral Road, Chennai - 600 086, Tamil Nadu, India. E-mail: dragarwal@vsnl.com

Manuscript received: 22.12.15; Revision accepted: 15.09.16

This is an open access article distributed under the terms of the Creative Commons Attribution-NonCommercial-ShareAlike 3.0 License, which allows others to remix, tweak, and build upon the work non-commercially, as long as the author is credited and the new creations are licensed under the identical terms.

For reprints contact: reprints@medknow.com

Cite this article as: Narang P, Agarwal A. The “correct shake” for “handshake” in glued intrascleral fixation of intraocular lens. Indian J Ophthalmol 2016;64:854-6.

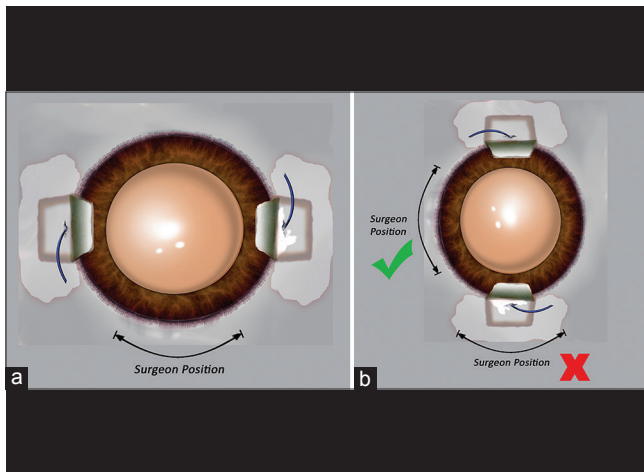


Figure 1: Image depicting surgeon's position for easy haptic externalization. (a) The scleral flaps are positioned horizontally and the surgeon sits almost perpendicular to the plane of haptic manipulation. (b) This image demonstrates the scleral flaps that are made at 12'o clock and 6'o clock positions. If the surgeon positions at the same plane as of the plane of haptic externalization for handshake, difficulty in manipulation is encountered. The surgeon when shifts temporally, the position is apt and the haptics can be easily manipulated with the correct shake for handshake technique

introduced into the eye, and sclerotomy was performed at a distance of 1.5 mm from the limbus with a 22-gauge needle beneath the scleral flaps, followed by vitrectomy [Fig. 2b]. The surgeon now shifts temporally irrespective of the previous position [Fig. 2c]. All the surgical steps as in a normal glued IOL surgery ensue. A corneal incision was made and a three-piece foldable IOL was injected and was slowly unfolded inside the eye [Fig. 2c]. The tip of the leading haptic was grasped with a glued IOL forceps (end opening forceps) and the haptic was pulled and externalized. A side port incision was created between the corneal incision and the left sclerotomy site. The trailing haptic was grasped with a glued IOL forceps and was then flexed into the eye. The trailing haptic was then transferred from the right hand to the left hand that was holding a glued IOL forceps introduced from the side port incision. A handshake technique^[1] was performed [Fig. 2d and e], wherein the haptics are transferred from right hand to left hand initially followed by withdrawal of right hand from the eye while the left-hand grasps the haptic. The forceps in the right hand was then introduced from the right sclerotomy site and the haptics were again transferred from left hand to the right hand. This transfer of haptics comprises the handshake technique and this movement is facilitated only when the surgeon sits perpendicular to the plane of haptic movement and transfer. The haptics were then externalized and tucked into the scleral pockets created with a 26-gauge needle [Fig. 2f and Video 1]. Vitrectomy was performed at the sclerotomy site to cut down any vitreous strand, infusion was stopped, scleral bed was dried up, and fibrin glue was applied at the base of scleral flaps.

Discussion

The technical aspect and proper understanding of the finer nuances are essential to optimize the outcome of surgery. For haptic exteriorization, "handshake technique" has been

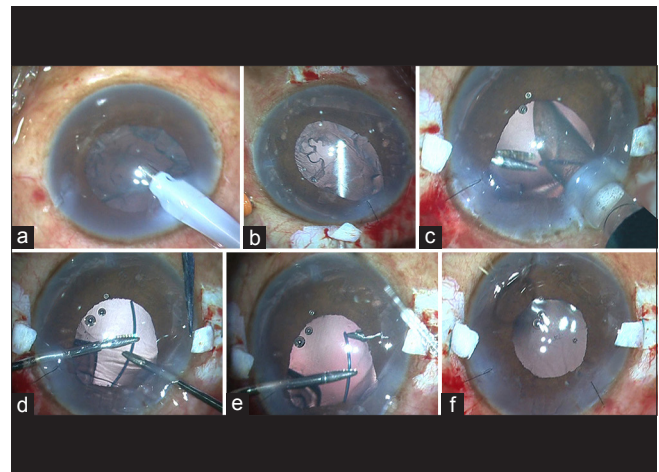


Figure 2: Surgical steps. (a) The posterior capsule ruptures. (b) Two partial thickness scleral flaps are made at 12'o clock and 6'o clock positions and vitrectomy is performed. (c) The surgeon shifts temporally (note the position of scleral flaps that now lie horizontally). A new corneal incision is made and a three-piece foldable intraocular lens is loaded and injected. The glued intraocular lens forceps introduced from the left sclerotomy site grasps the tip of haptic. (d) The trailing haptic is flexed and handshake technique is performed. (e) Tip of the trailing haptic is grasped and externalized. (f) Haptics tucked into the scleral pockets

described to be useful in myriad of clinical situations such as subluxation of lens, haptic slippage, and small pupil apart from the routine procedure of haptic maneuvering in glued IOL.^[1] This technique allows easy maneuverability of haptic issues within a closed globe system, and it is performed till the surgeon reaches the tip of haptic while the transfer of haptic from one hand to another continues. Handshake technique has been described in peer literature, but the article did not highlight the value of proper surgeon's positioning during the procedure.^[1] With due surgical experience with this technique, we the authors realized that it is extremely necessary to select proper surgical position for the surgeon after considering the relevant factor such as the measurement of corneal diameter as it is necessary to gauge the amount of haptic that will be exteriorized. In cases of large eyes with greater WTW diameter, the surgeon prefers to perform a vertical glued IOL^[5] as the vertical diameter of cornea is comparatively less and in doing, so the seating position of the surgeon should be almost perpendicular to the plane of scleral flaps for the "correct shake" for "handshake" to happen. Doing so leads to easy haptic externalization, reduces the intraoperative manipulation, and indirectly improves the surgical outcome of the surgery.

Financial support and sponsorship

Nil.

Conflicts of interest

There are no conflicts of interest.

References

1. Agarwal A, Jacob S, Kumar DA, Agarwal A, Narasimhan S, Agarwal A. Handshake technique for glued intrascleral haptic fixation of a posterior chamber intraocular lens. *J Cataract Refract Surg* 2013;39:317-22.

2. Agarwal A, Kumar DA, Jacob S, Baid C, Agarwal A, Srinivasan S. Fibrin glue-assisted sutureless posterior chamber intraocular lens implantation in eyes with deficient posterior capsules. *J Cataract Refract Surg* 2008;34:1433-8.
 3. Narang P. Modified method of haptic externalization of posterior chamber intraocular lens in fibrin glue-assisted intrascleral fixation: No-assistant technique. *J Cataract Refract Surg* 2013;39:4-7.
 4. Gabor SG, Pavlidis MM. Sutureless intrascleral posterior chamber intraocular lens fixation. *J Cataract Refract Surg* 2007;33:1851-4.
 5. Ladi JS, Shah NA. Vertical fixation with fibrin glue-assisted secondary posterior chamber intraocular lens implantation in a case of surgical aphakia. *Indian J Ophthalmol* 2013;61:126-9.
-