



Bacterial profile of suction drains and the relationship thereof to surgical-site infections in prosthetic breast reconstruction

Jeongmin Yoon, Jae-Ho Chung, Na-Hyun Hwang, Byung-Il Lee, Seung-Ha Park, Eul-Sik Yoon

Department of Plastic and Reconstructive Surgery, Korea University Anam Hospital, Korea University College of Medicine, Seoul, Korea

Original Article

Background Despite the increasing popularity of prosthetic breast reconstruction, scant data exist on the microbiological profile of drainage fluid from closed-suction drains and the relationship thereof to surgical-site infections (SSIs) in breast reconstruction surgery. This study aimed to determine whether bacteria isolated from drainage fluid were associated with the development of SSIs, and whether the bacterial profile of drainage fluid could be a clinically useful predictor of SSIs.

Methods We performed a retrospective chart review of 61 women who underwent tissue expander/implant or direct-to-implant reconstructions. Patient demographics and culture studies of drainage fluid from suction drains collected on postoperative day 7 were evaluated.

Results Sixteen patients (26.23%) were culture-positive, and 45 patients (73.77%) were culture-negative. The most frequently isolated bacteria were coagulase-negative staphylococci, followed by *Staphylococcus aureus*. SSIs were diagnosed in seven patients and were mostly resolved by systemic antibiotics; however, the tissue expander or implant was explanted in two patients. Positive culture of drainage fluid from closed-suction drains was significantly associated with the development of SSIs ($P < 0.05$). The positive predictive value was 37.50%, and the negative predictive value was 97.78%.

Conclusions To our knowledge, this study is the first to demonstrate a significant association between the microbiological profile of drainage fluid from closed-suction drains and the development of SSIs in patients with prosthetic breast reconstructions. The high negative predictive value suggests that microbial testing of drainage fluid from closed-suction drains may have clinical utility. Further prospective studies with larger sample sizes are required to confirm our findings.

Keywords Mammoplasty / Breast implants / Suction / Infection / Bacteria

Correspondence: Eul-Sik Yoon
Department of Plastic and Reconstructive Surgery, Korea University Anam Hospital, Korea University College of Medicine, 73 Incheon-ro, Seongbuk-gu, Seoul 02841, Korea
Tel: +82-2-920-5368
Fax: +82-2-922-7437
E-mail: yesanam2@korea.ac.kr

Received: 8 May 2018 • Revised: 23 Jul 2018 • Accepted: 5 Sep 2018
pISSN: 2234-6163 • eISSN: 2234-6171 • <https://doi.org/10.5999/aps.2018.00437> • Arch Plast Surg 2018;45:542-549

INTRODUCTION

In 2016, over 109,000 women underwent breast reconstructions in the United States. Tissue expander or implant-based re-

constructions were the most frequently performed procedures, accounting for 81.10% of operations [1]. Despite the increasing number of procedures performed yearly, the overall complication rate of postmastectomy breast reconstruction remains as

high as 60% [2,3]. Among all potential complications, surgical-site infections (SSIs) in cases of prosthesis-based reconstruction are the problem of greatest concern; the average rate of SSI after prosthetic breast reconstruction ranges from 1% to 35.4% [4-8]. SSIs after prosthetic breast reconstruction are often devastating, resulting in prolonged hospitalization and implant loss in the majority of cases.

To reduce hematoma formation and fluid collection, one or more closed-suction drains are usually inserted deep to the mastectomy flaps and in the axilla [9]. Such drains are kept in place during the postoperative period for a period of time that varies considerably based on the surgeon's experience [10]. Surgical drains provide an entry for bacteria into the clean wound environment. Recently, Felipe et al. [11] investigated the rate of bacterial colonization in closed-suction drains after mastectomy in patients with breast cancer and found that bacteria were isolated in 33% of drainage fluid samples at 1 week after mastectomy and in 81% at 2 weeks. In 85% of the patients who developed an SSI, the bacteria identified were the same as those identified in the suction drain cultures; furthermore, bacterial colonization of the drain was found to be an independent predictor of SSI.

In various surgical fields, whether cultures from closed-suction drains are associated with the development of SSI is controversial, and the diagnostic value of routine cultures is not firmly established. While Takada et al. [12] reported that positive drain culture results were related to the development of SSIs in patients who underwent hip arthroplasty, Ahn et al. [13] reported that drain culture was a poor predictor of SSI in patients who underwent primary spinal surgery. In breast reconstruction, no study has investigated whether positive culture results for closed-suction drains are associated with SSI. Therefore, this study assessed the microbiological profile of cultures from closed-suction drains in patients who underwent prosthetic breast reconstruction after mastectomy and investigated whether the culture results were predictive of SSI. The main purpose of this study was to investigate whether a positive culture result was related to the development of SSIs and to evaluate the prognostic value of culturing drainage fluid for predicting SSIs in prosthetic breast reconstruction patients.

METHODS

Study population

We retrospectively investigated patients who had undergone prosthetic breast reconstruction after breast cancer surgery from March 2015 to December 2016 at Korea University Anam Hospital. The breast procedures in this study included immediate or

delayed tissue expander/implant and direct-to-implant reconstruction after breast cancer surgery. The exclusion criteria were as follows: exchange of the tissue expander for a permanent implant and implant placement beneath a latissimus dorsi flap. Approval from the Korea University Anam Hospital Institutional Review Board was obtained for conducting this study (2018-AN0214). The patients provided written informed consent for the publication and the use of their images.

SSI definition

Superficial and deep SSIs were defined according to the criteria of the Centers for Disease Control and Prevention [14]. Under these criteria, infection occurs within 30 days or within 1 year if an implant is in place, and the patients must present either purulent drainage from the incision or infectious symptoms such as localized pain, fever, and tenderness. For patients diagnosed with SSIs, we aseptically cultured tissue that was biopsied from infected wounds whenever possible.

Surgical technique and protocol

At our center, all patients received prophylactic antibiotic administration within 30 minutes before surgery, consisting of a single intravenous dose of 1 g of cefazidone. After surgery, patients were given an intravenous dose of 1 g of cefazidone twice daily until postoperative day (POD) 7, after which 500 mg of cephalexin was administered orally 3 times a day for a week.

We performed tissue expander/implant reconstruction or direct-to-implant reconstruction based on perfusion and the availability of a skin flap. During surgery, acellular dermal matrix was used in all cases; it was sutured inferiorly to the inferior border of the pectoralis major muscle and laterally to the inframammary fold crease. For patients who underwent tissue expander/implant reconstruction, a tissue expander was placed beneath the pectoralis major muscle flap, which would be exchanged for a permanent implant after an appropriate interval. Then, two closed-suction drains were placed under the mastectomy flap at the end of the procedure: one in the subcutaneous plane and the other in the submuscular plane. For patients who underwent direct-to-implant reconstruction, an implant was placed in the submuscular plane, and only a single closed-suction drain was inserted subcutaneously.

A 2-mL specimen of drainage fluid was routinely collected on POD 7 and was sent to the microbiology laboratory of the hospital for culture analysis. Before aspirating the drainage fluid, the suction drains were sterilized with 10% aqueous povidone-iodine solution. For patients who underwent tissue expander/implant reconstruction, the suction drain placed in the submuscular plane was first removed on POD 7, and the other was re-

moved between POD 8 and 14 when the daily discharge volume decreased to below 30 mL or on POD 14, whichever came first. For patients who underwent direct-to-implant reconstruction, the suction drain was removed after aspirating drainage fluid on POD 7. Patients were discharged after the removal of at least one closed-suction drain and were followed up twice a week until the wounds had healed completely. After that, they routinely visited the outpatient clinic at 2-week intervals unless any signs of infections such as fever, erythema, swelling, or pain developed.

Data collection

Data collected through retrospective chart review included age, body mass index, preoperative diagnosis of diabetes mellitus or arterial hypertension, smoking status, history of chemotherapy and/or irradiation, time of breast reconstruction (delayed or immediate reconstruction), type of breast cancer surgery (skin-sparing mastectomy, nipple-sparing mastectomy, or breast-conserving surgery), concurrent axillary lymph node dissection, microbiological data from cultures of drainage fluid from closed-suction drains, and the development of SSIs.

Statistical analysis

Statistical analysis was conducted using SPSS version 22.0 (IBM Corp., Armonk, NY, USA). Continuous variables are shown as means with standard deviations, and categorical variables as counts and percentages. The studied variables were analyzed with the chi-square test or the Fisher exact test for categorical variables and the Student t-test for numerical variables. P-values < 0.05 were considered to indicate statistical significance.

RESULTS

During the study period, 61 women underwent immediate or delayed tissue expander and direct-to-implant breast reconstructions (Table 1). Among them, 16 patients (26.23%) had

Table 1. Patients' demographic and clinical characteristics

Characteristic	Groups with positive cultures	Groups with negative cultures	P-value
No. of patients	16 (26.23)	45 (73.77)	
Age (yr)	50.25 ± 10.89	45.42 ± 7.52	0.116
Body mass index (kg/m ²)	23.71 ± 3.90	23.41 ± 3.62	0.784
Type of reconstruction			1.000
Tissue expander/implant	15 (93.75)	43 (95.56)	
Direct-to-implant	1 (6.25)	2 (4.44)	
Time of reconstruction			1.000
Immediate	15 (93.75)	43 (95.56)	
Delayed	1 (6.25)	2 (4.44)	
Operative details			0.07
Bilateral	4 (25)	3 (6.67)	
Unilateral	12 (75)	42 (93.33)	
Type of mastectomy			
Nipple-sparing mastectomy	4 (25)	27 (60)	0.016
Skin-sparing mastectomy	12 (75)	17 (37.78)	0.010
Breast-conserving surgery	0	1 (2.22)	1.000
Axillary lymph node dissection	7 (43.75)	21 (46.67)	1.000
Comorbidity			
Diabetes	1 (6.25)	1 (2.22)	0.459
Hypertension	3 (18.75)	6 (13.33)	0.686
Smoking	2 (12.50)	0	0.066
Previous irradiation	0	2 (4.44)	1.000
Previous chemotherapy	2 (12.50)	13 (28.89)	0.312

Values are presented as number (%) or mean ± standard deviation. Data comparison was performed using the chi-square test or Fisher exact test for categorical variables and the Student t-test for numerical variables.

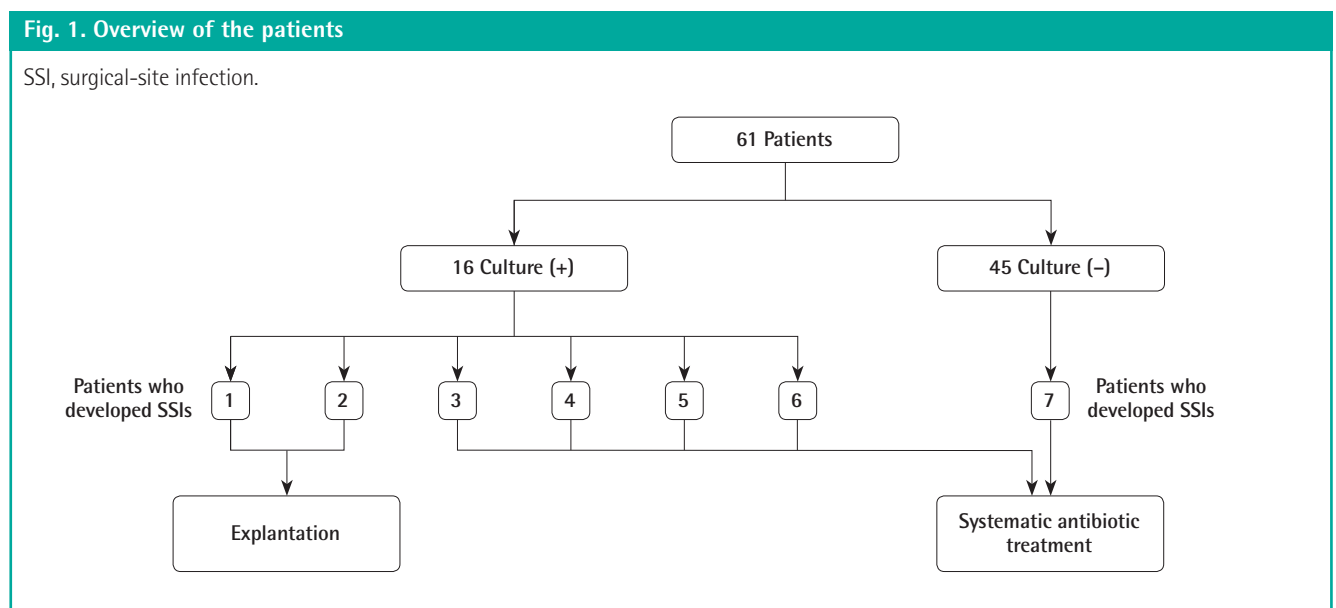


Table 2. Microbiological profile of drainage fluid samples

Isolate	Prevalence
Gram-positive bacteria	
Coagulase-negative <i>Staphylococcus</i>	7 (33.33)
<i>Staphylococcus aureus</i>	3 (14.29)
<i>Bacillus</i> spp.	
<i>Enterococcus faecalis</i>	2 (9.52)
Others	1 (4.76)
<i>Corynebacterium</i> spp.	1 (4.76)
Total	14 (66.66)
Gram-negative bacteria	
<i>Acinetobacter baumannii</i>	3 (14.29)
<i>Pseudomonas</i> spp.	
<i>Pseudomonas aeruginosa</i>	2 (9.52)
<i>Pseudomonas oryzihabitans</i>	1 (4.76)
<i>Stenotrophomonas maltophilia</i>	1 (4.76)
Total	7 (33.33)

Values are presented as number (%).

positive cultures, and 45 (73.77%) had negative cultures (Fig. 1). The majority of patients underwent tissue expander/implant reconstruction: the positive and negative drain culture groups consisted of 15 (93.75%) and 43 (95.56%) tissue expander/implant reconstructions, respectively. Of the three patients who underwent delayed breast reconstructions, one patient underwent a tissue expander/implant operation, and two patients underwent a direct-to-implant procedure.

The bacterial species present in the positive cultures of drainage fluid are listed in Table 2. Fluid from four patients was positive for multiple bacteria species. One patient who underwent bilateral tissue expander/implant reconstruction had three different bacterial species in her drainage fluid. Two patients who underwent unilateral tissue expander/implant reconstruction and one patient who underwent unilateral direct-to-implant reconstruction had two different bacterial species. A total of 21 bacterial isolates identified in 16 patients were included in this analysis. Two-thirds of the isolates cultured from drainage fluid were Gram-positive, and seven contained coagulase-negative staphylococci. *Staphylococcus aureus* was detected in three cases (14.29%), and all were methicillin-sensitive. With regard to Gram-negative bacteria, *Acinetobacter baumannii* was detected in three cases (14.29%) and *Pseudomonas* spp. in three cases (14.29%).

SSIs developed in six of the 16 women in whom the closed-suction drain cultures were positive (Table 3). Only one of the 45 patients who were culture-negative developed an SSI. Suction drain cultures had a sensitivity of 85.71%, a specificity of 81.48%, a positive predictive value (PPV) of 37.50%, and a negative predictive value (NPV) of 97.78% (Table 4). A positive

Table 3. Results for drain cultures and SSIs

Drain culture	Total	SSI	
		Positive	Negative
Positive	16	6	10
Negative	45	1	44

SSI, surgical-site infection.
P=0.0009; data comparison was performed using Fisher exact test.

Table 4. Predictive power of positive drain cultures for SSIs

Prediction of SSIs	Percentile
Sensitivity	85.71
Specificity	81.48
PPV	37.50
NPV	97.78

SSI, surgical-site infection; PPV, positive predictive value; NPV, negative predictive value.

suction drain culture was significantly associated with the development of SSIs (P = 0.0009).

Details of the patients who developed SSIs are presented in Table 5. The type and timing of the breast reconstructions were as follows: five immediate tissue expander/implant reconstructions, one immediate direct-to-implant reconstruction, and one delayed direct-to-implant reconstruction. Coagulase-negative staphylococci were found in cultures of drainage fluid from three patients. In patients 1 and 2, methicillin-sensitive *S. aureus* was isolated from closed-suction drains on POD 7. After these patients developed SSIs, tissue biopsies were taken aseptically from the infected postoperative wound site whenever possible, and methicillin-sensitive *S. aureus*, previously isolated from the drainage fluid on POD 7, was detected. All patients who developed SSIs received systemic antibiotics, and the symptoms of five of these patients resolved completely. Patients 1 and 2 were not healed by the continuous use of antibiotics and were admitted for surgical removal of the tissue expander and implant (Fig. 2). Their SSIs resolved completely after surgical debridement of the infected wound and prosthesis removal.

DISCUSSION

Despite the increase in the number of prosthetic breast reconstructions performed annually, the infection rate still ranges from 1% to 35.4% [4-8]. Furthermore, for 3% of patients, postoperative infection leads to additional surgery and explantation of the implants, imposing both medical and financial burdens [15,16]. During breast reconstruction after breast cancer surgery, one or more closed-suction drains are routinely inserted to

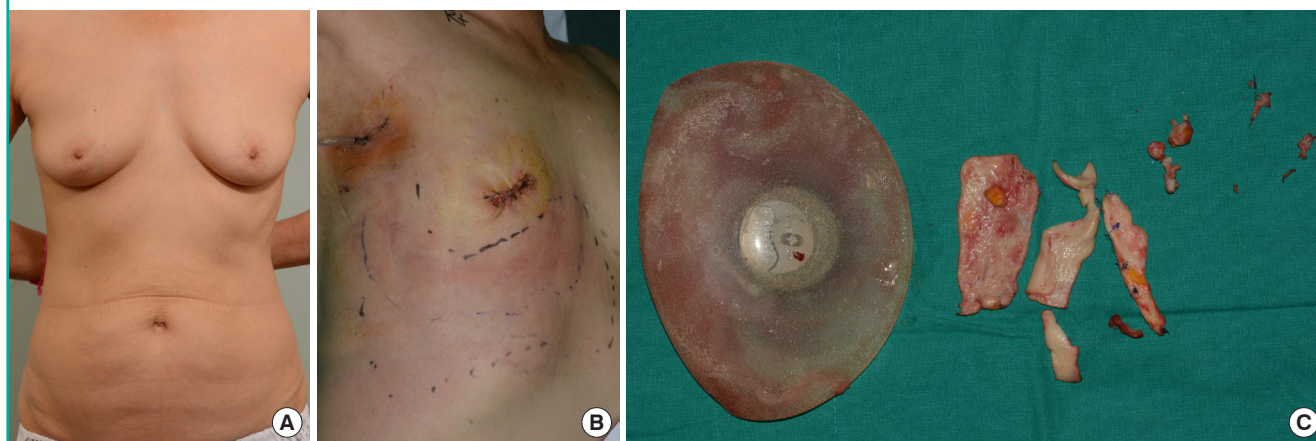
Table 5. Epidemiological and microbiological characteristics of SSIs

Patient	Age (yr)	Type of reconstruction	Type of mastectomy	Drain fluid culture on POD 7	Days between surgery and SSIs	Tissue biopsy culture	Treatment
1	61	Immediate tissue expander/implant	Skin-sparing mastectomy	MSSA	19	MSSA	Implant removal
2	45	Delayed direct-to-implant	Nipple-sparing mastectomy	MSSA, <i>Pseudomonas aeruginosa</i>	35	MSSA	Implant removal
3	55	Immediate tissue expander/implant	Skin-sparing mastectomy	MRSE	22	Not performed	Antibiotics
4	53	Immediate tissue expander/implant	Skin-sparing mastectomy	MRSH, <i>Corynebacterium</i> spp.	33	<i>Enterobacter cloacae</i>	Antibiotics
5	51	Immediate tissue expander/implant	Skin-sparing mastectomy	MRSE	10	Not performed	Antibiotics
6	32	Immediate tissue expander/implant	Skin-sparing mastectomy	<i>Bacillus</i> spp.	14	MRSE	Antibiotics
7	47	Immediate direct-to-implant	BCS	No growth	25	No growth	Antibiotics

SSI, surgical-site infection; POD, postoperative day; MSSA, methicillin-sensitive *Staphylococcus aureus*; MRSE, methicillin-resistant *Staphylococcus epidermidis*; MRSH, methicillin-resistant *Staphylococcus haemolyticus*; BCS, breast-conserving surgery.

Fig. 2. Case: patient 1

A 61-year-old woman who underwent skin-sparing mastectomy and immediate breast reconstruction with a tissue expander. (A) Preoperative photograph. (B) Nineteen days after breast reconstruction, a surgical-site infection developed. Erythema was observed around the incision site. (C) The tissue expander was finally removed to relieve the symptoms of infection.



prevent hematoma and seroma formation, and the duration of placement is usually determined based on the surgeon's experience.

Suction drains are kept in close proximity to the implant or tissue expander and may be ideal for the early detection of bacterial growth that can contribute to SSIs. Several studies in other surgical fields have investigated the relationship between SSIs and suction drain cultures, but controversy remains. According to Kobayashi et al. [17], even though insufficient data supported the conclusion that suction tip culture could indicate the presence or absence of SSIs in patients who underwent spinal surgery, it might be useful for early detection of methicillin-resistant bacteria. Although several breast surgery studies have in-

vestigated the relationship between suction drain cultures and SSIs, it is not clear from these studies whether the two are significantly related. Felipe et al. [11] investigated risk factors for SSIs in 354 women who underwent breast-conserving surgery or mastectomy. Closed suction drains were inserted in the axilla or under both the skin flap and axilla, and drainage fluid was collected at POD 7 and when the drain was removed. Bacterial colonization was significantly associated with SSIs, with a relative risk of 2.50 (95% confidence interval, 1.15–5.44).

We classified the bacteria grown from drainage fluid cultures and explored the relationship between suction drain cultures and SSIs after breast reconstruction procedures. The profile of bacteria we found in cultures was similar, but not identical, to

those reported in previous studies [15,18]. Gram-positive bacteria were more common in our study (66.66%) than Gram-negative bacteria. While Cohen et al. [15] also reported more frequent isolation of Gram-positive bacteria (75%) than Gram-negative bacteria (20%), Weichman et al. [18] reported an equal distribution of Gram-positive and Gram-negative bacteria. These differences in bacterial profiles can be explained by the use of different prophylactic antibiotics at different medical centers and the unique microbiomes of the patients. Furthermore, we routinely collected drainage fluid from closed-suction drains and performed microbial analyses, while Weichman et al. [18] and Cohen et al. [15] obtained tissue samples from patients who had already developed SSIs. Because the cultures of drainage fluid were routinely performed, the microbial profile of patients was analyzed regardless of the presence of SSIs.

Among the patients with positive cultures, a greater proportion had undergone skin-sparing mastectomy than among those with negative cultures (75% vs. 37.78%), and this difference was statistically significant ($P = 0.010$) (Table 1). After the placement of a tissue expander or implant, the mastectomy skin flap can be closed under more tension in skin-sparing mastectomy than in nipple-sparing mastectomy, resulting in skin flap necrosis. The presence of devitalized tissues in the wound may favor bacterial growth, affecting the bacterial colonization of drainage fluid. Except for the mastectomy type, the two groups did not show statistically significant differences for any demographic or clinical parameters.

In our analysis, the most common bacteria from suction drain cultures were coagulase-negative staphylococci, followed by *S. aureus* and *A. baumannii*. The majority of coagulase-negative staphylococci were *Staphylococcus epidermidis*. The breast is not sterile, and endogenous skin flora has been noted as a principal cause of implant-related infections after prosthetic breast reconstruction [19,20]. The usual causative organisms of SSIs are *S. aureus*, coagulase-negative staphylococci, streptococci, and *Propionibacterium* spp., and Ahn et al. [21] demonstrated that *S. epidermidis* and *Propionibacterium* spp. were present in 47% of silicone implant patients with symptomatic infections [20]. Seven patients in our study eventually developed SSIs 10 to 35 days after tissue expander or direct-to-implant reconstruction. In the patient who underwent direct-to-implant reconstruction after breast-conserving surgery, we failed to isolate any bacteria from the drainage fluid at POD 7 and in a tissue biopsy at the outpatient clinic. Although the symptoms of five patients subsided in response to systematic antibiotic treatment with cefazone and ciprofloxacin, the implant and tissue expanders in two patients were explanted due to the severity of symptoms and their unresponsiveness to conservative treatment. *S. aureus* was

isolated from the routine collection of drainage fluid from closed-suction drains at POD 7, and an identical species was found in isolates from pus after SSIs developed. In a previous study of acute postoperative breast implant infections, *S. aureus* was responsible for periprosthetic infections in 68% of patients who developed infections [22]. In addition, 66.66% of the *S. aureus* isolates in that study were resistant to methicillin. In our analysis, however, all *S. aureus* isolates were sensitive to methicillin. This discrepancy may have been due to our relatively small sample size, because another study reported that the majority of *S. aureus* isolates were sensitive to methicillin [15].

Our data suggest that bacterial colonization of drainage fluid is significantly associated with the development of SSIs. A relationship between bacterial colonization of drains and SSIs was previously reported for patients who underwent a total mastectomy. Degnim et al. [23] demonstrated that SSIs more frequently occurred in patients with greater levels of bacterial colonization than in patients with less or no bacterial colonization (22% vs. 4%). Moreover, our analysis further revealed that the NPV of drain culture for SSIs was 97.78%, suggesting that drain culture might be able to accurately predict true negative cases. However, the PPV, sensitivity, and specificity were 37.50%, 85.71%, and 81.48%, respectively. Further studies with larger sample sizes are required to more accurately determine the prognostic value of closed-suction drain cultures.

Our study, however, has several limitations. As we used a retrospective review design, a prospective trial is required for further validation and to increase the power of the study design. In addition, well-known risk factors for SSI in breast surgery include obesity, smoking, old age, and other medical comorbidities such as diabetes mellitus [11,24]; however, the sample size used in this study was not large enough to control for all these variables, meaning that there was insufficient statistical power to address whether suction drain cultures were an independent predictor of SSIs. Despite these limitations, the strength of this study is that it is the first study to evaluate the association between drainage fluid culture and SSIs in patients who underwent prosthesis-based breast reconstructions.

In our analysis, Gram-positive bacteria, especially coagulase-negative staphylococci and *S. aureus*, were most frequently isolated from drainage fluid of closed-suction drains in patients who underwent prosthetic breast reconstruction. We also demonstrated a significant association between positive culture results and the development of SSIs, and the drain cultures had a high NPV, suggesting that culturing of drainage fluid could be useful for the early detection of SSIs and selection of antibiotics when SSIs develop. To obtain stronger evidence for this association and the clinical value of drainage fluid cultures, further pro-

spective clinical studies in a larger population should be performed.

NOTES

Conflict of interest

No potential conflict of interest relevant to this article was reported.

Ethical approval

The study was approved by the Institutional Review Board of Korea University Anam Hospital (IRB No. 2018AN0214) and performed in accordance with the principles of the Declaration of Helsinki. Written informed consents were obtained.

Patient consent

The patient provided written informed consent for the publication and the use of her images.

REFERENCES

1. Plastic surgery statistics report [Internet]. Arlington Heights, IL: American Society of Plastic Surgeons, c2017 [cited 2018 Sep 27]. Available from <https://www.plasticsurgery.org/documents/News/Statistics/2016/plastic-surgery-statistics-full-report-2016.pdf>.
2. Alderman AK, Wilkins EG, Kim HM, et al. Complications in postmastectomy breast reconstruction: two-year results of the Michigan Breast Reconstruction Outcome Study. *Plast Reconstr Surg* 2002;109:2265-74.
3. Phillips BT, Wang ED, Mirrer J, et al. Current practice among plastic surgeons of antibiotic prophylaxis and closed-suction drains in breast reconstruction: experience, evidence, and implications for postoperative care. *Ann Plast Surg* 2011;66:460-5.
4. Nahabedian MY, Tsangaris T, Momen B, et al. Infectious complications following breast reconstruction with expanders and implants. *Plast Reconstr Surg* 2003;112:467-76.
5. Phillips BT, Bishawi M, Dagum AB, et al. A systematic review of antibiotic use and infection in breast reconstruction: what is the evidence? *Plast Reconstr Surg* 2013;131:1-13.
6. Pittet B, Montandon D, Pittet D. Infection in breast implants. *Lancet Infect Dis* 2005;5:94-106.
7. Spear SL, Masden D, Rao SS, et al. Long-term outcomes of failed prosthetic breast reconstruction. *Ann Plast Surg* 2013;71:286-91.
8. Spear SL, Seruya M. Management of the infected or exposed breast prosthesis: a single surgeon's 15-year experience with 69 patients. *Plast Reconstr Surg* 2010;125:1074-84.
9. Boostrom SY, Throckmorton AD, Boughey JC, et al. Incidence of clinically significant seroma after breast and axillary surgery. *J Am Coll Surg* 2009;208:148-50.
10. Murray JD, Elwood ET, Jones GE, et al. Decreasing expander breast infection: a new drain care protocol. *Can J Plast Surg* 2009;17:17-21.
11. Felipe WA, Werneck GL, Santoro-Lopes G. Surgical site infection among women discharged with a drain in situ after breast cancer surgery. *World J Surg* 2007;31:2293-9.
12. Takada R, Jinno T, Koga D, et al. Is drain tip culture prognostic of surgical site infection? Results of 1380 drain tip cultures in total hip arthroplasty. *J Arthroplasty* 2015;30:1407-9.
13. Ahn JS, Lee HJ, Park E, et al. Suction drain tip culture after spine surgery: can it predict a surgical site infection? *Asian Spine J* 2015;9:863-8.
14. Horan TC, Andrus M, Dudeck MA. CDC/NHSN surveillance definition of health care-associated infection and criteria for specific types of infections in the acute care setting. *Am J Infect Control* 2008;36:309-32.
15. Cohen JB, Carroll C, Tenenbaum MM, et al. Breast implant-associated infections: the role of the national surgical quality improvement program and the local microbiome. *Plast Reconstr Surg* 2015;136:921-9.
16. Nguyen MD, Chen C, Colakoglu S, et al. Infectious complications leading to explantation in implant-based breast reconstruction with AlloDerm. *Eplasty* 2010;10:e48.
17. Kobayashi K, Imagama S, Ito Z, et al. Is a drain tip culture required after spinal surgery? *Clin Spine Surg* 2017;30:356-9.
18. Weichman KE, Levine SM, Wilson SC, et al. Antibiotic selection for the treatment of infectious complications of implant-based breast reconstruction. *Ann Plast Surg* 2013;71:140-3.
19. Araco A, Gravante G, Araco F, et al. Infections of breast implants in aesthetic breast augmentations: a single-center review of 3,002 patients. *Aesthetic Plast Surg* 2007;31:325-9.
20. Washer LL, Gutowski K. Breast implant infections. *Infect Dis Clin North Am* 2012;26:111-25.
21. Ahn CY, Ko CY, Wagar EA, et al. Microbial evaluation: 139 implants removed from symptomatic patients. *Plast Reconstr Surg* 1996;98:1225-9.
22. Feldman EM, Kontoyiannis DP, Sharabi SE, et al. Breast implant infections: is cefazolin enough? *Plast Reconstr Surg* 2010;126:779-85.
23. Degnim AC, Scow JS, Hoskin TL, et al. Randomized controlled trial to reduce bacterial colonization of surgical drains

after breast and axillary operations. *Ann Surg* 2013;258:
240-7.

24. Olsen MA, Lefta M, Dietz JR, et al. Risk factors for surgical

site infection after major breast operation. *J Am Coll Surg*
2008;207:326-35.