



Short Communication

Clinical classification of tooth position in the alveolar bone housing with periodontal defects



Yoshiaki Hasegawa ^a, Tadahiro Takayama ^{b,c*}, Yoshihiro Iwano ^d

^a Hasegawa Dental Office, Tokyo, Japan

^b Department of Periodontology, Nihon University School of Dentistry, Tokyo, Japan

^c Division of Advanced Dental Treatment, Dental Research Center, Nihon University School of Dentistry, Tokyo, Japan

^d Iwano Dental Clinic, Tokyo, Japan

Received 21 November 2020; Final revision received 23 November 2020

Available online 7 December 2020

KEYWORDS

Classification;
Alveolar bone housing;
Tooth position;
Periodontal regenerative procedure

Abstract A new classification of tooth position in the alveolar bone housing, which indicates the width of alveolar bone for buccolingual direction, with bone defects caused by periodontal disease is proposed. This classification highlights the importance of tooth position in the alveolar bone housing in terms of the progression of the regenerative process and the factors that may affect the prognosis of compromised teeth after regenerative surgery. Tooth positions were divided into two groups: (i) The whole tooth is centrally positioned in the existing alveolar bone housing (Grade I) and (ii) A part of the tooth is exposed out of the existing alveolar bone housing (Grade II). Grade II is further divided into two subgroups according to situations encountered in clinical practice. The following subclasses are suggested: Subgroup A, where the alveolar bone housing is broader than the tooth, and Subgroup B, where the alveolar bone housing is narrower than the tooth. These subgroups represent a discrepancy between tooth size and alveolar bone dimensions in the buccolingual orientation. This classification could be useful for planning the correct regenerative treatment for each type of the tooth position in the alveolar bone housing with periodontal defects.

© 2020 Association for Dental Sciences of the Republic of China. Publishing services by Elsevier B.V. This is an open access article under the CC BY-NC-ND license (<http://creativecommons.org/licenses/by-nc-nd/4.0/>).

* Corresponding author. Department of Periodontology, Nihon University School of Dentistry, 1-8-13 Kanda-Surugadai, Chiyoda-ku, Tokyo, 101-8310, Japan. Fax: +81 3 3219 8349.

E-mail address: takayama.tadahiro@nihon-u.ac.jp (T. Takayama).

Introduction

Loss of alveolar bone support is one of the characteristic symptoms of destructive periodontal disease and is the anatomical condition resulting from the apical spread of periodontitis caused by invasion of pathogens to periodontal tissues. In particular, regarding the interaction between site-specific progression and the local anatomy, alveolar bone morphology is determined by a variety of factors, including the location of the causative subgingival biofilm on the root surface, complex root anatomic form, the interproximal distance of roots, thickness of the alveolar bone, and root position within the alveolar bone housing which indicates the width of alveolar bone for buccolingual direction.¹ Classifications are generally based on specific morphological criteria and are helpful for diagnosis, treatment planning, and prognosis. Hence, we developed and validated a new classification for the relationship between the position of compromised teeth and alveolar bone housing with periodontal defects. This classification system also includes a proposed treatment recommendation.

According to the classification by Goldman et al.,² intrabony defects are defined by the apical location of the base of the pocket concerning the residual alveolar crest. These defects are of two types: intrabony defects and craters. Intrabony defects have been classified according to their structure in terms of residual bony walls, the width of the defect, and their topographic extension around the teeth. Three-wall, two-wall, and one-wall defects have been defined based on the number of residual alveolar bone walls. These definitions represent the primary classification system. Conditions concomitant with the pathological resorption of bone within the furcation of a multirouted tooth, defined as furcation involvement, are also included in the group of periodontal osseous defects. In different classifications, the extent of horizontal attachment loss was used to define the different degrees or categories of defects. The classification most widely used is that of Hamp et al.,³ which established these classes of furcation involvement.

The abovementioned classifications, however, have not accounted for tooth position in the alveolar bone housing with bony defects. Therefore, we defined the classification of the tooth position in the alveolar bone housing with bone defects. The benefit of this classification was that it supports the clinical criteria used to assess the degree of difficulty of periodontal regenerative surgery for affected teeth and their prognosis.

Classification

Tooth positions were classified as follows:

Grade I (Fig. 1A): The tooth is positioned in the existing alveolar bone housing.

Grade IIA (Fig. 1B): Part of the tooth is outside the existing alveolar bone housing. However, the buccolingual width of the tooth is less than the alveolar bone buccolingual diameter.

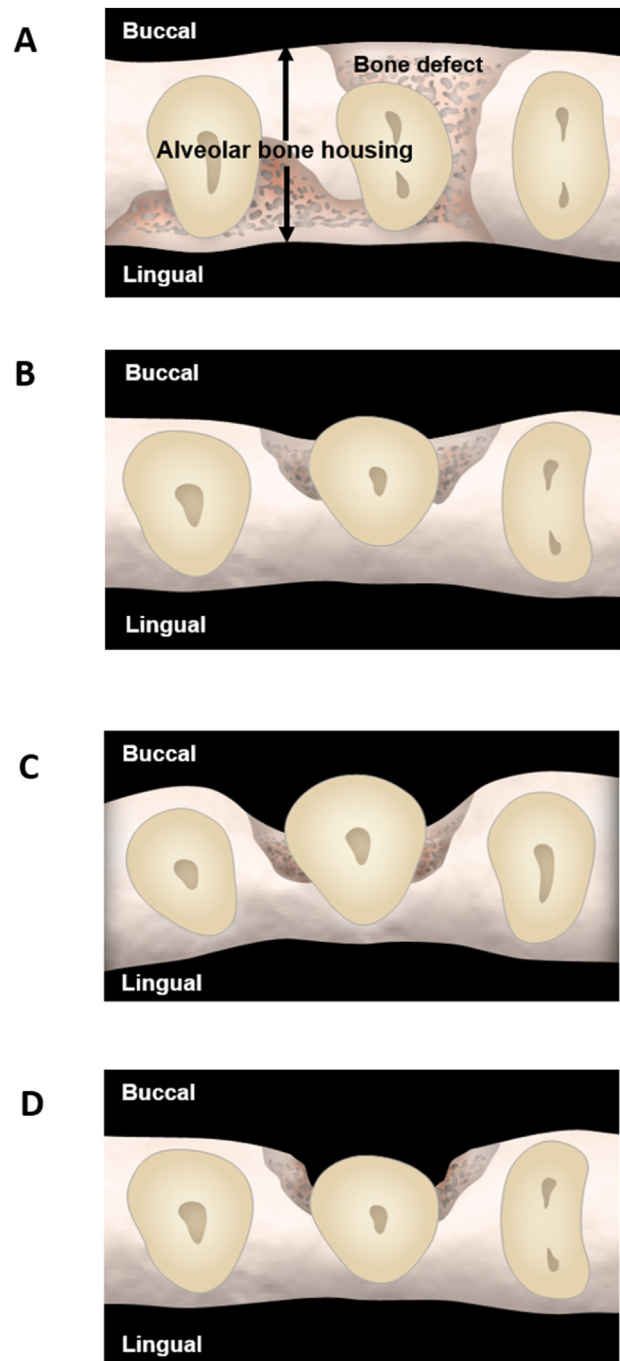


Fig. 1 (A) Diagrammatic occlusal view of a Grade I defect, where the tooth is positioned inside the existing alveolar bone housing. (B) Diagrammatic occlusal view of a Grade IIA defect, where part of the tooth is outside the buccal bone wall and the buccolingual width of the tooth is less than the alveolar bone buccolingual diameter. (C) Diagrammatic occlusal view of a Grade IIB defect, where part of the root is outside the buccal bone wall and the buccolingual width of the tooth is more than the alveolar bone buccolingual diameter. (D) Diagrammatic occlusal view of a Grade IIA defect after orthodontic treatment. The compromised tooth is in the alveolar bone housing.

Grade IIB (Fig. 1C): Part of the tooth is outside the existing alveolar bone housing. However, the buccolingual width of the tooth is more than the alveolar bone buccolingual diameter.

Recommended surgical treatment

Grade I

For teeth that are positioned within the alveolar bone housing, periodontal regenerative treatment is expected to produce favorable results. The morphology of this defect provides an environment ideal for periodontal regeneration and tends to respond positively to regenerative modalities. The outcomes of treatment depend on the rigid space-making properties of the defect itself. Therefore, conventional periodontal regeneration, which includes the use of various of bone grafts and substitutes, guided tissue regeneration (GTR), enamel matrix derivatives, and combinations thereof, is applicable.⁴ It is a general belief that the best grafting material would be autogenous bone because of its osteogenic and osteoinductive properties. Furthermore, autogenous bone grafts have been recommended by many investigators for both periodontal and alveolar bone regeneration procedures.⁵ The clinical selection and application of one or more therapies for periodontal regeneration should be based on the clinician's experiences and understanding of regenerative biology and technology.

Grade IIA

In the first step of treatment, the part of the tooth that is outside of the buccal bone wall is moved into the alveolar bone housing by orthodontic force (Fig. 1D). In this situation, Grade IIA defects can be treated in the same way as treating Grade I defects.

Grade IIB

For these defects, orthodontic treatment is contraindicated because the tooth is greater than the width of existing osseous housing. When teeth are located outside the alveolar bone housing, the defects do not allow for making space because there are no bone walls that ensure room for regeneration. In these situations, nonabsorbable bone particles and a connective tissue graft (CTG) to contain them are recommended to achieve a successful result.

The healing environment of Grade IIB defects is more complicated than those of Grade I or Grade IIA defects. Because space cannot be made for Grade IIB defects, the regeneration procedure must be accurate to ensure sufficient space for periodontal regeneration and protection of graft materials during healing. Therefore, in general, the envelope of bone must be preserved so that the appropriate treatment methods can be chosen, and the extent of such preservation is a significant factor in determining the prognosis for periodontal regeneration.

Numerous bone substitutes, both natural and synthetic, are available for clinical use. Of the natural substitutes,

deproteinized bovine bone (Bio-Oss®; Geistlich Biomaterials, Wolhusen, Switzerland) is widely advocated by scientific literature; it has been tested extensively in vitro and in vivo in many studies ranging from animal preclinical research to human randomized clinical trials. It is conceivable that deproteinized bovine bone may not be completely resorbed, and it seems to be inactive and stable over time and to remain isolated in the bone, marrow, and fibrovascular tissue.⁶ The characteristic of this material is useful for regenerative treatment of non-containing defects, and it can secure space maintenance and maintain formability.

The purpose of supplementing GTR technique with a bone graft, with, or without a biomaterial placed underneath the membrane or a CTG, is to support the graft materials and prevent a collapse of the space so that tissue regeneration can occur.

The use of a CTG as a soft tissue wall has recently been suggested for periodontal regeneration of intrabony defects. The adjunctive clinical efficacy of a CTG placed at the buccal aspect of non-containing defect accompanying a buccal bone resorption, which are highly likely to show a marked root exposure, was demonstrated. The authors described the treatment of intrabony defects associated with compromised roots exposed beyond the buccal bone wall with a surgical technique that combines the use of a CTG and bone filler material as a scaffold inside the intrabony component of the defect.⁷ The beneficial effect of the CTG may partially result from the increase in gingival thickness. Thick gingival tissues exhibit greater resistance to the recession and enhance the quality of plaque control, protection from bacterial aggression, and tissue remodeling after surgical procedures, including regenerative surgery. Also, conversion from a thin to a thick phenotype may have a beneficial effect on the long-term stability of the gingival profile, since thick biotypes were less prone to the development of gingival recession.⁸

Clinical significance of the classification

The proposed classification of tooth position in the alveolar bone housing with periodontal defects allows the evaluation of the following information:

- (1) The real indications for periodontal regenerative procedures. It is possible to plan in advance the quite detailed treatment and presume strict predictability for a regenerative treatment based on the relationship between the tooth position and the features of the defect at the alveolar bone housing.
- (2) The type of periodontal regenerative treatment suited to the tooth position in the alveolar process with bone defects. The classification indicates a choice among many treatment approaches: for Grade I, conventional representative periodontal regenerative procedures; for Grade IIA, an initial movement of the tooth back to the original position in the alveolar bone housing through orthodontic treatment and then proper regenerative therapy at the periodontal defect sites; and for Grade IIB, regenerative treatment for the tooth position (because orthodontic

treatment is contraindicated) and the recommended surgical treatment, which involves the combination of nonabsorbable bone graft materials and a CTG.

- (3) The prognostic guideline for each type of tooth position in the alveolar bone housing with osseous defects.

Conclusion

The proposed classification of tooth position at periodontal defect sites comprises two grades, with two subcategories, that are based on the buccolingual width of the alveolar bone housing. It provides recommendations for selecting the most appropriate treatment protocol.

This classification is based on tooth position in the alveolar bone housing with periodontal defects and is a valid and helpful tool to guide clinicians toward achieving predictable regeneration outcomes.

Declaration of competing interest

The authors have no conflicts of interest relevant to this article.

References

1. Prichard JF. The etiology, diagnosis and treatment of the intrabony defect. *J Periodontol* 1967;38:455–65.
2. Goldman HM, Cohen WD. The infrabony pocket: classification and treatment. *J Periodontol* 1958;29:272–91.
3. Hamp SE, Nyman S, Lindhe J. Periodontal treatment of multi-rooted teeth. Results after 5 years. *J Clin Periodontol* 1975;2:126–35.
4. Caffesse RG, Echeverria JJ. Treatment trends in periodontics. *Periodontol* 2019;79:7–14.
5. Miron RJ, Hedbom E, Saulacic N, et al. Osteogenic potential of autogenous bone grafts harvested with four different surgical techniques. *J Dent Res* 2011;90:1428–33.
6. Hosseinpour S, Ahsaie MG, Rad MR, Baghani MT, Motamedian SR, Khojasteh A. Application of selected scaffolds for bone tissue engineering: a systematic review. *Oral Maxillofac Surg* 2017;21:109–29.
7. Santoro G, Zucchelli G, Gherlone E. Combined regenerative and mucogingival treatment of deep intrabony defects associated with buccal gingival recession: two case reports. *Int J Periodontics Restor Dent* 2016;36:849–57.
8. Müller HP, Eger T. Masticatory mucosa and periodontal phenotype: a review. *Int J Periodontics Restor Dent* 2002;22:172–83.