

# Severe hepatotoxic adverse reaction in a healthy schoolgirl after treatment with flucloxacillin

C-J Törnbage<sup>1</sup>  
G Brunlöf<sup>2</sup>  
S M Wallerstedt<sup>2</sup>

<sup>1</sup>Department of Paediatrics, Central Hospital, Skaraborg, Skövde, Sweden; <sup>2</sup>Department of Clinical Pharmacology, Sahlgrenska University Hospital, Göteborg, Sweden

**Abstract:** This is the first detailed description of a severe hepatotoxic reaction in a previously healthy 9-year-old schoolgirl after ingestion of some flucloxacillin tablets. She was clinically well within one week and alanine aminotransferase in serum was normalized in one month. Follow up for more than one year was normal.

**Keywords:** adverse reaction, children, flucloxacillin, hepatopathy

Due to few pediatric drug safety studies there is limited knowledge on the risks of drug treatment in children. Observations of drug reactions in clinical practice are of importance in the absence of this knowledge. In hospitalized children, the overall incidence of adverse drug reactions (ADRs) has been reported to be 9.5% and the corresponding figure was 1.5% in outpatient children.<sup>1</sup> When vaccine reports are included, the proportion of serious ADRs has been reported to be 13% in children.<sup>1</sup>

Flucloxacillin has been registered in Sweden since 1975. The hepatotoxicity of the substance was first recognized in 1981, when the first case concerning this was reported.<sup>2</sup> The exact mechanism of flucloxacillin-induced liver injury is unknown, but metabolic activation may be of importance<sup>3</sup> and the immune system may be involved, at least in some cases.<sup>4</sup> The incidence has been estimated to 8.5 in 100,000 first-time users.<sup>5</sup>

Today, a total of 348 and 1477 reports concerning suspected hepatotoxicity during flucloxacillin treatment have been registered in the Swedish ADR database (SWEDIS, November 2007) and in the WHO ADR database (VigiBase, November 2007), respectively. In 18 (SWEDIS) and 49 (VigiBase) cases, the outcome was lethal, flucloxacillin deemed to have determined the lethal outcome in seven and 32 cases, respectively.

In total, 37 reports concerning children younger than 18 years during flucloxacillin treatment have been reported previously to VigiBase. However, no description of the course of events is available in this database. Below, we will describe a case in which a young girl experienced a severe hepatotoxic ADR after short treatment of flucloxacillin.

## Case report

A previously healthy nine-year-old girl of 47 kg was successfully treated with penicillin V for the diagnosis cutaneous *Borrelia* infection. Six months later (January 24, 2007), fever, headache and a small wound on the left foot without any known trauma appeared. One tablet of paracetamol 500 mg was ingested. The following day (January 25, 2007), inflammation and lymphangitis in the foot/leg developed. A general practitioner was consulted and cellulitis with *Staphylococcus aureus* was suspected and flucloxacillin 500 mg twice daily was prescribed. No further steps were taken to verify this diagnosis. After ingestion of two tablets of flucloxacillin (January 25, 2007), the patient started

Correspondence: Carl-Johan Törnbage  
Senior Doctor, Neonatologist, NICU,  
Central Hospital, S-651 85 Karlstad,  
Sweden  
Tel +46 05 013 3022  
Mob +46 073 709 3382  
Email carl-johan\_tornbage@hotmail.com

vomiting and experienced diarrhea for three days. Fever appeared the following day (January 26, 2007), persisting for three days (until January 28, 2007) and varying between 37.0 °C and 40.0 °C. The parents noted yellow-colored hands and feet, but no affection of the conjunctiva. On January 28, the patient attended the pediatric hospital. At arrival, the patient was fully conscious. Physical examination revealed no distinct pain of the liver, no palpable hepatosplenomegaly, body temperature 39.6 °C, weight 47.0 kg, breathing rate 16/minute, heart rate 120/minute, oxygen saturation 93%, and blood pressure was 141/63 mmHg (upper limit for age 120/79 mmHg). Laboratory tests showed hemoglobin concentration 138 g/l (>120 g/L), C-reactive protein 13 mg/L (<5 mg/L), white blood cells 4.4 ( $4-10 \times 10^9$ ), neutrophils 62% (35%–65%), eosinophils 0.6% (<6.0%). Liver enzymes are described in Figure 1 and Table 1. International Normalized Ratio (INR) was maximally 1.7 and no clinical symptom of bleeding was present. Serologic tests for cytomegalovirus, Epstein–Barr virus, and hepatitis A and B were negative.

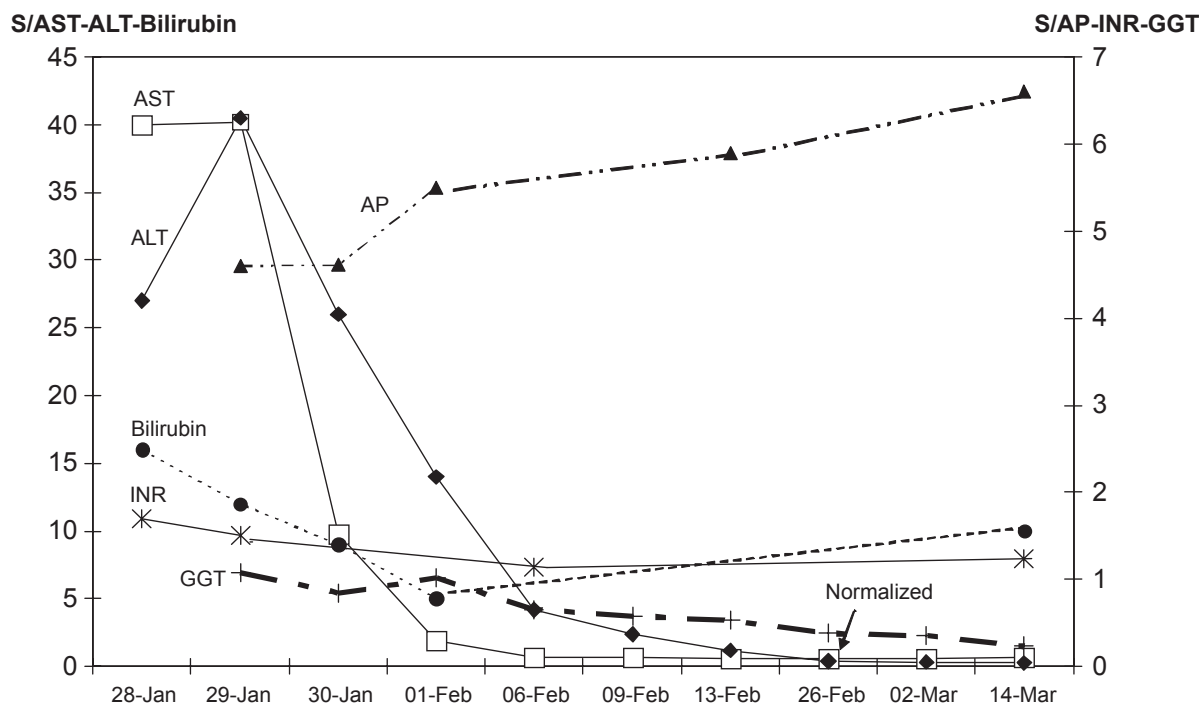
Upon arrival to the hospital, flucloxacillin was withdrawn and no other antibiotic was administered. Hence, a total of 6–7 tablets of flucloxacillin were ingested. No further tablets of paracetamol were administered. The medical

history revealed neither intake of mushrooms or herbal medicines, nor changed eating habits. The patient had not taken any additional medication before hospital care. No tendency for eating carrots could be detected. The patient recovered within a few days with the gastric pain and the lymphangitis disappearing after three days. During a follow-up period of five weeks, the patient was in good condition. At the last examination during January 2008 she was clinically well and laboratory investigation showed normal results.

## Discussion

In the present case report, liver enzymes were elevated following treatment with flucloxacillin in a nine-year-old child. Aspartate aminotransferase (AST) was elevated more than 60-fold, alanine aminotransferase (ALT) more than 50-fold, gamma-glutamyl transpeptidase (GGT) nearly two-fold, whereas alkaline phosphatase (AP) and pancreatic amylase were unaffected. INR was increased to 1.7, indicating a reduced liver function.

Drug-induced hepatotoxicity includes hepatocellular, cholestatic, or mixed reactions. The present report represents a hepatocellular reaction. Flucloxacillin-induced liver injury most often include a cholestatic or a mixed reaction,<sup>6,7</sup>



**Figure 1** Liver enzymes in the present case report.

**Abbreviations:** ALT, alanine aminotransferase; AP, alkaline phosphatase; AST, aspartate aminotransferase; INR, International Normalized Ratio; GGT, gamma-glutamyl transpeptidase.

**Table 1** Liver enzymes in the present case report

	28 Jan	29 Jan	30 Jan	01 Feb	06 Feb	09 Feb	13 Feb	26 Feb	02 Mar	14 Mar
AST (<0.6 $\mu$ kat/L)	40	40.2	9.8	1.9	0.68	0.64	0.54	0.53	0.58	0.67
ALT (<0.75 $\mu$ kat/L)	27	40.5	26	14	4.18	2.39	1.19	0.39	0.33	0.26
Bilirubin (5–25 $\mu$ mol/L)	16	12	9	5						10
GGT (<0.6 $\mu$ kat/L)		1.08	0.84	1.02	0.65	0.58	0.53	0.38	0.35	0.23
AP (0.9–7.2 $\mu$ kat/L)		4.6	4.6	5.5			5.9			6.6
INR (<1.3)	1.7	1.5			1.1					1.2

**Abbreviations:** ALT, alanine aminotransferase; AP, alkaline phosphatase; AST, aspartate aminotransferase; INR, International Normalized Ratio; GGT, gamma-glutamyl transpeptidase.

but hepatocellular reactions have also been reported.<sup>8</sup> The patient had also ingested one tablet of paracetamol corresponding to a single dose of 10 mg/kg which is a low dose. The toxic ADR of paracetamol is predominantly dose-dependent and associated with hepatocellular reactions<sup>7</sup> and depends on the cytochrome P 450-induced toxic metabolite. The production of the metabolite can be modified after ingestion of alcohol,<sup>9</sup> nonsteroid anti-inflammatory drug<sup>9</sup> and during anorectic conditions<sup>10</sup> which not occurred in this case. However, paracetamol can not be excluded from contributing to the reaction. Unfortunately, no serum concentrations of the drugs are available in the present case.

The most frequent drug reported to SWEDIS due to a hepatotoxic reaction is flucloxacillin. In the database, a total of 11 ADR reports with a possible relationship with flucloxacillin concern children, none of which includes a hepatotoxic reaction. The present case represents the first hepatotoxic ADR to flucloxacillin in a child where clinical data is available. Since there is vast under-reporting of ADRs,<sup>10–12</sup> several hepatotoxic reactions to flucloxacillin in children may not have been reported. In conclusion, we invite physicians to increase their attention to hepatotoxic reactions after treatment with flucloxacillin in children.

## Disclosure

The authors report no conflicts of interest in this work.

## References

1. Impicciatore P, Choonara I, Clarkson A, Provasi O, Pandolfini C, Bonati M. Incidence of adverse drug reactions in paediatric in/out-patients: a systematic review and meta-analysis of prospective studies. *Br J Clin Pharmacol.* 2001;52:77–83.
2. Olsson R, Wiholm BE, Sand C, Zettergren L, Hultcrantz R, Myrhed M. Liver damage from flucloxacillin, cloxacillin and dicloxacillin. *J Hepatol.* 1992;15(1–2):154–161.
3. Lakehal F, Dansette PM, Becquemont L, et al. Indirect cytotoxicity of flucloxacillin toward human biliary epithelium via metabolite formation in hepatocytes. *Chem Res Toxicol.* 2001;14:694–701.
4. Andrews E, Daly AK. Flucloxacillin-induced liver injury. *Toxicology.* 2008;254(3):158–163.
5. Russmann S, Kaye JA, Jick SS, Jick H. Risk of cholestatic liver disease associated with flucloxacillin and flucloxacillin prescribing habits in the UK: cohort study using data from the UK General Practice Research Database. *Br J Clin Pharmacol.* 2005;60(1):76–82.
6. de Abajo FJ, Montero D, Madurga M, Garcia Rodriguez LA. Acute and clinically relevant drug-induced liver injury: a population based case-control study. *Br J Clin Pharmacol.* 2004;58:71–80.
7. Bjornsson E, Jerlstad P, Bergqvist A, Olsson R. Fulminant drug-induced hepatic failure leading to death or liver transplantation in Sweden. *Scand J Gastroenterol.* 2005;40(19):1095–1101.
8. Bjornsson E, Kalaitzakis E, Olsson R. The impact of eosinophilia and hepatic necrosis on prognosis in patients with drug-induced liver injury. *Aliment Pharmacol Ther.* 2007;25:1411–1421.
9. Prescott LF, Critchley JA. Drug interactions affecting analgesic toxicity. *Am J Med.* 1983;75(5A):113–116.
10. Moling O, Cairon F, Rimenti G, Rizza F, Pristera R, Miani P. Severe hepatotoxicity after therapeutic doses of acetaminophen. *Clin Ther.* 2006;28(05):1755–1792.
11. Alvarez-Requejo A, Carvajal A, Begaud B, Moride Y, Vega T, Arias LH. Under-reporting of adverse drug reactions. Estimate based on a spontaneous reporting scheme and a sentinel system. *Eur J Clin Pharmacol.* 1998;54:483–488.
12. Backstrom M, Mjorndal T, Dahlqvist R. Under-reporting of serious adverse drug reactions in Sweden. *Pharmacoepidemiol Drug Saf.* 2004;13:483–487.