

Subdural hydatid cyst presenting as recurrent subdural hygroma

AbRAR A. Wani, Altaf U. Ramzan, Furqan A. Nizami, Nayil K. Malik, Bashir Dar, Ashish Kumar

Department of Neurosurgery, Sher-i-Kashmir Institute of Medical Sciences, Srinagar, Jammu and Kashmir, India

ABSTRACT

Intracranial hydatid disease is an uncommon entity that usually is parenchymal in location. Presence of hydatid cyst in subdural location is being reported for the first time in the literature. A 13-year-old female child with the diagnosis of hydatid disease of brain was operated. She was advised to take albendazole which she did not take. In postoperative period she developed recurrent subdural hygroma for which multiple surgical interventions were done and finally cause of recurrent subdural hygroma was found to be hydatid cyst in the subdural space. The patient had initially undergone craniotomy for the excision of hydatid cyst. Later on she developed subdural hygroma for which the burr hole drainage was done twice. At time of third recurrence subduro-peritoneal (SDP) shunt was done. When she had recurrence again along with hydrocephalus, than VP shunt and revision of the SDP shunt was planned. While doing revision of SDP shunt, hydatid cyst was seen emerging from the burr hole site. A craniotomy was done to remove the hydatid cyst from the subdural space. Since then there has been no recurrent collection. Complete surgical excision is the best treatment modality to treat hydatid cyst of brain. Accidental spillage of the contents can have lead to recurrence, so every effort must be taken to prevent spillage of contents. Postoperatively all the patients must be put on antihelminthics.

Key words: Brain, hydatid cyst, recurrence, subdural hygroma

Introduction

Hydatid disease is caused by the larval form of *Echinococcus granulosus*/*Echinococcus multilocularis*. While the dog is the definitive host, sheep, cattle and occasionally humans serve as intermediate hosts. The prevalence of hydatid disease is high, especially in sheep and cattle-raising countries. The ingested ova reach the small intestine, where the liberated embryos penetrate the mucosa, and reach the portal circulation. Later systemic, hematogenous dissemination ensues and it can reach brain.

Intracranial hydatid cysts account for 1-2% of all *Echinococcus granulosus*. In the brain, hydatid cysts are usually confined to the supratentorial compartment; in the region supplied by middle cerebral artery. The parietal lobe^[1] is especially involved, as was the case in our patient in which patient presented with a huge hydatid cyst in left fronto-parietal area [Figure 1]. Hydatid cysts in the brain usually do not calcify. Occasional perifocal edema may be seen; especially in recurrence.^[2] The development of symptoms and neurological deficits is usually late and is due to raised intracerebral tension.

The correct preoperative diagnosis can be established by CT scan and obviates the need for diagnostic aspiration which is hazardous.^[1] The differential diagnoses in a child include abscess, cystic neoplasm and pencephalic cyst. CT scan not only helps in diagnosis with high accuracy, but also identifies the most superficial part of the cyst for a cortical incision and minimizes the risk of rupture at surgery which leads to recurrence. Specific diagnosis is best achieved by histological examination.

The treatment of hydatid cyst is exclusively surgical.^[3] The surgical challenge is to remove the cyst intact. Spillage of its contents can result in anaphylactic shock and the spillage

Access this article online	
Quick Response Code:	Website: www.asianjns.org
	DOI: 10.4103/1793-5482.145336

Address for correspondence:

Dr. Abrar A. Wani, Assistant Professor, Department of Neurosurgery, Sher-i-Kashmir Institute of Medical Sciences, Soura, Srinagar, J and K, India. E-mail: abrarawani@rediffmail.com

of the scolex-bearing fluid may result in dissemination and recurrence of the cyst.

Case Report

A 13-year-old female child presented with the history of seizures and signs of raised intracranial pressure (ICP). CT scan head revealed a huge hypodense cystic mass lesion in left fronto-temporo-parietal region with mass effect as seen [Figure 1]. Patient was operated with the diagnosis of hydatid cyst and whole of the cyst along with its membranes were removed [Figure 2]. Intraoperatively there was accidental spillage of some of the contents of cyst which were thoroughly washed away with saline. Pathological report was that of hydatid cyst and hydatid serology was positive. Chest X-ray and ultrasound abdomen did not reveal any associated cyst. Patient was put on anticonvulsants and albendazole 10 mg/kg was advised for 3 months with serial liver function tests and monitoring. However, the patient stopped the medication after a couple of weeks and did not come for follow-up.

One month following this surgery, patient came back with the history of recurrent vomiting, headache and seizures. CT scan head was done which revealed left fronto-parietal

subdural hygroma collection with mass effect and midline shift with porencephalic cyst at the operative site. There was no communication between the two cavities [Figure 3]. The subdural hygroma was drained, it was clear fluid. The patient developed recurrent collection for which again burr hole drainage and later on a subduro-peritoneal shunt was done. The examination of the fluid revealed absence of infection.

For third time about 1 year later, patient came with history of drowsiness, vomiting and seizures. Patient was admitted and CT scan brain revealed hydrocephalus and recurrent subdural collection. CSF analysis from shunt tap did not show infection [Figure 4]. Plan was made to put a ventriculo-peritoneal shunt on right side and revise the previously placed subduro-peritoneal shunt on left side. While doing the revision shunt on left side, it was found that there was a hydatid membrane pouting out through burr hole. So craniotomy was done and hydatid cyst removed en mass without spillage [Figure 5]. In postoperative period CT scans showed resolution of the SDH as well as decrease in ventricular size [Figure 6]. Due to financial constraints MRI brain could not be done any of the time. Now the patient is on our follow up since last one year and is asymptomatic except for two episodes of generalized seizures for which she is now receiving valproic acid (20 mg/kg).

Discussion

Intracranial hydatid cysts are more frequently located in the supratentorial compartment. The parietal lobe is the most common site.^[1] All the four cases reported by Dharker *et al.*^[4] and three out of five cases of intracerebral hydatid cysts as reported by Balasubramaniam *et al.*^[5] had parietal lobe involvement. In our case the primary hydatid cyst was located in left was located in fronto-parietal area. The other less common sites are skull,^[5] cavernous sinus,^[6] eye ball,^[7] pons,^[8] extradural,^[9] cerebellum and ventricles.^[10] The cerebral hydatid cysts usually grow slowly and present clinical symptoms only when they increase in size and produce mass effect. The growth rate of the hydatid cysts of the brain and has been variably reported between 1.5 and 10 cm/year.^[4,11] CT and MRI revealed round cystic lesions that were isodense and isointense, respectively, to the cerebrospinal fluid (CSF) with no rim enhancement or perifocal edema.

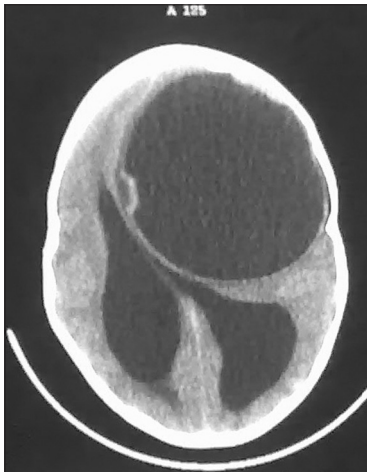


Figure 1: Large fronto-parietal hydatid cyst is seen with significant mass effect and effacement of the lateral ventricles

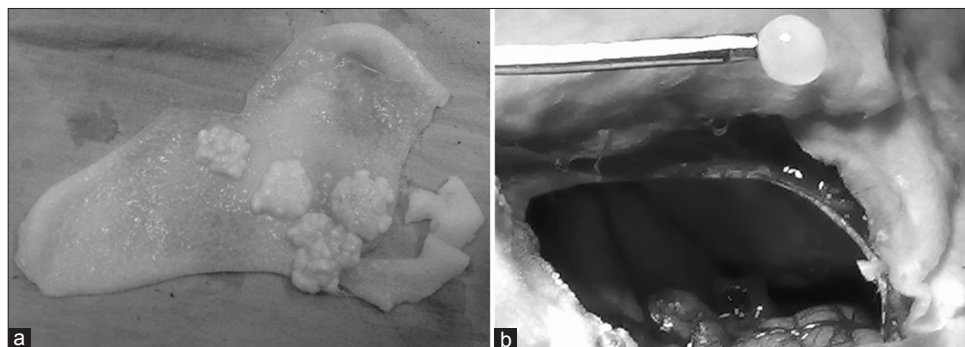


Figure 2: (a) Lamellated membrane with intracystic scolices and (b) Daughter cysts being removed after removal of primary cyst

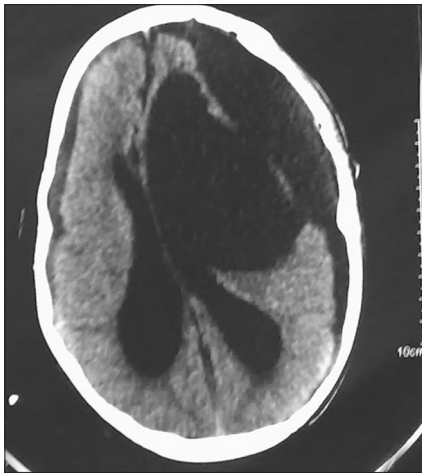

Figure 3: Postoperative CT scan showing subdural hygroma and operative site porencephalic cyst

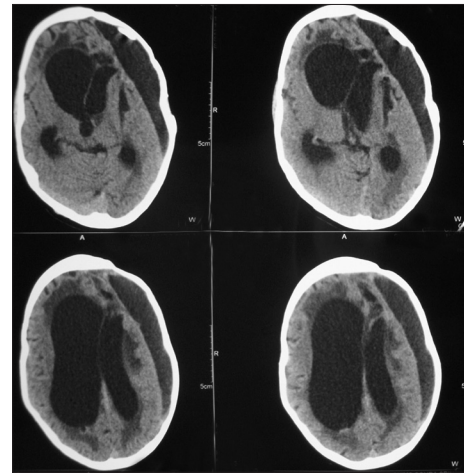


Figure 4: CT scan showing subdural hygroma with hydrocephalous

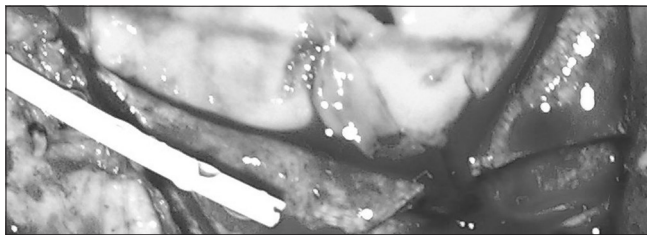


Figure 5: Intraoperative photograph showing hydatid cyst after opening dura

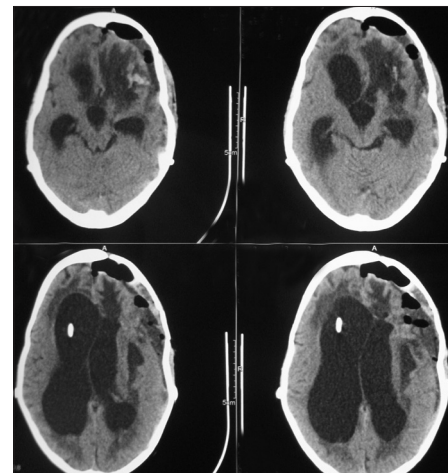


Figure 6: CT scan showing hydrocephalus less than before however porencephalic cyst has completely disappeared and SDH has decreased in volume

Long-term follow-up confirms that intracranial hydatid cysts should always be surgically removed without rupture; the outcome remains excellent in these cases. Correct preoperative diagnosis is vital for the successful outcome of the surgery. A high index of suspicion is therefore required in endemic areas despite the availability of advanced neuroimaging techniques. Novel diagnostic methodologies such as MR spectroscopy and MR diffusion-weighted imaging might help in the diagnosis of intracranial hydatid cysts.^[12] Medical treatment with albendazole seems to be beneficial both pre- and post-operatively.

At present, the most commonly used technique for the removal of these cysts in the brain is the Dowling and Orlando method.^[2,13,14] There have been other techniques proposed, such as Arana-Rodriguez's technique, but these are not frequently implemented.^[15] The essential steps of Dowling's technique are to make a large flap, an opening of the cortex overlying the cyst, with an area having a diameter of no less than three-quarters of the diameter of the cyst, and to allow the cyst to be delivered via gravity by lowering the head of the operating table while injecting warm saline between the cyst and the surrounding brain.^[13]

Solitary intracranial hydatid cysts are common; multiple intracranial cysts are rare. Onal *et al.*^[16] found only three cases of multiple cysts in their series of 33 cases and Lunardi *et al.*^[3]

found two cases in their series of 12 cases. We are reporting this unique case in which patient had recurrent subdural hydatid cyst with multiple small intraparenchymal cysts. After thorough literature review we did not found any other case with this presentation.

The primary cysts are formed as a result of direct infestation of the larvae in the brain without the demonstrable involvement of other organs. The primary cysts are fertile as they contain scolices and brood capsules. Hence, the rupture of primary cyst can result in recurrence as seen in our case report. The secondary cysts results from spontaneous, traumatic or surgical rupture of the primary intracranial hydatid cyst and they lack brood capsule and scolices. The secondary intracranial hydatid cysts are therefore infertile and the resultant risk of recurrence after their rupture is negligible.

Tuzun *et al.*^[17] retrospectively analyzed 25 pediatric patients who underwent surgery for cerebral hydatid cysts over a 16-year period. The complications related to surgical technique

and cyst location were recorded. Postoperative radiological findings of the patients were documented. Intraoperative cyst rupture occurred in three patients. Subdural effusion developed in five patients, pencephalic cyst in four, subdural effusion associated with pencephalic cyst in two, hemorrhage in two, epidural hematoma in one, and pneumocephalus in three patients. Subdural-peritoneal shunt was placed in two patients. Recurrence of cerebral hydatid cyst was observed in only one patient who experienced intraoperative cyst rupture. So the incidence of recurrence in case of cerebral hydatid cyst is very less and the subdural recurrence as seen in our case is extremely rare.

Isolated case reports^[18,19] showed complete disappearance of the multiple intracranial hydatid cysts with albendazole therapy with a daily dose of 10 mg/kg for 4 months. Our patient has missed the initial therapy, which may be the cause of unusual subdural recurrence within one year of surgical removal of primary cyst. Albendazole is a broad spectrum oral anthelmintics drug, which acts by blocking the glucose uptake of the larvae and the adult worm. The glycogen storage is depleted, thereby decreasing the ATP formation that results in the death of the parasite. Golematis *et al.*^[20] analyzed 44 patients who were treated with albendazole and found that the large cysts decreased in the size, while the smaller ones disappeared. Erashin *et al.*^[4] reported better effectiveness of the drug therapy in recurrent cases and in cases with rupture at the surgery.

Conclusions

Recurrence in hydatidosis of brain is unusual; however, every effort must be made to prevent spillage of the cyst contents. Albendazole therapy must be administered in every patient with special emphasis in patients who have developed spillage of cyst contents during surgery.

References

- Sharma SC, Ray RC. Primary hydatid cyst of the brain in an adult: Report of a case. *Neurosurgery* 1991;23:374-6.
- Erşahin Y, Mutluer S, Güzelbağ E. Intracranial hydatid cysts in children. *Neurosurgery* 1993;33:219-24.
- Lunardi P, Missori P, Di Lorenzo N, Fortuna A. Cerebral hydatidosis in childhood: A retrospective survey with emphasis on long-term follow-up. *Neurosurgery* 1991;29:515-7.
- Dharker SR, Dharker RS, Vaishya ND, Sharma ML, Chaurasia BD. Cerebral hydatid cysts in central India. *Surg Neurol* 1977;8:31-4.
- Balasubramaniam V, Ramanujam PB, Ramamurthi B. Hydatid disease of the nervous system. *Neurol India* 1970;18:92-5. The reference is correct and can be seen in pubmed (*Neurol India*. 1970 Dec; 18:Suppl 1:92-5. PMID: 5508116).
- Rivierez M, el-Azhari A, el Tantaoui M, Alaoui M. Hydatid cyst of the cavernous sinus. A case. *Neurochirurgie* 1992;38:46-9.
- Sinav S, Demirci A, Sinav B, Oge F, Sullu Y, Kandemir B. A primary intraocular hydatid cyst. *Acta Ophthalmol (Copenh)* 1991;69:802-4.
- Abbassioun K, Amirjamshidi A, Moinipoor MT. Hydatid cyst of the pons. *Surg Neurol* 1986;26:297-300.
- Bhaskar S, Ajay C, Amit K S. Posterior fossa extradural hydatid cyst with septae and calcification. *Neurol India*. 2012;60(2): 242-243.
- (this has been replaced by above reference from same journal) Jiménez-Mejías ME, Castillo-Ojeda E, Cuello Contreras JA, García Gutiérrez D, Romero Arce J, Pachón Díaz J. Cerebral hydatidosis. Analysis of a series of 23 cases. *Med Clin (Barc)* 1991;97:125-32.
- Seirra J, Oviedo J, Berthier M, Leiguarda R. Growth rate of secondary hydatid cysts of the brain. *J Neurosurg* 1985;62:781-2.
- Ciurea AV, Fountas KN, Coman TC, Machinis TG, Kapsalaki EZ, Fezoulidis NI, *et al.* Long-term surgical outcome in patients with intracranial hydatid cyst. *Acta Neurochir (Wien)* 2006;148:421-6.
- Carrea R, Dowling E Jr, Guevara JA. Surgical treatment of hydatid cysts of the central nervous system in the pediatric age (Dowling's technique). *Childs Brain* 1975;1:4-21.
- Tuzun Y, Kadioglu HH, Izci Y, Suma S, Keles M, Aydin IH. The clinical, radiological and surgical aspects of cerebral hydatid cysts in children. *Pediatr Neurosurg* 2004;40:155-60.
- Arana IR, Rodriguez BR, San Julian J. New technique for removal of cerebral hydatid cyst: Preliminary route [in Spanish]. *Bol Soc Cir Urug*. 1951;22(2):239-50. (this is present in pubmed)
- Onal C, Barlas O, Orakdögen M, Hepgül K, Izgi N, Unal F. Three unusual cases of intracranial hydatid cysts in paediatric age group. *Pediatr Neurosurg* 1997;26:208-13.
- Tuzun Y, Solmaz I, Sengul G, Izci Y. The complications of cerebral hydatid cyst surgery in children. *Childs Nerv Syst* 2010;26:47-51.
- Singounas EG, Laventis AS, Sakas DS, Hadley DM, Lampadariou DA, Karvounis PC. Successful treatment of intracerebral hydatid cysts with albendazole: Case report and review of literature. *Neurosurgery* 1992;31:571-4.
- Todorov T, Vutova K, Petkov D, Balkanski G. Albendazole treatment of multiple cerebral hydatid cysts: Case report. *Trans R Soc Trop Med Hyg* 1988;82:150-2.
- Golematis B, Lakiotis G, Persidou-Golematis P, Bonatsos G. Albendazole in the conservative treatment of multiple hydatid disease. *Mt Sinai J Med* 1989;56:53-5.

How to cite this article: Wani AA, Ramzan AU, Nizami FA, Malik NK, Dar B, Kumar A. Subdural hydatid cyst presenting as recurrent subdural hygroma. *Asian J Neurosurg* 2016;11:322.

Source of Support: Nil, Conflict of Interest: None declared.