

Available online at [www.sciencedirect.com](http://www.sciencedirect.com)

ScienceDirect

journal homepage: [www.elsevier.com/locate/radcr](http://www.elsevier.com/locate/radcr)

## Case Report

# A rare case of co-existing adrenal and pelvic myelolipomas

Dr Qasim Wadood<sup>a,\*</sup>, Dr Saad Ahmad Qureshi<sup>a</sup>, Dr Pavel Singh, Consultant<sup>b</sup>,  
Dr Jonathan Freedman, Consultant<sup>c</sup>

<sup>a</sup>New Cross Hospital, Royal Wolverhampton Trust, Wolverhampton, WV10 0QP, West Midlands, UK

<sup>b</sup>Department of Diagnostic Imaging, National University Hospital, Singapore

<sup>c</sup>Queen Elizabeth Hospital, Birmingham B15 2WB, West Midlands, UK

## ARTICLE INFO

## Article history:

Received 2 January 2018

Revised 20 June 2018

Accepted 8 July 2018

Available online 11 August 2018

## Keywords:

Myelolipoma

Adrenal

Extra adrenal

Liposarcoma

Radiology

## ABSTRACT

We are reporting a case of co-existing left sided pelvic and right sided adrenal myelolipomas in a 68-year-old male patient. Both lesions were incidentally discovered on CT whilst undergoing a staging scan for suspected urinary bladder cancer. The patient had a background of hypertension and type 2 diabetes. Contrast enhanced CT scan showed both lesions to be of mixed fat and soft tissue density. Given the size, location, and attenuation characteristics of the pelvic mass, retroperitoneal liposarcoma was thought to be a differential diagnosis, prompting the decision for an elective CT-guided biopsy. Both masses were targeted successfully using core biopsy needles. Subsequently, histopathology results for both the right adrenal and the left pelvic masses showed features compatible with myelolipomas. The right retroperitoneal mass was compatible with an adrenal myelolipoma and left pelvic mass was deemed as an extra-adrenal myelolipoma (EAML).

© 2018 The Authors. Published by Elsevier Inc. on behalf of University of Washington.

This is an open access article under the CC BY-NC-ND license.

(<http://creativecommons.org/licenses/by-nc-nd/4.0/>)

## Introduction

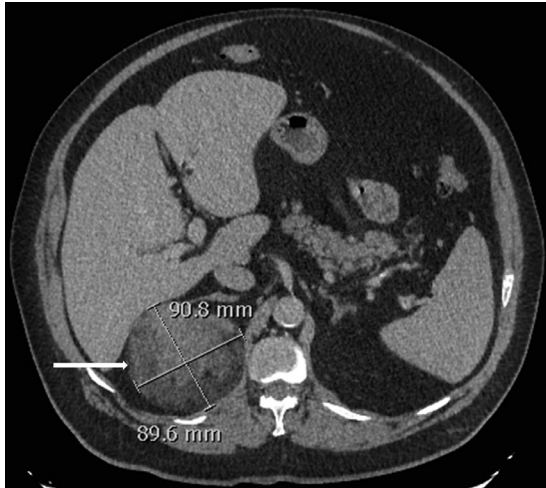
Myelolipomas are rare lesions composed of mature adipose tissue combined with myeloid and erythroid cells. When contained within the adrenal gland, the presence of macroscopic fat on imaging is pathognomonic of an adrenal myelolipoma, which can be confidently diagnosed on cross sectional imaging alone. On the other hand, extra adrenal myelolipomas (EAMLs) are very rare tumors and can be difficult to differenti-

ate from malignant retroperitoneal lesions such as liposarcomas, hence, requiring histopathological confirmation. We are reporting a rare case where an adrenal myelolipoma and an EAML co-existed in a 68-year-old male with a background of hypertension and type 2 diabetes.

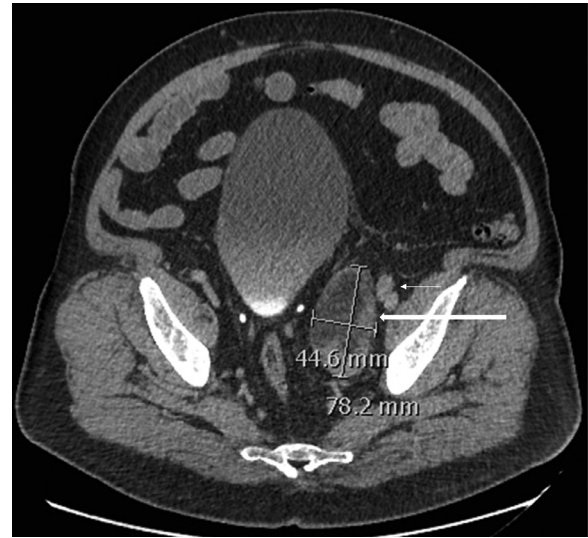
\* Corresponding author.

E-mail addresses: [q.wadood@nhs.net](mailto:q.wadood@nhs.net) (D.Q. Wadood), [saad.qureshi@nhs.net](mailto:saad.qureshi@nhs.net) (D.S.A. Qureshi), [pavel\\_singh@nuhs.edu.sg](mailto:pavel_singh@nuhs.edu.sg) (D.P. Singh).  
<https://doi.org/10.1016/j.radcr.2018.07.008>

1930-0433/© 2018 The Authors. Published by Elsevier Inc. on behalf of University of Washington. This is an open access article under the CC BY-NC-ND license. (<http://creativecommons.org/licenses/by-nc-nd/4.0/>)



**Fig. 1** – Axial section of contrast enhanced CT scan of abdomen showing a 9.1 x 9.0 cm mixed attenuation soft tissue mass with fatty components, arising from right adrenal (white arrow).



**Fig. 2** – Axial section of contrast enhanced CT scan of pelvis showing a 7.8 x 4.5 cm mixed attenuation soft tissue mass with fatty components (thick white arrow), medial to the left external iliac vessels (thin white arrow).

## Discussion

Adrenal lesions greater than 1 cm in size on cross sectional imaging are referred to as ‘incidentalomas’ [1]. With the advancements in modern day imaging they are now detected more frequently. Benign adrenal lesions are found in 3%-10% of the general population, of which non-functioning adrenal adenomas are the majority [2]. Other primary adrenal lesions which are encountered include adrenocortical carcinomas, cysts, myelolipomas, and pheochromocytomas.

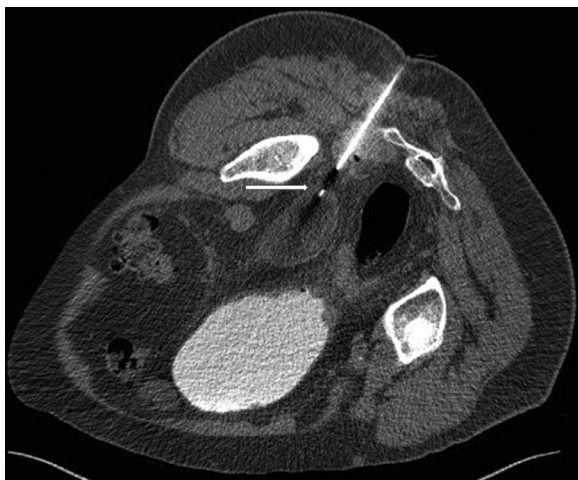Edgar von Gierke in 1905 was the first person to describe myelolipomas [3]. The underlying aetiology has still not completely been established with several theories existing including the fact that they could be remnants of fetal bone marrow, embolism of bone marrow cells, and hyperplasia of heterotopic reticulum cells [4,5]. Although, the diagnosis of an adrenal myelolipoma can be confidently made based on computed tomography (CT) or magnetic resonance imaging (MRI) features alone, because it is the only known entity composed of macroscopic fat in this location [6]. In the case of this patient, cross sectional imaging was accurately used to make a diagnosis of an adrenal myelolipoma (Fig. 1) but due to the size of the mass, a decision was made to conduct a biopsy to provide further clarity on the lesion. The presence of intralesional macroscopic fat is a very characteristic feature for myelolipomas. When using CT, a negative attenuation (between -30 and -90 Hounsfield units) is generated by fatty elements and myeloid components appear higher in attenuation. An encapsulated mass, with macroscopic fatty tissue intermixed with areas of soft tissue that does not invade adjacent structures, strongly suggests the diagnosis of a myelolipoma. As adrenal myelolipomas are asymptomatic lesions of the adrenal cortex and have no malignant potential, surgical management is usually not required. Surgery is generally only recommended for symptomatic patients or when the growth of the mass is

progressive. Small asymptomatic tumors (less than 4 cm) have been suggested to be monitored routinely due to the minimal risk of spontaneous rupture or bleeding [7]. There is no clear consensus about lesion size for which surgery should be considered, with some reporting sizes greater than 4 cm or 7 cm as measurements for which surgery should be done due to higher risks of complications [8,9].

Moreover, approximately 15% of myelolipomas arise as extra adrenal lesions, most commonly in the presacral region [10]. A summary of 37 cases of EAMLs in one report identified the following sites: the presacral space ( $n=15$ , 40.5%), the retroperitoneum ( $n=8$ , 21.6%), the thoracic cavity ( $n=5$ , 13.5%), the pelvic cavity ( $n=3$ , 8.1%), the kidneys ( $n=2$ , 5.4%), the stomach ( $n=1$ , 2.7%), the liver ( $n=1$ , 2.7%), the bladder ( $n=1$ , 2.7%), and multiple lesions ( $n=1$ , 2.7%) [11]. EAMLs are very rare, regardless of the location they are identified at. Since their histological composition is similar to adrenal myelolipomas, they share similar appearances on imaging (Fig. 2).

EAMLs are described as well circumscribed round masses with a size recorded up to 26 cm [9]. A review of the literature has shown that they are more likely to be discovered in middle aged females, with a female to male predominance of 2:1 [12,13]. Akin to myelolipomas, they are often asymptomatic with a good prognosis, hence they may be followed up by CT or MRI imaging. EAMLs have the potential to grow causing symptoms, such as distension, anorexia, and pain. The tumoral mass effect can influence surrounding organs, for example, renal failure from perirenal lesions, sciatic pain or urinary retention in presacral lesions or numbness, and gait disturbance in the case of intraspinal lesions [14,15].

Nevertheless, EAMLs being rare tumors, with limited number of clinical cases reported, can be difficult to establish from imaging alone. Calcification can be used to identify 20% of adrenal myelolipomas and in only a few cases of EAMLs [17,18]. Calcification is hyperdense, often punctate, and it may



**Fig. 3 – Axial section of non-contrast CT scan showing transgluteal, core needle biopsy (white arrow) of fat containing pelvic mass.**

be related to previous hemorrhages [6]. Reported observations suggest that EAMLs have less fat content than adrenal myelolipomas and are less likely to contain calcifications [19]. Presacral myelolipomas can be particularly difficult to differentiate from other retroperitoneal masses too. The presence of fat density on CT imaging usually leads to malignant retroperitoneal tumors with fatty content as the main differential, the most common retroperitoneal fat-containing tumor being a liposarcoma [16]. Hence, EAMLs can present a diagnostic challenge for radiologists and can be misdiagnosed as liposarcomas.

Other differentials for EAMLs include teratomas, extramedullary hematopoiesis, renal angiomyolipomas, and neurogenic tumors. Therefore, conducting a biopsy of EAMLs is justified to obtain a definitive diagnosis, as highlighted by the case presented (Fig. 3).

Several studies have reported the usefulness of CT or ultrasound-guided fine needle biopsy for acquiring complementary diagnostic information [20,21]. This is especially valuable for differentiating EAMLs from other malignant retroperitoneal lesions. Percutaneous fine needle biopsy is simple, safe, and effective. However, clinicians should be aware of the risks of malignant seeding, bleeding, and sampling errors during biopsy procedures. The risks of hemorrhage, rupture, or infection that are associated with biopsy must factor into a clinician's decision to proceed with any invasive diagnostic procedure. EAMLs are such tumors that require tissue samples for definitive diagnosis, and under ultrasound or CT guidance histological samples obtained will demonstrate numerous trilineage haematopoietic cells and variable proportions of mature adipose cells [22].

## Conclusion

In summary, myelolipomas are composed of mature adipose tissue combined with haematopoietic tissue, such as myeloid

and erythroid cells. When contained within the adrenal gland, the presence of macroscopic fat on imaging is pathognomonic of an adrenal myelolipoma which can be confidently diagnosed using cross sectional imaging features alone.

On the other hand, EAMLs are rare tumors and a definitive diagnosis on imaging alone is often challenging. Despite the fact that they are histologically similar to adrenal myelolipomas, it can be difficult to differentiate them from malignant retroperitoneal lesions, most notably liposarcomas. Thus, a core biopsy is a useful complementary investigation which can help provide confirmation of the diagnosis.

## Supplementary materials

Supplementary material associated with this article can be found, in the online version, at [doi:10.1016/j.radcr.2018.07.008](https://doi.org/10.1016/j.radcr.2018.07.008).

## REFERENCES

- [1] NIH state-of-the-science statement on management of the clinically inapparent adrenal mass (“incidentaloma”). *NIH Consens State Sci Statements* 2002;19:1–25.
- [2] Wale DJ, Wong KK, Viglianti BL, Rubello D, Gross MD. Contemporary imaging of incidentally discovered adrenal masses. *Biomed Pharmacother* 2017;87:256–62.
- [3] Oberling C. Les formations myelo-lipomateuses. *Bull Assoc Fr Etud Cancer* 1929;18:234–46.
- [4] Gao B, Sugimura H, Sugimura S, Hattori Y, Iriyama T, Kano H. Mediastinal myelolipoma. *Asian Cardiovasc Thorac Ann* 2002;10(2):189–90.
- [5] Karam AR, Nugent W, Falardeau J, Desai D, Khan A, Shankar S. Multifocal extra-adrenal myelolipoma arising in the greater omentum. *Radiol Case Rep* 2009;3(11):2023.
- [6] Goldman S, Kenney P. The adrenal gland. In: LEE J, editor. *Computed body tomography with MRI correlation*. 4th ed Philadelphia [S1]: Lippincott Williams & Wilkins; 2006. p. 1311–73.
- [7] Kenney PJ, Wagner BJ, Rao P, Heffess CS. Myelolipoma: CT and pathologic features. *Radiology* 1998;208:87–95.
- [8] Daneshmand S, Quek ML. Adrenal myelolipoma: diagnosis and management. *Urol J* 2006;3:71–4.
- [9] Jaiswal P, Saida N, Sen A. Adrenal myelolipoma—a management dilemma. *Indian J Surg Oncol* 2012;3:33–5.
- [10] Patel VG, Babalola OA, Fortson JK, Weaver WL. Adrenal myelolipoma: report of a case and review of the literature. *Am Surg* 2006;72(7):649–54.
- [11] Singla AK, Kechejian G, Lopez MJ. Giant presacral myelolipoma. *Am Surg* 2003;69(4):334–8.
- [12] Kammen BF, Elder DE, Fraker DL, Siegelman ES. Extra adrenal myelolipoma: MR imaging findings. *Am J Roentgenol* 1998;171:721–3.
- [13] George SA, Manipadam MT, Thomas R. Primary myelolipoma presenting as a nasal cavity polyp: a case report and review of the literature. *J Med Case Rep* 2012;6:127.
- [14] Kumar M, Duerinckx AJ. Bilateral extraadrenal perirenal myelolipomas: an imaging challenge. *Am J Roentgenol* 2004;183(3):833–6.
- [15] Orsola A, Raventos C, Trias I, Espanol I, Orsola I. Urinary retention secondary to presacral myelolipoma; first reported case diagnosed by prostate TUR and requiring a cystectomy. *Int Urol Nephrol* 2005;37(4):717–19.

- 
- [16] Tokuyama N, Takeuchi H, Kuroda I, Aoyagi T. Incidental presacral myelolipoma resembling the liposarcoma: a case report and literature review. *Case Rep Urol* 2016;2016:1–3.
- [17] Federle M, Anne V. Adrenal myelolipoma. In: Federle M, editor. *Diagnostic imaging: abdomen*. 1st ed Salt lake: Amirsys; 2004. p. III 2–24–25.
- [18] Vaziri M, Sadeghipour A, Pazooki A, Shoolami LZ. Primary mediastinal myelolipoma. *Ann Thorac Surg* 2008;85(5):1805–6.
- [19] Craig WD, Fanburg-Smith JC, Henry LR, Guerrero R, Barton JH. Fat-containing lesions of the retroperitoneum: radiologic–pathologic correlation. *Radiographics* 2009;29(1):261–90.
- [20] Gill KRS, Hasan MK, Menke DM, Wallace MB. Presacral myelolipoma: diagnosis by EUS-FNA and Trucut biopsy. *Gastrointest Endosc* 2010;71(4):849–50.
- [21] Rao P, Kenney PJ, Wagner BJ, Davidson AJ. Imaging and pathologic features of myelolipoma. *Radiographic* 1997;17(6):1373–85.
- [22] Hakim A, Rozeik C. Adrenal and extra-adrenal myelolipomas-a comparative case report. *J Radiol Case Rep* 2014;8:1–12.