



Arab Journal of Urology
(Official Journal of the Arab Association of Urology)

www.sciencedirect.com



STONES/ENDOUROLOGY

ORIGINAL ARTICLE

**Percutaneous unroofing of renal simple cysts:
Experience from one centre**

Ali Tehranchi, Sepehr Hamedanchi *, Afshin Badalzadeh

Department of Urology, Imam Medical Centre, Urmia University of Medical Sciences, Ershad Blvd, Urmia, Iran

Received 3 June 2011, Received in revised form 7 July 2011, Accepted 8 July 2011

KEYWORDS

Decortication;
Percutaneous resection;
Simple renal cyst;
Unroofing

ABBREVIATIONS

PU, percutaneous unroofing;
US, ultrasonography

Abstract Objective: To assess the efficacy of percutaneous unroofing (PU) for treating simple renal cysts, compared with laparoscopic decortication and open surgery.

Patients and methods: From November 2009 to October 2010, 11 patients with 12 simple cysts in renal units were managed by PU. All cysts were evaluated with ultrasonography and abdominal computed tomography. A standard transurethral resectoscope was used to resect the cyst wall, and the parenchymal portion of the cyst was subsequently cauterised. A drain was left in place for 2 days. Success was defined as a > 50% reduction in cyst diameter.

Results: At the 5-month follow-up, patients were asked about their symptoms and assessed by ultrasonography. Of the 12 cyst units, eight were completely resolved, three were reduced to < 50% in diameter and one was persistent, close to the original size.

Conclusion: Simple renal cysts can be managed safely by PU, with a success rate of > 90%. This technique offers several advantages over open surgery, with a shorter hospital stay, improved convalescence and reduced risk of complications. PU also avoids the multiple trocar sites, extensive dissection, and technical difficulty associated with laparoscopy.

© 2011 Arab Association of Urology. Production and hosting by Elsevier B.V. All rights reserved.

Introduction

Renal cysts are common benign lesions of the kidney, estimated to occur in $\geq 24\%$ of individuals aged > 40 years and

50% of those aged > 50 years [1]. The incidence is $\approx 10\%$ in the general population, and the prevalence increases with age [2]. With the recent widespread and increased use of abdominal cross-sectional radiographic imaging, the incidence of asymptomatic renal cysts is probably higher than previous estimates. Most renal cysts are simple, asymptomatic, and of unknown aetiology. However, some patients develop abdominal and/or

* Corresponding author. Tel.: +98 9144412600.

E-mail address: sepehrhamedanchi@yahoo.com (S. Hamedanchi).



flank pain, haematuria, hypertension, recurrent infection, or obstructive uropathy as a result of a renal cyst [3].

Fortunately, in most patients, for an asymptomatic simple renal cyst an intervention is unnecessary unless symptoms or complications develop. A cyst can be decompressed by percutaneous aspiration with or without sclerosis, open surgery, antegrade or retrograde endoscopic marsupialisation and laparoscopic decortication. Percutaneous unroofing (PU) is a novel technique in the treatment of simple renal cysts; we assessed the efficacy of PU for treating simple renal cysts, compared with laparoscopic decortication and open surgery.

Patients and methods

From November 2009 to October 2010, in our department, 11 patients (eight men and three women; mean age 59 years, range 47–78) with 12 simple renal cyst units were managed by PU. The indications for intervention included flank and/or abdominal pain in seven, recurrent infection in two, hypertension secondary to cyst compression of renal parenchyma in one and segmental hydronephrosis secondary to cyst encroachment on the renal collecting system in one patient.

All cysts were evaluated with ultrasonography (US) and abdominal CT (Fig. 1). If there was no contraindication, such as malignancy risk, abscess, pyonephrosis, peri-pelvic location and coagulopathy, the cyst wall was resected. To diagnose a benign simple cyst on US it should have a sharply defined, thin distinct smooth wall, be spherical or oval with no internal echoes, and have good transmission of sound waves, with acoustic enhancement behind the cyst (class I in the Bosniak classification) [4].

Under general anaesthesia and with the patient prone, before resection was attempted the cyst was punctured percutaneously under US guidance using a subcostal approach, and aspirated for cytological examination and creatinine measurement. If the obtained fluid was consistent with a benign cyst, and there was no communication with the renal collecting system, a guidewire was placed and the tract was dilated with a metal coaxial dilator up to 30 F adjacent to the exophytic portion of the cyst.

The nephroscope was placed adjacent to the cyst in an extra-parenchymal location. A hydro-dissection technique with irrigation fluid (distilled water) was used to make a proper

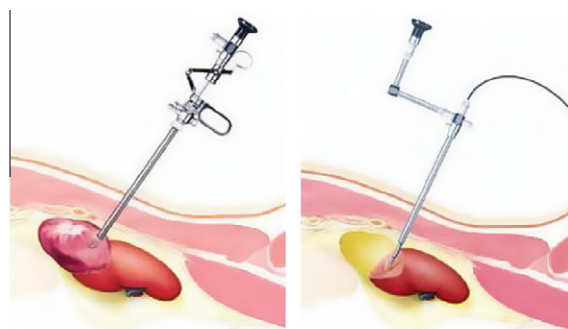

Figure 2 PU of a simple renal cyst using a resectoscope.

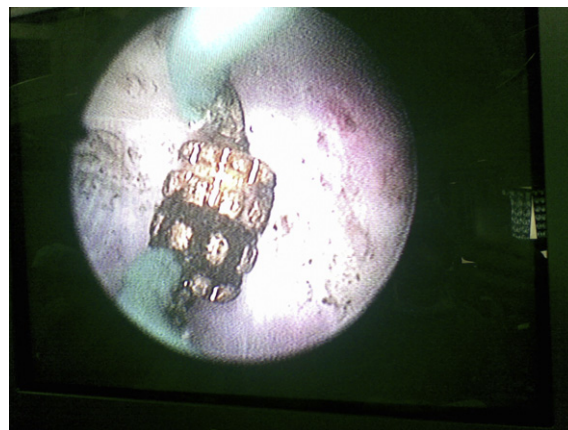


Figure 3 Intra-operative view of cauterising the parenchymal portion of the cyst.

plane between the extra-parenchymal portion of the cyst wall and surrounding structures. The nephroscope was then inserted into the exophytic portion of the cyst following the guidewire and the interior cyst wall was inspected. If there was no abnormality, a standard transurethral resectoscope was used to resect the exophytic portion of the cyst wall and the parenchymal portion of the cyst was subsequently cauterised (Figs. 2 and 3). A 26 F drainage tube was left in place for 2 days. Patients were discharged on the second day after the drains were removed.

Results

Of the 12 cysts, seven were in the right kidney and five in the left; none were in a peri-pelvic position, three were in the lower pole, six in the mid-portion and three in the upper pole. The median (range) cyst diameter was 92 (65–130) mm. All the cysts were primary and there were no previous interventions. The preoperative evaluation with US and CT categorized all the cysts as class I Bosniak. The longest resection was 70 min and the mean operative duration was 45 min.

There was no major complication such as bleeding, urinary leakage, adjacent organ injury or parenchymal damage. At the 5-month follow-up patients were asked about their symptoms and were assessed by US. Of the 12 cyst units, eight were completely resolved, three were reduced to < 50% in diameter and one was persistent, close to the original size. Six of seven patients with preoperative pain reported a significant improvement and the remaining one felt moderate pain. None of the

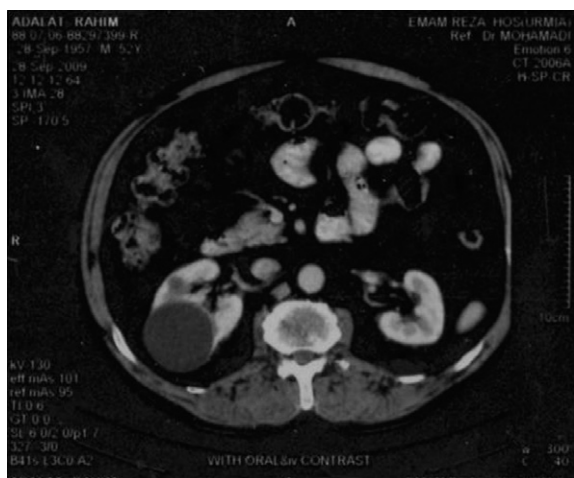


Figure 1 CT of a right simple renal cyst.

patients had a UTI during the follow-up. The patient who had hypertension did not benefit from surgery, and upper pole hydronephrosis was resolved in the last patient.

Discussion

The principles of managing renal simple cysts are based on eliminating clinical symptoms and preventing complications such as bleeding, infection and conditions secondary to cyst encroachment on the renal parenchyma and collecting system. The open surgical exploration of renal cysts has been reported since the early 1900s. One of the earliest descriptions of open surgical management of renal cysts was by Kretschmer in 1920 [5]. Of 35 patients who were explored through flank or abdominal incisions, 18 had resection of a renal cyst, 16 required nephrectomy, and in one patient the cyst was marsupialised. Because the surgical treatment of a benign condition such as a renal cyst did not generally require organ extirpation, but rather only excision of the cyst wall and evacuation of its fluid contents, less invasive means of treating symptomatic renal cysts without requiring a large flank or abdominal incision were sought. Open renal cyst ablation remained the standard approach until the late 1980s, when minimally invasive methods were introduced.

In 1989, Holmberg and Hietala [6] described percutaneous puncture and drainage of peripheral renal cysts under local anaesthesia, followed by instillation of bismuth phosphate as a sclerosant. Many agents have reportedly been used for this purpose, including glucose, phenol, ethanol, iophendylate, morrhuate sodium, lipidol, povidone-iodine, tetracycline, *n*-butyl cyanoacrylate, laurith 9 (also called polidocanol), and bismuth phosphate [7,8]. Although the short-term success rate was high, limitations of this technique included a high recurrence rate (54%) and the risk of collecting system strictures as a result of scarring caused by the sclerosing agent, making this technique ill-advised for cysts located in the peri-pelvic region [9].

Hulbert et al. [10] presented the first description of the advantages of laparoscopic decortication of symptomatic renal cysts in 1992. This technique included the ability to address multiple, peri-pelvic and bilateral renal cysts in a single operation by both the transperitoneal and retroperitoneal approaches. Numerous series of laparoscopic ablation of symptomatic simple renal cysts were published [11,12]. The mean (range) operative duration was 111 (75–164) min and the mean hospital stay was 3 days. A complication rate of 0–20% (mean 3.5%) and no mortality in these series compares favourably with historical series of open renal cyst ablation, reporting a complication rate of 37% and mortality rate of 1.6% [13].

The success of laparoscopic renal cyst ablation, as defined by relief of symptoms (symptomatic success), averaged 97% when comparing all series, with 92% of patients showing no evidence of cyst recurrence on follow-up imaging studies (radiographic success).

Endoscopic retrograde marsupialisation for treating simple renal cysts, using a flexible ureteroscope, has been described, but there are many limitations to this technique, because it is technically difficult, limited to peri-pelvic cysts, and needs a second procedure to remove the ureteric stent.

PU is another method under development for managing symptomatic renal cysts. Gelet et al. [14] described six cases of symptomatic benign renal cysts in which a standard transurethral resectoscope was used to resect the cyst wall. At the

follow-up four of these six patients had no recurrence on imaging studies, and all were asymptomatic. Plas and Hübner [15] reported a series of 10 patients who had a long-term follow-up after percutaneous resection. At a mean (range) follow-up of 46 (26–66) months, five were cyst-free, two had residual cysts and three had developed a distinct new cyst. All 10 patients were asymptomatic.

In the present study, in eight of the 12 cyst units there was no recurrence, in three there were residual cysts and in one the operation failed at the 5-month follow-up. All of the patients were symptom-free and there was radiological success in 11 of 12 cysts.

In conclusion, the limitations of PU include the inability to access antero-medial cysts without compromising renal parenchyma, and the theoretical risk associated with systemic fluid absorption. PU offers several advantages over open surgery, with a possibly shorter hospital stay, improved convalescence and reduced risk of complications. PU also avoids multiple trocar sites, extensive dissection, and the technical difficulty associated with laparoscopy. In addition, instruments are used that are familiar to the urologist.

Conflict of Interest

The authors have no conflict of interest to declare.

References

- [1] Laucks SP, McLachlan MS. Aging and simple cysts of the kidney. *Br J Radiol* 1981;**54**:12–4.
- [2] McAninch JW. Disorders of the kidneys. In: Tanagho EA, McAninch JW, editors. *Smiths general urology*. 17th ed. McGraw Hill; 2008. p. 510–1.
- [3] Amar AD, Das S. Surgical management of benign renal cysts causing obstruction of the renal pelvis. *Urology* 1984;**14**:429–33.
- [4] Bosniak M. The current radiological approach to renal cyst. *Radiology* 1986;**158**:110.
- [5] Kretschmer HL. Solitary cysts of the kidney. *J Urol* 1920;**iv**:567–83.
- [6] Holmberg G, Hietala SO. Treatment of simple renal cysts by percutaneous puncture and instillation of bismuth-phosphate. *Scand J Urol Nephrol* 1989;**23**:207–12.
- [7] Ohta S, Fujishiro Y, Fuse H. Polidocanol sclerotherapy for simple renal cysts. *Urol Int* 1997;**58**:145.
- [8] Phelan M, Zajko A, Hrebinko RL. Preliminary results of percutaneous treatment of renal cysts with povidone-iodine sclerosis. *Urology* 1999;**53**:816.
- [9] Su Li-Ming. Laparoscopic renal cyst ablation. In: Gill IS, editor. *Textbook of laparoscopic urology*. 1st ed. Informa Healthcare; 2006. p. 259.
- [10] Hulbert JC, Shepard TG, Evans RM. Laparoscopic surgery for renal cystic disease. *J Urol* 1992;**147**(Suppl.):443 [abstract 882].
- [11] Rubenstein SC, Hulbert JC, Pharand D, Schuessler WW, Vancaillie TG, Kavoussi LR. Laparoscopic ablation of symptomatic renal cysts. *J Urol* 1993;**150**:1103–6.
- [12] Roberts WW, Bluebond-Langner R, Boyle KE, Jarrett TW, Kavoussi LR. Laparoscopic ablation of symptomatic parenchymal and peripelvic renal cysts. *Urology* 2001;**58**:165–9.
- [13] Kropp KA, Grahack JT, Wendel RM, Dahl DS. Morbidity and mortality of renal exploration for cyst. *Surg Gynecol Obstet* 1967;**125**:803–6.
- [14] Gelet A, Sanseverino R, Martin X, Leveque JM, Dubernard JM. Percutaneous treatment of benign renal cysts. *Eur Urol* 1990;**18**:248–52.
- [15] Plas EG, Hübner WA. Percutaneous resection of renal cysts: a long-term followup. *J Urol* 1993;**149**:703–5.