



Contents lists available at ScienceDirect

International Journal of Surgery Case Reports

journal homepage: www.casereports.com

Adventitial cystic disease of the popliteal artery treated by bypass graft utilizing the short saphenous vein: A case report



Katsunori Miyake*, Naoki Sawamura, Yuki Ikegaya, Naoko Isogai, Jun Kawachi, Rai Shimoyama, Ryuta Fukai, Hiroyuki Kashiwagi, Hidemitsu Ogino

Department of Surgery, Shonan Kamakura General Hospital, 1370-1 Okamoto, Kamakura, Kanagawa 247-8533, Japan

ARTICLE INFO

Article history:

Received 4 April 2017

Received in revised form 15 July 2017

Accepted 15 July 2017

Available online 20 July 2017

Keywords:

Cystic disease

Popliteal artery

Bypass graft

Short saphenous vein

ABSTRACT

INTRODUCTION: Adventitial cystic disease is relatively rare vascular disease, frequently occurred in the popliteal artery. No definitive treatment has been established yet.

PRESENTATION OF CASE: A 53-year-old woman presenting intermittent claudication of the right leg was diagnosed as adventitial cystic disease of popliteal artery. Percutaneous balloon dilation yielded an immediate recurrence. The disease was successfully treated by bypass grafting utilizing the short saphenous vein to replace the part of the popliteal artery containing the adventitial cyst. No postoperative complication was found six months after surgery.

DISCUSSION: Comparing to a great saphenous vein, a short saphenous vein as a material of bypass graft has a significant advantage, as only a single surgical field is necessary.

CONCLUSION: We propose that bypass graft surgery employing a short saphenous vein is worth considering as a treatment of adventitial cystic disease at the popliteal artery.

© 2017 The Authors. Published by Elsevier Ltd on behalf of IJS Publishing Group Ltd. This is an open access article under the CC BY-NC-ND license (<http://creativecommons.org/licenses/by-nc-nd/4.0/>).

1. Introduction

Adventitial cystic disease (ACD), first reported by Atkins et al. in 1947 [1], is a non-arteriosclerotic disease accompanied by ischemic symptoms of the lower limbs. ACD is caused by stenosis or occlusion of the blood vessel compressed by the cyst that was arising from the adventitial wall. As the arterial stenosis frequently occurs in the lower extremity, intermittent claudication is a common symptom of ACD. This disease commonly occurs unilaterally, which accounts for approximately 90% of cases of ACD and is usually found in young men [2]. The etiology is still unknown, although there are several hypotheses, such as dysplasia during fetal development [3], repeated injury [4], and synovial tissue intrusion into the arterial wall [5]. No definite treatment has been established yet, while various approaches have been tried to cure ACD [6]. In this report, we provide the successful result of a novel approach to treat and cure ACD, utilizing the short saphenous vein as a material of bypass graft.

2. Presentation of case

Diagnosis: Our patient was a 53-year-old nonsmoking woman, who had a history of right breast carcinoma. She also showed intermittent claudication of the right leg during the last 6 months.

Percutaneous balloon dilatation was performed in another institution, resulted in an instant recurrence within one week. While ankle brachial pressure index (ABI) was normal (1.13/1.13), computed tomography (CT) scan with contrast indicated popliteal artery stenosis due to cystic lesion (Fig. 1a and b). Thus, the patient was diagnosed with ACD of the right popliteal artery.

Surgical procedure: We marked the short saphenous vein when the patient was in a prone position (Fig. 2a), as we intended to employ a small piece of the short saphenous vein in this bypass grafting surgery. Note that the blood vessel we picked up had no stenosis or thrombosis. At surgery, it was revealed that the right popliteal artery had been compressed by an adventitial cyst (2 × 1 × 1 cm) (Fig. 2b). In the same surgical field, we obtained the short saphenous vein in the length of approximately 3 cm, ran into the popliteal vein. The lesional popliteal artery including the adventitial cyst was resected and then replaced by the short saphenous vein (Fig. 2c). The resected tissue of the adventitial cyst was unilobular, filled with high-viscosity mucus. The cyst developed around the popliteal artery semi-circumferentially (Fig. 2d).

Postoperative course: The patient could walk one day after surgery. She was discharged home on the postoperative day 4th. Intermittent claudication disappeared, and the patient was able to walk 10 km without a rest one month after surgery. No recurrence of stenosis or cyst has been found by CT scan 6 months after operation (Fig. 1c).

* Corresponding author.

E-mail address: kmiyake17@gmail.com (K. Miyake).

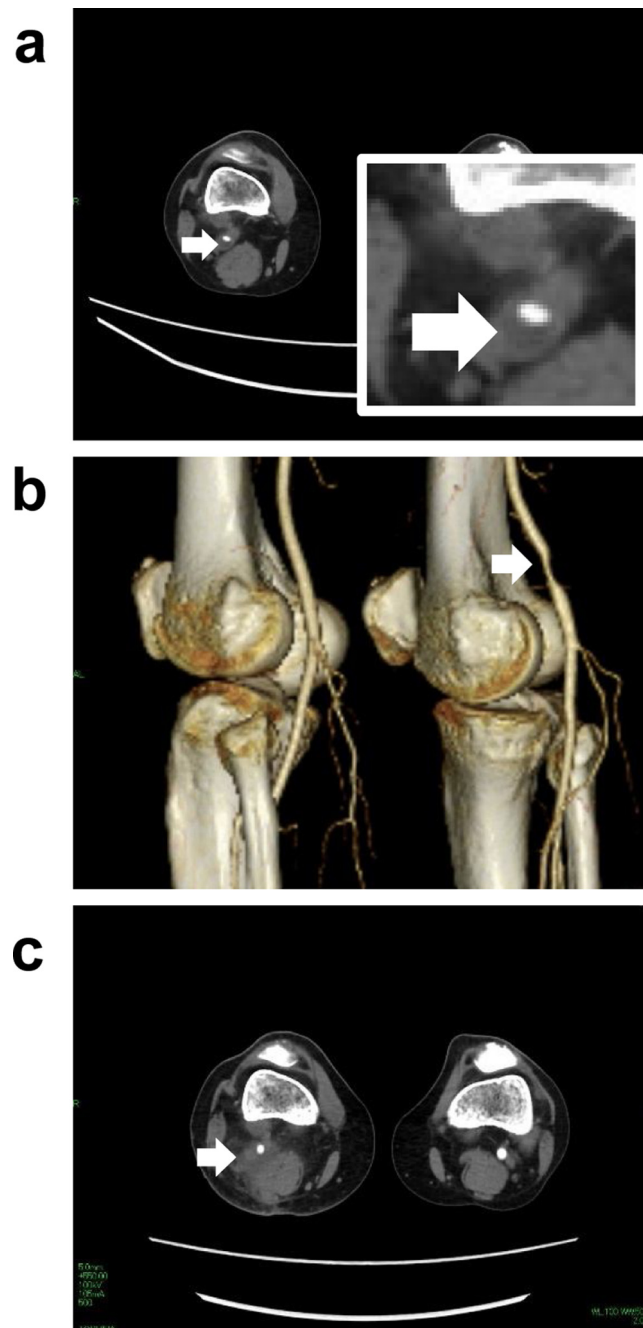


Fig 1. Pre- and post-operative CT scan images show pathogenesis and cure of adventitial cystic disease. (a) Preoperative axial CT image shows that the developed cystic lesion was compressing the popliteal artery of the right leg (indicated by white arrowhead). Inset, CT image enlarged at the cystic lesion. (b) Reconstituted three-dimension CT image apparently demonstrates the stenosis of the right popliteal artery (white arrowhead). (c) Postoperative CT image indicates no recurrence of the cyst (white arrowhead) six months after surgery.

3. Discussion

We report a case of the patient with adventitial cystic disease of the popliteal artery, who had an immediate recurrence after endovascular treatment. The disease was successfully treated by vascular surgery employing an autologous short saphenous vein.

In order to choose adequate treatment, it is crucial to distinguish ACD from other diseases presenting similar symptoms, such as arteriosclerosis obliterans, Buerger's disease, and popliteal artery entrapment syndrome. Toward this end, CT or MRI scan is of value in the differential diagnosis of adventitial cystic disease, in which hourglass-like or crescent-shape image indicates the culprit vessel

compressed by cystic lesion. On the other hand, angiography or ABI is less conclusive, as it would be difficult to distinguish ACD from other stenotic diseases. Indeed, our patient showed normal preoperative ABI, and thus a definitive diagnosis was based on a CT scan with contrast.

Arterial stenosis of our patient was initially treated by balloon dilation, resulted in an immediate recurrence. It should be noted that surgery is generally the first line in the treatment of ACD, though a definitive therapy has not been established yet. Imaging diagnosis of CT indicated that the cause of the arterial stenosis was compression of the blood vessel by the adventitial cyst. We assume, therefore, that balloon dilation of the vessel was insufficient to

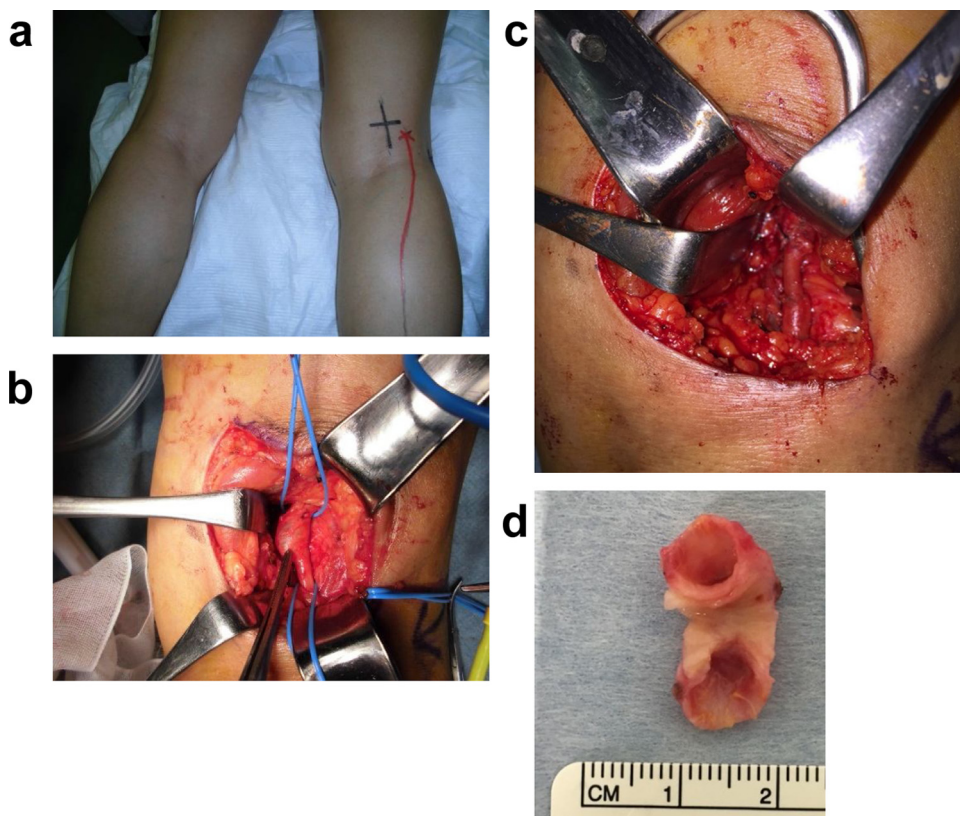


Fig. 2. Operative views including surgical fields of the cystic lesion at the popliteal artery. (a) Before surgery, the site of the adventitial cyst (black cross) and the short saphenous vein (red line) were directly marked on the surface of the skin in a prone position. (b) At surgery, adventitial cyst at the popliteal artery exhibits severe adhesion to neighboring tissues. (c) The popliteal artery developing the cyst was resected and was replaced by the short saphenous vein. The length of the blood vessel including the cyst was approximately 2 cm. (d) Resected popliteal artery revealed that the cyst was unilobular, filled with high-viscosity mucus, and developed around the popliteal artery semi-circumferentially.

secure blood flow, ended up with postoperative recurrence. This notion is supported by previous literatures reporting the cases in which surgery was eventually required after balloon dilation treatment [2,7]. After all, treatment of the cyst is definitely necessary to cure the symptoms of ACD including intermittent claudication. Consequently, surgery should be considered first to treat with vascular stenosis and occlusion in the case of ACD.

In surgical treatment, there are two options – bypass grafting or not. Cystectomy accompanied by excision of the popliteal artery requires either bypass grafting or blood vessel prosthesis implantation [6]. Alternatively, the popliteal artery can be restored without bypass grafting after removal of the cyst. Although the latter strategy is simple and less invasive, the former one yields better prognosis in terms of arterial patency [8].

The patient described in this report was treated by cystectomy followed by bypass grafting, because the expanded cyst wall extended to the entire circumference of the lumen of the artery at the cystic lesion. We employed an autologous vein as a graft in this case, rather than an artificial blood vessel. While a great saphenous vein has been frequently used in autogenous vein bypass grafting, two surgical fields and intraoperative postural changes are required to prepare a great saphenous vein graft, which is relatively demanding. Therefore, we employed a short saphenous vein, and not the great saphenous vein, in bypass grafting in this patient. The short saphenous vein runs into the popliteal vein just next to the popliteal artery. Thus, one of the major advantages utilizing a short saphenous vein is that graft preparation and implantation can be performed in the same surgical field, which is far less invasive. Since the short saphenous vein is narrower than the great saphenous

vein, our concern was possible stenosis at the bypass grafting site. Fortunately, no complication has occurred during the last six months since surgery. We believe that the short saphenous vein grafting implies a wide application to treat with a variety of vascular diseases.

Our patient did not show any recurrence at the time of six months after surgery. It has been reported, however, that approximately 10% of patients had recurrence of the cyst [9] around the vein graft [10]. Therefore, a long-term follow up is necessary even in our patient. Nonetheless, we propose that bypass graft surgery employing a short saphenous vein deserves for a promising option as a treatment of adventitial cystic disease at the popliteal artery.

This case report has been reported in line with the SCARE criteria [11].

Conflict of interest

We have nothing to declare regarding the conflicts of interest.

Funding

None.

Ethical approval

Ethical Committee in Shonan Kamakura General Hospital has approved this case report.

Consent

The patient approved and we obtained written consent form with signature for publication of this case report and accompanying images.

Authors contribution

KM designed the study concept, performed surgery, interpreted the data, and wrote the manuscript. NS, YI, NI, JK, RS, RF, HK, and HO significantly contributed to obtain the clinical data.

Guarantor

Katsunori Miyake.

References

- [1] H.J. Atkins, J.A. Key, A case of myxomatous tumour arising in the adventitia of the left external iliac artery; case report, *Br. J. Surg.* 34 (1947) 426.
- [2] M. Jarraya, S. Simmons, A. Farber, O. Teytelboym, N. Naggara, A. Guermazi, Uncommon diseases of the popliteal artery: a pictorial review, *Insights Imaging* 7 (2016) 679–688.
- [3] H. Nicolau, S. Calen, J.C. Gourul, H.P. Stoiber, M. Cesarini, J. Videau, Adventitial cysts of the popliteal artery, *Ann. Vasc. Surg.* 2 (1988) 196–198.
- [4] P.B. Bliss, Cystic myxomatous degeneration of the popliteal artery, *Am. Heart J.* 68 (1964) 838–839.
- [5] G.D. Jay, F.L. Ross, R.A. Mason, F. Giron, Clinical and chemical characterization of an adventitial popliteal cyst, *J. Vasc. Surg.* 9 (1989) 448–451.
- [6] A.R. Baxter, K. Garg, P.J. Lamparello, F.F. Mussa, N.S. Cayne, T. Berland, Cystic adventitial disease of the popliteal artery: is there a consensus in management? *Vascular* 19 (2011) 163–166.
- [7] P.W. van Rutte, E.V. Rouwet, E.H. Belgers, R.F. Lim, J.A. Tejjink, In treatment of popliteal artery cystic adventitial disease, primary bypass graft not always first choice: two case reports and a review of the literature, *Eur. J. Vasc. Endovasc. Surg.* 42 (2011) 347–354.
- [8] I.A. Tsolakis, C.S. Walvatne, M.D. Caldwell, Cystic adventitial disease of the popliteal artery: diagnosis and treatment, *Eur. J. Vasc. Endovasc. Surg.* 15 (1998) 188–194.
- [9] D. McAnespey, R.C. Rosen, J.M. Cohen, K. Fried, S. Elias, Adventitial cystic disease, *J. Foot Surg.* 30 (1991) 160–164.
- [10] T. Ohta, R. Kato, I. Sugimoto, M. Kondo, H. Tsuchioka, Recurrence of cystic adventitial disease in an interposed vein graft, *Surgery* 116 (1994) 587–592.
- [11] R.A. Agha, A.J. Fowler, A. Saeta, I. Barai, S. Rajmohan, D.P. Orgill, et al., The SCARE statement: consensus-based surgical case report guidelines, *Int. J. Surg.* 34 (2016) 180–186.

Open Access

This article is published Open Access at [sciencedirect.com](https://www.sciencedirect.com). It is distributed under the [IJSCR Supplemental terms and conditions](#), which permits unrestricted non commercial use, distribution, and reproduction in any medium, provided the original authors and source are credited.