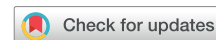



Original Research

Cutaneous manifestations of orthostatic intolerance syndromes

Caroline T. Starling BSA^a, Quoc-Bao D. Nguyen MD^b, Ian J. Butler MB.BS^c,
Mohammed T. Numan MD^c, Adelaide A. Hebert MD^{b,c,*}



^aUTHealth McGovern Medical School at Houston, Houston, Texas

^bDepartment of Dermatology, UTHealth McGovern Medical School at Houston, Houston, Texas

^cDepartment of Pediatrics, UTHealth McGovern Medical School at Houston, Houston, Texas

ARTICLE INFO

Article history:

Received 23 July 2020

Revised 5 February 2021

Accepted 5 March 2021

Keywords:

Dysautonomia

Orthostatic intolerance

Cutaneous manifestations

Hyperhidrosis

ABSTRACT

Dysautonomia refers to a group of autonomic nervous system disorders that affect nearly 70 million people worldwide. One subset of dysautonomia includes syndromes of orthostatic intolerance (OI), which primarily affect adolescents and women of childbearing age. Due to the variability in disease presentation, the average time from symptom onset to diagnosis of dysautonomia is 6 years. In general, there is a paucity of dermatological research articles describing patients with dysautonomia. The objective of this review is to summarize the existing literature on cutaneous manifestations in dysautonomia, with an emphasis on syndromes of OI. A PubMed database of the English-language literature (1970–2020) was searched using the terms “dysautonomia”, “orthostatic intolerance”, “cutaneous”, “skin”, “hyperhidrosis”, “hypohidrosis”, “sweat”, and other synonyms. Results showed that cutaneous manifestations of orthostatic intolerance are common and varied, with one paper citing up to 85% of patients with OI having at least one cutaneous symptom. Recognition of dermatological complaints may lead to an earlier diagnosis of orthostatic intolerance, as well as other comorbid conditions.

© 2021 Published by Elsevier Inc. on behalf of Women's Dermatologic Society.

This is an open access article under the CC BY-NC-ND license

(<http://creativecommons.org/licenses/by-nc-nd/4.0/>)

Background

Dysautonomia

Dysautonomia refers to a group of conditions in which there is a malfunction of the autonomic nervous system, typically involving both sympathetic and parasympathetic components, and is estimated to affect 70 million people worldwide (Goldstein et al., 2002). Various forms of dysautonomia affect individuals in different life stages. Autonomic dysfunction may present with a genetic component early on in infants, as transient episodes in otherwise healthy adolescents, or as neurodegenerative diseases later in life. Forms that occur among infants and children include sensory and autonomic neuropathy or familial dysautonomia. Among children and young adults, postural orthostatic tachycardia syndrome (POTS) and neurocardiogenic syncope (NCS) are prevalent. Neurodegenerative disorders that may occur with autonomic dysfunction include multiple system atrophy, Parkinson's disease, pure autonomic failure, and multiple sclerosis (Novak, 2019). In addition, dysautonomia can occur as a secondary disease due to con-

ditions such as alcoholism and diabetes. Small fiber neuropathies may manifest with dysautonomia as well (Novak, 2019).

Among the various forms of dysautonomia, syndromes of orthostatic intolerance (OI) are most prevalent and will be emphasized in this review. OI is characterized by reduced blood volume return when changing position from lying down to standing up. NCS is defined as a loss of consciousness with a drop of systolic blood pressure >20 mmHg from baseline with cerebral hypoperfusion and is often induced by orthostasis or emotional triggers (Lankford et al., 2015; Novak, 2019). NCS is the most common form of dysautonomia, and the majority of patients with this type of autonomic dysfunction typically experience one or two fainting episodes throughout their lives. POTS is defined as an increase in heart rate (HR) of 30 beats per minute (bpm) upon orthostatic challenge in adults or 40 bpm in adolescents age ≤18 years, or a rate >120 bpm within the first 10 minutes of standing or upright tilt for adults or 130 bpm within the first 5 minutes for those age ≤13 years, in the absence of other chronic debilitating conditions (Singer et al., 2012). POTS is associated with symptoms of OI (National Institute of Neurological Disorders and Stroke, 2020). Subtypes of POTS have been described based on similar features observed in patient populations and can be delineated as follows: hyperadrenergic, neuropathic, central, autoimmune, hypovolemic, or forms associated with deconditioning (Novak, 2019). For exam-

* Corresponding author.

E-mail address: Adelaide.A.Hebert@uth.tmc.edu (A.A. Hebert).

ple, hyperadrenergic POTS is characterized by sympathetic nervous system overactivity with plasma norepinephrine ≥ 600 pg/mL while standing (Raj, 2006). Neuropathic POTS is characterized by patchy peripheral denervation, and hypovolemic POTS is characterized by abnormal decreases in blood volume. POTS can result in chronic fatigue, sleep disturbances, and difficulty standing, which greatly affects quality of life (Freeman et al., 2015; Goldstein et al., 2002). The exact prevalence of POTS is unknown, but studies estimate that >500,000 Americans are affected, nearly 80% of whom are women age 15 to 50 years (National Institute of Neurological Disorders and Stroke, 2020).

Dysautonomia is associated with many other chronic conditions, including Ehlers-Danlos syndrome (EDS), mast cell activation disorders, and rheumatologic disorders, which will be discussed as well. At present, there are few publications on dysautonomia in dermatology journals. To our knowledge, this is the first review summarizing the literature on dermatologic findings in patients with dysautonomia.

Objective

The objective of this review is to summarize the existing literature on cutaneous manifestations in dysautonomia, with an emphasis on syndromes of OI.

Methods

This manuscript is a review of a literature search performed in July 2020 in PubMed using the following terms: “dysautonomia”, “orthostatic intolerance”, “postural orthostatic tachycardia”, “neurocardiogenic syncope”, “skin”, “cutaneous”, “hyperhidrosis”, “hypohidrosis”, and “sweat”. The search generated 575 articles, including 500 English-language articles and two articles with available English translations.

Titles and abstracts were screened to select publications that were specific to childhood/early adulthood forms of dysautonomia and OI. All relevant English-language literature was reviewed. Papers on rare, neurodegenerative, and acute forms of dysautonomia were excluded, including familial/Riley-Day syndrome, multiple system atrophy, Parkinson's disease, multiple sclerosis, Guillain-Barré syndrome, spinal cord injury, stroke, Rett syndrome, and animal studies. Appendix A shows a comprehensive list of the article exclusion criteria.

Results

Cutaneous manifestations

Cutaneous manifestations are common among individuals with OI syndromes. A review of 26 patients with POTS showed that 22 patients (85%) had at least one cutaneous symptom (Huang et al., 2016). Cutaneous manifestations of OI include, but are not limited, to Raynaud's phenomenon, livedo reticularis, cutaneous flushing, evanescent hyperemia, pallor, urticaria, erythromelalgia, and hypo- and hyperhidrosis. Table 1 summarizes the prevalence of cutaneous manifestations noted in the studies in which such data were available. Raynaud's phenomenon appears to be more prevalent compared with other cutaneous manifestations (Huang and Hohler, 2015; Huang et al., 2016; Ojha et al., 2011).

Huang et al. (2016) noted Raynaud's phenomenon in 48% of the 26 patients with POTS who participated in their study. Primary Raynaud's phenomenon is characterized by reversible vasospasm in the peripheral arteries, whereas secondary Raynaud's phenomenon is associated with underlying disorders. The prevalence of Raynaud's phenomenon in the general population is approximately 3%

to 5% (Maundrell and Proudman, 2015). Livedo reticularis is characterized by netlike, mottled discoloration of the skin, most often seen on the legs, arms, or trunk (Kelly and Baker, 2018). Livedo reticularis can be physiological, but should be further evaluated for possible underlying disorders (including antiphospholipid syndrome or, as this review shows, OI) when seen with systemic symptoms.

Facial pallor and erythema are common as well and often present periodically (Khan and Affleck, 2018; Pandian et al., 2007). Erythromelalgia, defined as episodes of burning pain and erythema, is commonly observed on the hands and feet. Patients with symptoms of autonomic dysfunction have reported episodes in less common anatomical sites, including the ears (Hoeijmakers et al., 2012; Raieli et al., 2016).

Parsaik et al. (2013) analyzed differences in symptoms among patients with POTS versus OI and found that those with POTS had a mild difference in degree of sweating. Among 84 patients with POTS, 4% reported decreased sweating and 18% reported increased sweating. Among 100 patients with OI, 2% reported decreased sweating and 15% reported increased sweating (Parsaik et al., 2013).

Cutaneous manifestations may prompt clinicians to investigate autonomic dysfunction. For example, in a study of a family with autosomal dominant transmission of primary focal hyperhidrosis, four of six members reported orthostatic symptoms, two of whom had increased responses on head-up tilt testing (Del Sorbo et al., 2012). Skin biopsies showed a loss of epidermal nerve fibers and reduced innervation of the sweat glands. Additionally, one family member who was not affected by hyperhidrosis experienced abnormal responses during other cardiovascular autonomic testing, including isometric hand grip, cold pressor, and hyperventilation.

Diagnosing autonomic dysfunction

If autonomic dysfunction is suspected, clinicians may ask the patient if he or she has the following: 1) difficulty sitting or standing upright, 2) indigestion or other gastric symptoms, 3) abnormal blood vessel functioning (e.g., low or high blood pressure), 4) increased or decreased sweating, 5) changes in urinary frequency or urinary incontinence, and 6) blurred vision or loss of vision (Sletten et al., 2012). Headache is a common presenting symptom, noted in nearly half of patients in a retrospective study of patients with OI (Gourishankar et al., 2020). Erectile dysfunction is a common symptom in dysautonomia as well. Figure 1 summarizes an approach to screening for OI. Referral to a neurologist or cardiologist with special interest in dysautonomia for further testing may be helpful if the patient experiences challenges in two or more of these domains. Figure 2–5 display case examples from the UTHealth Dysautonomia Center of Excellence.

Autonomic testing comprises cardiovagal, sudomotor, and adrenergic components (Low et al., 2013). Cardiovagal function may be assessed by HR variability during deep breathing and by the Valsalva maneuver. Sudomotor function may be assessed by the quantitative sudomotor axon reflex test (QSART) and the thermoregulatory sweat test, otherwise known as the starch iodine test. In the QSART, multi-compartmental capsules are placed on the skin, and iontophoresis of acetylcholine is applied to stimulate the sweat glands (Illigens and Gibbons, 2009). Humidity recordings are translated into sweat output measurements (Low, 1993). A decrease in sweat production indicates dysfunction of sympathetic nerve terminal acetylcholine release. In the thermoregulatory sweat test, the patient's core body temperature is raised to 38°C, and sweat patterns are identified by a change in color of an applied indicator powder mixture, either alizarin red powder or iodine corn starch. Sympathetic skin response is used to study sudomotor and sympathetic function of the sweat glands. In this test,

Table 1
Cutaneous manifestations of orthostatic intolerance syndromes

Dermatological manifestation	Type of dysautonomia	Patient population	Citation
Acrocyanosis	POTS	1 case	Landero, 2014
Dysesthesia/allodynia	POTS	1 case	Landero, 2014
Erythromelalgia	Cardiovascular and other autonomic systemic symptoms	9 of 40 patients (23%)	Oaklander and Klein, 2013
Evanescent hyperemia	POTS	2 cases	Huang and Hohler 2015; Landero, 2014
Livedo reticularis	POTS	2 cases, one in which the patient had Raynaud's phenomenon as well	Huang and Hohler 2015; Landero, 2014
Madarosis	POTS	1 case	Landero, 2014
Pruritus associated with rash	POTS	54% of 26 patients at Boston University Medical College	Huang et al., 2016
Rash (unspecified)	POTS	77% of 26 patients at Boston University Medical College	Huang et al., 2016
Raynaud's phenomenon	POTS	48% of 26 patients at Boston University Medical Center; 1 patient with joint hypermobility and Raynaud's phenomenon; 20 of 27 patients (74%) with POTS in Ohio	Huang and Hohler, 2015; Huang et al., 2016; Ojha et al., 2011
Urticaria	POTS	25% of 26 patients at Boston University Medical College	Huang et al., 2016
Varicose veins	POTS	13% of 26 patients at Boston University Medical College	Huang et al., 2016
Hypohidrosis	POTS, OI	4% of 84 patients with POTS reported decreased sweating and 2% with OI reported decreased sweating; of 30 women (age 20–58 years), 17 patients (56%) had abnormal QSART, which was typically patchy and involved the lower extremity (lower volume); 8 of 152 female patients with POTS (5%) at Mayo Clinic (68% with abnormal QSART); 1 patient with Sjögren's syndrome	Chikazawa et al., 1998; Parsaik et al., 2013; Peltier et al., 2010; Thieben et al., 2007
Hyperhidrosis	POTS, OI, unspecified orthostatic symptoms	18% with POTS reported increased sweating and 15% with OI reported increased sweating; 4 of 6 family members with hyperhidrosis and reported orthostatic symptoms; 5 of 10 patients with POTS in Australia; 14 of 152 female patients with POTS (9%) at Mayo Clinic (68% with abnormal QSART); 1 patient with Sjögren's syndrome	Chikazawa et al., 1998; Del Sorbo et al., 2012; Pandian et al., 2007; Parsaik et al., 2013; Thieben et al., 2007
Pallor	POTS	7 of 10 patients with POTS in Australia	Pandian et al., 2007
Erythema of extremities	POTS	5 of 10 patients with POTS in Australia	Pandian et al., 2007
Flushing	Orthostatic hypotension	1 patient with OH and Sjögren's syndrome	Chikazawa et al., 1998

OI, orthostatic intolerance; POTS, postural orthostatic tachycardia syndrome; QSART, quantitative sudomotor axon reflex test

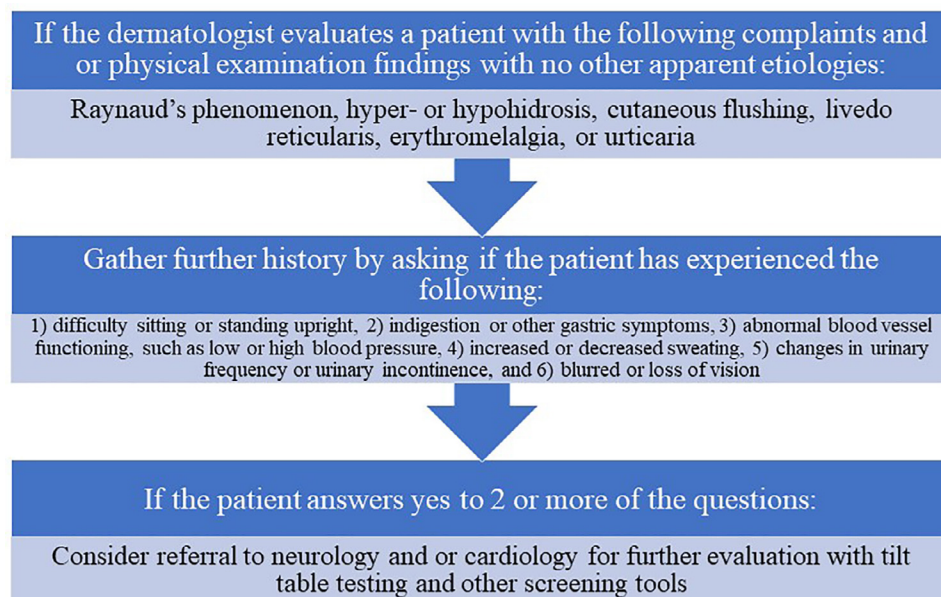


Fig. 1. Flow chart of approach to screening for orthostatic intolerance syndromes in the dermatology office.

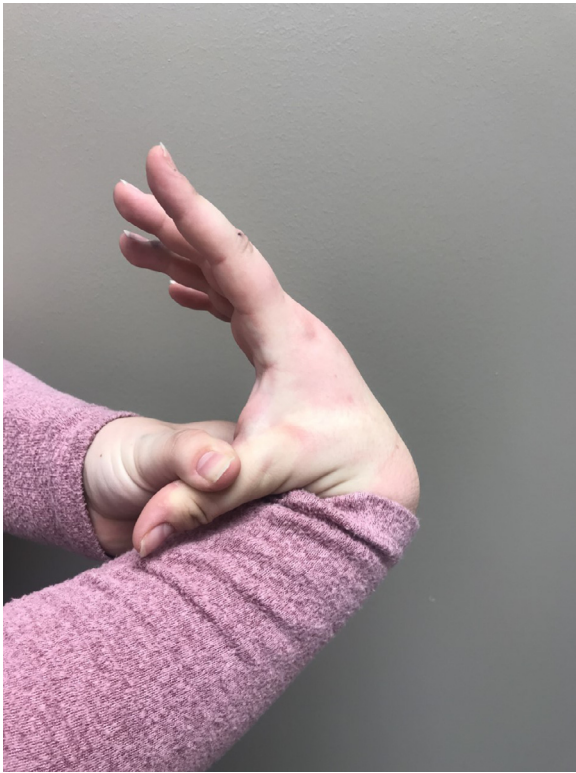

Fig. 2. Twenty-year-old female patient with a history of hyperhidrosis, Ehlers-Danlos/joint hypermobility syndrome, and dysautonomia demonstrating joint hypermobility of the right wrist with flexion of the thumb to the forearm.

changes in skin potential are measured and recorded once a stimulus is applied, such as a deep breath, startle response, or electrical stimulation (Arunodaya and Taly, 1995; Illigens and Gibbons, 2009).

Adrenergic function is assessed by blood pressure and HR responses in the head-up tilt test and by the Valsalva maneuver. In the head-up tilt test, a normal response is a rise in HR of 5 to 20

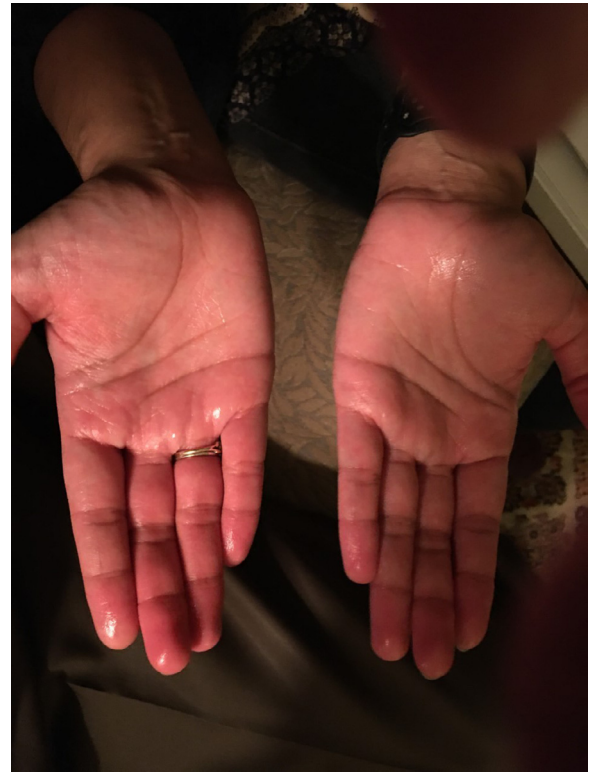

Fig. 3. Hyperhidrosis of the palms in a 30-year-old female patient with dysautonomia.

bpm and relatively constant blood pressure (no more than 10 mm Hg decrease in systolic and a modest rise in diastolic blood pressure).

The autonomic reflex screen combines the peripheral sudomotor and adrenergic function, cardiac vagal, and adrenergic function results in a composite autonomic severity score, which ranges from 0 to 10 (normal autonomic function to maximal dysfunction; Low et al., 2013).

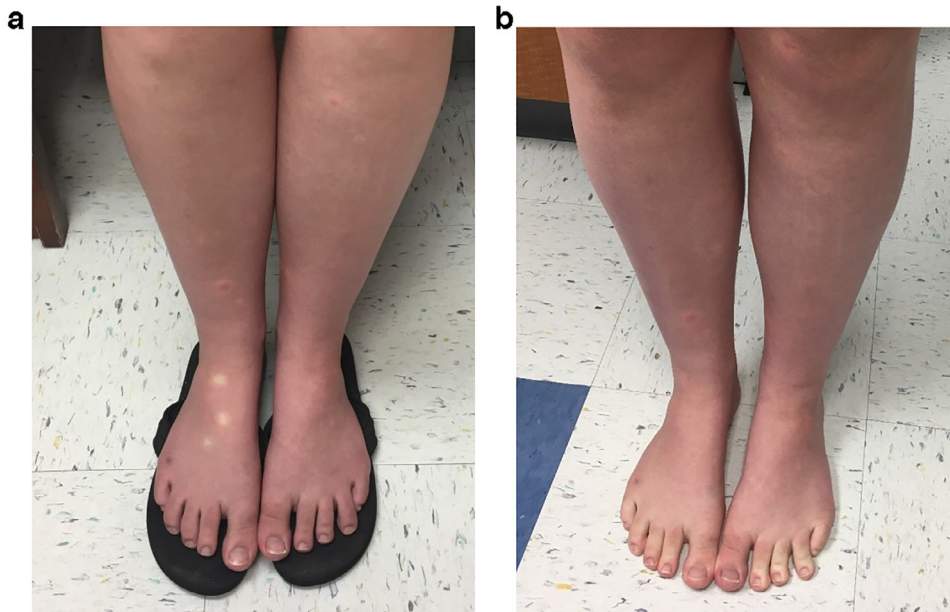


Fig. 4. Fourteen-year-old female patient with dysautonomia with (A) acrocyanosis and prolonged blanching of the right dorsal foot after finger-tip pressure while sitting and (B) acrocyanosis and blanching of the toes while standing.

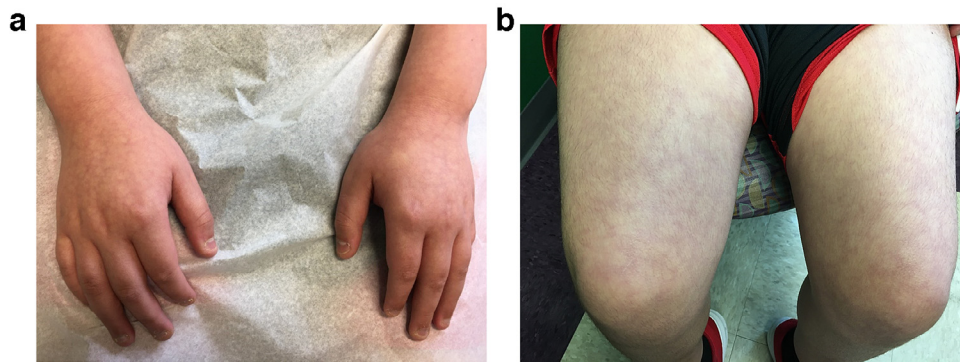


Fig. 5. Fourteen-year-old male patient with tachycardia and dysautonomia presenting with livedoid pattern on the (A) hands and forearms and (B) thighs.

Joint hypermobility and Ehlers-Danlos syndrome

EDS refers to a group of heritable soft connective tissue disorders. EDS hypermobile type (HT) is characterized by generalized joint hypermobility and skin texture abnormalities. Currently, EDS-HT is grouped with joint hypermobility syndrome (JHS) as one entity, although both syndromes have been studied separately (Tinkle et al., 2017). Dysautonomia is common among this patient population and is often overlooked (Celletti et al., 2017; Kumar and Lenert, 2017). Celletti et al. (2017) measured autonomic dysfunction in 35 patients with JHS/EDS-HT and found that 48.6% of their patients had POTS, 31.4% had OI, and one patient had orthostatic hypotension. Other studies have estimated the prevalence of OI to be 74% in patients with EDS-HT and 78% in patients with joint hypermobility syndrome (De Wandele et al., 2014; Gazit et al., 2003). Symptoms of patients with EDS-HT vary tremendously and extend beyond musculoskeletal abnormalities.

Autonomic symptoms among patients with EDS-HT include increased sympathetic activity at rest and decreased sympathetic activity in response to stimuli (De Wandele et al., 2014). Compared with healthy individuals, patients with EDS-HT are more likely to have POTS and lower sweat volume production. Furthermore, skin extensibility was linked to increased autonomic dysfunction in patients with EDS-HT. Abnormal sweat testing was common among a small population of patients with POTS and EDS-HT (Miglis et al., 2017).

De Wandele et al. (2013) performed a cluster analysis of patients with EDS-HT that identified three subgroups with different symptoms, as well as a varying number of symptoms. Notable cutaneous findings included skin fragility and slow wound healing. The authors hypothesized that clinical heterogeneity observed among patients with EDS-HT could be due to underlying dysautonomia. Of note, the group with a higher number of nonmusculoskeletal symptoms had worse physical and psychosocial health, indicating the importance of addressing the whole spectrum of symptoms in patients with EDS-HT (De Wandele et al., 2013). Piezogenic papules and easy bruising are common with EDS-HT as well (Castori et al., 2010). The presence of hematomas was correlated with symptoms of chest discomfort, palpitations, orthostatic tachycardia, and categories of chronic moderate and severe pain in patients with joint hypermobility in a study completed in Cuba (Menéndez Alejo et al., 2009). Similar to dysautonomia, EDS-HT is underdiagnosed, resulting in increased expenses and inappropriate therapies that further reduce quality of life in this patient population (Castori et al., 2010).

Mast cell activation disorders

Mast cells are involved in IgE-mediated allergic responses and play an important role in responding to pathogens or tissue injury.

Mast cell activation disorder (MCAD) may manifest with flushing, urticaria, pruritus, diarrhea, abdominal cramping, anaphylaxis, neuropsychiatric symptoms, osteoporosis, and possible hepato- or splenomegaly. Growing evidence suggests there is a link between Ehlers-Danlos syndrome and MCAD (Seneviratne et al., 2017). Notable symptoms of this patient population include asthma or a history of anaphylaxis in addition to joint hypermobility. Cheung and Vadas (2015) proposed a disease triad including MCAD, POTS, and EDS after screening for MCAD symptoms among patients with a diagnosis of POTS and EDS (Cheung and Vadas, 2015). This relationship may explain the cutaneous findings of pruritus in some patients with POTS.

Other comorbidities

Dysautonomia is commonly observed in patients with Sjögren's syndrome, Behçet disease, and antiphospholipid syndrome, and other autoimmune diseases. In Sjögren's syndrome, OI is prevalent, indicative of sympathetic dysfunction. Secretomotor and pupillo-motor function is decreased due to exocrine gland destruction. Urinary dysfunction and gastroparesis are common symptoms as well, pointing to parasympathetic dysfunction (Mandl et al., 2008). Cases of decreased sweating have been reported, likely due to autoimmune forms (Sakakibara et al., 2004).

Dysautonomia, including POTS, NCS, inappropriate sinus tachycardia, labile hypertension, complex regional pain syndrome, gastrointestinal dysmotility, and neurogenic bladder, has been observed in patients with antiphospholipid syndrome and may be the presenting symptoms in some cases (Schofield, 2017). Livedo reticularis and Raynaud's phenomenon are prevalent cutaneous manifestations in patients with antiphospholipid syndrome and autonomic dysfunction. Recognition of this condition is important, given patients' high risk of thrombotic events. Autonomic dysfunction has been observed in several patients with Bechet's disease as well, characterized by increased latencies in sympathetic skin response testing (Borman et al., 2012).

Pathogenesis of dysautonomia and cutaneous manifestations

The pathogenesis of syndromes of OI is not well established, but many symptoms experienced by patients can be explained by abnormal vasoconstriction and vascular dynamics (Stewart et al., 2003; 2008; 2009; 2011; 2011; Medow et al., 2005). Autonomic neuropathy likely contributes to the inadequate vascular response observed in POTS as well (Kanjwal et al., 2003; Oaklander and Klein, 2013). Evidence for associations with autoimmunity is stronger for idiopathic and paraneoplastic forms of dysautonomia, which are beyond the scope of this review (Klein, 2008). However, the presence of ganglionic acetylcholine receptor antibodies in a small percentage of patients with POTS has been observed

(Vernino et al., 2000). One group examined cells of a patient with POTS to investigate low levels of plasma choline concentration and observed upregulation in choline transporter when cells were treated with choline (Schenkel et al., 2015). Choline plays a role in osmoregulation and could be indicated to reduce volume regulation abnormalities in patients with POTS.

The cause of dysautonomia in patients with EDS-HT is not well elucidated; however, several hypotheses exist. A high prevalence of abnormal QSART among this subset of patients suggests peripheral neuropathy, and consequently insufficient vasoconstriction during upright posture, as one mechanism. Increased blood vessel distensibility, leading to increased venous pooling, is another plausible cause of dysautonomia in patients with EDS-HT, specifically those who have normal QSART results (De Wandele et al., 2014). Increased arterial elasticity has been demonstrated by decreased pulse wave velocity in patients with EDS (Miller et al., 2020). Patients with EDS-HT are often prescribed vasoactive medications, which influence sympathetic function as well. Still, the high prevalence of dysautonomia in patients with JHS who are not taking vasoactive medications points to the multifactorial cause of dysautonomia.

Pathophysiology of cutaneous manifestations in patients with POTS

Insufficient vascular dynamics in patients with dysautonomia likely contributes to the development of cutaneous manifestations. The mechanism by which livedo reticularis occurs may be due to the venodilation of vessels and ischemia in the subcapillary venous plexus. Raynaud's phenomenon and dysesthesia can be induced by diminished blood flow and hypoxia. Evanescent hyperemia, which is highly prevalent among patients with hyperadrenergic/low-flow forms of POTS, could be due to local increased cutaneous reactivity to vasoconstrictors, including angiotensin II (Landerio, 2014). Hyperhidrosis and hypohidrosis likely occur due to a malfunction of both the sympathetic and parasympathetic pathways, with fluctuations in activity of the eccrine sweat glands (Kaya et al., 2005).

Several studies have assessed the innervation of the sweat glands among patients who experience sweat disorders in the context of rare, debilitating neurologic diseases. Among patients with Ross syndrome, individuals who experience either anhidrosis or hyperhidrosis are found to have an absence of sympathetic cholinergic innervation within the skin (Nolano et al., 2006). Sweat glands among patients with familial dysautonomia are normal in number; however, the density of innervation of sweat glands is lower compared with that of individuals without the disease (Hilz et al., 2004). Studies describing the innervation of sweat glands among patients with other forms of dysautonomia are warranted.

Quality of life among patients with dysautonomia

Quality of life in patients with dysautonomia varies depending on the severity and frequency of the symptoms patients experience. For those with more severe symptoms, impairment can hinder routine daily activities and is comparable to that of patients with congestive heart failure or chronic obstructive pulmonary disease (Grubb Blair, 2008). A lack of diagnosis contributes to patient suffering as well. The average time to diagnosis of POTS is nearly 6 years. Furthermore, patients are commonly misdiagnosed as having panic disorder or anxiety (Grubb Blair P. 2008; Freeman et al. 2015).

Treatment for cutaneous manifestations

The use of an oral angiotensin II type I receptor antagonist, losartan, resulted in marked improvement in a patient with POTS who presented with numerous dermatologic manifestations upon

hospitalization due to a flare in symptoms. The patient's dermatologic symptoms included evanescent, hyperemic, sharply demarcated, irregular patches that resolved upon diascopy, livedo reticularis, acrocyanosis, koilonychia, and patchy loss of eyelashes (Landerio, 2014). Of note, the patient did have a history of menometrorrhagia and low serum ferritin on laboratory testing; therefore, the koilonychia was likely due to iron deficiency. Treatment with fludrocortisone resulted in a reduction of evanescent hyperemia episodes in another patient with POTS (Huang and Hohler, 2015). Compression stockings, adequate oral salt and fluid intake, and exercise provided relief for this patient as well. Treatment with midodrine reduced livedo reticularis and Raynaud's phenomenon in a patient with POTS (Huang and Hohler, 2015).

Medications to treat the underlying autonomic dysfunction in patients with POTS include adequate fluid intake, elastic compression stockings, beta blockers, stimulants, serotonin reuptake inhibitors/norepinephrine reuptake inhibitors, pyridostigmine, fludrocortisone, midodrine, erythropoietin, octreotide, and clonidine (Grubb Blair, 2008; Klein, 2008).

Conclusions

Cutaneous manifestations of dysautonomia include, but are not limited to, Raynaud's phenomenon, livedo reticularis, pallor, cutaneous flushing, evanescent hyperemia, erythromelalgia, and hypohidrosis. The role of the dermatologist may be critical in the initial recognition of autonomic dysfunction due to the myriad of cutaneous findings. This manuscript is meant to increase clinician awareness of dysautonomia and orthostatic intolerance, which may reduce delays in diagnosis and treatment of this complex, multisystem disorder. The secondary goal of this review is to encourage clinicians to increase efforts to document and record cutaneous findings in this patient population, given that the majority of available publications with prevalence estimates are case series or mid-sized cohort studies. Further study on the treatment of cutaneous manifestations of orthostatic intolerance is warranted.

Conflicts of interest

None.

Funding

None.

Study approval

The author(s) confirm that any aspect of the work covered in this manuscript that has involved human patients has been conducted with the ethical approval of all relevant bodies.

Supplementary materials

Supplementary material associated with this article can be found, in the online version, at [doi:10.1016/j.ijwd.2021.03.003](https://doi.org/10.1016/j.ijwd.2021.03.003).

References

- Arunodaya GR, Taly AB. Sympathetic skin response: A decade later. *J Neurol Sci* 1995;129(2):81–9.
- Borman P, Tuncay F, Kocaoğlu S, Okumuş M, Güngör E, Ekşioğlu M. The subclinical autonomic dysfunction in patients with Behçet disease: An electrophysiological study. *Clin Rheumatol* 2012;31(1):41–7.
- Castori M, Camerota F, Celletti C, Danese C, Santilli V, Saraceni VM, et al. Natural history and manifestations of the hypermobility type Ehlers-Danlos syndrome: A pilot study on 21 patients. *Am J Med Genet A* 2010;152A(3):556–64.

- Celletti C, Camerota F, Castori M, Censi F, Giofrè L, Calcagnini G, et al. Orthostatic intolerance and postural orthostatic tachycardia syndrome in joint hypermobility syndrome/Ehlers-Danlos syndrome, hypermobility type: Neurovegetative dysregulation or autonomic failure? *BioMed Res Int* 2017;2017.
- Cheung I, Vadas P. A new disease cluster: Mast cell activation syndrome, postural orthostatic tachycardia syndrome, and Ehlers-Danlos syndrome. *J Allergy Clin Immunol* 2015;135(2):AB65.
- Chikazawa H, Nishiya K, Hashimoto K. Peripheral neuropathy and dysautonomia in a patient with primary Sjögren's syndrome. *Nihon Rinsho Meneki Gakkai Kaishi* 1998;21(1):57–63.
- De Wandele I, Rombaut L, Leybaert L, Van de Borne P, De Backer T, Malfait F, et al. Dysautonomia and its underlying mechanisms in the hypermobility type of Ehlers-Danlos syndrome. *Semin Arthritis Rheum* 2014;44(1):93–100.
- De Wandele I, Rombaut L, Malfait F, De Backer T, De Paepe A, Calders P. Clinical heterogeneity in patients with the hypermobility type of Ehlers-Danlos syndrome. *Res Dev Disabil* 2013;34(3):873–81.
- Del Sorbo F, Brancati F, De Joanna G, Valente EM, Lauria G, Albanese A. Primary focal hyperhidrosis in a new family not linked to known loci. *Dermatol Basel* 2012;223(4):335–42.
- Freeman K, Goldstein DS, Thompson CB. The dysautonomia project: Understanding autonomic nervous system disorders for physicians and patients. Sarasota, FL: Bardolf & Company; 2015.
- Gazit Y, Nahir AM, Grahame R, Jacob G. Dysautonomia in the joint hypermobility syndrome. *Am J Med* 2003;115(1):33–40.
- Goldstein DS, Robertson D, Esler M, Straus SE, Eisenhofer G. Dysautonomias: Clinical disorders of the autonomic nervous system. *Ann Intern Med* 2002;137(9):753–63.
- Gourishankar A, Belton MD, Hashmi SS, Butler IJ, Lankford JE, Numan MT. Demographic and clinical features of pediatric patients with orthostatic intolerance and abnormal head-up tilt table test: A retrospective descriptive study. *Pediatr Neonatol* 2020;61(1):68–74.
- Grubb Blair P. Postural tachycardia syndrome. *Circulation* 2008;117(21):2814–17.
- Hilz MJ, Axelrod FB, Bickel A, Stemper B, Brys M, Wendelschafer-Crabb G, et al. Assessing function and pathology in familial dysautonomia: Assessment of temperature perception, sweating and cutaneous innervation. *Brain J Neurol* 2004(Pt 9):2090–8.
- Hoeijmakers JGJ, Han C, Merckies ISJ, Macala LJ, Lauria G, Gerrits MM, et al. Small nerve fibres, small hands and small feet: A new syndrome of pain, dysautonomia and acromesomelia in a kindred with a novel Nav1.7 mutation. *Brain* 2012;135(2):345–58.
- Huang H, Deb A, Culbertson C, Morgenshtern K, DePold Hohler A. Dermatological manifestations of postural tachycardia syndrome are common and diverse. *J Clin Neurol* 2016;12(1):75–8.
- Huang H, Hohler AD. The dermatological manifestations of postural tachycardia syndrome: A review with illustrated cases. *Am J Clin Dermatol* 2015;16(5):425–30.
- Illigens BMW, Gibbons CH. Sweat testing to evaluate autonomic function. *Clin Auton Res* 2009;19(2):79–87.
- Kanjwal Y, Kosinski D, Grubb BP. The postural orthostatic tachycardia syndrome: Definitions, diagnosis, and management. *Pacing Clin Electrophysiol* 2003;26(8):1747–57.
- Kaya D, Karaca S, Barutcu I, Esen AM, Kulac M, Esen O. Heart rate variability in patients with essential hyperhidrosis: Dynamic influence of sympathetic and parasympathetic maneuvers. *Ann Noninvasive Electrocardiol* 2005;10(1):1–6.
- Kelly R, Baker C. Other vascular disorders. *Dermatology*. Philadelphia, PA: Elsevier; 2018. p. 1847–57.
- Khan S, Affleck A. Periodic facial erythema in a patient with postural orthostatic tachycardia syndrome. *Clin Exp Dermatol* 2018;43(1):100–2.
- Klein CM. Evaluation and management of autonomic nervous system disorders. *Semin Neurol* 2008;28(02):195–204.
- Kumar B, Lenert P. Joint hypermobility syndrome: Recognizing a commonly overlooked cause of chronic pain. *Am J Med* 2017;130(6):640–7.
- Landero J. Postural orthostatic tachycardia syndrome: A dermatologic perspective and successful treatment with losartan. *J Clin Aesthetic Dermatol* 2014;7(8):41–7.
- Lankford J, Numan M, Hashmi SS, Gourishankar A, Butler IJ. Cerebral blood flow during HUTT in young patients with orthostatic intolerance. *Clin Auton Res* 2015;25(5):277–84.
- Low PA. Autonomic nervous system function. *J Clin Neurophysiol* 1993;10(1):14–27.
- Low PA, Tomalia VA, Park KJ. Autonomic function tests: some clinical applications. *J Clin Neurol* 2013;9(1):1–8.
- Mandt T, Granberg V, Apelqvist J, Wollmer P, Manthorpe R, Jacobsson LTH. Autonomic nervous symptoms in primary Sjögren's syndrome. *Rheumatology* 2008;47(6):914–19.
- Maudrell A, Proudman SM. Epidemiology of Raynaud's phenomenon. In: Wigley FM, Herrick AL, Flavahan NA, editors. *Raynaud's phenomenon: A guide to pathogenesis and treatment*. New York, NY: Springer; 2015. p. 21–35.
- Medow MS, Minson CT, Stewart JM. Decreased microvascular nitric oxide-dependent vasodilation in postural tachycardia syndrome. *Circulation* 2005;112(17):2611–18.
- Menéndez Alejo FM, Díaz Lazaga D, Torrez Cárdenas V, Martínez Rodríguez V. The joint hypermobility syndrome in a Cuban juvenile population. *Reumatol Clin* 2009;5(6):244–7.
- Miglis MG, Schultz B, Muppidi S. Postural tachycardia in hypermobile Ehlers-Danlos syndrome: A distinct subtype? *Auton Neurosci Basic Clin* 2017;208:146–9.
- Miller AJ, Schubart JR, Sheehan T, Bascom R, Francomano CA. Arterial elasticity in Ehlers-Danlos syndromes. *Genes* 2020;11(1):55.
- National Institute of Neurological Disorders and Stroke. *Dysautonomia information* [Internet]; 2020 [cited 2020 July 5]. Available from: <https://www.ninds.nih.gov/disorders/all-disorders/dysautonomia-information-page#disorders-r1>.
- Nolano M, Provitera V, Perretti A, Stancanelli A, Saltalamacchia AM, Donadio V, et al. Ross syndrome: A rare or a misknown disorder of thermoregulation? A skin innervation study on 12 subjects. *Brain J Neurol* 2006;129(Pt 8):2119–31.
- Novak P. Autonomic disorders. *Am J Med* 2019;132(4):420–36.
- Oaklander AL, Klein MM. Evidence of small-fiber polyneuropathy in unexplained, juvenile-onset, widespread pain syndromes. *Pediatrics* 2013;131(4):e1091–100.
- Ojha A, Chelimsky TC, Chelimsky G. Comorbidities in pediatric patients with postural orthostatic tachycardia syndrome. *J Pediatr* 2011;158(1):20–3.
- Pandian JD, Dalton K, Henderson RD, McCombe PA. Postural orthostatic tachycardia syndrome: An underrecognized disorder. *Intern Med J* 2007;37(8):529–35.
- Parsaik AK, Singer W, Allison TG, Sletten DM, Joyner MJ, Benarroch EE, et al. Orthostatic intolerance without postural tachycardia: How much dysautonomia? *Clin Auton Res* 2013;23(4):181–8.
- Peltier AC, Garland E, Raj SR, Sato K, Black B, Song Y, et al. Distal sudomotor findings in postural tachycardia syndrome. *Clin Auton Res* 2010;20(2):93–9.
- Raieli V, Compagno A, D'Amelio M. Red ear syndrome. *Curr Pain Headache Rep* 2016;20(3):19.
- Raj SR. The postural tachycardia syndrome (POTS): Pathophysiology, diagnosis & management. *Indian Pacing Electrophysiol J* 2006;6(2):84–99.
- Sakakibara R, Hirano S, Asahina M, Sawai S, Nemoto Y, Hiraga A, et al. Primary Sjögren's syndrome presenting with generalized autonomic failure. *Eur J Neurol* 2004;11(9):635–8.
- Schenkel LC, Singh RK, Michel V, Zeisel SH, da Costa KA, Johnson AR, et al. Mechanism of choline deficiency and membrane alteration in postural orthostatic tachycardia syndrome primary skin fibroblasts. *FASEB J* 2015;29(5):1663–75.
- Schofield JR. Autonomic neuropathy-in its many guises-as the initial manifestation of the antiphospholipid syndrome. *Immunol Res* 2017;65(2):532–42.
- Seneviratne SL, Maitland A, Afrin L. Mast cell disorders in Ehlers-Danlos syndrome. *Am J Med Genet C Semin Med Genet* 2017;175(1):226–36.
- Singer W, Sletten DM, Opfer-Gehrking TL, Brands CK, Fischer PR, Low PA. Postural tachycardia in children and adolescents - What is abnormal? *J Pediatr* 2012;160(2):222–6.
- Sletten DM, Suarez GA, Low PA, Mandrekar J, Singer W. COMPASS 31: A refined and abbreviated composite autonomic symptom score. *Mayo Clin Proc* 2012;87(12):1196–201.
- Stewart JM, Medow MS, Montgomery LD. Local vascular responses affecting blood flow in postural tachycardia syndrome. *Am J Physiol Heart Circ Physiol* 2003;285(6):H2749–56.
- Stewart JM, Ocon AJ, Clarke D, Taneja I, Medow MS. Defects in cutaneous angiotensin-converting enzyme 2 and angiotensin-(1-7) production in postural tachycardia syndrome. *Hypertension* 2009;53(5):767–74.
- Stewart JM, Ocon AJ, Medow MS. Ascorbate improves circulation in postural tachycardia syndrome. *Am J Physiol Heart Circ Physiol* 2011;301(3):H1033–42.
- Stewart JM, Taneja I, Glover J, Medow MS. Angiotensin II type 1 receptor blockade corrects cutaneous nitric oxide deficit in postural tachycardia syndrome. *Am J Physiol Heart Circ Physiol* 2008;294(1):H466–73.
- Thiepen MJ, Sandroni P, Sletten DM, Benrud-Larson LM, Fealey RD, Vernino S, et al. Postural orthostatic tachycardia syndrome: The Mayo clinic experience. *Mayo Clin Proc* 2007;82(3):308–13.
- Tinkle B, Castori M, Berglund B, Cohen H, Grahame R, Kazkaz H, et al. Hypermobile Ehlers-Danlos syndrome (a.k.a. Ehlers-Danlos syndrome Type III and Ehlers-Danlos syndrome hypermobility type): Clinical description and natural history. *Am J Med Genet C Semin Med Genet* 2017;175(1):48–69.
- Vernino S, Low PA, Fealey RD, Stewart JD, Farrugia G, Lennon VA. Autoantibodies to ganglionic acetylcholine receptors in autoimmune autonomic neuropathies. *N Engl J Med* 2000;343(12):847–55.